

## Expression of Vascular Endothelial Growth Factor and Microvessel Density in Psoriatic Skin Lesions

### Abstract

**Background:** Psoriasis is a common chronic and immune-mediated skin disorder having a significant impact on the patient's quality of life. An analysis of the role of angiogenic vascular endothelial growth factor (VEGF) expression and microvessel density in psoriatic skin lesions may help in better understanding of the disease pathogenesis. The aim of this study was to examine the expression of vascular endothelial growth factor (VEGF) and microvessel density using CD34 antibodies in psoriatic skin lesions by immunohistochemical examination using normal skin of healthy individuals as controls. **Materials and Methods:** Patients with clinical diagnosis of plaque type of psoriasis (e.g., chronic plaque) ( $n = 49$ ) were included in the study. 5-mm punch biopsies were taken from the psoriatic skin lesions in these patients. A total of 20 punch biopsies were taken from the control group comprising of 20 healthy volunteers. The biopsies were subjected to histopathological examination for confirmation of diagnosis and grading. Immunohistochemical evaluation was done for the expression of VEGF, and microvessel density was assessed using CD34 and compared with the controls. **Results:** An increased VEGF expression by keratinocytes ( $49.80\% \pm 21.16\%$ ) and microvessel density in the papillary dermis ( $15.302\% \pm 3.8061\%$ ) was observed in patients with psoriasis, which was significantly higher as compared to controls ( $P < 0.0001$ ). A significant positive correlation was observed between VEGF expression by keratinocytes and the microvessel density in the dermis ( $r = 0.664$ ,  $P = 0.01$ ). No significant correlation was observed between the histopathological grade of psoriasis and microvessel density, or with the VEGF expression. **Conclusion:** VEGF expression ascertained to be a significant factor in the pathogenesis of psoriasis.

**Keywords:** CD34, microvessel density, psoriasis, vascular endothelial growth factor

### Introduction

Psoriasis vulgaris is an inflammatory and chronic proliferative dermatological disorder characterized clinically by the appearance of red, scaly, and raised skin lesions<sup>[1]</sup> as a result of abnormal differentiation, hyperproliferation, and inflammatory infiltration in the dermis and epidermis.<sup>[1]</sup> Long-term treatment is often required, and refractoriness to treatment modalities and relapses are common reinforcing the need of newer treatment modalities. A study by Folkman *et al.* reported that increased angiogenesis is a contributory factor in psoriasis pathogenesis.<sup>[2]</sup>

Vascular endothelial growth factor (VEGF), CD31, CD34, and nerve growth factor (NGF) have been established as prognostic marker of angiogenesis.<sup>[3]</sup> The keratinocytes in the psoriatic lesions are considered as the main source of

proangiogenic cytokines, which induce angiogenesis through VEGF.<sup>[4]</sup> VEGF, a 40- to 45-kDa dimeric glycoprotein, regulates neovascularization during skeletal growth, reproductive functions, embryogenesis, and pathological processes.<sup>[5]</sup> Therefore, overexpression of VEGF plays a predictive marker in psoriasis. Detection of CD34 antigen, in the endothelial cells of capillaries (approximately 1% of human thymocytes), acts as a marker of angiogenesis to measure the microvascular density (MVD).<sup>[6]</sup>

Currently, anti-VEGF therapy is under developmental stage for the treatment of numerous malignancies. Evaluation of the expression of VEGF and CD34 in psoriatic plaques and comparing the same with normal skin may provide some insights to the pathogenesis of psoriasis thus helping the development of targeted therapy. Hence, we aimed to study the expression of VEGF and MVD using CD34 antibodies in

Priya T. Rajan,  
T. N. Suresh,  
T. S. Rajashekar<sup>1</sup>

Departments of Pathology and  
<sup>1</sup>Dermatology, Sri Devaraj Urs  
Medical College, Sri Devaraj  
Urs Academy of Higher  
Education and Research, Kolar,  
Karnataka, India

### Address for correspondence:

Dr. T. N. Suresh,  
Department of Pathology, Sri  
Devaraj Urs Medical College,  
Sri Devaraj Urs Academy of  
Higher Education and Research,  
Kolar - 563 101, Karnataka,  
India.  
E-mail: sureshstn@rediffmail.  
com

### Access this article online

Website: [www.idoj.in](http://www.idoj.in)

DOI: 10.4103/idoj.IDOJ\_147\_17

### Quick Response Code:



**How to cite this article:** Rajan PT, Suresh TN, Rajashekar TS. Expression of vascular endothelial growth factor and microvessel density in psoriatic skin lesions. Indian Dermatol Online J 2018;9:418-21.

**Received:** July, 2017. **Accepted:** March, 2018.

This is an open access journal, and articles are distributed under the terms of the Creative Commons Attribution-NonCommercial-ShareAlike 4.0 License, which allows others to remix, tweak, and build upon the work non-commercially, as long as appropriate credit is given and the new creations are licensed under the identical terms.

For reprints contact: [reprints@medknow.com](mailto:reprints@medknow.com)

psoriatic skin lesions by immunohistochemical examination and tried to correlate it with the histological grade.

## Materials and Methods

The psoriasis cases were chosen randomly from the archives of Department of Pathology from January 2007 to July 2014. 49 (men: 29; women: 20) patients who were recently diagnosed with psoriasis vulgaris between 15 and 70 years of age were recruited.

A 5-mm punch biopsy was taken from each patient of psoriasis including the full-thickness skin and subcutaneous fat. The control group included biopsies from 20 volunteers in which 10 were healthy volunteers and 10 were autopsy specimens (within 12 h of death). The control biopsies were matched with psoriatic patient specimens with respect to age group.

Each tissue sample was fixed in 10% buffered neutral formalin for 24 h and routinely processed and stained with hematoxylin–eosin. Histopathological grading was done based on Trojak's grading system for psoriatic lesions.<sup>[7]</sup>

## Immunohistochemistry

Immunohistochemistry (IHC) was performed on 4- $\mu$ m-thick section from 10% formalin-fixed paraffin-embedded tissues using a nonbiotin polymer-based horseradish peroxidase (HRP) detection system for antibodies VEGF165 (Biogenix, USA; catalogue No. AM236-5M ready to use) and CD34 (Biogenix; catalogue No. AR483-5R ready to use).

The MVD index for the quantification of angiogenesis was calculated using the method described by Behrem *et al.*<sup>[8]</sup> The slide was screened at low power magnification ( $\times 40$ ) to identify the areas with highest vascularization in papillary dermis. Number of vessels were counted in three such high-density areas at high magnification ( $\times 400$ ). Areas with dense hemorrhagic infiltrates and vessels with caliber larger than eight red blood cells were excluded from the count. Single endothelial cells or a cluster of endothelial cells positive for CD34 in membrane/cytoplasm were regarded as a distinct single countable microvessel. The values were finalized after mutual consensus was obtained between two observers and was entered as the MVD/high-power field (HPF) for each individual lesion. Immunostaining for VEGF was semiquantitatively scored using the modified scoring system protocol by Soo *et al.*<sup>[9]</sup>

Suprabasilar layers of the epidermis were assessed for VEGF expression. Cell showing granular positivity within the cytoplasm was considered positive for VEGF. The mean percentage of positive cells for the expression was determined after examining a minimum of five areas at  $\times 400$  magnification. Biopsies with less than 10% cells which were stained positive were defined as negative.

## Statistical analysis

Statistical analysis was performed using SPSS v.22.0. The demographic data were analyzed using descriptive statistics, and the VEGF and MVD values were compared using independent *t*-test. The correlation between VEGF expression by keratinocytes and MVD among cases and controls was evaluated using Pearson's correlation.  $P < 0.05$  was considered to be statistically significant.

## Results

Most of the patients in the study were in the age group of 31–40 years. The mean age of patients included in the study was  $39.67 \pm 14.94$  years. VEGF expression in the keratinocytes was found to be  $49.80\% \pm 21.16\%$  and MVD in the papillary dermis was  $15.30\% \pm 3.80\%$ . However, in the control skin samples, VEGF expression was  $3.95\% \pm 3.94\%$  and MVD was  $5.52\% \pm 1.46\%$  [Figures 1 and 2]. VEGF expression and MVD were significantly upregulated in psoriatic skin in comparison to normal healthy skin ( $P < 0.0001$ ) [Table 1]. Among the cases, a significant positive correlation was observed between VEGF expression by keratinocytes and the MVD in the papillary dermis ( $r = 0.664$ ;  $P = 0.01$ ) [Figure 3]. A positive correlation was observed between VEGF expression by keratinocytes ( $r = 0.292$ ) and MVD ( $r = 0.226$ ) with histopathological grade of psoriasis, respectively. However, the correlation was statistically insignificant ( $P > 0.05$ ).

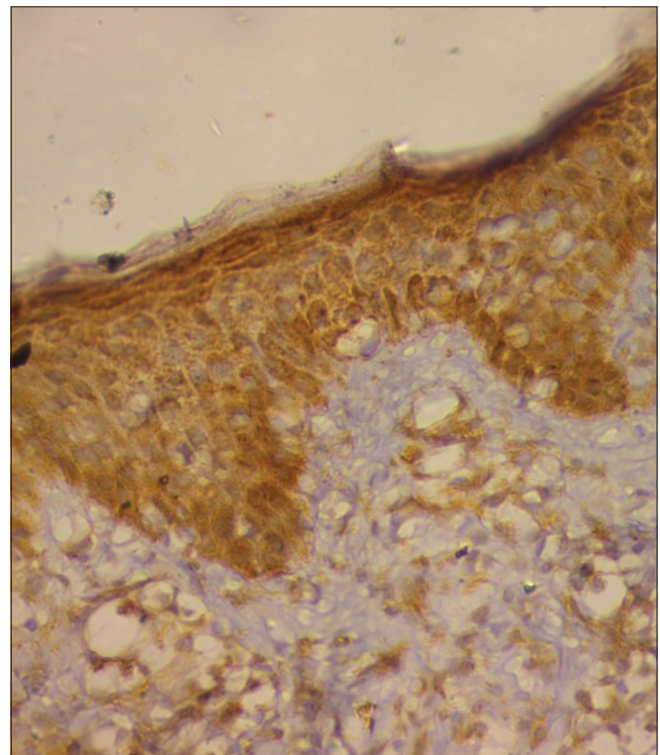


Figure 1: Strong positive expression of VEGF by keratinocytes in a lesional biopsy on immunohistochemistry ( $\times 40$ )



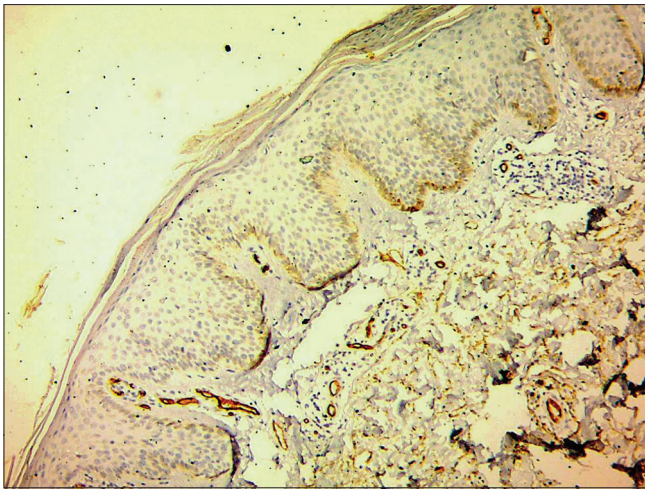


Figure 2: Microvessel density in cases of psoriasis using CD34 antibodies (x40)

**Table 1: Vascular endothelial growth factor expression by keratinocytes and microvessel density assessment in cases and control group**

	<i>n</i>	Mean±SD (%)	<i>P</i>
VEGF			
Case	49	49.80±21.16 (% of keratinocytes)	<0.0001
Control	20	3.95±3.94 (% of keratinocytes)	
MVD			
Case	49	15.30±3.80 (per HPF)	<0.0001
Control	20	5.15±1.46 (per HPF)	

SD = Standard deviation; VEGF = Vascular endothelial growth factor; MVD = Microvessel density; HPF = High power field

## Discussion

In our study, psoriasis was found to be more common in the younger age group with slight male preponderance. A study by Dogra *et al.* also found that the age group of 20–39 years has the highest incidence of psoriasis with male preponderance.<sup>[10]</sup>

In psoriasis patients, VEGF expression was significantly higher throughout the keratinocytes (49.8% ± 21.2%;  $P < 0.0001$ ) as compared to with controls (VEGF expression was mild and focal), which is comparable to the report by Salem *et al.*<sup>[11]</sup> (46.4% ± 19.7%) and Simonetti *et al.*<sup>[12]</sup> (45.60% ± 19.84%) who observed a strong VEGF expression in psoriasis throughout the epidermis. Another study revealed that mean VEGF expression in the endothelial cells of the dermis was 30.82% ± 0.65% in psoriatic skin;<sup>[13]</sup> however, a reduction was observed in VEGF expression by 81.6% at week 10 under etanercept treatment.<sup>[20]</sup> Keratinocyte cell-derived VEGF contributes to the pathogenesis of psoriasis by the induction of permeability in the dermal vessels through its angiogenic effect and chemotactic action on the inflammatory cells and endothelial cells.<sup>[14]</sup> Another study done on 40 psoriatic patients concluded that there was overexpression of VEGF

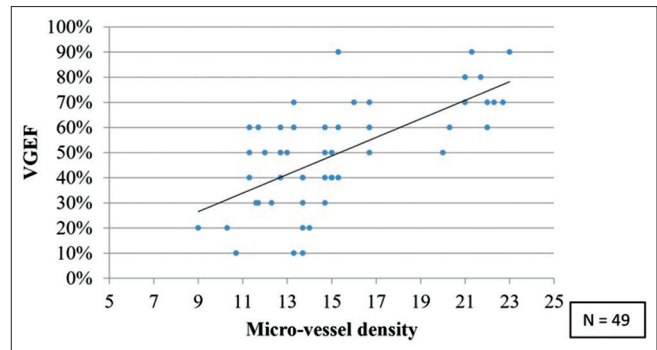


Figure 3: Scatter plot depicting the correlation between the microvessel density and vascular endothelial growth factor expression of the cases

in keratinocytes of psoriatic lesions when compared with normal skin.<sup>[15]</sup>

Psoriasis begins with angiogenesis in the superficial dermal microvasculature, dilatation of dermal papillary capillaries, tortuosity, permeability, and a prominent elongation.<sup>[16]</sup> The MVD in the psoriatic lesions in our study was significantly higher as compared to normal healthy skin ( $P < 0.0001$ ). The results were in agreement with the study conducted by Amin and Azim, in which CD34 expression was observed in lesional, nonlesional, and normal skin;<sup>[17]</sup> however, the expression in the lesional skin was significantly higher than the nonlesional skin and very weak in the normal skin. The other proangiogenic factors that are implicated in the pathogenesis of psoriasis include VEGF, hypoxia-inducible transcription factors (HIFs), angiopoietins, tumor necrosis factor (TNF), transforming growth factor (TGF)- $\alpha$ , interleukin (IL)-8, and IL-17.

In our study, we found an increased VEGF expression in psoriatic plaques, which may play an important role in the pathogenesis of the disease, vascular dilatation, increased vascular permeability, and epidermal hyperplasia. In our study, there was a positive correlation between MVD and VEGF expression in cases ( $r = 0.664$ ;  $P = 0.01$ ). Similarly, a study by Chawla *et al.* showed that overexpression of VEGF correlated well with increased MVD which indicated an increasing trend in psoriasis when compared with the psoriasiform lesions.<sup>[18]</sup>

The expression of VEGF by keratinocytes and MVD in dermis did not correlate significantly with a histopathological grade in cases of psoriasis. Psoriasis is known to be a dynamic process, both clinically and histologically. Microscopic diversity occurs among psoriatic patients with clinically similar lesions between lesions of an individual and even within single plaques. A study conducted in severe psoriasis showed that histological grade does not correlate with disease severity.<sup>[7]</sup> Thus, the role of histopathological examination in psoriasis patients is limited to confirm the diagnosis. Furthermore, it is also difficult to differentiate it from other psoriasis forms of dermatoses, which include seborrheic dermatitis,

psoriasiform drug eruption, chronic fungal infections, lichen simplex chronicus, chronic spongiotic dermatitis, secondary syphilis, pellagra, and so on.

As the sample size was small, studies with large sample sizes are required to validate the results presented in this study. In addition, further research is needed to identify newer angiogenic markers to analyze specific angiogenic pathway in psoriasis.

### Conclusion

VEGF expression is higher in psoriatic lesions compared with healthy skin. A significant positive correlation was seen between the degree of expression of VEGF by the epidermis and the MVD in the dermis. When correlated with histopathological grade of psoriasis, no significant correlation was observed with VEGF expression or MVD. Altogether, VEGF plays a significant role in the pathogenesis of psoriasis by way of its angiogenic activity in the lesions.

### Financial support and sponsorship

Nil.

### Conflicts of interest

There are no conflicts of interest.

### References

- Moorchung N, Khullar J, Mani N, Chatterjee M, Vasudevan B, Tripathi T. A study of various histopathological features and their relevance in pathogenesis of psoriasis. *Indian J Dermatol* 2013;58:294.
- Folkman J. Angiogenesis in cancer, vascular, rheumatoid and other disease. *Nat Med* 1995;1:27-30.
- Raychaudhuri SP, Jiang WY, Farber EM. Psoriatic keratinocytes express high levels of nerve growth factor. *Acta Derm Venereol* 1998;78:84-6.
- Liew S-C, Das-Gupta E, Chakravarthi S, Wong S-F, Lee N, Safdar N, *et al.* Differential expression of the angiogenesis growth factors in psoriasis vulgaris. *BMC Res Notes* 2012;5:201.
- Marina ME, Roman II, Constantin A-M, Miha CM, Tătaru AD. VEGF involvement in psoriasis. *Clujul Med* 2015;88:247.
- Miyata Y, Mitsunari K, Asai A, Takehara K, Mochizuki Y, Sakai H. Pathological significance and prognostic role of microvessel density, evaluated using CD31, CD34, and CD105 in prostate cancer patients after radical prostatectomy with neoadjuvant therapy. *Prostate* 2015;75:84-91.
- Trozak DJ. Histologic grading system for psoriasis vulgaris. *Int J Dermatol* 1994;33:380-1.
- Behrem S, Zarkovic K, Eskinja N, Jonjic N. Endoglin is a better marker than CD31 in evaluation of angiogenesis in glioblastoma. *Croat Med J* 2005;46:417-22.
- Soo R, Putti T, Tao Q, Goh B-C, Lee K-H, Kwok-Seng L, *et al.* Overexpression of cyclooxygenase-2 in nasopharyngeal carcinoma and association with epidermal growth factor receptor expression. *Arch Otolaryngol Head Neck Surg* 2005;131:147-52.
- Dogra S, Mahajan RJ. Psoriasis: Epidemiology, clinical features, co-morbidities, and clinical scoring. *Indian Dermatol Online J* 2016;7:471.
- Salem A, Nasar A, Kandil A, Farag R, El-Kasheshy K. Role of vascular endothelial growth factor, survivin, and inducible nitric oxide synthase expression in psoriasis: An immunohistochemical study. *Egypt J Dermatol Venerol* 2014;34:21.
- Simonetti O, Lucarini G, Campanati A, Goteri G, Zizzi A, Marconi B, *et al.* VEGF, survivin and NOS overexpression in psoriatic skin: Critical role of nitric oxide synthases. *J Dermatol Sci* 2009;54:205-8.
- Avramidis G, Krüger-Krasagakis S, Krasagakis K, Fragiadaki I, Kokolakis G, Tosca A. The role of endothelial cell apoptosis in the effect of etanercept in psoriasis. *Br J Dermatol* 2010;163:928-34.
- Detmar M, Brown LF, Schön MP, Elicker BM, Velasco P, Richard L, *et al.* Increased microvascular density and enhanced leukocyte rolling and adhesion in the skin of VEGF transgenic mice. *J Invest Dermatol* 1998;111:1-6.
- Beek C, Van Reede E. The nature and frequency of the histological changes found in psoriasis vulgaris. *Arch Dermatol Res* 1977;257:255-64.
- Heidenreich R, Röcken M, Ghoreschi K. Angiogenesis drives psoriasis pathogenesis. *Int J Clin Exp Pathol* 2009;90:232-48.
- Amin MM, Azim ZA. Immunohistochemical study of osteopontin, Ki-67, and CD34 of psoriasis in Mansoura, Egypt. *Indian J Pathol Microbiol* 2012;55:56.
- Chawla N, Kataria SP, Aggarwal K, Chauhan P, Kumar D. Significance of vascular endothelial growth factor and CD31 and morphometric analysis of microvessel density by CD31 receptor expression as an adjuvant tool in diagnosis of psoriatic lesions of skin. *Indian J Pathol Microbiol* 2017;60:189.