



# Long-Delayed Manifestation of COVID-19 Coagulopathy Presenting with Severe Cerebral Venous Thrombosis Causes Massive Brain Hemorrhage

Mardjono Tjahjadi<sup>1,2</sup> Sinatrya Caropeboka<sup>2</sup> Christian Permana<sup>2</sup> Krisandi Susanto<sup>2</sup> Eka Susanto<sup>3</sup>

<sup>1</sup>Department of Surgery, Faculty of Medicine, Universitas Katolik Indonesia Atma Jaya, Jakarta, Indonesia

<sup>2</sup>Department of Neurosurgery, Mitra Keluarga Kemayoran Hospital, Jakarta, Indonesia

<sup>3</sup>Department of Anatomical Pathology, Faculty of Medicine, Universitas Indonesia, Jakarta, Indonesia

Address for correspondence Mardjono Tjahjadi, MD, PhD, Department of Surgery, Faculty of Medicine, Universitas Katolik Indonesia Atma Jaya, Jakarta 14440, Indonesia (e-mail: mardjonotjahjadi@gmail.com).

AJNS 2022;17:342–346.

## Abstract

COVID-19 infection causes coagulopathy, which may lead to cerebral venous thrombotic (CVT) event. It usually occurs in patients with higher severity level of infection and manifests mostly within a month after the infection. However, in rare cases, the CVT may happen long after the infection and unrelated to the degree of the infection severity. We present the case of a previously healthy 62-year-old male patient with very mild COVID-19 symptoms that resolved in 3 weeks of home isolation treatment. Immediately after the infection, he developed hypercoagulability and was treated routinely with a novel oral anti-coagulant drug. Four months after the infection, he developed a worsening headache which, in several days, deteriorated to cause reduction in his consciousness level. Imaging showed a right temporoparietooccipital massive brain hemorrhage with right transverse and sigmoid sinus thrombosis. Emergency decompressive craniectomy was performed and the patient recovery was excellent. In patients with a hypercoagulable state after COVID-19 infection, the possibility of CVT event should be observed. It may not be related to the severity of the infection, and it may happen long after the infection.

## Keywords

- ▶ cerebral venous thrombosis
- ▶ COVID-19
- ▶ long covid
- ▶ decompressive craniectomy

## Introduction

Venous thrombosis induced by COVID-19 is increasingly reported in the literature with prevalence ranging from 16 to 40%. Most cases are related to the severity level of the infection and eventually lead to worse outcome of the disease.<sup>1–3</sup> This thrombosis complication usually occurs in

the later stage of the disease and mostly manifests as deep vein thrombosis and pulmonary embolism.<sup>2,3</sup> The incidence of cerebral venous thrombosis (CVT) is somewhat rarer than the other venous thrombosis manifestations, estimated approximately 0.5% of all venous thrombotic events in COVID-19.<sup>4</sup> But comparing with the general population,

DOI <https://doi.org/10.1055/s-0042-1750388>.  
ISSN 2248-9614.

© 2022. Asian Congress of Neurological Surgeons. All rights reserved.

This is an open access article published by Thieme under the terms of the Creative Commons Attribution-NonDerivative-NonCommercial-License, permitting copying and reproduction so long as the original work is given appropriate credit. Contents may not be used for commercial purposes, or adapted, remixed, transformed or built upon. (<https://creativecommons.org/licenses/by-nc-nd/4.0/>)

Thieme Medical and Scientific Publishers Pvt. Ltd., A-12, 2nd Floor, Sector 2, Noida-201301 UP, India

the incidence of CVT in COVID-19 patient is higher, estimated approximately 4.5/100,000 versus to 1.6/100,000 people in the general population.<sup>5,6</sup>

Most CVT cases in COVID-19 occurred within 1 month of the infection and carry a high mortality rate, especially the one with brain hemorrhage.<sup>6-10</sup> In the present study, we report an uncommon case of long-delayed CVT due to prolonged coagulopathy in a previously healthy individual with mild symptomatic COVID-19. The CVT manifest in severe brain hemorrhage, which can be successfully treated with decompression craniectomy and anti-thrombotic medications.

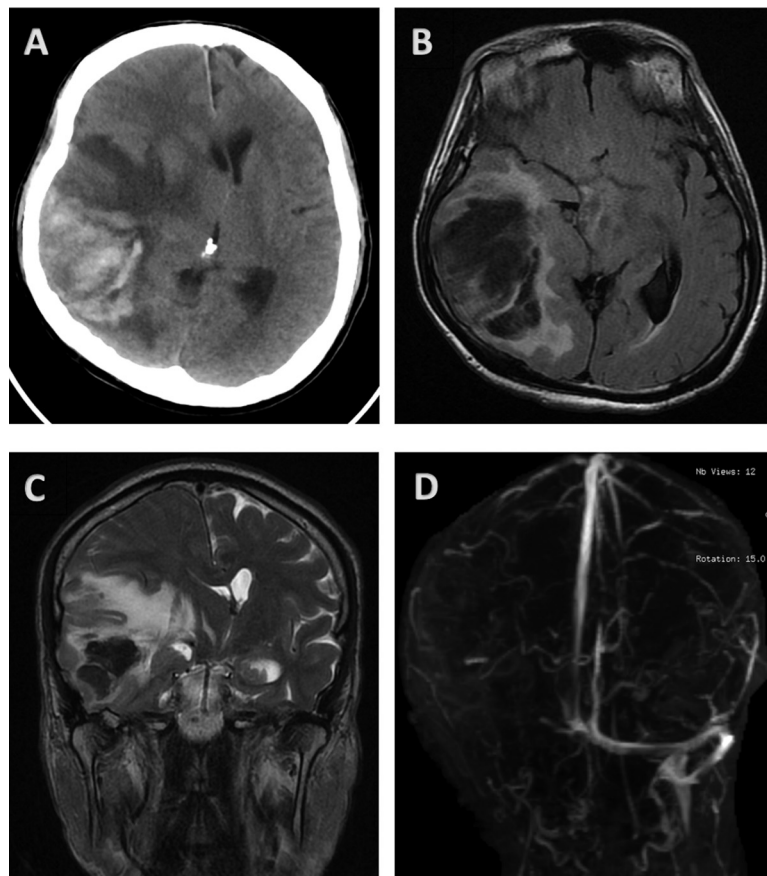
## Case Report

Four months earlier, a previously healthy 62-year-old developed mild sore throat with no fever. He was then swabbed due to contact tracing of one of his coworkers who was confirmed positive for COVID-19. His COVID-19 PCR swab test returned positive, and due to his very mild COVID-19 symptoms, he was treated with home isolation protocol. During isolation period, he did not experience any additional symptoms nor worsening of his existing symptoms. Two weeks afterward, he had very well recovery and two times PCR tests confirmed negative result. However, his laboratory finding at that time showed an increment of D-dimer level to

1,289 ng/mL, which has not been shown previously. A novel oral anti-coagulant drug, edoxaban 30 mg, was prescribed once daily and the D-dimer was routinely checked on weekly basis. During follow-up, the D-dimer level ranged from 367 to 911 ng/mL and the edoxaban dose was adjusted by his primary physician accordingly and he was recommended to have aggressive hydration. In his past medical history, no specific medical condition especially related to any pro-thrombotic, malignancy, or other vascular risk factors were recorded.

For 5 days prior to the incidence, the patient had started complaining mild-to-moderate headache, which worsened gradually until he became unconscious 2 hours before he presented to us. His blood test results showed increased D-dimer levels to 2,880 ng/mL, otherwise within normal limit. Initial examination in the emergency room found reduced consciousness level of Glasgow Coma Score (GCS) of 12 (E3M5V4) with left hemiparesis and motor power score of 3 (able to resist gravity), pupil was 3 mm symmetrical, and responsive well to light stimuli. Blood pressure was 180/100 mm Hg, heart rate was 100 bpm, dan respiratory rate was 20 ×/min; temperature was 36.5°C. Repeated COVID-19 PCR swab showed negative result.

Emergency head CT scan resulted in severe brain edema with hemorrhagic transformation on the right



**Fig. 1** (A) CT Scan and (B) T2 Flair MRI: Cerebral imaging showing large inhomogeneous hemorrhagic lesion with malignant edema at right parietotemporooccipital region leading to subfacine and transtentorial brain herniation. (C) An axial T2 Flair imaging shows absence of abnormal flow void at right transverse and sigmoid sinus. (D) Coronal MIP image time-of-flight venography shows loss of signal at right transverse and sigmoid sinus.

temporoparietooccipital with 1.5 cm midline shifting and deviation of the brainstem (►Fig. 1A). Brain MRI, MRA, and MRV were then performed to rule out any other causes such as vascular malformation or brain tumor bleeding. Brain MRI confirmed a large brain hemorrhagic with malignant edema (►Fig. 1B). MRA showed normal brain vasculature without any occlusion or malformation. However, in the MRV, we found nonvisualization of right-side transverse and sigmoid sinuses and major veins anastomosis, which indicated a massive cerebral venous thrombosis at the right side (►Fig. 1C, D). A moment later, the patient's condition deteriorating to GCS score of 9 (E2M5V2). He was recommended to get emergency decompressive craniectomy. Intra-operative finding demonstrating a massive brain thrombosis with diffuse hemorrhagic (►Fig. 2A). Surgery was done successfully and some brain specimen was taken and sent to the pathology department for further study.

Immediately after the surgery, patient's consciousness improved to fully alert with GCS 15 while the left side weakness was slowly recovered within several days.

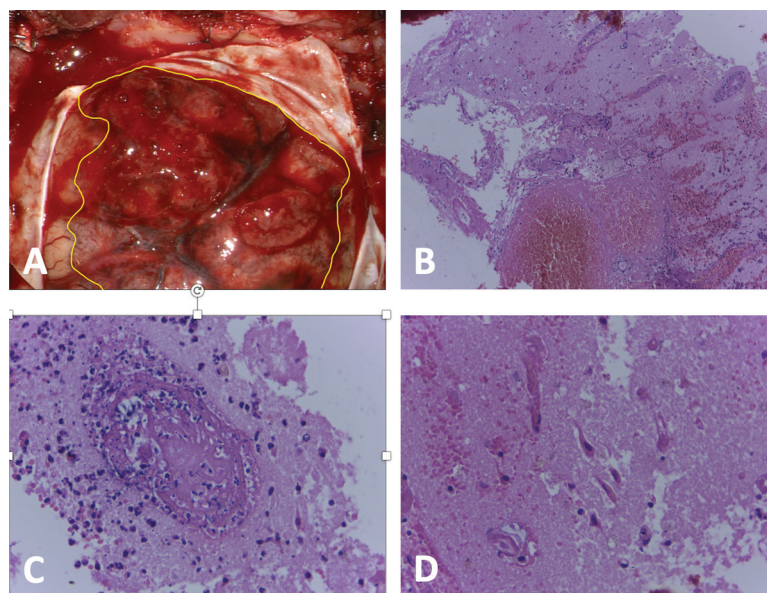
Brain biopsy showed severe diffuse thrombosis feature supporting the MRI and intra-operative finding, which suggested severe venous thrombosis (►Fig. 2B–D) His blood test result once again showed normal findings, but the D-dimer level was still high on 2,890 ng/mL.

## Discussion

In COVID-19 patients, the exact mechanism triggers the thromboembolic event is not fully understood; however, there are several postulates. The first is through the severe immune response, that is, the “cytokine storm” that releases the pro-inflammatory cytokines, which are believed to be involved in the abnormal clot formation and

hyperactive platelet aggregation. Second is the downregulation of angiotensin-converting enzyme 2 (ACE2), which leads to a high expression of angiotensin 2 (Ang2). The increasing Ang2 levels could promote vasoconstriction and increase the expression of tissue factor, which induces thrombosis.<sup>11,12</sup> Third, viral infection may induce endothelial cells dysfunction which in turn causes excess thrombin generation and prevents fibrinolysis.<sup>13</sup> Fourth, hypoxemia may elevate blood viscosity and activate some specific genes to generate thrombotic events.<sup>14</sup> Other mechanisms of thrombotic events may relate to advance age, male gender, hypertension, immobilization, sepsis dehydration, and central venous catheter.<sup>7,15</sup>

Along with the previous proposed mechanisms, CVT as in other thromboembolic events occurred following Virchow's triad which consists of venous stasis, activation of blood coagulation, and vessel wall damage. Some other factors such as thrombophilia, antiphospholipid antibodies, female gender, pregnancy, oral contraceptive, hormone replacement therapy, and mechanical head injury may also contribute to the development of CVT.<sup>16,17</sup> CVT in general population manifests as headache in 90% of patients, seizure in 40%, intra-parenchymal hemorrhage and ischemic stroke in 31% and 14%, respectively.<sup>18</sup> Other symptoms such as visual disturbances, encephalopathy, and focal neurological signs were also reported in smaller proportion.<sup>19</sup> The clinical manifestations of CVT in COVID-19 patient are rather different, headache only occurred in 31%, others are altered sensorium (38.5%), reduced consciousness (31%), and intracranial bleeding (61.5%). Another unique point of CVT in COVID-19 is the age of patients, which in the COVID-19 group the mean age was above 50 years old, while in the general population, the mean age was 36 years old. Cortical veins involvement was



**Fig. 2** (A) Macroscopic appearance of hemorrhagic cerebral venous thrombosis on right temporoparietal area (inside the yellow line area). (B) Histopathological H&E staining with 100x magnification demonstrating brain parenchyma with diffuse hemorrhage and thrombosis. (C) Histopathological H&E staining with 400x magnification demonstrating diffuse brain thrombosis with neutrophil infiltration. (D) Histopathological H&E staining with 400x magnification demonstrating ischemic and degenerative neurons.

also more frequent in COVID-19 patients than in the general population.<sup>6</sup>

Diagnosis of CVT, as in other venous thromboembolic events, were made based on clinical finding, imaging, and blood tests result; several laboratory parameters, such as C-reactive protein, fibrinogen level, prothrombin time, platelet count, lipid dehydrogenase, IL-6, and serum ferritin, have been known to predict the development of thrombosis. However, the most important laboratory test indicating the risk of thrombosis is the change in D-dimer level, which in the acute phase may be confused with other causes such as inflammation. The steady increase in D-dimer level may demonstrate the possibility of thrombosis.<sup>15</sup> Less-invasive radiological examination such as CTV or MRV in most cases are enough to make the CVT diagnosis, even though brain DSA is still the gold standard. However, in the COVID-19 setting, these less-invasive tests are more efficient than performing DSA. The common locations of thrombosis are multiple sinus involvement, followed by the lateral sinus, and superior sagittal sinus. Interesting finding in COVID-19's CVT—the involvement of cortical veins is significantly higher than in general CVT (38.5% vs. 10%).<sup>20</sup>

Treatment of CVT includes treatment of underlying cause, symptomatic therapy, and anti-thrombotic therapy. Unfractionated heparin or low molecular weight heparin are recommended in the acute-subacute phase, but for long-term medication, oral warfarin or novel oral anticoagulants such as factor Xa inhibitor (apixaban, edoxaban, and rivaroxaban) and direct thrombin inhibitor (dabigatran) may control the thrombosis.<sup>21,22</sup> Emergency decompressive craniectomy is recommended if there is massive brain hemorrhage or edema with mass effect.

Regarding the association of the CVT with the severity of illness, it seems that the majority of the patients develop CVT were in mild-to-moderate illness. One recent systematic review demonstrated 36, 28, and 36% were in mild, moderate, and critical illness.<sup>6</sup> Another multinational case series also reported 10 of 13 (77%) patients developed CVT were in mild-moderate respiratory symptoms. Mortality rate of CVT in COVID-19 patients was reported between 23 and 45%, with amongst mild symptomatic COVID-19 subgroup the mortality rate is approximately 40%.<sup>6,9,10,20</sup>

The incidence of pro-thrombotic complication in the COVID-19 post-acute phase has been widely known, as the majority of thromboembolic events were reported within 30 days after discharge.<sup>6–8</sup> In our case, the CVT manifest as severe brain hemorrhagic occur 4 months after COVID infection in a previously healthy man, and he was treated with an anti-thrombotic under strict monitoring of his primary physician. This report may support the not-yet understood long-term COVID effect, especially in coagulopathy complication.

A long-delayed severe CVT (more than 4 months) after COVID-19 infection is considered rare, especially in the previously mild infection case. This finding may improve our understanding of the nature of COVID antibody reaction mechanism to develop thrombosis, specifically in the cerebral venous system.

## Conclusion

Our case report supports the evidence that hypercoagulable complication caused by COVID-19 may occur long after the infection and not solely come from the severe-critical patients' subgroup but may also from the mild symptomatic subgroup. In severe cerebral venous thrombosis with hemorrhagic transformation, early decision to do decompressive craniectomy will benefit the patient.

### Conflict of Interest

None declared.

## References

- Di Minno A, Ambrosino P, Calcaterra I, Di Minno MND. COVID-19 and venous thromboembolism: a meta-analysis of literature studies. *Semin Thromb Hemost* 2020;46(07):763–771
- Klok FA, Kruip MJHA, van der Meer NJM, et al. Incidence of thrombotic complications in critically ill ICU patients with COVID-19. *Thromb Res* 2020;191:145–147
- Middeldorp S, Coppens M, van Haaps TF, et al. Incidence of venous thromboembolism in hospitalized patients with COVID-19. *J Thromb Haemost* 2020;18(08):1995–2002
- Romoli M, Jelcic I, Bernard-Valnet R, et al; Infectious Disease Panel of the European Academy of Neurology A systematic review of neurological manifestations of SARS-CoV-2 infection: the devil is hidden in the details. *Eur J Neurol* 2020;27(09):1712–1726
- Devasagayam S, Wyatt B, Leyden J, Kleinig T. Cerebral venous sinus thrombosis incidence is higher than previously thought: a retrospective population-based study. *Stroke* 2016;47(09):2180–2182
- Tu TM, Goh C, Tan YK, et al. Cerebral venous thrombosis in patients with COVID-19 infection: a case series and systematic review. *J Stroke Cerebrovasc Dis* 2020;29(12):105379
- Baldini T, Asioli GM, Romoli M, et al. Cerebral venous thrombosis and severe acute respiratory syndrome coronavirus-2 infection: a systematic review and meta-analysis. *Eur J Neurol* 2021;28(10):3478–3490
- Cavalcanti DD, Raz E, Shapiro M, et al. Cerebral venous thrombosis associated with COVID-19. *Am J Neuroradiol* 2020;41(08):1370–1376
- Nwajei F, Anand P, Abdalkader M, et al. Cerebral venous sinus thromboses in patients with SARS-CoV-2 infection: three cases and a review of the literature. *J Stroke Cerebrovasc Dis* 2020;29(12):105412
- Ostovan VR, Foroughi R, Rostami M, et al. Cerebral venous sinus thrombosis associated with COVID-19: a case series and literature review. *J Neurol* 2021;268(10):3549–3560
- Celi A, Cianchetti S, Dell'Omo G, Pedrinelli R. Angiotensin II, tissue factor and the thrombotic paradox of hypertension. *Expert Rev Cardiovasc Ther* 2010;8(12):1723–1729
- Forrester SJ, Booz GW, Sigmund CD, et al. Angiotensin II signal transduction: an update on mechanisms of physiology and pathophysiology. *Physiol Rev* 2018;98(03):1627–1738
- Goeijenbier M, van Wissen M, van de Weg C, et al. Review: viral infections and mechanisms of thrombosis and bleeding. *J Med Virol* 2012;84(10):1680–1696
- Gupta N, Zhao YY, Evans CE. The stimulation of thrombosis by hypoxia. *Thromb Res* 2019;181:77–83
- Miesbach W, Makris M. COVID-19: coagulopathy, risk of thrombosis, and the rationale for anticoagulation. *Clin Appl Thromb Hemost* 2020;26:1076029620938149
- Coutinho JM, Zuurbier SM, Aramideh M, Stam J. The incidence of cerebral venous thrombosis: a cross-sectional study. *Stroke* 2012;43(12):3375–3377

- 17 Silvis SM, de Sousa DA, Ferro JM, Coutinho JM. Cerebral venous thrombosis. *Nat Rev Neurol* 2017;13(09):555–565
- 18 Gulati D, Strbian D, Sundararajan S. Cerebral venous thrombosis: diagnosis and management. *Stroke* 2014;45(02):e16–e18
- 19 Medicherla CB, Pauley RA, de Havenon A, Yaghi S, Ishida K, Torres JL. Cerebral venous sinus thrombosis in the COVID-19 pandemic. *J Neuroophthalmol* 2020;40(04):457–462
- 20 Mowla A, Shakibajahromi B, Shahjouei S, et al. Cerebral venous sinus thrombosis associated with SARS-CoV-2; a multinational case series. *J Neurol Sci* 2020;419:117183
- 21 Field TS, Hill MD. Cerebral venous thrombosis. *Stroke* 2019;50(06):1598–1604
- 22 Wasay M, Khan M, Rajput HM, et al. New oral anticoagulants versus warfarin for cerebral venous thrombosis: a multi-center, observational study. *J Stroke* 2019;21(02):220–223