

Cite this article as: Kocyigit M, Gullu AU, Senay S, Alhan C. Robotic-assisted beating heart surgery provides precise repair of periprosthetic mitral valvular leak. *Interact CardioVasc Thorac Surg* 2022; doi:10.1093/icvts/ivac071.

# Robotic-assisted beating heart surgery provides precise repair of periprosthetic mitral valvular leak

Muharrem Kocyigit, Ahmet Umit Gullu \*, Sahin Senay and Cem Alhan

Department of Cardiovascular Surgery, Acibadem Mehmet Ali Aydınlar University School of Medicine, Istanbul, Turkey

\* Corresponding author. Acibadem Maslak Hospital, Büyükdere Cad. No 41, Sarıyer, Istanbul 34452, Turkey. Tel: +90-505-501-38-44; e-mail: aumitgullu@yahoo.com (A.U. Gullu).

Received 4 August 2021; received in revised form 12 November 2021; accepted 11 April 2022

## Abstract

The prosthetic paravalvular leak is a rare but important complication following mitral valve replacement. Determining the location of the leak is almost always dependent on perioperative transoesophageal echocardiography and the considerable expertise of echo operators. Acoustic shadowing due to the prosthetic valve may create another important difficulty. In this report, we present a case with a paravalvular leak diagnosed 1 year after mitral valve replacement. Beating heart surgery and robotic 3D/high-resolution camera provided to localize the direct location of leak coherent with perioperative echocardiography and precise repair. The robotic approach prevented the potential complications of aortic cross-clamp and re-sternotomy.

**Keywords:** Minimal invasive surgery • Robotic surgery • Mitral valve replacement

## INTRODUCTION

The paravalvular leak is one of the most important complications of mitral valve replacement surgery with a prevalence of 2–13% [1, 2]. Severe leakage, major haemolysis and infective endocarditis are factors for reintervention. It is highly important for the surgeon to know the location of the periprosthetic valvular leak before the surgery for a secure repair and suturing of an unsuitable location based on echocardiographic misinformation may cause the leakage to continue. However, understanding the location of the leak almost depends on the perioperative echocardiographic examination and observation at an arrested heart with an empty left ventricle.

In this report, a patient with a leaking periprosthetic mitral valve is presented. He underwent repair on beating heart with excellent exposure of surgical field via 3D robotic technology, which made repair more secure.

## CASE REPORT

An 83-year-old man was admitted to our hospital with exertional dyspnoea. He had a history of mechanical mitral valve replacement, coronary artery bypass grafting and a pacemaker implantation a year ago in another institution. Transthoracic echocardiography showed severe mitral paraprosthetic valvular leakage, tricuspid valve regurgitation, mild aortic regurgitation and huge left atrium

(94 mm). There was no abnormality in left ventricular wall motion with a 60% of ejection fraction. Robot-assisted prosthetic mitral valve repair and tricuspid valve intervention were planned.

Double-lumen endotracheal tube and TEE probe were inserted. 3D images of TEE showed paraprosthetic mitral valve leakage at the 2 points using a clock-wise format in surgical view: 1 major leak at 7 o'clock and 1 jet flow at 9 o'clock side. Leak produced an eccentric jet through the left atrium wall with a Coanda effect (Video 1).

Venous cannulation was achieved by the right internal jugular and femoral vein and then arterial cannulation was performed via the femoral artery under the TEE guidance. A 3-cm incision was made between the anterior axillary and midclavicular line at the 4th intercostal space, and then right and left arm ports were placed through intercostal spaces (Fig. 1). The robotic arms were docked (da Vinci<sup>®</sup> Xi HD Intuitive Surgical, USA) and after achieving the ACT >450 s, the cardiopulmonary bypass (CPB) was started. The operation was continued without aortic cross-clamping and arresting the heart. The paravalvular leak locations were consistent with TEE and visualized clearly after the atriotomy (Video 1). The prosthetic valve leaflets were in normal function. The leakages were sutured with interrupted pledget sutures. The atriotomies were closed following the placement of a ring to the tricuspid valve annulus. Continuous carbon dioxide (5 l/min) and 2 suction catheters were used to prevent air embolism and both catheters were kept in place until the end of CPB and until no air is visible in TEE.

After weaning from the CPB, TEE showed no mitral paravalvular leak and tricuspid regurgitation. The operation was continued and terminated in a similar fashion. The postoperative period was uneventful and the patient was discharged from the hospital by the 10th postoperative day. The patient is still in a good clinical condition, at a routine follow-up and echocardiographical examinations for 2 years.

## DISCUSSION

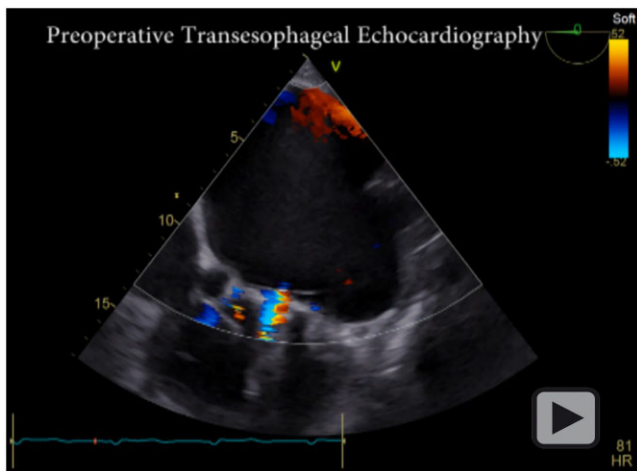
Although great advances have been made in cardiac imaging technologies, which have improved the perioperative examination, considerable expertise with echocardiography is necessary to obtain adequate information regarding the exact site of mitral valve pathology. This is especially important to localize the exact point of a

periprosthetic valvular leak. Acoustic shadowing due to the prosthetic valve may create an important difficulty. In a study of Foster et al. [2], there was a disagreement between the findings of preoperative TEE and operation in 8 (12%) of the 66 sections examined; the main cause was the localization of a leak to adjacent sections of the prosthetic sewing ring. Furthermore, in 1 case, a perivalvular leak was noted on the preoperative TEE study and however could not be identified by the surgeon intraoperatively and persisted on the postoperative follow-up. This last case shows the challenge of surgeons in trying to assess mitral defects in a nonphysiological state when the left ventricle is decompressed at an arrested heart.

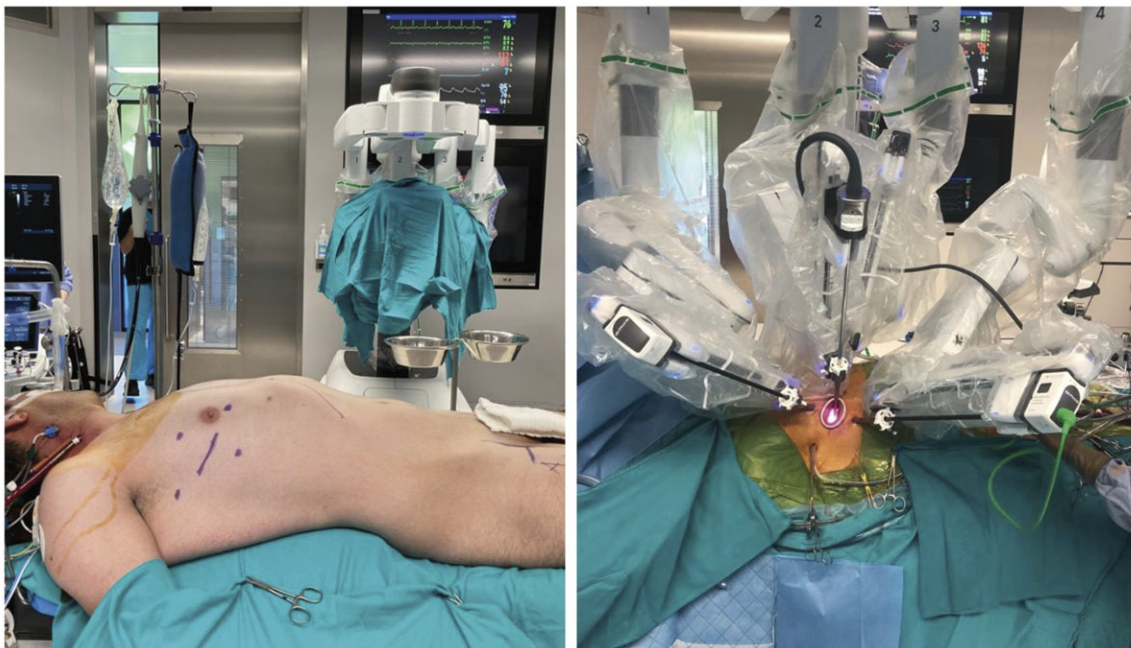
The use of 3D/HD camera, which has magnifying technology along with the beating heart technique, may help to show the true location of the leak and precisely close the defect. Beating heart technique may prevent potential complications of aortic cross-clamping such as cerebral thromboemboli. Moreover, although the defect can be observed via sternotomy/beating heart technique, the lateral approach may avoid the complications of repeat sternotomy including catastrophic re-entry into the heart and massive bleeding or injury to previous bypass grafts if exist.

Air embolism is one of the major concerns and deairing is an essential part of beating heart mitral valve surgery. For this purpose, carbon dioxide was insufflated during the procedure and vacuum assist venous cannulas were used. Two suction catheters were placed, one of them being kept in the left atrium and the other in the left ventricle via mitral valve. Moreover, these catheters provided a good exposure at the bloody surgical field and in fact, mild aortic regurgitation might have an effect to prevent air embolism [3, 4].

The operative mortality for redo valvular surgery is higher than the initial one and stands at ~14% across of all patients [1]. This makes transcatheter closure an attractive option; however, it is limited by the off-label usages, finite choice of devices and operator experience, challenging anatomy with different kinds and shapes, and challenges posed by very large defects. An unsuccessful intervention will risk and worsen the functioning of the prosthetic valve. In a recent study, closure with transcatheter was



**Video 1:** Echocardiographical and operational images of paravalvular leakage during repair.



**Figure 1:** Operational set-up during robotic-assisted mitral valve operations.

unsuccessful in 19.2% of 26 patients. Haemolysis worsened in 3 patients despite successful closure; all required further valvular surgery and 2 died [5]. We did not prefer this approach related to the existence of 2 different defects at paravalvular locations and complicated repair techniques may prolong the operational time, which may increase the risk of failure.

In conclusion, repairing the prosthetic mitral paravalvular leak at the beating heart with robotic assistance is feasible and avoids sternal re-entry. Robotic endoscope along with beating heart provides enhanced view, visibility of the leak and finally precisely repair.

### Reviewer information

Interactive CardioVascular and Thoracic Surgery thanks Johannes Bonatti, Husam Balkhy, Stepan Cerny and the other, anonymous reviewer(s) for their contribution to the peer review process of this article.

**Conflict of interest:** none declared.

### REFERENCES

- [1] Sivakumar K. Transcatheter closure of paravalvular leaks - how do I do it? *Indian Heart J* 2013;65:289–94.
- [2] Foster GP, Isselbacher EM, Rose GA, Torchiana DF, Akins CW, Picard MH. Accurate localization of mitral regurgitant defects using multi-plane transesophageal echocardiography. *Ann Thorac Surg* 1998;65:1025–31.
- [3] Senay S, Gullu AU, Alhan C. Robotic mitral valve replacement for rheumatic mitral disease. *Ann Cardiothorac Surg* 2017;6:64–6.
- [4] Güllü AÜ, Şenay Ş, Ersin E, Demirhisar Ö, Whitham T, Koçyiğit M *et al.* Robotic-assisted cardiac surgery without aortic cross-clamping: a safe alternative approach. *J Card Surg* 2021;36:165–8.
- [5] Galrinho A, Branco LM, Fiarresga A, Cacula D, Sousa L, Ramos R *et al.* Paravalvular leak closure: still a challenge with unpredictable results. *Rev Port Cardiol (Engl Ed)* 2021;40:261–9.