

Surgical Management of Proximal Fifth Metatarsal Fractures in Elite Athletes

A Systematic Review

J. Brett Goodloe,^{*†} MD, William M. Cregar,[‡] MD, Alexander Caughman,[†] BS, Evan P. Bailey,[†] BS, William R. Barfield,[†] PhD, and Christopher E. Gross,[†] MD

Investigation performed at the Medical University of South Carolina, Charleston, South Carolina, USA

Background: As a result of the high physical demand in sport, elite athletes are particularly prone to fifth metatarsal fractures. These injuries are typically managed surgically to avoid high rates of delayed union and allow for quicker return to play (RTP).

Purpose: To review studies showing clinical and radiographic outcomes, RTP rates, and complication rates after different surgical treatment modalities for fifth metatarsal fractures exclusively in elite-level athletes.

Study Design: Systematic review; Level of evidence, 4.

Methods: A systematic search was conducted within the PubMed, Scopus, and Cochrane databases from January 2000 to January 2020. Inclusion criteria consisted of clinical outcome studies after operative management of fifth metatarsal fractures in elite athletes. Exclusion criteria consisted of nonoperative management, high school or recreational-level athletic participation, nonclinical studies, expert opinions, and case series with <5 patients.

Results: A total of 12 studies met inclusion and exclusion criteria, comprising 280 fifth metatarsal fractures treated surgically. Intramedullary screw fixation was the most common fixation construct (47.9%), and some form of intraoperative adjunctive treatment (calcaneal autograft, iliac crest bone graft, bone marrow aspirate concentrate, demineralized bone matrix) was used in 67% of cases. Radiographic union was achieved in 96.7% of fractures regardless of surgical construct used. The overall mean time to union was 9.19 weeks, with RTP at a mean of 11.15 weeks. The overall reported complication rate was 22.5%, with varying severity of complications. Refracture rates were comparable between the different surgical constructs used, and the overall refracture rate was 8.6%.

Conclusion: Elite athletes appeared to have a high rate of union and reliably returned to the same level of competition after surgical management of fifth metatarsal fractures, irrespective of surgical construct used. Despite this, the overall complication rate was >20%. Specific recommendations for optimal surgical management could not be made based on the heterogeneity of the included studies.

Keywords: fifth metatarsal; athletes; return to play; Jones fracture; sport

Although the Jones fracture is the most commonly publicized fracture of the fifth metatarsal, the entire bone endures excessive loads during sport.^{14,33,42} Acceleration maneuvers and the cumulative effect of bending moments applied to the fifth metatarsal during sport make it particularly vulnerable to injury.^{1,13,33} Fifth metatarsal fractures can result in significant disability and can prevent athletic participation.^{4,21} The tenuous vascular supply to the fifth metatarsal, specifically at the metadiaphyseal junction, makes these fractures susceptible to delayed healing and nonunion, which can also prolong return to sport.^{5,6,37}

Several classification systems are used to describe fractures of the fifth metatarsal. Sir Robert Jones first described the “Jones fracture” in a small case series of 4 patients, including himself, as fractures at the metadiaphyseal junction.¹⁹ The Lawrence and Botte²³ classification system is commonly used and holds prognostic value based on fracture zonal distributions. Finally, Torg et al⁴⁴ described a classification scheme based on radiographic appearance as it pertains to fracture acuity.

In elite-level athletes, fifth metatarsal fractures at the metadiaphyseal region are often managed surgically to avoid high rates of delayed union or nonunion and allow for quicker return to play (RTP).^{5,20,24,35,39} Intramedullary screw fixation is considered the gold standard; however, many different modes of fixation exist. Additionally,

The Orthopaedic Journal of Sports Medicine, 9(9), 23259671211037647

DOI: 10.1177/23259671211037647

© The Author(s) 2021

This open-access article is published and distributed under the Creative Commons Attribution - NonCommercial - No Derivatives License (<https://creativecommons.org/licenses/by-nc-nd/4.0/>), which permits the noncommercial use, distribution, and reproduction of the article in any medium, provided the original author and source are credited. You may not alter, transform, or build upon this article without the permission of the Author(s). For article reuse guidelines, please visit SAGE’s website at <http://www.sagepub.com/journals-permissions>.

augmentation with bone grafting or modern orthobiologics is commonly used to further enhance healing.^{9,16,18-22} Despite good outcomes with surgical management, several potential complications exist, including refracture, non-union, sural nerve injury, infection, failed fixation, complex regional pain syndrome, and the inability to return to the same level of play.^{10,12,22,39,47}

Numerous review articles have evaluated nonoperative versus operative management of proximal fifth metatarsal fractures in the general population.^{7,39,48} Despite the overwhelming recommendation of surgical management of fifth metatarsal fractures in the athletic population, to our knowledge, no reviews exist that specifically evaluate the current literature as it pertains to operative management of fifth metatarsal fractures solely in elite-level athletes. This systematic review aimed to evaluate outcomes, rates of RTP, and complications after varying surgical treatment modalities for fifth metatarsal fractures in elite athletes.

METHODS

Literature Search

A study protocol was developed and registered with the International Prospective Register of Systematic Reviews (PROSPERO, ID Number: CRD42020164648). A systematic search of the current literature was conducted within the PubMed, Scopus, and Cochrane databases using the standardized reporting of systematic reviews by the PRISMA (Preferred Reporting Items for Systematic Reviews and Meta-Analyses) guidelines.³¹ The databases were searched from January 2000 to January 17, 2020. To identify potentially missed articles, the reference lists of all included articles were hand searched; however, no additional studies were identified.

Eligibility Criteria

All articles pertaining to fifth metatarsal fractures published between January 2000 and January 17, 2020, were eligible for inclusion. Inclusion criteria were as follows: (1) surgical management of fifth metatarsal fractures; (2) elite-level athletes evaluated (defined as collegiate, Olympic, or professional level); (3) clinical or radiographic outcomes reported. Exclusion criteria consisted of nonclinical studies, expert opinions (level 5 studies), case series with <3 patients studies that entailed fifth metatarsal base avulsion fractures, high school or recreational-level athletic participation, and studies that included only nonoperative

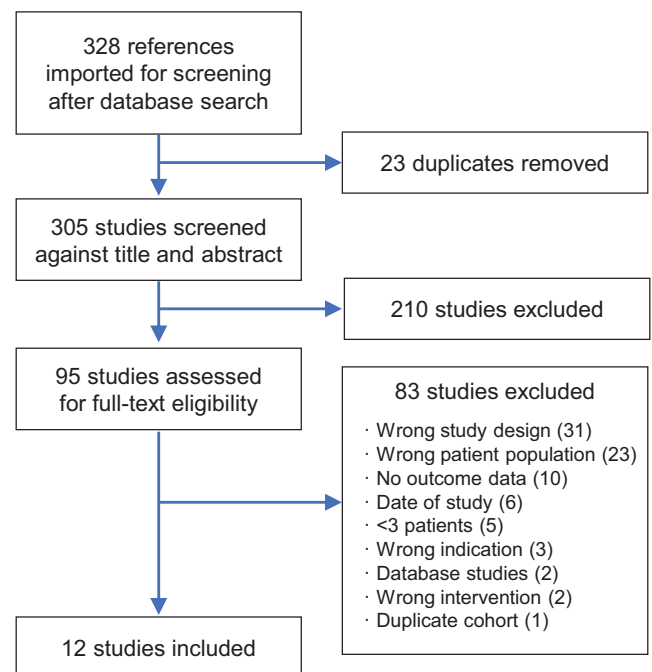


Figure 1. PRISMA flow diagram. PRISMA, Preferred Reporting Items for Systematic Reviews and Meta-Analyses.

management. If a study included a nonoperative cohort, this arm of the study was excluded; however, the operative cohort was included if it met the inclusion criteria and was either stratified or controlled for within the results.

Data Extraction and Collection

An initial screening identified 328 studies. Two reviewers (A.C., E.P.B.) independently screened all titles and abstracts, and disagreements were resolved by a third reviewer (W.M.C.). After initial screening, 95 studies were identified for full-text review. Again, two reviewers (A.C., E.P.B.) independently screened all full-text articles, with a third author (W.M.C.) resolving any conflicts.

A total of 12 studies[§] were included after application of inclusion and exclusion criteria, as outlined in Figure 1. There were 11 level 4 studies and 1 level 3 study. No prospective cohorts or randomized controlled trials were identified for inclusion. Of the 12 studies included, 91.7% were

[§]References 3, 8, 17, 21, 22, 27, 28, 32, 34, 43, 45, 51.

*Address correspondence to J. Brett Goodloe, MD, Medical University of South Carolina, 96 Jonathan Lucas Street, CSB 708, Charleston, SC 29425, USA (email: goodloej@musc.edu).

[†]Department of Orthopaedic Surgery and Physical Rehabilitation, Medical University of South Carolina, Charleston, South Carolina, USA.

[‡]Department of Orthopaedic Surgery, Rush University Medical Center, Chicago, Illinois, USA.

Final revision submitted March 27, 2021; accepted May 3, 2021.

One or more of the authors has declared the following potential conflict of interest or source of funding: J.B.G. has received education payments from Medical Device Business Services and Peerless Surgical. W.M.C. has received hospitality payments from Medical Device Business Services. C.E.G. has received research support from Wright Medical; education payments from Arthrex and Peerless Surgical; consulting fees from Medshape; and hospitality payments from Exactech, Integra LifeSciences, Sonoma Orthopedics, and Stryker. AOSSM checks author disclosures against the Open Payments Database (OPD). AOSSM has not conducted an independent investigation on the OPD and disclaims any liability or responsibility relating thereto.

TABLE 1
Quality Assessment (Critical Appraisal Skills
Programme Tool)

Item
1. Did the study address a clearly focused issue?
2. Was an appropriate method used to address the issue raised?
3. Were the patients recruited appropriately?
4. Was bias reduced by defining the intervention (ie, operative/nonoperative)?
5. Were outcomes accurately measured for each fracture type?
6. Were confounding factors identified?
7. If identified, were the confounding factors taken into account?
8. Was patient follow-up complete?
9. Were results all clearly defined (radiographic, clinical, return to sport)?
10. Are the results realistic?
11. Can the results be applied to the local population?
12. Do the results of this study fit with other available evidence?

published between 2010 and 2020. The largest study included 73 patients with 75 fifth metatarsal fractures.²⁷

The following variables were extracted from each study for analysis: study type, level of evidence, patient age, patient sex, sample size, type of sport, level of participation, follow-up duration, surgical intervention, intervention type, adjunctive therapies, fracture type, fracture acuity, rehabilitation course, weightbearing status, complications, clinical time to union, radiographic time to union, and time to RTP. Data were organized into a customized Excel spreadsheet (Microsoft) that was created at the onset of the review process.¹⁵

Data Analysis

The quality of each article was determined using the Critical Appraisal Skills Programme (CASP) tool. This tool was used previously for a similar study.³⁹ The CASP tool is designed to assess the quality of a study by using 12 “yes/no” questions, with higher quality studies having more questions with a “yes” response (Table 1). We used this tool to evaluate the available literature regarding the study question. Data were analyzed descriptively through SPSS Statistics (Version 24; IBM Corp) by using frequencies and proportions for categorical variables.

RESULTS

Study Characteristics

The characteristics of the 12 included studies are summarized in Table 2. A total of 278 elite athletes (mean age, 22.3 ± 2.78 years) with 280 fifth metatarsal fractures were included. Male athletes comprised 96.3% of the subjects in the 11 studies that reported patient sex. Based on the Torg classification system and study descriptors, 52.2% of fractures were interpreted as stress fractures (type 2 or 3) and 36.3% were described as acute fractures without prodromal symptoms (type 1). Another 2.9% of fractures were

symptomatic nonunions that failed initial nonoperative management before surgeon referral, and 8.6% were refractures previously treated with surgical fixation. Soccer and football athletes comprised 59.3% and 16.2% of the cohort, respectively. The mean follow-up period was 47.2 months across the 7 studies that reported this information.

Surgical Interventions and Adjunctive Therapy

Intramedullary screw fixation was the most common method of fixation reported (134/280; 47.9%). Implant types included solid stainless steel screws, cannulated screws, and cannulated titanium cancellous screws. Screw sizes ranged from 4.0 to 6.5 mm, including both fully threaded and partially threaded. Modified tension band wiring was the second most common method of fracture fixation (75/280; 26.8%), although it was used in only 1 study.²⁷ Other methods of fixation included open reduction and plantar plate fixation (46/280; 16.4%), fifth metatarsal biplanar rotational osteotomy (19/280; 6.8%), and external fixation with an Ilizarov mini fixator (6/280; 2.1%) (Table 3).

Some form of intraoperative adjunctive treatment was used in 67.1% of cases (188/280). Ipsilateral calcaneal autograft was the most common source of bone graft,^{3,8,17,27,28,51} followed by iliac crest bone autograft, proximal tibial autograft, and distal tibial autograft.^{18,21,22,32,45} Various techniques for bone grafting were used, from minimally invasive subperiosteal injections to open inlay procedures. Only 2 of the included studies^{34,43} did not use any form of adjunctive bone grafting, accounting for 26 athletes. Additionally, perioperative vitamin D assessment and supplementation were conducted in only 3 studies.^{3,32,51} Bone stimulators were used postoperatively in 3 studies as well.^{21,28,32} A summary of the adjunctive therapies used is outlined in Table 3.

Postoperative Protocol

All 12 studies reported on postoperative protocols. A total of 11 studies described an initial period of nonweightbearing postoperatively ranging from 0 to 42 days with a mean of 19 days. One study allowed for immediate partial weightbearing on postoperative day 1, with “progressive weightbearing” if the patient remained clinically asymptomatic.⁴³ Postoperative rehabilitation protocols are summarized in Table 4.

Outcomes Evaluated

The most common outcome measures evaluated were the presence of radiographic union, time to union, and return to sport. Union, defined as complete bony healing on radiographs or computed tomography (CT) imaging, was achieved in 269 of 280 treated fifth metatarsal fractures (96.7%). Of the 12 studies, 6 used only plain radiographs; the other 6 used either strictly CT or a combination of radiographic and CT imaging based on individualized clinical assessment. Among the 7 studies that reported time to union data, the mean time to union was 9.19 weeks (range, 5.1-30.3 weeks). Among the 11 studies that reported RTP data, the mean time to return was 11.15 weeks (range, 3-40

TABLE 2
Characteristics of the Included Studies^a

Lead Author (Year)	LOE	Sample Size (N = 278 athletes, 280 fractures)	Mean Age, y	Mean Follow-up, mo	Fracture Type	Sport
Bernstein ³ (2018)	4	8 (8 M)	21.9	38.4	Acute fracture (n = 4), refractures (prior IM screw fixation, n = 4)	6 Football, 1 basketball, 1 track and field
Dearden ⁸ (2020)	4	19 (19 M)	NR	NR	Acute fracture (n = 13), nonunions (n = 3), refractures (n = 3); 2 had osteotomy around IM screw, 1 had screw removal and autograft-from-calcaneus bone graft	2 Football, 3 soccer, 1 hockey, 1 ultimate Frisbee, 12 rugby
Hunt ¹⁷ (2011)	4	21 (16 M, 5 F)	28.4	29	Acute refracture (n = 16, prior IM screw fixation by another surgeon), symptomatic nonunion (n = 5, nonoperative treatment failure)	12 Football, 3 basketball, 1 baseball, 1 tennis, 2 golf, 2 cross-country
Lareau ²¹ (2016)	4	25 (25 M)	24	NR	Acute fracture of proximal 5th MT (mean time from injury to surgery, 8.5 d)	25 Football
Larson ²² (2002)	4	6 (NR)	21	NR	Acute fracture (n = 2), delayed fracture (n = 4)	2 Basketball, 4 soccer, 1 track and field
Lee ²⁷ (2011)	3	73 (71 M, 2 F) ^b	19.8	NR	Torg 1 (acute, n = 19), Torg 2 (stress, n = 42), Torg 3 (stress, n = 19)	72 Soccer, 1 hockey
Miller ²⁸ (2019)	4	37 (37 M)	23	60.6	Stress fracture of proximal 5th MT, Torg 2/3 (n = 37)	37 Soccer
O'Malley ³² (2016)	4	10 (10 M)	25.7	NR	Torg 1 (acute, n = 7), Torg 2 (n = 2), refracture (n = 1)	10 Basketball
Pecina ³⁴ (2011)	4	20 (19 M, 1 F)	21	123.6	Stress fracture, acute presentation with prodromal symptoms (n = 20)	NR
Tomic ⁴³ (2013)	4	6 (6 M)	20.3	48	Acute fracture (n = 6)	3 Soccer, 3 handball
Tsukada ⁴⁵ (2012)	4	15 (14 M, 1 F)	20.2	49.2	Torg 1 (acute, n = 2), Torg 2 (delayed, n = 7), Torg 3 (nonunion, n = 6)	13 Soccer, 1 handball, 1 rugby
Young ⁵¹ (2020)	4	38 (37 M, 1 F)	19.7	23	Torg 1 (acute, n = 20), Torg 2 (delayed, n = 14), Torg 3 (nonunion, n = 4)	3 Basketball, 33 soccer, 1 handball, 1 rugby

^aAll included studies were retrospective case series. F, female; IM, intramedullary; LOE, level of evidence; M, male; MT, metatarsal; NR, not reported.

^bA total of 75 fractures in 73 patients.

weeks). In all 12 studies, only 2 athletes were explicitly described as unable to return to the same level of competition. A summary of outcome measures reported in each study is provided in Table 5.

Complications

A collective 22.5% complication rate was reported across all 12 studies. However, the severity of complications ranged widely. Among all studies, 24 patients experienced a refracture (8.6%). Despite significant variability in the definition of delayed union and nonunion between studies, the combined reported rate of delayed union and nonunion was 6.8% (19/280). Other less commonly reported complications included transient sensory neuropraxias of the sural nerve, superficial skin complications, stress fractures at the screw tip, synostosis of the fourth and fifth metatarsals, and hardware irritation leading to removal of hardware. The complication profile of included studies is provided in Table 6.

Study Quality Assessment

The mean number of “yes” responses on the CASP was 8.42 (range, 6-10) among the studies included. Each study

addressed a clearly focused issue with clearly defined, realistic results that fit with other available evidence. As well, the intervention was defined and surgical technique outlined in each included study. The outcome of any fracture could have numerous confounding variables, but these were rarely addressed. Follow-up was highly variable between studies, with 4 of 12 studies (33%) failing to state the mean follow-up duration.

DISCUSSION

High-level athletes represent an exclusive patient population with unique treatment goals and adequate accessibility to resources that may optimize their care. Elite athletes are at particularly high risk for developing fifth metatarsal fracture because of their high activity level and repetitive stresses. This review highlights that the vast majority of elite athletes achieve radiographic union (96.7%) with an overall time to union around 9 weeks, an average RTP time around 11 weeks, and a near 99.9% return to preinjury level of competition after operative management of fifth metatarsal fractures.

Consistent with current literature, intramedullary screw fixation was the most common fixation method used across

TABLE 3
Intervention and Adjunctive Treatment^a

Lead Author (Year)	Intervention ^b	Hardware Type	Adjunctive Treatment ^c
Bernstein ³ (2018)	ORIF, plantar plating + bone graft	4-Hole, 3.0-mm titanium locking straight plate (Arthrex) and 3.0-mm screws	Calcaneal autogenous bone grafting (n = 8); vitamin D assessment preoperatively and supplemented if deficient
Dearden ⁸ (2020)	5th MT biplanar, rotational osteotomy	2 Cortical screw fixation of the osteotomy site; no additional fixation at proximal 5th MT fracture site	Autograft cancellous bone from calcaneal tuberosity (n = 1, refracture)
Hunt ¹⁷ (2011)	IM screw fixation ± bone graft	Solid stainless-steel screw, partially threaded (diameter, 4.5-6.5 mm)	Calcaneal autograft (n = 4), iliac crest bone marrow aspirate (n = 7), demineralized bone matrix (n = 1), iliac crest bone graft + DBM (n = 7), distal tibial autograft + DBM (n = 1), none (n = 1)
Lareau ²¹ (2016)	IM screw fixation + bone graft	Solid stainless-steel screw, partially threaded (diameter, 5.5-6.5 mm)	Iliac crest bone marrow aspirate with demineralized bone matrix (n = 25, injected into subperiosteal space); bone stimulators until union
Larson ²² (2002)	IM screw fixation ± bone graft	Cannulated screw (diameter, 4.0-6.5 mm)	Iliac crest bone graft (n = 1), bone marrow aspirate (n = 1), local grafting (n = 1), none (n = 3)
Lee ²⁷ (2011)	ORIF, modified tension band ± bone graft	2 Cortical screw fixation (1 cm away from fracture site) and wire loop (figure-of-8 fashion)	Calcaneal corticocancellous autograft from anterior process of calcaneus (Torg type 3, n = 13)
Miller ²⁸ (2019)	IM screw fixation + bone graft	Solid stainless-steel screw, partially threaded (diameter, 4.5-6.5 mm)	Calcaneal autograft + bone marrow aspirate (n = 37); bone stimulator until union
O'Malley ³² (2016)	IM screw fixation + bone graft	Solid stainless-steel screw, partially threaded (diameter, 5.5-6.5 mm)	Bone marrow aspirate concentrate from ipsilateral iliac crest (n = 10, all patients), tricortical iliac bone graft (n = 3), bone stimulators recommended (70% compliance), vitamin D assessed and supplemented, if deficient, with Forteo (n = 3; 2 after refracture)
Pecina ³⁴ (2011)	IM screw fixation	AO solid malleolar screw (diameter, 4.5 mm)	None
Tomic ⁴³ (2013)	External fixation	Ilizarov mini-fixator	None
Tsukada ⁴⁵ (2012)	IM screw fixation + bone graft	Cannulated titanium cancellous screw, partially threaded (diameter, 4.0-5.0 mm)	Proximal tibia autologous bone grafting (n = 15)
Young ⁵¹ (2020)	ORIF, plantar plating ± bone graft	Low-profile 2-hole or 4-hole 3.0-mm titanium straight plate, two 2.7-mm screws (divergent orientation)	Calcaneal autologous corticocancellous bone graft (n = 11), inlay bone grafting technique (n = 1); vitamin D supplementation (n = 38)

^aDBM, demineralized bone matrix; IM, intramedullary; MT, metatarsal; ORIF, open reduction internal fixation.

^bIM screw, 134/280; tension band, 75/280; plantar plate, 46/280; fifth MT osteotomy, 19/280; external fixation, 6/280.

^c188/280 (67.1%) of athletes had intraoperative adjunctive therapy at time of surgery.

all studies (47.9%). Previous studies report conflicting data regarding the outcomes of intramedullary screw fixation in athletes. DeLee et al⁹ and Porter et al³⁶ reported a 100% union rate with early return to sport after intramedullary screw fixation. In contrast, Larson et al²² reported a 40% failure rate with intramedullary screw fixation in their patient cohort, with all but 1 failure occurring in elite athletes. Wright et al⁴⁷ reported on 6 refractures in athletes after intramedullary screw fixation, and Hunt and Anderson¹⁷ treated 16 patients who were referred for revision after refracture around a prior intramedullary screw. The current study found a combined 98.5% union rate and a 9.7% refracture rate with the use of intramedullary screw fixation in elite athletes. The screw type and size varied among studies as did the use of adjunctive therapies, which must be considered when interpreting these results. However, much research has been conducted on the

biomechanical profile of screw fixation, with no current recommendation regarding optimal screw characteristics, including size, threads, or cannulated versus solid.^{12,22,47} Achieving adequate medullary fill while avoiding distal cortical abutment is the most commonly recommended and practiced technique.

Compression plating and tension band wiring allow for direct visualization of the fracture, counter the tensile forces of the lateral and plantar aspect of the fifth metatarsal, provide torsional control, and avoid disruption of the blood supply as the primary nutrient artery to the fifth metatarsal enters from the dorsomedial aspect.^{30,51} The present study found comparable rates of refracture for plantar plating (8.7%; 4/46 fractures) compared with reported refracture rates with intramedullary screw fixation. Additionally, Young et al⁵¹ reported a 23.7% rate of hardware removal in a cohort of 38 patients after plantar

TABLE 4
Postoperative Rehabilitation Protocol^a

Lead Author (Year)	Intervention	Postoperative Footwear; NWB Time	Protocol Basics
Bernstein ³ (2018)	ORIF, plantar plating + bone graft	Fracture boot; 14 d	Wk 0 to 2, active/passive ROM. Wk 3 to 6, progressive WB with resisted training. Wk 6 to 12, carbon fiber orthotic with full release for cutting/pivoting at 12 wk.
Dearden ⁸ (2020)	5th MT biplanar, rotational osteotomy	Aircast boot; 10 d	D 0 to 10, NWB. D 10, Air cast boot applied, 50% WB. D 21, swimming allowed. D 42, transition to training shoe. Jogging at 12 wk and expected return to full sports at 16 wk.
Hunt ¹⁷ (2011)	IM screw fixation ± bone graft	Splint or cast; 28 d	Wk 0 to 4, NWB. Wk 4, transition to CAM boot. Transition to running shoes with custom orthotic when clinically asymptomatic and show radiographic consolidation. Running initiated after radiographic union.
Lareau ²¹ (2016)	IM screw fixation + bone graft	CAM boot; 14 d	Wk 0 to 2, NWB. Wk 2, WB in CAM boot. Transition to accommodative shoe when clinically asymptomatic. Transition to running shoe when radiographs demonstrated bridging bone. Wk 6, run progression protocol and sport-specific integration with custom orthosis.
Larson ²² (2002)	IM screw fixation ± bone graft	Walker boot/splint; 14 d	Wk 0 to 2, NWB. Wk 2, WB in CAM boot with progressive WB as tolerated. Return to full activity when clinically asymptomatic and demonstrate radiographic progression.
Lee ²⁷ (2011)	ORIF, modified tension band ± bone graft	Short leg splint; 42 d	Wk 0 to 6, NWB. Wk 6, transition to walking boot with progressive WB. Return to full activity when clinically asymptomatic and demonstrate full radiographic union on radiograph and CT.
Miller ²⁸ (2019)	IM screw fixation + bone graft	Short boot; 14 d	Wk 0 to 2, NWB. Wk 2 to 4, partial WB in boot. Wk 4 to 6, full WB in boot. At 6 wk, underwent biomechanical assessment and placed in orthosis with recommendation to wear until 1 y postoperatively.
O'Malley ³² (2016)	IM screw fixation + bone graft	Short leg splint; 14 d	Wk 0 to 2, NWB in splint. Wk 2 to 4, partial WB in boot with crutches. Wk 4 to 6, full WB in boot + water therapy. Return to play when clinically asymptomatic and radiographic union.
Pecina ³⁴ (2011)	IM screw fixation	Short leg cast; 21 d	Wk 0 to 3, NWB in cast. Wk 3, WB as tolerated in hard-soled shoe. Wk 6, began running and jumping. Return to sports when clinically asymptomatic and radiographic progression toward union.
Tomic ⁴³ (2013)	External fixation	Adapted sport shoe; 1 d	D 1, 25% WB with crutches + adapted sport shoe. D 2, if no pain, then advanced to 50% WB, ankle ROM. D 3 to 7, progressive WB to full; if pain occurred, WB reduced to the previous level for 2 d. Goal of return to competitive sport in 7 wk.
Tsukada ⁴⁵ (2012)	IM screw fixation + bone graft	Splint or cast; 28 d	Wk 0 to 2, NWB in splint/cast. Wk 3 to 4, NWB without external stabilization. Wk 5 to 6, progressive WB with full WB at wk 6. Running permitted once union was achieved, with gradual increase in activity until competition.
Young ⁵¹ (2020)	ORIF, plantar plating ± bone graft	Splint or cast; 28 d	Wk 0 to 4, heel WB in cast/splint. Wk 4, transitioned to hard-soled shoe with shank with progressive WB. Running regimen began when clinically asymptomatic and union on radiograph and CT. Return to sport based on individual team protocols.

^aCAM, controlled ankle movement; CT, computed tomography; IM, intramedullary; MT, metatarsal; NWB, nonweightbearing; ORIF, open reduction internal fixation; ROM, range of motion; WB, weightbearing.

plating, in which 2 patients reported hardware prominence and 7 preferred plate removal. Lee et al²⁷ treated 75 patients who had fifth metatarsal fractures by using lateral tension band fixation and achieved 88% radiographic union with a mean time to union of 14.1 weeks. Those investigators used inlay bone graft for 1 patient who experienced a nonunion classified as Torg type 3; otherwise no additional adjunctive treatment was used. The investigators reported an overall refracture rate of 8%.²⁷

Another alternative fixation strategy is external fixation. Tomic et al⁴³ reported a case series of 6 elite athletes treated with mini-Ilizarov external fixation. Those authors suggested that external fixation allowed for adjustable distraction and compression at the fracture site, provided biplanar stabilization, and did not disrupt the anatomic integrity of the metatarsal. Tomic et al reported a 100% union rate in their cohort; the mean clinical time to healing was 4.1 weeks, and there was evidence of radiographic

TABLE 5
Outcome Measures (Radiographic Union and Return to Play)^a

Lead Author (Year)	Intervention ^b	Radiographic Union (n = 269/280; 96.7%), %	Time to Union, wk, mean (range) ^b	Time to RTP, wk, mean (range) ^c
Bernstein ³ (2018)	ORIF, plantar plating + bone graft	100.0	6.5 (5.1-9.1)	12.3 (10.1-16.3)
Dearden ⁸ (2020)	5th MT biplanar, rotational osteotomy	100.0	All patients had achieved clinical and radiographic union by 12 wk. ^d	All players had returned to competition level sporting activity at 20 wk. ^d
Hunt ¹⁷ (2011)	IM screw fixation ± bone graft	100.0	All patients had achieved clinical and radiographic union by 16 wk. ^d	12.3 (6-16) (RTP not influenced by specific bone graft used)
Lareau ²¹ (2016)	IM screw fixation + bone graft	100.0		8.7 (5.9-13.6)
Larson ²² (2002)	IM screw fixation ± bone graft	83.3		7.67 (3-12)
Lee ²⁷ (2011)	ORIF, modified tension band ± bone graft	88.0	14.1 (5.7-30.3)	
Miller ²⁸ (2019)	IM screw fixation + bone graft	97.3	12.7	10.5
O'Malley ³² (2016)	IM screw fixation + bone graft	100.0	7.5 (6-10)	10 (7-12.5)
Pecina ³⁴ (2011)	IM screw fixation	100.0		9 (5-14)
Tomic ⁴³ (2013)	External fixation	100.0	5.8 (5.4-6.4)	6.7 (6.4-6.9)
Tsukada ⁴⁵ (2012)	IM screw fixation + bone graft	100.0	8.4 (6-12)	12.1 (9-17)
Young ⁵¹ (2020)	ORIF, plantar plating ± bone graft	100.0	9.3 (8-16)	22.2 (12-40)

^aIM, intramedullary; MT, metatarsal; ORIF, open reduction internal fixation; RTP, return to play.

^bOverall mean time to union: 9.19 ± 3.13 wk.

^cOverall mean RTP time: 11.15 ± 4.35 wk.

^dValues not included in overall mean time to union or mean time to RTP because no true average was recorded.

consolidation at the fracture site at 5.8 weeks. Return to full athletic activity was reported at an average of 6.7 weeks, with 100% RTP. These findings are substantially better than other documented healing rates and average RTP included in this review. Due to the small sample size of their study population, this may represent type II error, and further adequately powered studies should be conducted to determine the validity of this treatment modality.

Substantial literature has evaluated foot morphological characteristics and their role in altering risk profiles for fifth metatarsal fractures.^{14,16,26,36} Studies have found that metatarsus adductus and hindfoot varus may predispose athletes to fifth metatarsal fractures and affect the rate of healing.^{38,49,50} Pecina et al³⁴ performed a computerized pedobarographic analysis on 20 athletes treated for fifth metatarsal fractures and found midfoot varus present in 90% of athletes, causing increased peak pressures on the lateral foot. Lee et al²⁵ found a correlation between fifth metatarsal curvature and lateral deviation angle with a higher risk of fracture. Dearden et al⁸ described an operative technique that addressed fifth metatarsal bony morphology with promising preliminary results, including 100% union rate within 12 weeks of surgery and a 100% rate of RTP before 20 weeks. The authors used a biplanar rotational osteotomy to correct fifth metatarsal curvature with the goal

of offloading the proximal fifth metatarsal. Fixation of the osteotomy site requires 2 cortical screws and no additional proximal fixation.⁸ Although further research is needed, this method may prove useful when there is concern for intramedullary screw cortical abutment or anatomic variants of the fifth metatarsal, or in the revision setting.

Despite various modes of fixation used, the present study found a large percentage of athletes who went on to radiographic union (96.7%). Diagnosing delayed union and nonunion was challenging, because author definitions varied significantly. Lee et al²⁷ defined nonunion as no visible radiographic signs of healing by 3 months postoperative, Miller et al²⁸ defined nonunion as a persistent radiographic fracture line present at 6 months, and Larson et al²² used a cutoff of 48 weeks to define nonunion. Traditionally, surgeons advocate for evidence of radiographic healing before clearing an athlete for return to sport.¹² In the present review, Miller et al²⁸ was the only study that reported a mean RTP time (10.5 weeks) that was earlier than the reported mean time to union (12.7 weeks). The subset of patients diagnosed with a delayed union were found to have significantly earlier RTP times (8.6 weeks) compared to the subset of patients who achieved union as expected (11.2 weeks; $P = .028$). This did not always affect the level of performance, as 1 player who developed a persistent

TABLE 6
Operative Complications^a

Lead Author (Year)	Intervention ^b (No. of fractures treated)	Operative Complications
Bernstein ³ (2018)	ORIF, plantar plating + bone graft (n = 8)	2 Transient sensory neurapraxias of the sural nerve (resolved at 6 wk)
Dearden ⁸ (2019)	5th MT biplanar, rotational osteotomy (n = 19)	1 Refracture (treated with IM screw technique), 1 synostosis (4th-5th metatarsal)
Hunt ¹⁷ (2011)	IM screw fixation ± bone graft (n = 21)	1 Refracture (automobile accident, elected nonoperative treatment, played senior collegiate season and rookie season in NFL)
Lareau ²¹ (2016)	IM screw fixation + bone graft (n = 25)	3 Refractures (all incomplete zone 2 with 5.5-mm screws, treated with revision IM screw exchange + iliac crest bone graft; all able to RTP)
Larson ²² (2002)	IM screw fixation ± bone graft (n = 6)	1 Nonunion (RTP at 3 wk, nonunion diagnosed at 48 wk, nonoperative treatment), 4 refractures (all treated with revision surgery + bone grafting)
Lee ²⁷ (2011)	ORIF, modified tension band ± bone graft (n = 75)	9 Nonunions (8 were type 2; 1 was type 3—defined by no visible signs of healing at 3 mo—revised by K-wire fixation + bone graft), 6 refractures (4 were Torg type 1; 2 were Torg type 2)—all caused by reinjury
Miller ²⁸ (2019)	IM screw fixation + bone graft (n = 37)	1 Superficial incisional infection (treated without PO Abx), 8 delayed unions (diagnosed at 3 mo as incomplete fracture healing), 1 nonunion (diagnosed at 6 mo, nonoperative treatment, asymptomatic), 1 refracture (revision IM screw exchange, healed by 12 wk)
O'Malley ³² (2016)	IM screw fixation + bone graft (n = 10)	3 Refractures (all were Torg type 1, treated with IM screw exchange and open bone grafting; 1 refractured again—treated with osteotomy), 1 hardware irritation (treated with headless screw exchange, led to refracture, needed an additional screw exchange with open bone grafting)
Pecina ³⁴ (2011)	IM screw fixation (n = 20)	1 Refracture (5 wk after surgery, nonoperative treatment)
Tomic ⁴³ (2013)	External fixation (n = 6)	2 Pin tract superficial infections (treated by pin removal/PO Abx)
Tsukada ⁴⁵ (2012)	IM screw fixation + bone graft (n = 15)	1 Thermal necrosis of the skin (intraoperative complication), 2 diaphyseal stress fractures (at screw tip/bone interface—1 nonoperative treatment, 1 treated with screw exchange for shorter screw)
Young ⁵¹ (2020)	ORIF, plantar plating ± bone graft (n = 38)	4 Refractures (1 was Torg type 1; 2 were Torg type 2; treatment: hardware removal + nonoperative management [n = 2], revision to IM screw fixation [n = 1], revision to tension band wiring + bone graft [n = 1]), 1 transient sensory neurapraxia, 1 superficial wound infection, 2 hardware prominences, 9 hardware removals after complete union (2 hardware prominence, 7 patient preference)

^aIM, intramedullary; MT, metatarsal; ORIF, open reduction internal fixation; PO Abx, oral antibiotics; RTP, return to play.

^bOverall complications: transient sensory neurapraxia, n = 3 (1.1% of all cases, 6.5% among plantar plating cases); stress fracture at tip of screw, n = 2 (1.5% among IM screw fixation cases); superficial skin complications, n = 4 (1.4% of all cases); delayed union or nonunion, n = 19 (6.8% of all cases, varying definitions of delayed union and nonunion); refracture, n = 24 (8.6%); synostosis, n = 1 (5.2% among osteotomy cases); hardware prominence, n = 3 (1.1% of all cases); hardware removal following union, n = 9 (3.2% of all cases, 19.6% among plantar plating cases).

nonunion was pain-free and continued playing professional soccer for several years postoperatively. Watson et al⁴⁶ also challenged the traditional nonoperative course of lengthy immobilization and prolonged rehabilitation before RTP. Their cohort of patients consisted of 25 collegiate athletes with proximal fifth metatarsal fractures treated operatively with intramedullary screw fixation who returned to play at an average of 3.6 weeks after surgery based on clinical progression of symptoms as a guide for RTP. Union was achieved in all athletes, and only 1 patient sustained a refracture (4%). Another reported risk factor for nonunion is lateral and plantar gapping at the fracture site. Lee et al²⁷ highlighted a significant difference between time to union when stratified by a plantar fracture gap >1 mm (<1 mm gap, mean 72.36 days; >1 mm gap, mean 129 days). Those authors recommended an additional plantar bone grafting procedure for Torg type 3 fractures when a plantar gap >1 mm exists.

It is important that surgeons caring for high-level athletes understand management options for refractures, especially given the relatively high rate of occurrence in this population (8.6%). The present review included 4 studies that treated refractures in their initial population.^{3,8,17,32} Plantar plating, intramedullary screw fixation, and fifth metatarsal osteotomy were all used in this setting. When exchange intramedullary screw fixation was performed, often the size or length of the screw was altered, and various types of adjunctive therapies were applied. The delivery of the adjunctive therapy varied from injection into the subperiosteal space to open inlay procedures. Hunt and Anderson¹⁷ treated 21 athletes with either refracture (n = 16) or nonunion (n = 5) after failed nonoperative management with intramedullary screw and various adjunctive treatments. The investigators used calcaneal autograft (n = 4), iliac crest bone marrow aspirate (n = 7), demineralized bone matrix (n = 1), iliac crest bone

graft with demineralized bone matrix (n = 7), distal tibial autograft with demineralized bone matrix (n = 1), and no bone graft (n = 1) in their patient cohort. They reported a 100% union rate at 4-month follow-up and found no significant difference in RTP rates between the different types of adjunctive therapies used. Understanding management options in the revision setting is important when treating elite athletes, because they experience complications and reinjuries at a higher rate than the normal population.

Adjunctive therapy was commonly used among studies. Intraoperative adjunctive therapy with bone grafting or orthobiologics was used in 67.1% of athletes treated. Only 2 studies included in this review did not use adjunctive treatments. It has become common practice to use bone marrow aspirate concentrate for sports-related fractures in elite-level athletes; however, to our knowledge, no randomized controlled comparative studies have been published on this topic.²⁹ No clear advantage of using bone graft could be definitively determined in this review due to the heterogeneity of its use.^{21,28,32}

Literature has been published regarding the use of bone stimulators for lower extremity stress fractures in athletes. Benazzo et al² reported an 88% union rate (22/25) for lower extremity stress fractures in athletes at an average of 52 days using an alternating electrical field without operative management. Streit et al⁴¹ performed a small randomized controlled trial involving 8 delayed unions or nonunions of the fifth metatarsal that were treated with active versus inactive pulsed electromagnetic fields (PEMF). The average time to complete radiographic union was 8.9 weeks for the active PEMF group compared with 14.7 weeks for the inactive PEMF group.⁴¹ The effects of bone stimulators on outcomes when used as an adjunct to surgery in elite-level athletes remains largely unknown, and there is no definitive evidence to recommend routine use postoperatively based on this systematic review.

Vitamin D insufficiency in athletes is more common than previously recognized. Vitamin D testing and supplementation of vitamin D were mentioned in only 3 of the included studies.^{3,32,51} Fishman et al¹¹ examined vitamin D levels in professional NBA players and found that nearly 80% of players were either deficient (<20 ng/mL) or insufficient (20-32 ng/mL). Shimasaki et al⁴⁰ reported that soccer players with 25(OH)D₃ serum levels <20 ng/mL were nearly 3 times as likely to develop a fifth metatarsal stress fracture compared with players who had serum levels >20 ng/mL. We suggest that all high-level athletes treated for fifth metatarsal fracture have vitamin D levels checked and subsequently supplemented at the time of treatment if found to be inadequate. Despite the small amount of existing literature supporting the use of these adjunctive treatments, their low risk profile combined with the potential for improving healing rates may justify their routine use in the treatment of elite athletes.

Several limitations should be considered when interpreting the results of the present review. The search terms used to conduct the literature search could have removed relevant articles inadvertently. A majority of studies included were level 4 observational studies; thus, there is potential risk for biased results. Each included study had inherent

flaws and weaknesses that are unavoidable but must be recognized in this review. We attempted to limit selection bias by including studies specifically evaluating elite athletes; however, even within the elite athlete population, there is substantial variation between sports in regard to loading and exertional forces during performance. Selecting only elite athletes limits the generalizability of these results to the general population. Additionally, fracture type and chronicity of fractures varied substantially throughout the review, making direct comparisons difficult. The rate of nonunion was difficult to interpret because there was not a universal definition used in all studies. Because of the limitations listed, the results presented in this systematic review are purely descriptive. Statistical comparative analyses were not performed for this review given the significant heterogeneity of data. Unfortunately, no definitive statements on the optimal treatment protocol can be made based on the results of this study.

CONCLUSION

Surgical management of fifth metatarsal fractures in elite athletes can be challenging given the physical demands of sport and the desire for quick return to participation combined with an increased risk of nonunion. The goal of this systematic review was to explore surgical outcomes for the management of fifth metatarsal fractures exclusively in the elite athlete population. Surgical constructs used varied greatly between studies; however, outcomes appeared to be similar. Due to the heterogeneity between studies, specific recommendations for optimal surgical treatment of fifth metatarsal fractures in elite athletes are difficult to make. Higher level investigations are required to further evaluate different techniques in order to optimize patient outcomes.

REFERENCES

1. Arndt A, Ekenman I, Westblad P, Lundberg A. Effects of fatigue and load variation on metatarsal deformation measured in vivo during barefoot walking. *J Biomech*. 2002;35(5):621-628.
2. Benazzo F, Mosconi M, Beccarisi G, Galli U. Use of capacitive coupled electric fields in stress fractures in athletes. *Clin Orthop Relat Res*. 1995;310:145-149.
3. Bernstein DT, Mitchell RJ, McCulloch PC, Harris JD, Varner KE. Treatment of proximal fifth metatarsal fractures and refractures with plantar plating in elite athletes. *Foot Ankle Int*. 2018;39(12):1410-1415.
4. Carreira DS, Sandilands SM. Radiographic factors and effect of fifth metatarsal Jones and diaphyseal stress fractures on participation in the NFL. *Foot Ankle Int*. 2013;34(4):518-522.
5. Clapper MF, O'Brien TJ, Lyons PM. Fractures of the fifth metatarsal: analysis of a fracture registry. *Clin Orthop Relat Res*. 1995;315:238-241.
6. Dameron TB Jr. Fractures and anatomical variations of the proximal portion of the fifth metatarsal. *J Bone Joint Surg Am*. 1975;57(6):788-792.
7. Dean BJ, Kothari A, Uppal H, Kankate R. The Jones fracture classification, management, outcome, and complications: a systematic review. *Foot Ankle Spec*. 2012;5(4):256-259.
8. Dearden PMC, Ray RI, Slater HK. An alternative surgical approach to the Jones fracture. *Tech Foot Ankle Surg*. 2020;19(3):167-173.

9. DeLee JC, Evans JP, Julian J. Stress fracture of the fifth metatarsal. *Am J Sports Med.* 1983;11(5):349-353.
10. Fansa AM, Smyth NA, Murawski CD, Kennedy JG. The lateral dorsal cutaneous branch of the sural nerve: clinical importance of the surgical approach to proximal fifth metatarsal fracture fixation. *Am J Sports Med.* 2012;40(8):1895-1898.
11. Fishman MP, Lombardo SJ, Kharrazi FD. Vitamin D deficiency among professional basketball players. *Orthop J Sports Med.* 2016;4(7):2325967116655742.
12. Glasgow MT, Naranja RJ Jr, Glasgow SG, Torg JS. Analysis of failed surgical management of fractures of the base of the fifth metatarsal distal to the tuberosity: the Jones fracture. *Foot Ankle Int.* 1996;17(8):449-457.
13. Gross TS, Bunch RP. A mechanical model of metatarsal stress fracture during distance running. *Am J Sports Med.* 1989;17(5):669-674.
14. Guettler JH, Ruskan GJ, Bytomski JR, Brown CR, Richardson JK, Moorman CT III. Fifth metatarsal stress fractures in elite basketball players: evaluation of forces acting on the fifth metatarsal. *Am J Orthop (Belle Mead NJ).* 2006;35(11):532-536.
15. Harris JD, Quatman CE, Manring MM, Siston RA, Flanigan DC. How to write a systematic review. *Am J Sports Med.* 2014;42(11):2761-2768.
16. Hetsroni I, Nyska M, Ben-Sira D, et al. Analysis of foot structure in athletes sustaining proximal fifth metatarsal stress fracture. *Foot Ankle Int.* 2010;31(3):203-211.
17. Hunt KJ, Anderson RB. Treatment of Jones fracture nonunions and refractures in the elite athlete: outcomes of intramedullary screw fixation with bone grafting. *Am J Sports Med.* 2011;39(9):1948-1954.
18. Hunt KJ, Goeb Y, Esparza R, Malone M, Shultz R, Matheson G. Site-specific loading at the fifth metatarsal base in rehabilitative devices: implications for Jones fracture treatment. *PM R.* 2014;6(11):1022-1029; quiz 1029.
19. Jones R. I. Fracture of the base of the fifth metatarsal bone by indirect violence. *Ann Surg.* 1902;35(6):697-700.2.
20. Kavanaugh JH, Brower TD, Mann RV. The Jones fracture revisited. *J Bone Joint Surg Am.* 1978;60(6):776-782.
21. Lareau CR, Hsu AR, Anderson RB. Return to play in National Football League players after operative Jones fracture treatment. *Foot Ankle Int.* 2016;37(1):8-16.
22. Larson CM, Almekinders LC, Taft TN, Garrett WE. Intramedullary screw fixation of Jones fractures: analysis of failure. *Am J Sports Med.* 2002;30(1):55-60.
23. Lawrence SJ, Botte MJ. Jones' fractures and related fractures of the proximal fifth metatarsal. *Foot Ankle.* 1993;14(6):358-365.
24. Le M, Anderson R. Zone II and III fifth metatarsal fractures in athletes. *Curr Rev Musculoskelet Med.* 2017;10(1):86-93.
25. Lee KT, Kim KC, Park YU, Kim TW, Lee YK. Radiographic evaluation of foot structure following fifth metatarsal stress fracture. *Foot Ankle Int.* 2011;32(8):796-801.
26. Lee KT, Park YU, Jegal H, Kim KC, Young KW, Kim JS. Factors associated with recurrent fifth metatarsal stress fracture. *Foot Ankle Int.* 2013;34(12):1645-1653.
27. Lee KT, Park YU, Young KW, Kim JS, Kim JB. The plantar gap: another prognostic factor for fifth metatarsal stress fracture. *Am J Sports Med.* 2011;39(10):2206-2211.
28. Miller D, Marsland D, Jones M, Calder J. Early return to playing professional football following fixation of 5th metatarsal stress fractures may lead to delayed union but does not increase the risk of long-term non-union. *Knee Surg Sports Traumatol Arthrosc.* 2019;27(9):2796-2801.
29. Miller TL, Kaeding CC, Rodeo SA. Emerging options for biologic enhancement of stress fracture healing in athletes. *J Am Acad Orthop Surg.* 2020;28(1):1-9.
30. Mitchell RJ, Duplantier NL, Delgado DA, et al. Plantar plating for the treatment of proximal fifth metatarsal fractures in elite athletes. *Orthopedics.* 2017;40(3):e563-e566.
31. Moher D, Shamseer L, Clarke M, et al. Preferred reporting items for systematic review and meta-analysis protocols (PRISMA-P) 2015 statement. *Syst Rev.* 2015;4:1.
32. O'Malley M, DeSandis B, Allen A, Levitsky M, O'Malley Q, Williams R. Operative treatment of fifth metatarsal Jones fractures (zones II and III) in the NBA. *Foot Ankle Int.* 2016;37(5):488-500.
33. Orendurff MS, Rohr ES, Segal AD, Medley JW, Green JR III, Kadel NJ. Biomechanical analysis of stresses to the fifth metatarsal bone during sports maneuvers: implications for fifth metatarsal fractures. *Phys Sportsmed.* 2009;37(2):87-92.
34. Pecina M, Bojanic I, Smoljanovic T, Ivkovic A, Mirkovic M, Jelic M. Surgical treatment of diaphyseal stress fractures of the fifth metatarsal in competitive athletes: long-term follow-up and computerized pedobarographic analysis. *J Am Podiatr Med Assoc.* 2011;101(6):517-522.
35. Porter DA. Fifth metatarsal Jones fractures in the athlete. *Foot Ankle Int.* 2018;39(2):250-258.
36. Porter DA, Duncan M, Meyer SJ. Fifth metatarsal Jones fracture fixation with a 4.5-mm cannulated stainless steel screw in the competitive and recreational athlete: a clinical and radiographic evaluation. *Am J Sports Med.* 2005;33(5):726-733.
37. Portland G, Kelikian A, Kodros S. Acute surgical management of Jones' fractures. *Foot Ankle Int.* 2003;24(11):829-833.
38. Raikin SM, Slenker N, Ratigan B. The association of a varus hindfoot and fracture of the fifth metatarsal metaphyseal-diaphyseal junction: the Jones fracture. *Am J Sports Med.* 2008;36(7):1367-1372.
39. Roche AJ, Calder JD. Treatment and return to sport following a Jones fracture of the fifth metatarsal: a systematic review. *Knee Surg Sports Traumatol Arthrosc.* 2013;21(6):1307-1315.
40. Shimasaki Y, Nagao M, Miyamori T, et al. Evaluating the risk of a fifth metatarsal stress fracture by measuring the serum 25-hydroxyvitamin D levels. *Foot Ankle Int.* 2016;37(3):307-311.
41. Streit A, Watson BC, Granata JD, et al. Effect on clinical outcome and growth factor synthesis with adjunctive use of pulsed electromagnetic fields for fifth metatarsal nonunion fracture: a double-blind randomized study. *Foot Ankle Int.* 2016;37(9):919-923.
42. Thomson A, Akenhead R, Whiteley R, D'Hooghe P, Van Alsenoy K, Bleakley C. Fifth metatarsal stress fracture in elite male football players: an on-field analysis of plantar loading. *BMJ Open Sport Exerc Med.* 2018;4(1):e000377.
43. Tomic S, Vucic V, Dobric M, Bisignani G. Treatment of acute Jones fracture with Ilizarov external minifixator: case series of six elite athletes. *J Foot Ankle Surg.* 2013;52(3):374-379.
44. Torg JS, Balduini FC, Zelko RR, Pavlov H, Peff TC, Das M. Fractures of the base of the fifth metatarsal distal to the tuberosity: classification and guidelines for non-surgical and surgical management. *J Bone Joint Surg Am.* 1984;66(2):209-214.
45. Tsukada S, Ikeda H, Seki Y, Shimaya M, Hoshino A, Niga S. Intramedullary screw fixation with bone autografting to treat proximal fifth metatarsal metaphyseal-diaphyseal fracture in athletes: a case series. *Sports Med Arthrosc Rehabil Ther Technol.* 2012;4(1):25.
46. Watson S, Trammell A, Tanner S, Martin S, Bowman L. Early return to play after intramedullary screw fixation of acute Jones fractures in collegiate athletes: 22-year experience. *Orthop J Sports Med.* 2020;8(4):2325967120912423.
47. Wright RW, Fischer DA, Shively RA, Heidt RS Jr, Nuber GW. Refracture of proximal fifth metatarsal (Jones) fracture after intramedullary screw fixation in athletes. *Am J Sports Med.* 2000;28(5):732-736.
48. Yates J, Feeley I, Sasikumar S, Rattan G, Hannigan A, Sheehan E. Jones fracture of the fifth metatarsal: is operative intervention justified? A systematic review of the literature and meta-analysis of results. *Foot (Edinb).* 2015;25(4):251-257.
49. Yoho RM, Carrington S, Dix B, Vardaxis V. The association of metatarsus adductus to the proximal fifth metatarsal Jones fracture. *J Foot Ankle Surg.* 2012;51(6):739-742.
50. Yoho RM, Vardaxis V, Dikis J. A retrospective review of the effect of metatarsus adductus on healing time in the fifth metatarsal Jones fracture. *Foot (Edinb).* 2015;25(4):215-219.
51. Young KW, Kim JS, Lee HS, Jegal H, Park YU, Lee KT. Operative results of plantar plating for fifth metatarsal stress fracture. *Foot Ankle Int.* 2020;41(4):419-427.