Experimental Models of Virus-Induced Demyelination of the Central Nervous System

Mauro C. Dal Canto, MD,* and Stanley G. Rabinowitz, MD†

One of the arguments in favor of a viral pathogenesis for multiple sclerosis is the existence of several experimental and natural animal models of virus-induced primary demyelination. This review deals comprehensively with such models. Well-known examples of demyelinating viral infections in their natural host are JHM, Theiler, visna, and canine distemper encephalomyelitides. Recent reports of experimental murine infections with pathogens such as vesicular stomatitis, Chandipura, herpes simplex, Venezuelan equine encephalomyelitis, and Semliki Forest viruses are also discussed. The thrust of the review is to include viral models suspected of producing primary demyelination on an immunopathological basis.

Dal Canto MC, Rabinowitz SG: Experimental models of virus-induced demyelination of the central nervous system. Ann Neurol 11:109–127, 1982

Since Pasteur first developed an antirabies vaccine [72] it has been recognized that viruses, either inoculated as vaccines or by natural infection, may induce inflammatory-demyelinating lesions in human beings. Such diseases are now grouped under the term *disseminated encephalomyelitis* [14, 50]. Lesions in disseminated encephalomyelitis have striking similarities to those of experimental allergic encephalomyelitis (EAE), a prototypic autoimmune demyelinating disease of laboratory animals [51, 82, 99]. The clinical course of disseminated encephalomyelitis, which starts one to two weeks after infection, as well as its pathological similarity to EAE, have long suggested that demyelination in this disease is most probably caused by the host immune response [41].

A more common disease of humans, multiple sclerosis (MS), is also characterized by inflammatory demyelination [59, 78]. The course, however, generally is not acute but rather is chronic, with exacerbations and remissions over a period of many years [59]. Epidemiological [1], serological [68, 69], and virological [9, 13] data are compatible with the suggestion that a viral infection plays a role in the pathogenesis of MS [41]. In addition, because of the pathological similarities between MS and EAE as well as immunological data from human studies, several investigators [17, 87] have suggested that the host immune response may be necessary for induction of MS lesions. The immunological and viral hypotheses for the pathogenesis of MS are not mutually exclusive since a viral infection could trigger host immune mechanisms, which in turn would mediate tissue injury.

The possibility that important human demyelinating diseases may be triggered by viral infection has stimulated numerous laboratories to develop animal models of virus-induced demyelination during the past several years [50, 61]. New observations by several laboratories indicate that a variety of conventional viruses produce primary demyelination, probably based on immunopathological mechanisms. This paper reviews those findings and analyzes their relevance to human demyelinating disease.

Canine Distemper Virus Infection

Canine distemper virus (CDV) belongs to the genus *Morbillivirus* of the family Paramixoviridae [3]. It is antigenically related to bovine rinderpest and human measles viruses. All three viruses contain hemagglutinin but no neuraminidase in the virion envelope. Virions are composed of a relatively rigid helical nucleocapsid, 15 to 19 nm in diameter, enclosed in a lipid-containing envelope studded with projections. The overall diameter of the virion is 120 to 300 nm. The viral genome is a continuous molecule of single-stranded RNA with a molecular weight of 6×10^6 daltons. It is transcribed by a virion-associated polymerase into complementary messenger RNA, also present in the virion. Infected

From the Departments of *Pathology (Neuropathology) and †Medicine, Northwestern University Medical School, 303 E Chicago Ave, Chicago, IL 60611.

Received Aug 7, 1981, and in revised form Sept 22. Accepted for publication Sept 27, 1981.

Address reprint requests to Dr Dal Canto.

cells contain several size classes of virus RNA, some of which correspond to replicative and transcriptive intermediates [3]

Distemper, measles, and rinderpest viruses have similar protein compositions. Seven polypeptides have been characterized in CDV [11]. Nucleocapsids contain a single protein that may be cleaved by proteolytic enzymes used for cell dispersion. The virion envelope contains one large and one small glycoprotein [3].

Entry of virus into host cells is accomplished through virus attachment and fusion of the viral envelope with the cell membrane. Virus replication is mainly cytoplasmic, and maturation is by budding of assembled nucleocapsides through a virally modified cell membrane. One of the most characteristic effects of infection by CDV and related viruses is the induction of syncytium formation by cell fusion. This phenomenon has been observed both in vitro and in vivo [34, 43, 83, 92].

CDV produces a natural disease in the dog characterized by an incubation period of three to six days, fever, nasal discharge, and both intestinal and respiratory involvement. Commonly, central nervous system (CNS) symptoms ensue either during the acute phase of the disease or late, after three or four weeks of illness. In some cases CNS infection may appear without previous signs of disease or after a period of recovery from systemic manifestations [6].

Initial studies at the ultrastructural level were performed in animals with clinical symptoms extending from ten days to twelve weeks prior to death. In all dogs, both demyelinating and destructive lesions were observed [98]. Demyelination occurred in areas with variable degrees of inflammation, was often observed around blood vessels (Fig 1), and was generally associated with cells. Processes of mononuclear cells were seen to encompass myelinated fibers and proceed either to phagocytose myelin from the outer toward the inner lamellae or to penetrate the myelin sheaths and strip myelin lamellae from their respective axons. Quiescent lesions were characterized by groups of denuded axons surrounded by activated glial processes in the absence of residual inflammatory activity [98].

The destructive type of lesion was characterized by degeneration of both axons and myelin, extracellular proteinaceous exudate, increased extracellular space, and inflammatory cells, including macrophages [98]. In both demyelinating and destructive lesions, viral inclusions were observed in various types of cells but especially in astrocytes, and demonstrated the classic appearance of distemper nucleocapsids.

While the presence of intracellular virus in both demyelinating and destructive lesions was consistent with a direct viral insult as the cause of both types of

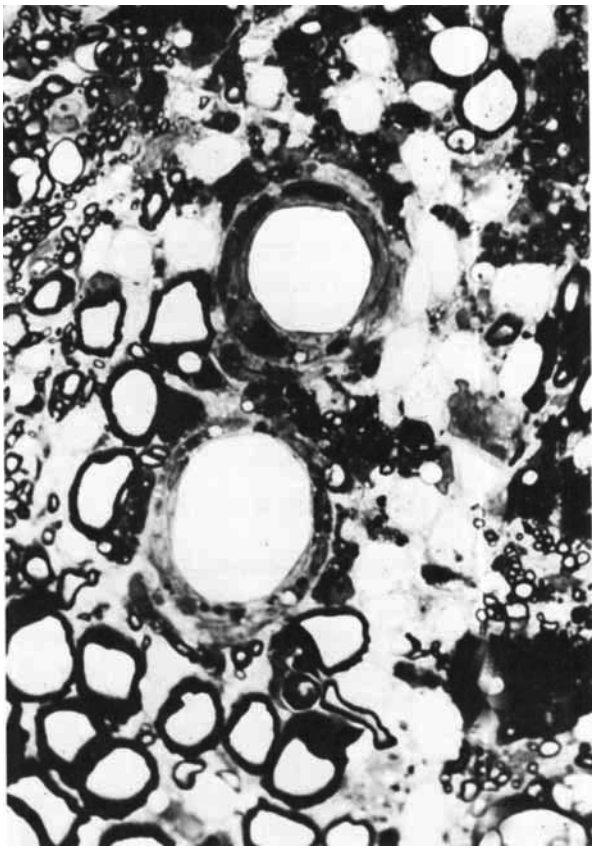

Fig 1. Canine distemper of two weeks' duration, 1 μm section. A group of naked axons surrounds two blood vessels, each containing macrophages within the Virchow-Robin space. (Toluidine blue; ×560 before 10% reduction.) (From Wisniewski, Raine, and Kay [98], Lab Invest 26:589–599, 1972. © 1972, U.S.–Canadian Division of the International Academy of Pathology.)

alterations, the association of demyelination with inflammatory cells also suggested the possibility of an immune-mediated process of myelin injury. In an attempt to resolve this question, studies were recently done to determine the sequence of events leading to demyelination in the early phase of the acute form of natural distemper [83]. Abundant evidence of early myelin breakdown was found in the absence of inflammatory cells except for occasional macrophages. In well-established lesions, on the other hand, inflammatory cells were numerous. Important cellular components of the acute lesions were multinucleated giant cells which, under electron microscopy, appeared to have been derived from fusion of astrocytes. Viral inclusions were numerous in both giant cells and astrocytes as well as in cells considered to be oligodendrocytes (Fig 2). A major conclusion from these studies was that demyelination in CDV infection was not necessarily related to the presence of an inflammatory response and that inflammatory

Fig 2. Canine distemper. An infected cell, probably an oligodendrocyte from an acute lesion, contains intranuclear and intracytoplasmic viral material. (×15,000) (From Raine [83], J Neurol Sci 30:13–28, 1976.)

cells probably represented a secondary late response to viral-induced tissue injury [83].

Because of the difficulty in studying the precise temporal development of natural distemper in the laboratory, investigators have tried to develop experimental models of the disease. To this point, however, the dog remains the only animal to develop demyelination after experimental infection with CDV. Initially, even in the natural host, CDV produced demyelination in only a small percentage of dogs. The isolation of R252 CDV by cocultivation with Vero cells and its subsequent inoculation into dogs expanded the incidence of demyelination to almost 50% of infected animals [62, 63]. These data highlight the fact that even in the natural host, ordinary nonadapted strains of CDV do not appear capable of producing consistent demyelination.

When R252 CDV was inoculated into 4- or 8-week-old dogs, three clinicopathological syndromes were observed [62]. In some dogs, pathological evidence of acute encephalitis developed two to five days after the first neurological signs appeared. In these animals, multiple areas of demyelination were observed in the medulla and cerebellum. Inflammatory cells were absent in such demyelinating lesions. Reactive astrocytes were numerous, and many astrocytic nuclei contained eosinophilic viral inclusions, as did some oligodendroglial nuclei. Immunologically, dogs with the acute syndrome were affected by severe, persistent lymphopenia. Subacute encephalitis presenting with intermittent neurological dysfunction occurred in other animals. Affected animals survived for at least twelve weeks after infection. Pathologically, there were multifocal demyelinating lesions in association with perivascular cuffs of mononuclear cells. Inflammatory cells were also found in nondemyelinated areas of white matter, however, and some demyelinated areas were free of inflammatory cells. Intracytoplasmic and intranuclear accumulations of CDV nucleocapsids were present in several types of cells, especially astrocytes. Immunologically, these animals developed transient lymphopenia. The last group of animals displayed asymptomatic CDV infection with no pathological lesions but were found to have transient lymphopenia.

The distribution of the acute versus subacute demyelinating disease appeared to be influenced by the animal's age at the time of inoculation. Thus, newborn dogs most often displayed the acute encepha-

litic form of CDV infection, while the subacute form was more common when dogs were infected as weanlings [45]. Such data imply a delicate balance between CDV infection and mechanisms of host immunity. Altering the balance profoundly affects the outcome of the disease. Thus, when viral factors predominate, acute fatal encephalitis ensues; if host defenses predominate, persistent infection develops [45]. Support for this hypothesis can be found in experimental studies in which anti-CDV antibody passively transferred to newborn gnotobiotic (germ-free) dogs resulted in prolongation of the disease course and, more importantly, in modification of the pathological lesions in the CNS [47]. Extensive involvement of gray matter, multiple viral inclusions in large neurons, and sporadic demyelination in dogs receiving anti-CDV antibody contrasted sharply with only sporadic foci of neuronal degeneration in untreated animals. Although the mechanisms of antibody-induced modification of CDV encephalitis are not well understood, these studies suggested that both clinical expression of the disease and severity of pathological lesions are at least partly dependent upon immunological factors [47].

In this context, the possibility exists that demyelinating lesions themselves may be modulated by the host immune response rather than being produced by direct viral cytolytic activity. From the cited studies of both natural and experimental CDV encephalitis, several conclusions emerge. Two lines of evidence favor the hypothesis that demyelination is immune mediated: (1) mononuclear inflammatory infiltrates can be found in lesions of both the subacute and chronic forms of CDV infection, i.e., "old dog encephalitis" [62, 98]; and (2) antimyelin antibodies have been shown to develop prior to the onset of encephalitis [44]. On the other hand, data against immune-mediated injury include the following: (1) the acute form of demyelination is not associated with inflammatory cells [83]; (2) in the subacute form, many of the demyelinating lesions can be anatomically separated from mononuclear infiltrates, and vice versa [62, 83]; (3) necrotic lesions indicative of frank viral cytolysis are present [98]; and (4) infection of glial cells, including oligodendrocytes, may directly cause demyelination [83]. In this regard, fusion of glial cells by virus, similar to the situation in subacute sclerosing panencephalitis, has been invoked as one possible mechanism leading to myelin disruption [83].

Relevance to MS

In recent years, epidemiological studies have suggested a relationship between dog ownership and the development of MS [10, 18, 19 49]. Other studies have failed to support such a relationship [46, 48]. Nevertheless, CDV infection is an important model for MS because it possesses the following characteristics: (1) it produces persistent infection; (2) the clinical syndrome may be characterized by relapses and remissions; and (3) demyelination may be immune mediated. CDV infection, however, has some notable drawbacks as a testable model for MS. For example, despite attempts by various laboratories, demyelination has not been obtained in rodents infected with CDV [60]. This makes further investigation of the model cumbersome and expensive. Furthermore, CDV is highly contagious, so studies must be conducted under strict conditions of isolation. Finally, immunological manipulations in dogs are not standardized and cannot be conducted under controlled genetic conditions such as exist for inbred strains of mice.

JHM Virus Infection

JHM virus (JHMV) is a neurotropic strain of mouse hepatitis virus, a member of the coronavirus family [84]. Coronaviruses owe their name to a crown, or *corona,* of widely spaced, bulbous peplomers or spikes, 12 to 24 nm in length, arranged around a spherical particle measuring 80 to 160 nm in diameter. They are enveloped, RNA-containing viruses that bud solely from the membranes of the endoplasmic reticulum, where nucleocapsids assume a horseshoe or flasklike configuration. The virion genome is a large, single piece of single-stranded infectious RNA of messenger polarity with a molecular size of about 5.4 million daltons [84].

The molecular events in coronavirus absorption, penetration, and uncoating, in biosynthesis of viral macromolecules, and in viral assembly occurring in infected cells both in vitro and in vivo are not completely understood. During maturation, nucleocapsids are assembled in the cytoplasm in association with the endoplasmic reticulum and Golgi apparatus. At the stage of budding from the membranes, peplomers are added to the virion. Release of the virus occurs by lysis of the cell membranes rather than by budding from the cell surface [84].

JHMV is endogenous to mice and was isolated by Cheever et al in 1949 [15] when its capacity to produce demyelination was first recognized. Recent studies in mice, rats, and in vitro have produced useful data aiding in the interpretation of this model. The outcome of the infection in mice is known to depend on viral dose and age of the host.

The importance of the dose of virus was clearly demonstrated by infecting 4-week-old Swiss mice [97]. For example, demyelinating lesions could be obtained with intracerebral inoculation of 10 to 100 $SMLD_{50}$ (suckling mouse lethal dose) of virus, while inocula of 1,000 to 10,000 $SMLD_{50}$ mainly resulted

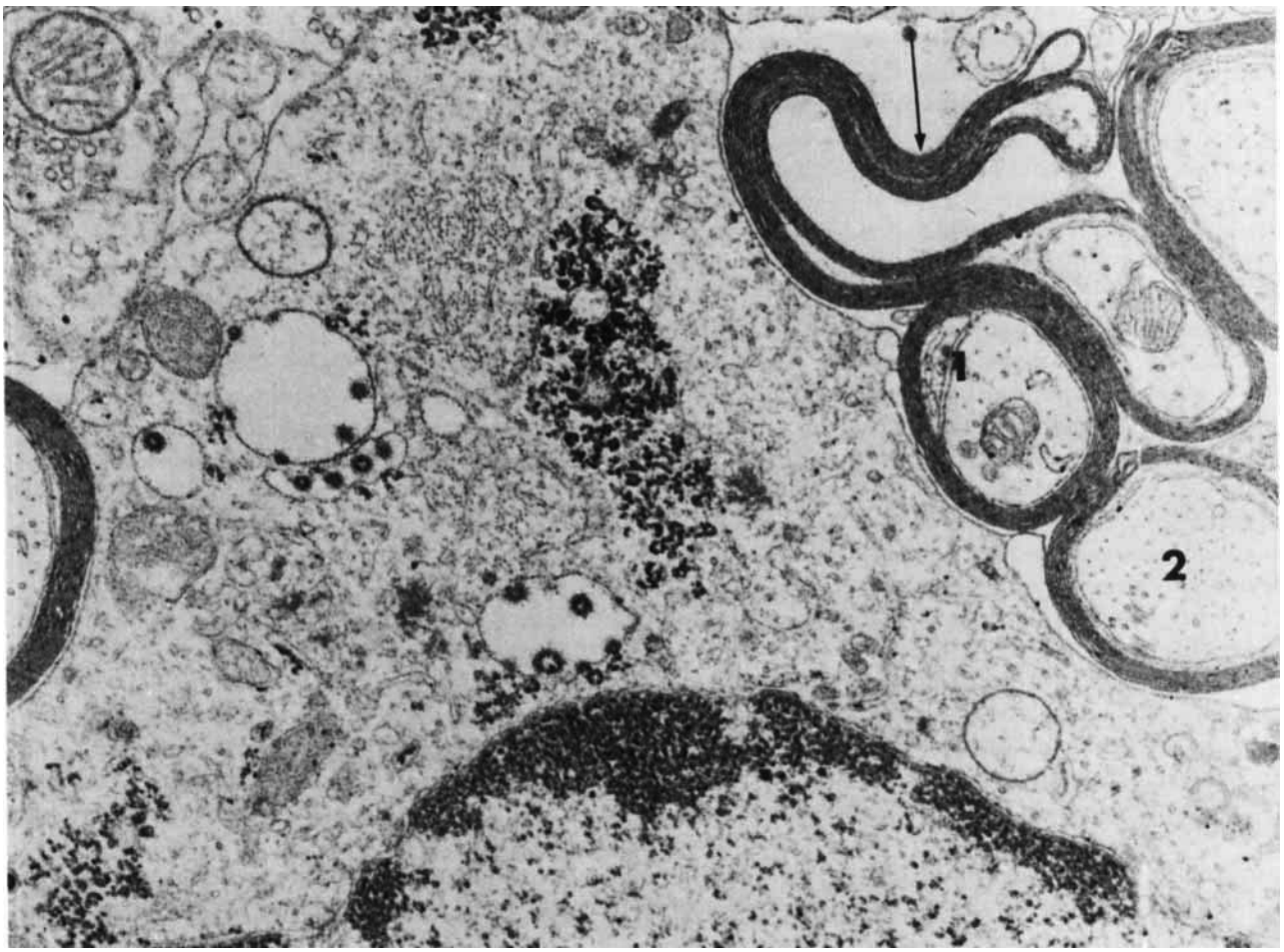

Fig 3. Oligodendrocyte containing intracisternal virions of mouse hepatitis virus (JHM strain). Aggregates of electron-dense particles, microtubules, filaments, and vacuoles are prominent in the hypertrophic cytoplasm. A redundant myelin loop (arrow) *is connected with an oligodendroglial process. Note the abnormal oligodendroglial connections with axons labeled* 1 *and* 2. *(×37,000) (From Powell and Lampert* [77], *Lab Invest 33:440–445, 1975. © 1975, U.S.–Canadian Division of the International Academy of Pathology.)*

in gray and white matter necrosis. With increasing viral dose, higher mortality was observed [97].

As in CDV infection, demyelination was best observed in animals of a certain age. Consistent demyelinating lesions could in fact be obtained in 4-week-old mice inoculated with 10 to 100 $SMLD_{50}$ of virus, while mice inoculated at 2 weeks of age always developed severe encephalomyelitis and died even after very small viral doses [97]. From studies in SJL mice, it appears that resistance to fatal JHMV infection of the CNS may depend in part upon age-related maturation of a specialized non-T, non-B, Ia-negative adherent cell population [89]. What specific antiviral mechanism these cells are responsible for is not yet clear [89].

Demyelination in 4-week-old mice develops in the first three to five days after infection and is not temporally associated with the appearance of mononuclear cell infiltrates, which may be observed shortly thereafter. Ultrastructurally, the virus is known to be pantropic since every cell type of the CNS becomes infected. Oligodendrocytes, however, appear to be the principal target for this virus [30, 52]. JHMV replication in oligodendroglia, as in other types of cells, is characterized by virus budding into cytoplasmic vacuoles and cisterns of the endoplasmic reticulum [30, 52]. Infected oligodendrocytes quickly undergo pathological alterations characterized by hyperproduction of haphazardly oriented membranes, abnormal multiple connections with myelin sheaths (Fig 3) [77], and formation of syncytia by fusion with other oligodendroglial cells [30]. The presence of morphological alterations in oligodendrocytes, the lack of a temporal and anatomical relationship between demyelination and inflammation, as well as the failure of immunosuppression to prevent demyelination [97] strongly suggest that myelin

degeneration in this model is due to primary viral injury of the myelin-supporting cell rather than to immune-mediated mechanisms.

An important feature of this model is the presence of active demyelination during the chronic phase of infection [38]. Strain and species differences influence this effect. Only 3 out of 110 weanling rats showed evidence of demyelination during chronic disease [64]. Among the strains of mice that have been studied, 15% of Balb/c mice and 46% of C57BL/6 mice infected at 12 weeks of age showed evidence of chronic demyelination [91]. In these mice, virus could be isolated from the CNS only during the acute phase of the disease. No detectable virus could be found later than fourteen days after inoculation, coincident with the increase in detectable antibody. Viral antigen, however, could be seen sporadically on immunofluorescence study in the CNS of infected animals for months after infection [91], suggesting that a persistent and perhaps defective infection develops in this model.

The mechanisms responsible for persistence of virus in JHMV infection have not been fully clarified. In vitro studies demonstrated that persistent infection of neuroblastoma cells is not associated with alterations in the properties of the virus, such as selection of temperature-sensitive or plaque mutants or production of defective interfering particles. Such studies have also failed to demonstrate the presence of interferon secreted by infected cells [90]. On the other hand, the introduction of an antiviral factor such as antibody can be responsible for modulating productive into persistent infection [90]. Addition of low-concentration antiviral antibody, in fact, produced a JHMV carrier culture characterized by the presence of cytoplasmic viral antigen but without surface viral antigen, production of infectious virus, or cytopathic effects [90]. In analogy with the in vitro situation, in vivo host immune responses may be a critical element for the establishment and maintenance of persistent JHMV infection [90].

Relevance to MS

JHMV infection is an important model for the following reasons: (1) it is a persistent infection; (2) it is characterized by both acute and chronic demyelination; and (3) it produces murine infection, which allows easy immunological, genetic, and virological manipulations in the laboratory. Furthermore, coronaviruses have been isolated from the brains of two MS patients [9]. These observations await further confirmation but, if valid, would lend credence to the importance of coronaviruses in human disease.

Visna Virus Infection

Visna virus belongs to the family of Retroviridae [4]. Virions are 60 to 90 nm in diameter and consist of a lipoprotein envelope enclosing an icosahedral shell that contains a filamentous nucleocapsid. The virion genome consists of a single-stranded RNA molecule composed of subunits and arranged in a coiled configuration. The genome is transcribed by a virion-associated reverse transcriptase into a DNA provirus that is incorporated into the cellular DNA [36]. This mechanism allows the virus to persist in cells without being recognized by the host immune system. Progeny RNA is transcribed from provirus DNA and acts as a messenger RNA. Provirus DNA is infectious. Viral maturation takes place by budding through the plasma membrane, which carries virus-coded glycoproteins. An important aspect of visna virus–cell interaction is the induction of syncytia by cell fusion [4].

Visna is a natural slow virus disease of sheep involving both the respiratory system and the CNS [70, 88]. Experimentally, intracerebral inoculation results in neurological disease after an incubation period of two months to eight years [76]. Symptoms also progress over periods of months to years, sometimes in a remitting-relapsing pattern eventuating in paraplegia or quadriplegia and ultimately death. Virus may be isolated from many tissues, including the CNS, for several years after infection [75]. Low viral titers, however, have made virus localization impossible by either immunofluorescence or electron microscopy.

Pathologically, two phases of the disease may be recognized [33, 75, 88]. The first is a subacute encephalitis characterized by inflammatory infiltrates and relatively little necrosis of tissue. Apparently the virus infects only a few cells, with moderate cytolysis but with enough production of antigen to stimulate an antibody response. The second phase is more severe and does not follow a stereotyped pattern, since different animals become ill at intervals ranging from two months to more than six years after infection. Lesions are more focal than in the subacute encephalitic phase and may show varying degrees of severity in different foci. Two types of alterations are seen [34, 75]. The first is characterized by inflammation and tissue necrosis, more severe around the ventricles and involving both gray and white matter in brain and spinal cord. The second type of lesion is characterized by primary demyelination that appears to be directly related to mononuclear inflammatory infiltrates. Acute and chronic lesions may be found at the same time, indicating that separate waves of demyelination may occur [32]. In some of the older lesions, remyelination may be observed (Fig 4).

Studies of the immune response to intracerebral

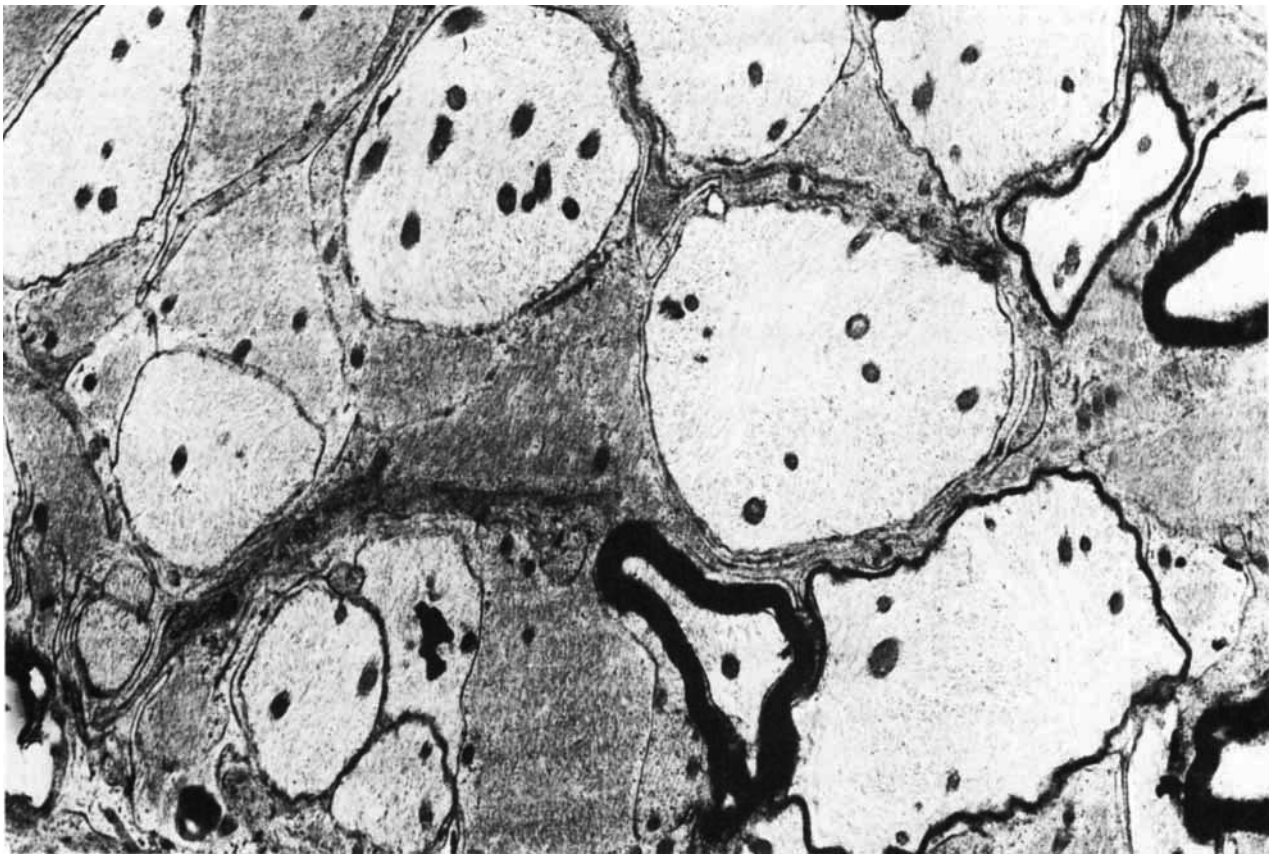

Fig 4. A group of normal-appearing demyelinated axons from a plaque in the posterior column of the lumbar spinal cord. This sheep was infected with visna virus by intracerebral inoculation 6½ years before sacrifice and had shown lameness of the hind legs for one week prior to sacrifice. (×9,100) (Courtesy of Dr G. Georgsson.)

visna virus infection have provided interesting results [61, 67, 75]. Complement-fixing antibodies are detected in serum two to three weeks after infection, while virus neutralizing antibodies appear by six weeks to three months. Antibody titers then persist at a fairly constant level for years. High titers of neutralizing antibodies are also present in the cerebrospinal fluid (CSF). The lack of correlation between serum and CSF antibody titers suggests that viral antibodies are synthesized locally in the CNS. In support of this conclusion, typical plasma cells are generally present in both CSF and CNS tissues, and oligoclonal immunoglobulin bands have been observed in some CSF specimens. There is evidence that the immune response is important in limiting the spread of virus, thus contributing to the slowness of the infection [61].

During study of cell-mediated immune responses, a transient virus-specific lymphocyte blast transformation was observed in cells from both blood and CSF of infected sheep. The response, however, lasted only four or five weeks and was observed in animals without clinical disease [61].

Recently, aspects of the disease have been uncovered which may help to explain the persistence of infection. During the course of infection, neutralizing antibodies to variants of visna virus antigenically distinct from the original inoculum were observed [75]. In addition, isolates recovered years after infection were antigenically different from the original inoculum [65]. This shifting of antigenic characteristics, or "antigenic drift," may be a mechanism by which virus escapes host defenses, thus being able to persist in the host for prolonged periods. The molecular mechanisms responsible for antigenic drift are not understood.

An important aspect of visna virus infection is the immunopathological nature of the early lesions, as demonstrated by immunosuppression studies with antithymocyte serum [66]. Whether myelin degeneration in the chronic phase is also immune mediated has yet to be determined.

Relevance to MS

Two of the important characteristics of visna are persistence of the infection and relapsing course. The mechanisms underlying restriction of virus replication and the role of antigenic drift in the expression of clinical disease are potentially of great relevance to MS. As a model of demyelination, visna has some limitations. The use of sheep as a laboratory animal is cumbersome and expensive. Second, the lack of available inbred strains of sheep limits immunological manipulations. Finally, primary demyelination is part of a more complex pathological process.

Theiler Murine Encephalomyelitis Virus Infection

Little is known about the molecular biology of Theiler murine encephalomyelitis virus (TMEV), an RNA virus that belongs to the family of Picornaviridae. Mature virions possess three major structural polypeptides in the range of 25,000 to 35,000 daltons and a smaller fourth major polypeptide of 6,000 daltons [58]. Virions measure 25 to 29 nm and have icosahedral symmetry. Picornaviruses are freed from infected cells by cell lysis [54]. Very little is known about the mechanisms leading to viral persistence in some infected cells.

In 1934 Max Theiler recovered several isolates from the CNS of young mice that had developed spontaneous flaccid paralysis. Inoculation of other mice with these brain-derived isolates produced a similar disease with pathological lesions closely resembling human poliomyelitis [94]. Theiler established the viral nature of these isolates and further demonstrated that surviving paralyzed mice had chronic infection of the CNS [94]. It was later recognized that Theiler viruses may be harbored in the intestinal contents of asymptomatic mice and that virus only rarely spread to the CNS to produce paralytic disease. Isolates from the CNS of paralyzed mice and from stools of asymptomatic mice were able to reproduce experimentally the same CNS paralytic disease as Theiler's original strains, and they are referred to as TO strains of TMEV. They contrast with two other strains of TMEV, GDVII and FA, which are less prevalent in nature and produce an acute encephalitis rather than chronic infection [57].

In 1952 Daniels et al [29] first described myelin destruction in the spinal cord of mice that were sacrificed several months after experimental infection with the DA strain of Theiler virus. Theiler virus encephalomyelitis is therefore one of the very first examples of chronic virus infection of an animal host leading to late pathological changes in the CNS.

Experimental infection of weanling mice with the DA strain of Theiler virus results in a biphasic illness characterized by an acute phase of gray matter inflammation and a chronic phase of white matter degeneration [55]. Only a small percentage of animals die of the acute gray matter disease, while the majority recover from this phase and later develop spastic paralysis indicating white matter destruction. Most mice that enter the phase of chronic white matter degeneration survive for months after infection [55].

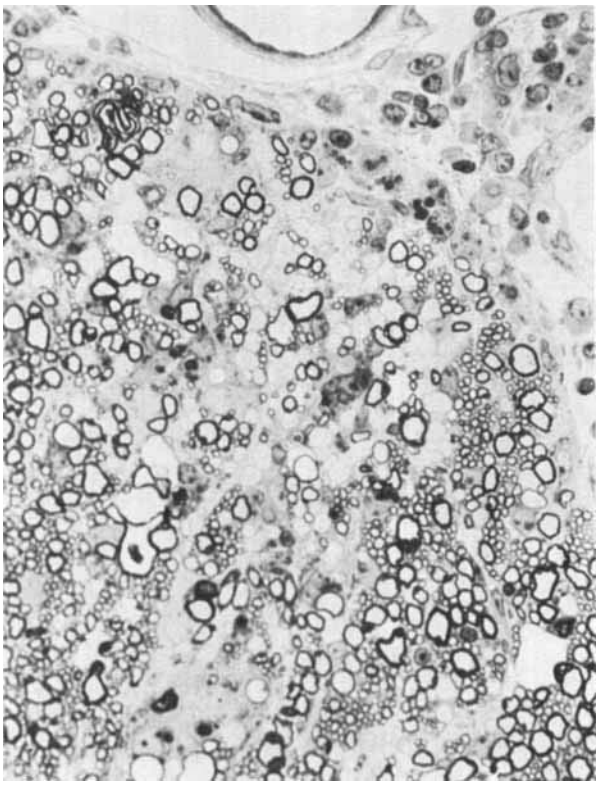

Fig 5. Photomicrograph of 1 μm section from the anterior column of the spinal cord of a mouse showing subarachnoid mononuclear inflammatory infiltrates and numerous naked axons in the superficial white matter. Early lesion, three weeks after infection with the DA strain of Theiler virus. (Toluidine blue; ×420 before 10% reduction.)

Growth of TMEV is essentially limited to the CNS after a very brief initial period of viremia followed by limited growth in extraneural organs. During the first three weeks there is logarithmic growth of virus in the CNS; at this time viral antigen is mainly localized in neurons and their processes, though other types of cells may already be infected [55]. From six weeks to more than a year after inoculation, low levels of infectious virus may still be recovered from the CNS although viral titers steadily decline with time [55]. During the chronic phase of the infection, viral antigen may be observed by ultrastructural immunohistochemical study to be localized in several cells of the spinal cord, i.e., neuronal terminals, astrocytes, inflammatory cells, and especially macrophages in and around white matter lesions [23].

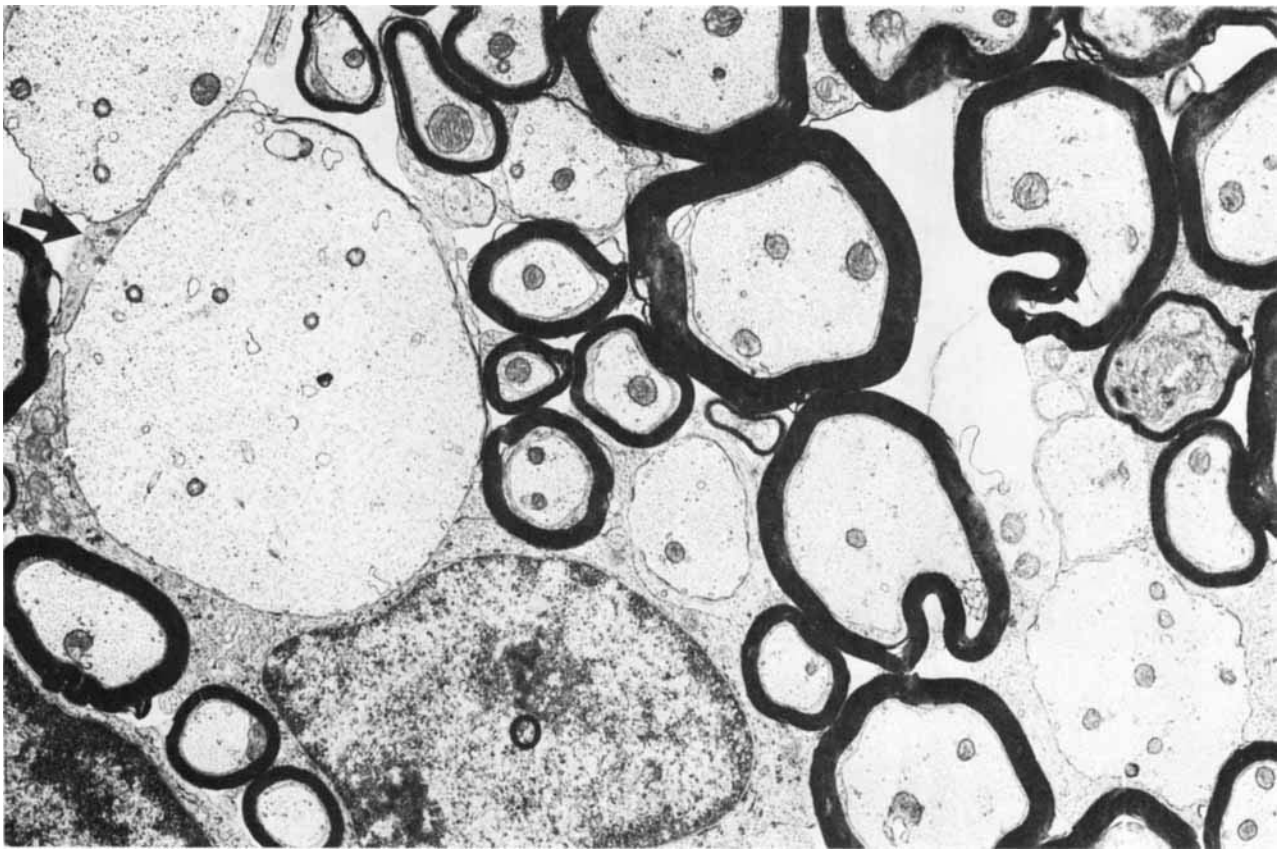

Fig 6. Several large demyelinated axons are observed in this field from the spinal cord of a mouse four weeks after infection with the DA strain of Theiler virus. A lymphoid cell nucleus is visible in the lower left corner. An oligodendrocyte (O) *has a normal nuclear and cytoplasmic appearance. A normal oligodendroglial tongue* (arrow in upper left corner) *is still attached to a large demyelinated axon. (×18,000)*

Pathologically, the first phase of spinal cord gray matter involvement is characterized by areas of focal necrosis, neuronophagia, and mononuclear cell infiltration. These changes are readily observed from the first to the fourth week after infection but decline progressively during the second month. Gray matter changes are rarely seen after six to seven weeks of infection [55]. The first phase of the infection is therefore an acute poliomyelitic disease that appears to be self limiting. The arrest in progression of gray matter lesions correlates temporally with the maximum rise in neutralizing antibody [55]. The second phase of the disease begins two to three weeks after infection and is characterized clinically by development of spastic paralysis of hind limbs. Spinal cord lesions consist of extensive meningeal mononuclear inflammatory infiltrates that extend into the white matter via the Virchow-Robin spaces [21, 55]. In close temporal and anatomical association with these infiltrates, submeningeal and perivascular areas of primary demyelination develop (Figs 5, 6). Ultrastructurally, vesicular disruption of myelin and stripping of myelin sheaths by mononuclear cell processes are the principal mechanisms of myelin destruction [21]. Axons remain essentially normal. These changes are practically identical to those of EAE, the prototype for autoimmune diseases of the CNS [51]. In contrast to JHMV infection, oligodendroglial cells are often observed to be intact in areas rich in demyelinated axons, indicating that oligodendroglial infection is not the primary cause of myelin degeneration (Fig 6) [21]. Ultrastructural immunohistochemical studies have also indicated that oligodendrocytes in and around demyelinating lesions appear to be free of viral antigen [23]. Although a low-level infection of these cells cannot be excluded, it appears that myelin degeneration in this disease is not primarily cytolytic. Immunosuppression studies strongly support this contention. When infected mice are treated with cyclophosphamide, white matter disease is greatly decreased or completely prevented, while gray matter disease is enhanced [56]. This result suggests that whereas gray matter alterations are probably due to primary viral

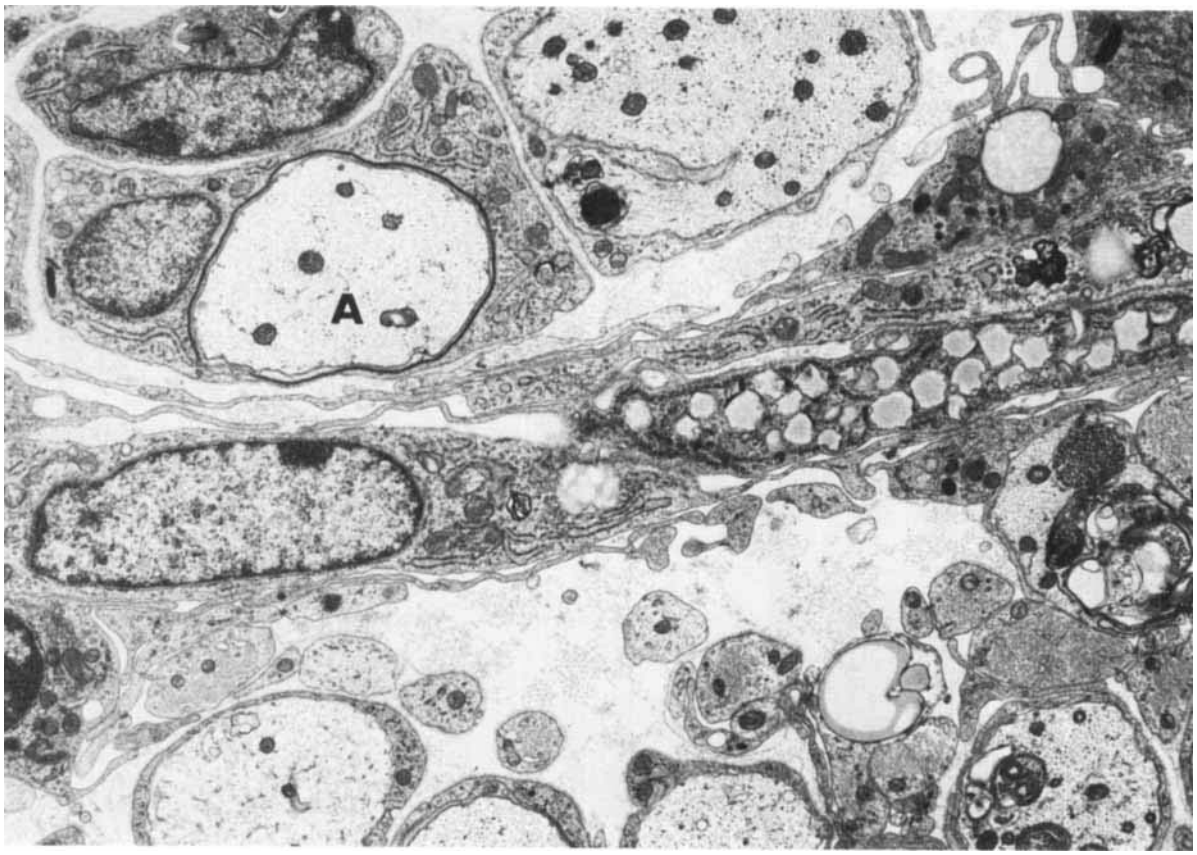

Fig 7. Numerous Schwann cells have invaded the spinal cord of a mouse five weeks after infection with the ww strain of Theiler virus and have contacted demyelinated axons. Remyelination has begun around one such axon (A). *(×12,000)*

cytopathic effects (poliomyelitis-like disease), white matter lesions are dependent on the host immune response [21, 56].

The mechanisms underlying host-mediated virus-induced demyelination in this model are still under investigation. The immune response to TMEV infection is rather peculiar. Although serum neutralizing antibody is present by one week, there is an unusually slow rise in antibody titer, which reaches its peak at around two months after infection and remains at that level for the entire period of the disease [57]. Similarly, the cellular immune response, as measured by in vitro incorporation of [^{3}H]-labeled thymidine into DNA of spleen cells in the presence of ultraviolet-inactivated TMEV antigen, is not detectable until two months after infection. Once established, however, it gradually rises and is present for the entire duration of the disease [81]. The delay in immune responses may be due in part to limited exposure of the immune system to the virus, which replicates only in the CNS. Under these conditions, stimulation of the immune system may be totally dependent on chronic leakage of virus across the blood-brain barrier. Macrophages, which by ultrastructural immunohistochemistry have been observed to contain large amounts of viral antigen in diseased white matter for months after infection, may be instrumental in carrying the virus across the barrier [23].

Recent studies have shown that by changing the strain of the host or by attenuating the virus through cell adaptation, a remitting-relapsing course may be obtained in this infection [22]. Relapses are characterized by new waves of inflammatory demyelination in previously normal white matter or by renewed demyelination of areas that had previously been remyelinated, mostly by invading Schwann cells (Figs 7, 8) [22]. Remyelination of CNS axons by Schwann cells is very prominent in this model. Normal function is probably restored in axons remyelinated by Schwann cells since mice appear completely normal during the remyelinating phase. MS patients have also been shown to have Schwann cell–remyelinated axons in chronic lesions [35]. It is intriguing to speculate that stimulation of Schwann cell activity in demyelinated CNS lesions might result in amelioration of neurological function in MS patients as well.

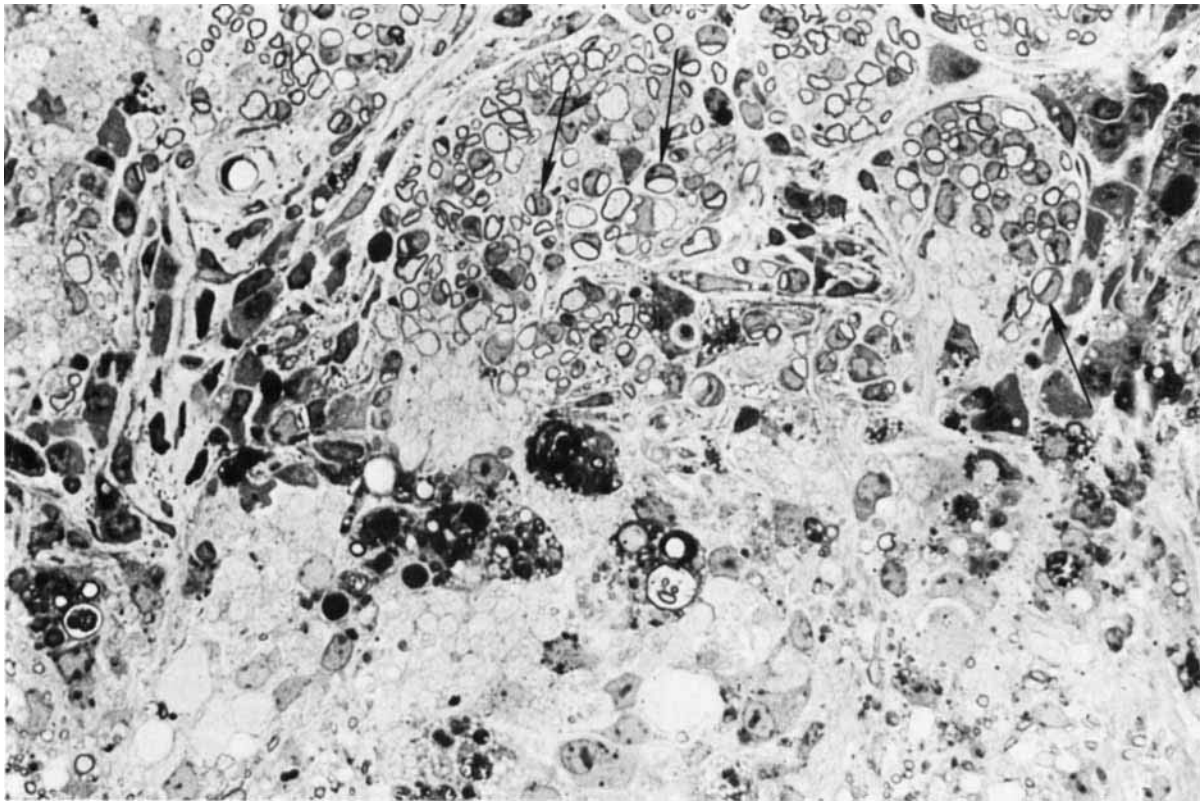

Fig 8. Recurrent demyelinating activity is seen in this 1 μm section from a lesion in the lateral column of the spinal cord of a mouse sacrificed twelve weeks after infection with the ww strain of Theiler virus. The upper portion of the figure shows numerous Schwann cells (arrows) *attached to axons, indicating chronicity of this portion of the lesion. Below this area, axons are seen that have been freshly denuded as evidenced by their being back to back and by the presence of renewed inflammatory and macrophage activity. (Toluidine blue; ×600)*

Ultrastructural immunohistochemical studies have shown that Schwann cells in areas undergoing a second wave of demyelination involving Schwann cell–remyelinated axons are free of viral antigen, while other cells, including macrophages, contain abundant immune reaction product [20]. These results add support to the contention that demyelination in this model is not due to a primary viral attack on the myelinating cells, but rather is dependent on the host immune response.

Relevance to MS

Theiler virus encephalomyelitis is an important model of human disease for the following reasons: (1) it is a persistent infection that develops in the majority of inoculated animals; (2) it utilizes the natural host of TMEV, the mouse, which is the best laboratory animal for immunological, virological, and genetic manipulations; (3) acute lesions are characterized by inflammatory demyelination, as is the case in MS; and (4) the host immune response appears to play a major role in the pathogenesis of myelin injury.

Recent Models

Although the infections described in the preceding sections have been considered the best available experimental viral models of primary demyelination, recent reports have detailed heretofore unexpected evidence indicating that many conventional viruses have the capacity to induce primary demyelination. Among these models are: temperature-sensitive (ts) mutants of vesicular stomatitis virus (VSV); a temperature-sensitive mutant of a human rhabdovirus, Chandipura virus (CV); Venezuelan equine encephalomyelitis virus (VEEV); Semliki Forest virus (SFV); and herpes simplex virus (HSV). While these viral models represent examples of artifically induced diseases, they nevertheless have the potential for advancing our knowledge into mechanisms underlying the production of demyelination. Furthermore, and most important, each viral model appears to represent primary demyelination mediated by immunopathological mechanisms.

Vesicular Stomatitis Virus

Vesicular stomatitis virus is a member of the rhabdovirus family. It is a negative-strand RNA virus with a genome coding for five structural proteins. The virus grows in many tissue culture cells, and substantial research has been done on its mechanisms of replication, maturation, assembly, and genetics [37, 39].

In terms of clinical disease, VSV is a natural pathogen for cattle, producing a benign, self-limited, vesicular eruption [39]. Because the early appearance of the eruption is similar in some respects to that in cattle infected with foot-and-mouth disease virus, VSV infection can be mistaken for this more formidable disease and cattle quarantined until evidence is forthcoming to prove that the infection is benign.

Temperature-sensitive mutants of VSV have been readily produced by mutagenizing standard parental virus and have been extensively studied to unravel the biochemical and genetic events underlying host–virus interaction [79]. Of particular interest in our present discussion is the fact that at least two ts mutants of VSV, ts G41 and ts G32, as part of a complex pathological process, produce primary demyelination.

Inoculation of 3- to 4-week-old Balb/c mice with ts G41 VSV produced in more than 90% a subacute neurological disease initially characterized by the development of lethargy, hunched posture, and ruffled fur within five to seven days after infection [80]. In 60% of infected mice the initial neurological signs proceeded to hind limb paralysis. These signs appeared by seven to ten days after infection and lasted 21 to 28 days. Only 10 to 15% of the mice died as a result of the infection. By four weeks most of the mice had recovered, although up to 10% remained paralyzed. Virus was isolated from brains of infected mice for three weeks after infection, and the recovered virus remained temperature sensitive, ruling out the possibility of revertant virus [80]. Pathologically, ts G41 VSV infection of mice produced a spectrum of abnormalities [26]. By six to seven days after infection, meningitis and diffuse microglial infiltration of the anterior horns of the spinal cord were apparent. Between one and three weeks after infection, numerous foci of primary demyelination developed in the white matter of the spinal cord. These areas of demyelination were associated with inflammatory infiltrates of mononuclear cells [26].

In contrast to the clinical illness caused by ts G41 VSV, ts G32 VSV produced disease in only 50% of infected Balb/c mice. The animals became lethargic about five days after infection, most dying by two weeks. In some less severely affected mice, only hind limb paralysis developed [25]. Pathologically, ts G32 VSV infection also produced both gray and white matter alterations. Infected mice displayed striking inflammation of the gray and white matter and prominent foci of primary demyelination. Again, as in ts G41 VSV infection, areas of demyelination were characterized by strict association with mononuclear inflammatory infiltrates and macrophages [25].

Because demyelination appeared late in the course of both infections, was intimately associated with inflammatory cells, and did not appear to involve oligodendrocyte destruction, speculation arose that the mechanisms for demyelination might be immune mediated. To determine if immune-mediated injury did contribute to demyelination in this model, nude and heterozygous littermates were infected with ts G32 VSV. Heterozygous mice demonstrated pathological alterations indistinguishable from those in Balb/c infected mice. Prominent inflammation and demyelination occurred. Homozygous nude mice, on the other hand, showed no evidence of myelin degeneration and little inflammation [25]. Gray matter disease, however, was enhanced in nude mice, and extensive necrosis occurred. Immunofluorescence studies performed in both heterozygous and nude mice demonstrated viral antigen in white and gray matter of both groups. In fact, in nude mice the amount of viral antigen detected as well as virus titers were greater than in heterozygous littermates, whereas demyelination was found only in heterozygous mice [25]. The studies in nude mice support the hypothesis that immune-mediated injury contributes in a major way to the pathogenesis of primary demyelination in ts G32 VSV infection.

Chandipura Virus

Chandipura virus also is a member of the rhabdovirus family [7]. As such, it is a negative-strand RNA virus that produces infection in a host of tissue culture cell lines and matures by budding from the surface of infected cells.

In contrast to VSV, CV is a human virus. Isolations of CV have been made in India and Africa from the blood of infected individuals, in whom the virus appears to produce a benign, self-limited, febrile illness [7]. To our knowledge, no reports have appeared of pathological studies conducted on tissues of infected persons. As with VSV, CV has been mutagenized in vitro, and clones of ts mutants of this virus have been produced by Gadkari and Pringle [31]. Whereas mice infected with wild-type CV succumbed to infection in three to four days with minimal neurological signs, infection by the ts mutant 472 CV was characterized by a slower disease process, beginning five to seven days after infection and lasting up to three weeks. Most mice demonstrated hind limb paralysis, and all affected mice eventually died.

Pathologically, the most intriguing and important findings were the development of extensive inflam-

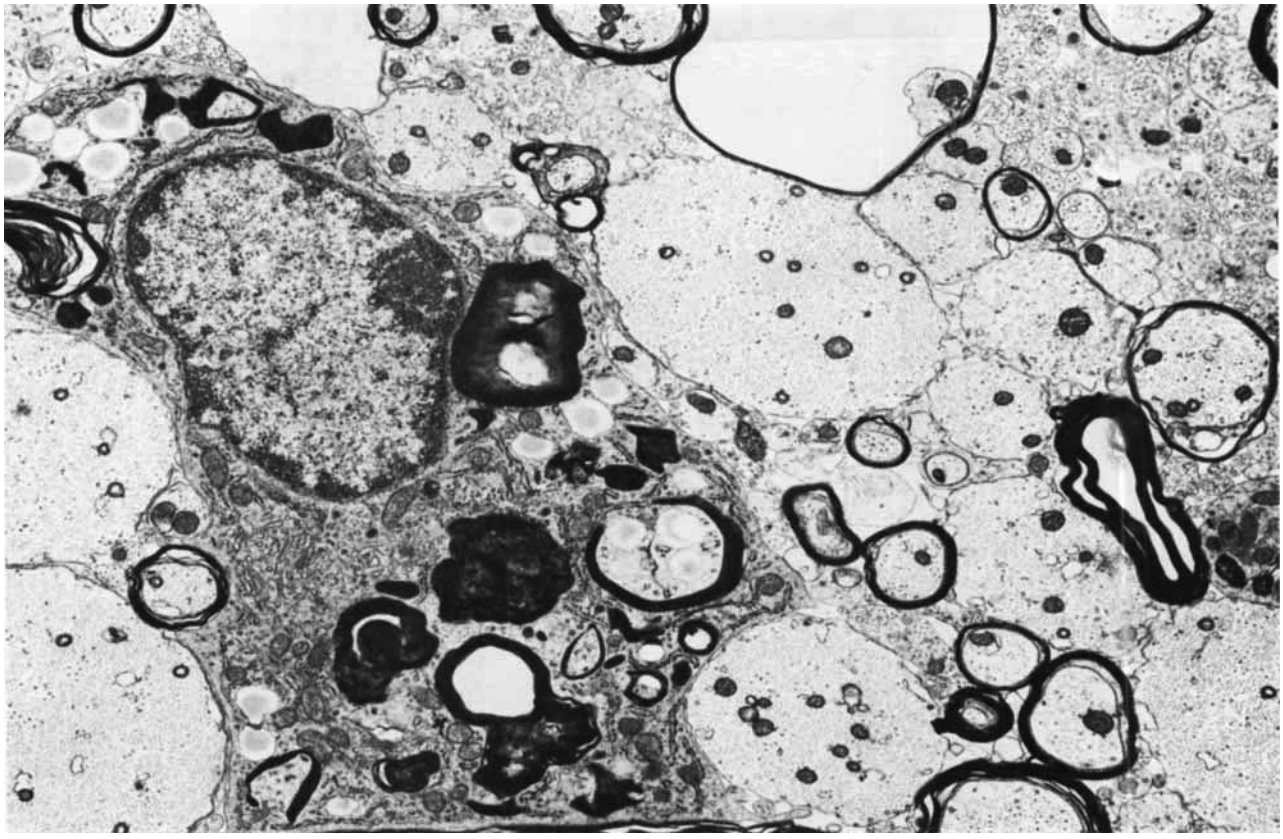

Fig 9. A large macrophage laden with myelin debris is surrounded by numerous demyelinated axons. From the spinal cord of a mouse twelve days after infection with the temperature-sensitive ts 472 mutant strain of Chandipura virus. (×11,800)

matory infiltrates and plaques of demyelination in spinal cord white matter (Fig 9) [27]. Both the time of appearance and the close anatomical relationship between inflammation and myelin injury suggested that ts 472 CV infection was similar to ts G32 VSV and to Theiler virus myelitis in terms of the pathogenesis of primary demyelination [27].

To evaluate this possibility, nude and heterozygous control mice were infected. Heterozygous nude mice showed perivascular mononuclear cell infiltrates in spinal cord white matter with surrounding primary demyelination. Homozygous nude mice, on the other hand, did not show white matter inflammation or demyelination, although, as with ts G32 VSV infection, extensive gray matter degeneration ensued [27]. These findings support the contention that whereas gray matter injury results from direct viral cytolytic activity, a host inflammatory response is required for production of primary demyelination.

Venezuelan Equine Encephalomyelitis Virus

Venezuelan equine encephalomyelitis virus belongs to the family Togaviridae, genus *Alphavirus* (arbovirus group A) [5]. Togaviruses contain a nucleocapsid with cubic symmetry, 20 to 40 nm in diameter, enclosed in a lipid-containing envelope. The virus genome is a continuous molecule of single-stranded RNA with a molecular weight of 4×10^6 daltons. Maturation of the virus occurs in the host cell cytoplasm. Nucleocapsids are formed in association with cell membranes and eventually bud from modified plasma membranes. Nucleocapsids possess antigenic determinants common to viruses of the same group, while the viral envelope contains both virus-specific and cross-reactive antigens [5].

VEEV may cause encephalitis in both animals and humans [53], but it had not been known to produce white matter alterations. Recently, however, extensive primary demyelination was observed in the spinal cords of infected mice starting nine days after infection [24]. Inflammatory cells were intimately associated with degenerating myelin, again suggesting an immunopathological mechanism of myelin injury (Fig 10) [24].

To probe a possible immunopathogenesis of white matter alterations, congenitally athymic nude mice and heterozygous controls were similarly infected.

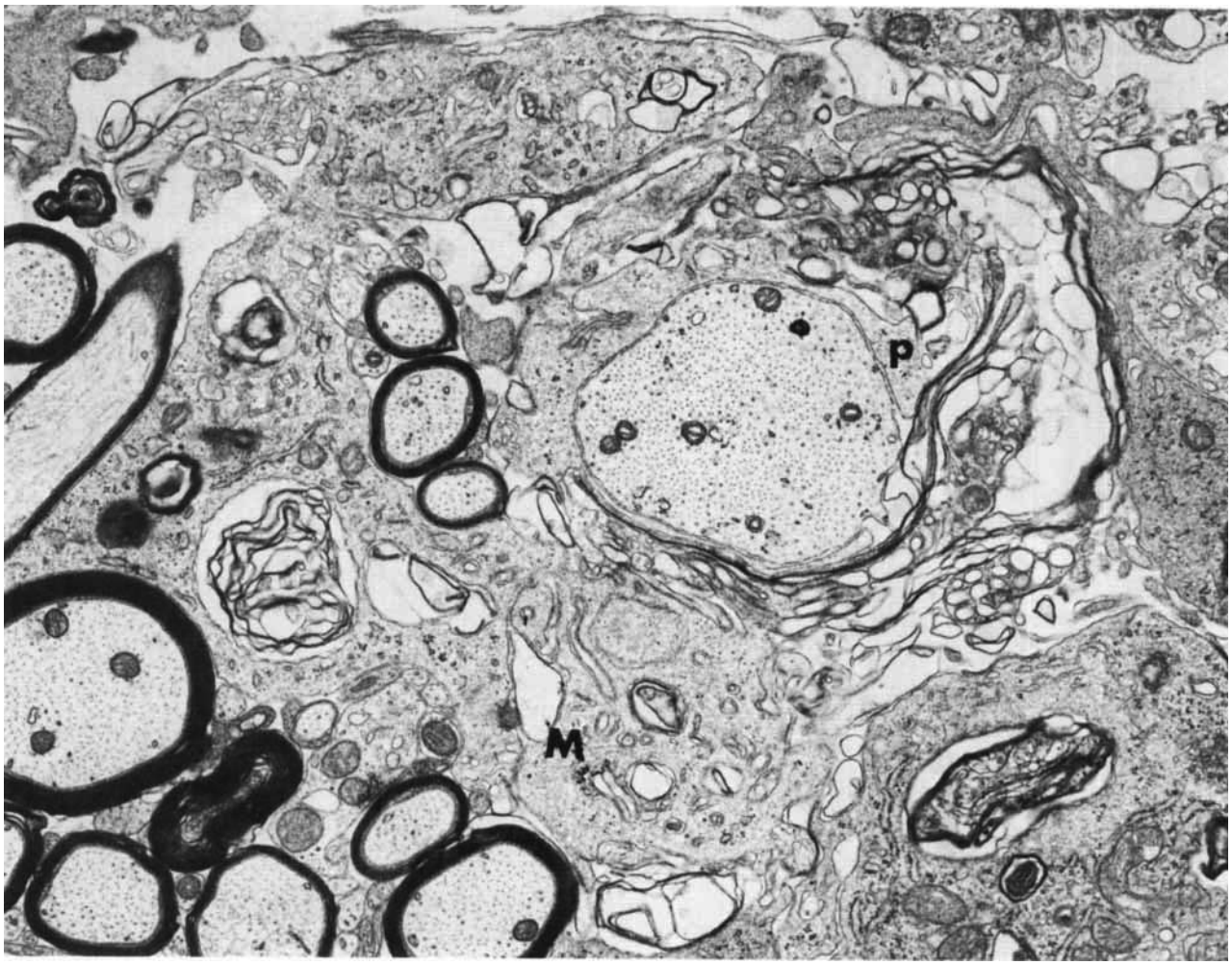

Fig 10. A large axon is undergoing demyelination in the spinal cord of a mouse twelve days after infection with Venezuelan equine encephalomyelitis virus. Note how myelin is stripped away from the axon by a large mononuclear cell process (p), *which probably originates from the mononuclear cell labeled* M. *(×16,000)*

Whereas heterozygous controls demonstrated both necrosis of gray matter and areas of inflammatory demyelination in white matter, nude mice showed only moderate gray matter alterations with no evidence of inflammation or demyelination in white matter [24]. When immunofluorescence studies were performed, nude mice demonstrated a heavier antigenic burden in both gray and white matter than heterozygous controls; absence of primary demyelination could not be explained by lack of viral replication [24]. These studies support the contention that white matter changes in VEEV infection depend upon the host immune response rather than being produced by primary viral cytopathic effect.

Semliki Forest Virus

Semliki Forest virus is an arbovirus of the family Togaviridae and belongs to the same *Alphavirus* genus as VEEV [5]. SFV and VEEV therefore have similar morphological and physicochemical characteristics.

In contrast to VEEV, SFV does not appear to be associated with any known illness of humans [5]. The virulent wild-type virus causes a fatal encephalitis in young mammals [8]. Infection of adult mice with the A774 avirulent strain of SFV, on the other hand, produces a focal, self-limiting encephalitis that is usually subclinical [16]. Demyelination has recently been shown to be a feature of infection by this avirulent strain. Lesions were focal and were randomly distributed in the brain by ten days after inoculation [16].

The pathogenesis of demyelination in SFV infection is controversial. A direct viral cytopathic effect on oligodendrocytes has been suggested by some investigators [86], while others have implicated the host immune response in the pathogenesis of the

CNS lesions, including demyelination [93]. In a recent study, demyelinating lesions were usually seen to be associated with mononuclear infiltrates rich in lymphocytes. A close anatomical association between lymphocytic processes and astrocytes or macrophages was interpreted as supporting evidence for immune-mediated myelin injury [42]. Experiments in nude mice also support this contention, as SFV-induced demyelination was reported to be less severe in these animals than in normal mice [40].

Relevance to MS

These recent models are important primarily because of the following characteristics: (1) they are examples of possible immune-mediated primary demyelination produced by conventional viruses; (2) they employ viruses that differ widely in their biochemistry, genetics, and replicative cycle; and (3) they involve murine hosts in which extensive data on host immune processes and genetics are available. Among the limitations of these models are that: (1) infection occurs in an unnatural host; (2) none of these infections are chronic or characterized by a relapsing and remitting course; and (3) in many of these infections demyelination is part of a complex pathological picture.

Herpes Simplex Virus

Up to this point only RNA viruses capable of producing primary demyelination experimentally have been discussed. A recent model employing the DNA virus herpes simplex will now be reviewed.

HSV belongs to the family Herpetoviridae [2]. Two types, HSV1 and HSV2, have been recognized, the first usually being responsible for herpes labialis and the second for genital infections. HSV has an icosahedral capsid, 85 to 110 nm in diameter, that comprises 162 capsomers. The capsid contains a core that appears as a ring of DNA surrounding a protein plug. The capsid is surrounded by a tegument that is wrapped in an envelope. Spikes project from the envelope to the outside. Virus development begins in the nucleus and continues in the cytoplasm until maturation by budding occurs. Cell-to-cell transfer of viral particles is common. The viral genome is made of double-stranded, linear DNA molecules [2].

Inoculation of the Rodanus strain of type 1 HSV into the cornea of mice and rabbits resulted in an ascending infection of the trigeminal nerve that reached the root–CNS transition in three to four days [95]. As soon as the infection reached the CNS portion of the trigeminal root entry zone, severe myelin destruction ensued accompanied by mononuclear inflammatory cell infiltration. In contrast, no demyelination was observed in the peripheral portion of the root entry zone or in the trigeminal nerve [95]. By immunofluorescence, viral antigen was rarely seen in trigeminal ganglion neurons, while it was always present in the CNS portion of the root entry zone as early as four to six days after inoculation. Astrocytes appeared to be the most heavily infected cells, but oligodendrocytes were also affected [95].

Immunosuppression of mice with cyclophosphamide prior to infection caused a marked reduction of mononuclear infiltrates in the CNS accompanied by a decrease in myelin destruction when compared with infected nonimmunosuppressed controls [96]. Both groups of animals showed comparable viral titers and serum neutralizing antibodies.

From these studies the authors concluded that the cellular immune response plays a definitive role in the process of myelin destruction in this animal model of HSV infection.

Relevance to MS

In contrast to other models of virus-induced demyelination, the HSV model is characterized by a single lesion in a well-defined, predictable site. The model lacks the multicentric nature of the demyelination found in both MS and the other experimental diseases. On the other hand, the fact that HSV is a ubiquitous virus in humans together with its known predilection for establishing latent infection makes potentially important the observations relative to its capacity of producing primary demyelination.

Discussion

From the models presented, it appears that viruses possess the capacity to cause widespread and extensive myelin destruction. At least two different mechanisms may be involved in the production of demyelination in viral infections. First, a direct viral cytopathic effect on oligodendrocytes can occur. JHMV encephalomyelitis of mice is the prototypic example of such a mechanism. A second mechanism, involving host immune reactivity to virus or CNS antigens, appears to play a major role in other models. Theiler virus encephalomyelitis may be the best example of such immune-mediated injury. In most infections, both mechanisms probably operate but their relative role varies. Since participation of the host immune system appears to play an important role in MS, models based on combined virus-immune pathogenesis may be especially relevant to human disease.

There could be several mechanisms of virus-induced myelin injury by an immune pathogenesis. First, viral antigenic material could be inserted into the plasma membranes of oligodendrocytes, which in turn could be damaged by the ensuing host antiviral immune attack. This is not likely to happen in Theiler

virus infection, as picornaviruses do not bud from cells. Second, virus and myelin could share some antigenic determinants. Although cross reactivity has been demonstrated between measles virus and myelin basic protein [71], this is unlikely to be the case with several different and unrelated viruses. Third, virus could cause primary myelin injury that would lead to release of free myelin antigenic material. The resulting series of events would be quite similar to EAE. Although this appears to be an attractive possibility, data exist which are not supportive. For example, experiments measuring cell-mediated immune responses to myelin basic protein in Theiler virus infection have given inconclusive results (unpublished data), in contrast to studies of EAE [73, 74]. Finally, in addition to the foregoing classic theories, considerable attention has been devoted in the last few years to the possibility that myelin may be damaged as an innocent bystander in the midst of an immune reaction against unrelated antigens. This concept originates from work done in 1968 by Ruddle and Waksman [85], who demonstrated nonspecific bystander killing of rat embryo fibroblasts in the presence of heterologous antigen and sensitized lymphoid cells. More recently, Wisniewski and Bloom [100] extended this concept to the CNS in vivo. They demonstrated primary demyelination following local injection of purified protein derivative in the spinal cord of guinea pigs previously sensitized to that antigen. It has been proposed that a similar mechanism may operate in viral infections, in which virus would act as the target antigen and myelin would be nonspecifically damaged by a surrounding antiviral immunological attack [21, 56, 99]. Such a mechanism of nonspecific myelin injury is supported by recent in vitro studies that demonstrated myelin vulnerability in the presence of neutral proteases, including plasminogen activator, secreted by nonspecifically activated macrophages [12]. The ultrastructural feature of vesicular disruption of myelin, often observed in demyelinating models, might well be the morphological expression of such biochemical events [28]. A mechanism of bystander injury in viral infections is particularly attractive because the various models described by different investigators employ viruses that are largely unrelated to each other. The host immune response therefore could represent the unifying factor behind the capacity of different viruses to cause similar pathological alterations in the CNS white matter.

Primary demyelination in response to a range of viruses may not be an unusual or rare event, but may represent a common consequence of the resolution of many viral infections. The clinical expression of diseases like MS may require multiple virological attacks engrafted on the appropriate immunological and genetic milieu.

Supported by Grants NS-13011 and NS-13045 from the National Institutes of Health and by a grant from the Kroc Foundation.

The expert technical assistance of Jannie Tong, Jayashree Huprikar, and Mary Grover as well as the secretarial assistance of Nancy Starks are gratefully acknowledged.

References

1. Alter M, Leibowitz U, Speer J: Risk of multiple sclerosis related to age at immigration to Israel. Arch Neurol 15:234–237, 1966
2. Andrewes CH, Pereira HG, Wildy P: Herpetoviridae. In Andrewes CH, Pereira HG, Wildy P (eds): Viruses of Vertebrates. Fourth edition. London, Bailliere Tindall, 1978, pp 312–355
3. Andrewes CH, Pereira HG, Wildy P: Paramyxoviridae. In Andrewes CH, Pereira HG, Wildy P (eds): Viruses of Vertebrates. Fourth edition. London, Bailliere Tindall, 1978, pp 221–254
4. Andrewes CH, Pereira HG, Wildy P: Retroviridae. In Andrewes CH, Pereira HG, Wildy P (eds): Viruses of Vertebrates. Fourth edition. London, Bailliere Tindall, 1978, pp 133–165
5. Andrewes CH, Pereira HG, Wildy P: Togaviridae. In Andrewes CH, Pereira HG, Wildy P (eds): Viruses of Vertebrates. Fourth edition. London, Bailliere Tindall, 1978, pp 67–118
6. Appel MJG: Pathogenesis of canine distemper. Am J Vet Res 30:1167–1182, 1969
7. Bhatt PN, Rodrigues FM: Chandipura, a new rhabdovirus isolated in India from patients with febrile illness. Ind J Med Res 55:1295–1305, 1976
8. Bradish CJ, Allner K, Maber HB: The virulence of original and derived strains of Semliki Forest virus for mice, guinea pigs and rabbits. J Gen Virol 12:141–160, 1971
9. Burks JS, DeVald BL, Jankovsky LD, Gerdes JC: Two coronaviruses isolated from central nervous system tissue of two multiple sclerosis patients. Science 209:933–934, 1980
10. Burridge MJ: Multiple sclerosis, house pets and canine distemper: critical review of recent reports. J Am Vet Med Assoc 173:1439–1444, 1978
11. Bussell RH, Waters DJ, Seals MK: Measles, canine distemper and respiratory syncytial virions and nucleocapsids. A comparative study of their structure, polypeptide and nucleic acid composition. Med Microbiol Immunol 160:105–124, 1974
12. Cammer W, Bloom BR, Norton WT, Gordon S: Degradation of basic protein in myelin by neutral proteases secreted by stimulated macrophages: a possible mechanism of inflammatory demyelination. Proc Natl Acad Sci USA 75:1554–1558, 1978
13. Carp RI, Licursi PC, Merz PA, Merz GS: Decreased percentage of polymorphonuclear neutrophils in mouse peripheral blood after inoculation with material from multiple sclerosis patients. J Exp Med 136:618–629, 1972
14. Carpenter S, Lampert PW: Postinfectious perivenous encephalitis and acute hemorrhagic leukoencephalitis. In Minckler J (ed): Pathology of the Nervous System. New York, McGraw-Hill, 1972, pp 2260–2269
15. Cheever FS, Daniels JB, Pappenheimer AM, Bailey OT: A

murine virus (JHM) causing disseminated encephalomyelitis with extensive destruction of myelin. I. Isolation and biological properties of the virus. J Exp Med 90:181–194, 1949
16. Chew-Lim M, Suckling AJ, Webb HE: Demyelination in mice after two or three infections with avirulent Semliki Forest virus. Vet Pathol 14:67–72, 1977
17. Ciongoli AK, Lisak RP, Zweiman B, Koprowski H, Waters D: *In vitro* cellular responsiveness in multiple sclerosis patients to a purified measles virus nuclear core and to other viral antigens. J Neurol Sci 28:331–338, 1976
18. Cook SD, Dowling PC: A possible association between house pets and multiple sclerosis. Lancet 1:980–982, 1977
19. Cook SD, Dowling PC, Russell WC: Neutralizing antibodies to canine distemper and measles virus in multiple sclerosis. J Neurol Sci 41:61–70, 1979
20. Dal Canto MC: Uncoupled relationship between demyelination and primary infection of myelinating cells in Theiler's virus encephalomyelitis. Infect Immun (in press)
21. Dal Canto MC, Lipton HL: Primary demyelination in Theiler's virus infection: an ultrastructural study. Lab Invest 33:626–637, 1975
22. Dal Canto MC, Lipton HL: Schwann cell remyelination and recurrent demyelination in the central nervous system of mice infected with attenuated Theiler's virus. Am J Pathol 98:101–122, 1980
23. Dal Canto MC, Lipton HL: Ultrastructural immunohistochemical demonstration of Theiler's virus in acute and chronic Theiler's demyelinating encephalomyelitis. Am J Pathol (in press)
24. Dal Canto MC, Rabinowitz SG: Central nervous system demyelination in Venezuelan equine encephalomyelitis infection. An experimental model of virus-induced myelin injury. J Neurol Sci 49:397–418, 1981
25. Dal Canto MC, Rabinowitz SG: Murine central nervous system infection by a viral temperature-sensitive mutant. Am J Pathol 102:412–426, 1981
26. Dal Canto MC, Rabinowitz SG, Johnson TC: Subacute infection with temperature-sensitive vesicular stomatitis virus mutant G41 in the central nervous system of mice. II. Immunofluorescent, morphologic and immunologic studies. J Infect Dis 139:36–51, 1979
27. Dal Canto MC, Rabinowitz SG, Johnson TC: Virus-induced demyelination. Production by a viral temperature-sensitive mutant. J Neurol Sci 42:155–168, 1979
28. Dal Canto MC, Wisniewski HM, Johnson AB, Brostoff SW, Raine CS: Vesicular disruption of myelin in autoimmune demyelination. J Neurol Sci 24:313–319, 1975
29. Daniels JB, Pappenheimer AM, Richardson S: Observations on encephalomyelitis of mice (DA strain). J Exp Med 96:517–530, 1952
30. Fleury HJA, Sheppard RD, Bornstein MB, Raine CS: Further ultrastructural observations of virus morphogenesis and myelin pathology of JHM virus encephalomyelitis. Neuropathol Appl Neurobiol 6:165–179, 1980
31. Gadkari DA, Pringle CR: Temperature-sensitive mutants of Chandipura virus. I. Inter- and intragroup complementation. J Virol 33:100–106, 1980
32. Georgsson G, Martin JR, Klein J, Palsson PA, Nathanson N, Petursson G: Primary demyelination in visna. An ultrastructural study of Icelandic sheep with clinical signs following experimental infection. Submitted for publication
33. Georgsson G, Nathanson N, Palsson PA, Petursson G: The pathology of visna and maedi in sheep. In Kimberlin RH (ed): Slow Virus Disease of Animals and Man. Amsterdam and New York, North-Holland, 1976, pp 61–96
34. Georgsson G, Palsson PA, Panitch H, Nathanson N, Petursson G: The ultrastructure of early visna lesions. Acta Neuropathol (Berl) 37:127–135, 1977
35. Ghatak NR, Hirano A, Doron Y, Zimmerman HM: Remyelination in multiple sclerosis with peripheral type myelin. Arch Neurol 29:262–267, 1973
36. Harter DH: The detailed structure of visna-maedi virus. In Kimberlin RH (ed): Slow Virus Diseases of Animals and Man. Amsterdam and New York, North-Holland, 1976, pp 45–60
37. Haspel MV, Duff R, Rapp F: Experimental measles encephalitis: a genetic analysis. Infect Immun 12:785–790, 1975
38. Herndon RM, Griffin DE, McCormick U, Weiner LP: Mouse hepatitis virus–induced recurrent demyelination. Arch Neurol 32:32–35, 1975
39. Howatson AF: Vesicular stomatitis and related viruses. Prog Virol 25:195–256, 1973
40. Jagelman S, Suckling AJ, Webb HE, Bowen ETW: The pathogenesis of avirulent Semliki Forest virus infection in athymic nude mice. J Gen Virol 41:599–607, 1978
41. Johnson RT, Weiner LP: The role of viral infections in demyelinating diseases. In Wolfgram F, Ellison G, Stevens J, Andrews J (eds): Multiple Sclerosis. New York and London, Academic, 1972, pp 245–264
42. Kelly WR, Blakemore WF, Jagelman S, Webb HE: An EM study of the focal demyelinating lesions in the mouse CNS during 29 days after an IP injection of avirulent Semliki Forest virus. J Neuropathol Appl Neurobiol (in press)
43. Koestner A, Long JF: Ultrastructure of canine distemper virus in explant tissue cultures of canine cerebellum. Lab Invest 23:196–201, 1970
44. Krakowka S, McCullough B, Koestner A, Olsen RG: Myelin specific autoantibodies associated with central nervous system demyelination in canine distemper infection. Infect Immun 8:819–827, 1973
45. Krakowka S, Koestner A: Age-related susceptibility to infection with canine distemper virus in gnotobiotic dogs. J Infect Dis 134:629–632, 1976
46. Krakowka S, Koestner A: Canine distemper virus and multiple sclerosis. Lancet 1:1127–1128, 1978
47. Krakowka S, Mador RA, Koestner A: Canine distemper virus–associated encephalitis: modification by passive antibody administration. Acta Neuropathol (Berl) 43:235–241, 1978
48. Kurland L, Brian D: Multiple sclerosis and canine pets. Ann Neurol 3:97–100, 1978
49. Kurtzke JF, Hyllested K: Multiple sclerosis in the Faroe Islands: I. Clinical and epidemiological features. Ann Neurol 5:6–21, 1979
50. Lampert PW: Autoimmune and virus-induced demyelinating diseases. A review. Am J Pathol 91:176–208, 1978
51. Lampert PW, Carpenter S: Electron microscopic studies on the vascular permeability and the mechanisms of demyelination in experimental allergic encephalomyelitis. J Neuropathol Exp Neurol 24:11–24, 1965
52. Lampert PW, Sims JK, Kniazeff AJ: Mechanism of demyelination in JHM virus encephalomyelitis. Electron microscopic studies. Acta Neuropathol (Berl) 24:76–85, 1973
53. Leon CA, Jaramillo R, Martinez S, Fernandez F, Teller H, Lasso B, De Guzman R: Sequelae of Venezuelan equine encephalitis in humans: a four-year follow-up. Int J Epidemiol 4:131–140, 1975
54. Levintow L: Reproduction of picornaviruses. Comp Virol 2:109–169, 1976
55. Lipton HL: Theiler's virus infection in mice: an unusual

biphasic disease process leading to demyelination. Infect Immun 11:1147–1155, 1975
56. Lipton HL, Dal Canto MC: Theiler's virus–induced demyelination. Prevention by immunosuppression. Science 192:62–64, 1976
57. Lipton HL, Dal Canto MC, Rabinowitz SG: Chronic Theiler's virus infection in mice. Microbiology 1977:505–508, 1977
58. Lipton HL, Friedman A: Purification of Theiler's murine encephalomyelitis virus and analysis of the structural virion polypeptides: correlation of the polypeptide profile with virulence. J Virol 33:1165–1172, 1980
59. Lumsden CE: Multiple sclerosis. In Vinken PJ, Bruyn GW (eds): Amsterdam and New York, North-Holland, 1970, pp 217–309
60. Lyons MJ, Hall WW, Petito C, Cam V, Zabriskie JB: Induction of chronic neurologic disease in mice with canine distemper virus. Neurology (NY) 30:92–98, 1980
61. Martin JR, Nathanson N: Animal models of virus-induced demyelination. In Zimmerman HM (ed): Progress in Neuropathology. New York, Raven, 1979, pp 27–50
62. McCullough B, Krakowka S, Koestner A: Experimental canine distemper virus–induced demyelination. Lab Invest 31:216–222, 1974
63. McCullough B, Krakowka S, Koestner A, Shadduck J: Demyelinating activity of canine distemper virus isolates in gnotobiotic dogs. J Infect Dis 130:343–350, 1974
64. Nagashima K, Wege H, Meyermann R, ter Meulen V: Demyelinating encephalomyelitis induced by a long-term corona virus infection in rats. Acta Neuropathol (Berl) 45:205–213, 1979
65. Narayan O, Griffin DE, Chase J: Antigenic drift of visna virus in persistently infected sheep. Science 197:376–378, 1977
66. Nathanson N, Panitch H, Palsson PA, Petursson G, Georgsson G: Pathogenesis of visna. II. Effect of immunosuppression upon early central nervous system lesions. Lab Invest 35:444–451, 1976
67. Nathanson N, Petursson G, Georgsson G, Palsson PA, Martin JR, Miller A: Pathogenesis of visna. IV. Spinal fluid studies. J Neuropathol Exp Neurol 38:197–208, 1979
68. Norrby E, Link H, Olsson JE, Panelius M, Salmi A, Vandvik B: Comparison of antibodies against different viruses in cerebrospinal fluid and serum samples from patients with multiple sclerosis. Infect Immun 10:688–694, 1974
69. Olsson JE, Link H: Immunoglobulin abnormalities in multiple sclerosis. Relation to clinical parameters: exacerbations and remissions. Arch Neurol 28:392–399, 1973
70. Palsson PA: Maedi and visna in sheep. In Kimberlin RH (ed): Slow Virus Diseases of Animals and Man. Amsterdam and New York, North-Holland, 1976, pp 17–43
71. Panitch HS, Swoveland P, Johnson KP: Antibodies to measles virus react with myelinic basic protein. Neurology (NY) 29:548–549, 1979
72. Pasteur L: Méthode pour prévenir la rage après morsure. C R Acad Sci (Paris) 101:765–774, 1885
73. Paterson PY: The demyelinating diseases: clinical and experimental studies in animals and man. In Samter M, Alexander N, Rose B, Sherman WB, Talmage DW, Vaughn JH (eds): Immunological Diseases. Boston, Little, Brown, 1978, pp 1400–1435
74. Paterson PY: Neuroimmunologic diseases of animals and humans. Rev Infect Dis 1:468–482, 1979
75. Petursson G, Nathanson N, Georgsson G, Panitch H, Palsson PA: Pathogenesis of visna I. Sequential virologic, serologic and pathologic studies. Lab Invest 35:402–412, 1976
76. Petursson G, Nathanson N, Palsson PA, Martin J, Georgsson G: Immunopathogenesis of visna. A slow virus disease of the central nervous system. Acta Neurol Scand 57 [Suppl 67]:205–219, 1978
77. Powell HC, Lampert PW: Oligodendrocytes and their myelin–plasma membrane connections in JHM mouse hepatitis virus encephalomyelitis. Lab Invest 33:440–445, 1975
78. Prineas JW: The etiology and pathogenesis of multiple sclerosis. In Vinken PJ, Bruyn GW (eds): Handbook of Clinical Neurology. Amsterdam and New York, North-Holland, 1970, pp 107–160
79. Pringle CR: Genetic characteristics of conditional lethal mutants of vesicular stomatitis virus induced by 5-fluorouracil, 5-azacytidine and ethyl methane sulfonide. J Virol 5:559–567, 1970
80. Rabinowitz SG, Johnson TC, Dal Canto MC: Subacute infection with temperature-sensitive vesicular stomatitis virus mutant G41 in the central nervous system of mice. I. Clinical and virological studies. J Infect Dis 139:26–35, 1979
81. Rabinowitz SG, Lipton HL: Cellular immunity in chronic Theiler's virus central nervous system infection. J Immunol 117:357–363, 1976
82. Raine CS: Experimental allergic encephalomyelitis and related conditions. In Zimmerman HM (ed): Progress in Neuropathology. New York, Grune & Stratton, 1976, pp 225–251
83. Raine CS: On the development of CNS lesions in natural canine distemper encephalomyelitis. J Neurol Sci 30:13–28, 1976
84. Robb JA, Bond CW: Coronaviridae. In Fraenkel-Conrat H, Wagner RR (eds): Comprehensive Virology. New York, Plenum, 1979, vol 14, pp 193–247
85. Ruddle NH, Waksman BH: Cytotoxicity mediated by soluble antigen and lymphocytes in delayed hypersensitivity, Part 1 (characterization of the phenomenon). J Exp Med 128:1237–1254, 1968
86. Sheahan BJ, Barrett PN, Atkins GJ: Demyelination in mice resulting from infection with a mutant of Semliki Forest virus. Acta Neuropathol (Berl) 53:129–136, 1981
87. Sheremata W, Cosgrove JBR, Eylar EH: Cellular hypersensitivity to basic myelin (A1) protein and clinical multiple sclerosis. N Engl J Med 291:14–17, 1974
88. Sigurdsson B: Rida, a chronic encephalitis of sheep. Br Vet J 110:341–354, 1954
89. Stohlman SA, Frelinger JA, Weiner LP: Resistance to fatal central nervous system disease by mouse hepatitis virus, strain JHM. II. Adherent cell-mediated protection. J Immunol 124:1733–1739, 1980
90. Stohlman SA, Weiner LP: Stability of neurotropic mouse hepatitis virus (JHM strain) during chronic infection of neuroblastoma cells. Arch Virol 57:53–61, 1978
91. Stohlman SA, Weiner LP: Chronic central nervous system demyelination in mice after JHM virus infection. Neurology (NY) 31:38–44, 1981
92. Storts RW, Koestner A, Dennis RA: The effects of canine distemper virus on explant tissue cultures of canine cerebellum. Acta Neuropathol (Berl) 1:1–14, 1968
93. Suckling AJ, Pathak S, Jagelman S, Webb HE: Virus-associated demyelination. A model using avirulent Semliki Forest virus infection of mice. J Neurol Sci 39:147–154, 1978
94. Theiler M: Spontaneous encephalomyelitis of mice, a new virus disease. J Exp Med 65:705–719, 1937
95. Townsend JJ, Baringer JR: Central nervous system susceptibility to herpes simplex virus infection. J Neuropathol Exp Neurol 37:255–262, 1978

96. Townsend JJ, Baringer JR: Morphology of central nervous system disease in immunosuppressed mice after peripheral herpes simplex virus inoculation. Trigeminal root entry zone. Lab Invest 40:178–182, 1979
97. Weiner LP: Pathogenesis of demyelination induced by a mouse hepatitis virus (JHM virus). Arch Neurol 28:298–303, 1973
98. Wisniewski H, Raine CS, Kay WJ: Observations on viral demyelinating encephalomyelitis. Canine distemper. Lab Invest 26:589–599, 1972
99. Wisniewski HM: Immunopathology of demyelination in autoimmune diseases and virus infections. Br Med Bull 33:54–59, 1977
100. Wisniewski HM, Bloom BR: Primary demyelination as a non-specific consequence of a cell-mediated immune reaction. J Exp Med 141:346–359, 1975

Erratum

In the article "Myelin basic protein in Alzheimer disease neuronal fractions and mammalian neurofilament preparations," by Selkoe, Brown, Salazar, and Marotta (Ann Neurol 10:429–436, 1981), the gel photographs for Figures 2 and 5 were interchanged. The *Annals* regrets this error. The correct figures are reproduced here.

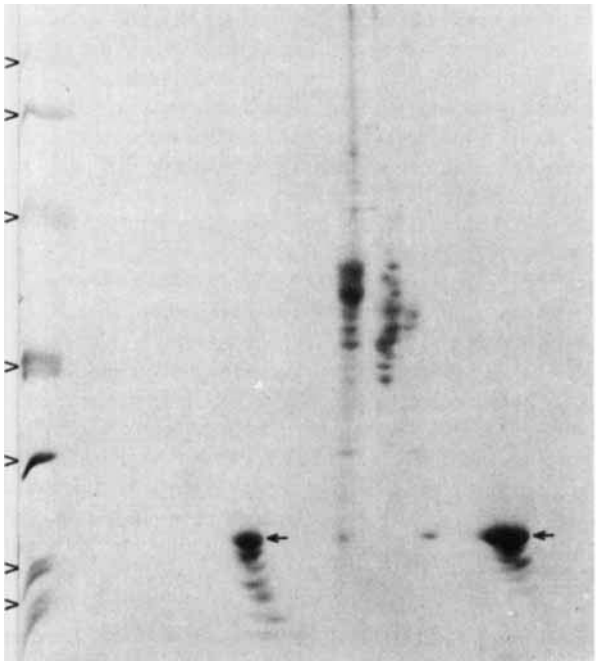

Fig 2. Two-dimensional electrophoretic comparison of purified human myelin basic protein (A) *and human neurofilament fraction* (B) *on the same slab gel. The major 20K proteins* (arrows) *have the same two-dimensional coordinates. The migration patterns of several minor polypeptides (MW 12,000 to 19,000) present in each preparation are also the same. Arrowheads identify molecular weight standards (from top): 117K, 94K, 68K, 43K, 30K, 21K (soybean trypsin inhibitor), and 14.3K.*

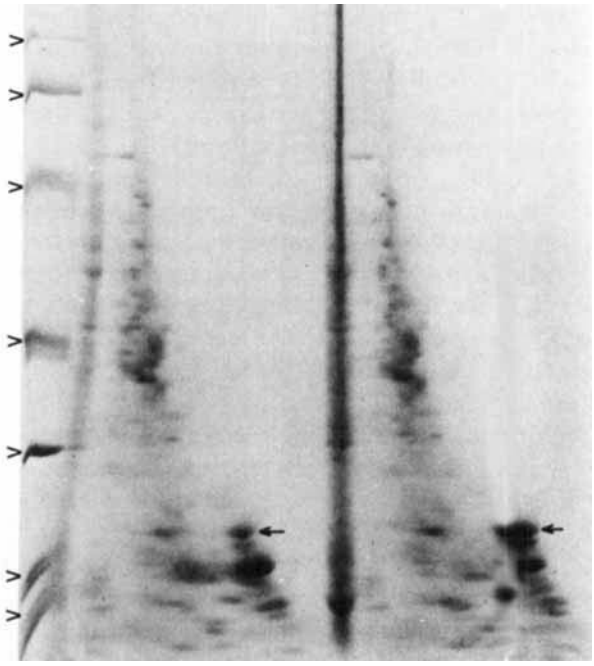

Fig 5. Two-dimensional electrophoretic comparison of matched control (A) *and Alzheimer* (B) *neuronal fractions on the same slab gel. The P20 protein* (arrows) *is markedly increased in the Alzheimer fraction. The two-dimensional coordinates of P20 are the same as those of purified myelin basic protein and the 20K protein of neurofilament fractions (compare Fig 2). Molecular weight standards as in Figure 2.*