

Brief Communication

Outcome of repeat penetrating keratoplasty in eyes with failed penetrating keratoplasty

Abdulrahman S. Khairallah, MD.

ABSTRACT

Objectives: To report the outcomes of penetrating keratoplasty (PKP) surgeries in eyes with failed PKP.

Methods: This was a retrospective, non-comparative, descriptive case series. Thirty eyes of 30 patients with failed PKP comprised our study group, they were reviewed from January 2007 to December 2012 at the King Khaled Eye Specialist Hospital, Riyadh, Kingdom of Saudi Arabia. Data were collected on best corrected visual acuity before and after one week, one month, 3 months, 6 months, one year, and 2 years following PKP. Intraoperative and postoperative complications, changes in intraocular pressure (IOP), additional surgical procedure and other ocular comorbidities were also documented. The visual outcomes at 6 months and one year were associated with risk factors.

Results: Before intervention, 18 (60%) eyes had vision <20/400. Vision was 20/20 to 20/60 in 10 (30%) eyes at 6 months, 17 (57%) eyes at 12 months, and 22 (73%) eyes at 24 months. The variation in IOP at different follow up periods was not significant ($p=0.2$). The presence of other ocular comorbidity was not significantly associated with functional visual outcome ($p=0.4$). Additional surgical procedure after repeat PKP enabled a regain of excellent vision in 9 (47%) eyes at one year. The numbers for past corneal surgeries were significantly associated with the visual outcome at 6 months.

Conclusion: Penetrating keratoplasty to manage failed PKP resulted in reducing visual disabilities.

*Saudi Med J 2016; Vol. 37 (9): 1029-1032
doi: 10.15537/smj.2016.9.14075*

Although corneal transplant is the most common organ transplant, long-term outcomes are not always favorable. The rejection rate was reported to be as high as 30% after 5 years of a successful keratoplasty.¹ Immunosuppressive strategies in the high risk group has helped in reducing this rejection rate, although repeat keratoplasty is often needed.² The success of repeat keratoplasty depends on the number of previous failed surgeries, an indication for keratoplasty and the approach used for keratoplasty.³⁻⁵ In view of sparing

availability of donor material, judicious use of corneal tissue especially in failed keratoplasties is a matter of concern. In a large series of keratoplasty surgeries in the USA, 8.9% were for eyes with failed past keratoplasty surgeries.⁶ King Khaled Eye Specialist Hospital (KKESH) in Riyadh, Kingdom of Saudi Arabia (KSA) is a tertiary eye center, where nearly 1000 keratoplasty surgeries are performed in a year.⁷ The outcomes of keratoplasty surgeries at KKESH have already been studied.⁸ However, the outcomes of repeat penetrating keratoplasty (PKP) in eyes that had a history of failed PKP have not yet been studied. We present the profile and visual outcomes, changes in intraocular pressure (IOP) and success rates in eyes with failed graft that were managed by PKP at KKESH.

Methods. This research project was approved by the Institutional Research Board of KKESH, Riyadh, KSA. The cases of failed PKP managed by repeat PKP from January 2007 to December 2012, and with at least a 6 month postoperative follow up were included in this review. One cornea surgeon was involved in data collection and review. Eye bank data relating to keratoplasty surgeries and the indication of repeat surgery were used to short list the patients to include in the present study. For these indemnified cases, case files and surgery details were extracted.

The demographic profile of participants included age, gender, and age at last PKP to manage failed PKP. Clinical details included; preoperative vision, duration between repeat PKP and previous surgery, indications for past PKP and IOP. The relevant history included; systemic comorbidities like diabetes and hypertension, the number of past keratoplasty surgeries, and the diagnosis of other ocular comorbidity by ophthalmologist in the past.

Intraoperative and immediate postoperative complications information was taken from the surgery logbook. The vision in these cases before and after surgery at different follow up periods was assessed using Snellen's vision chart held at 6 meters distance from the patient. The presenting and best-corrected visual acuity using pinhole were assessed. The IOPs were measured by an applanation tonometer mounted on a slit lamp biomicroscope (Topcon, Japan). In a few cases, IOP was measured on the table or on the first day postoperative follow up using Tono-Pen (Medtronic, USA).

The visual status of the managed eye was grouped as "20/20 to 20/60", "<20/60 to 20/200", "<20/200 to

Disclosure. Author has no conflict of interests, and the work was not supported or funded by any drug company.

20/400”, and “<20/400 but perception of light present”. The visual status and IOP at 6 months following the repeat PKP was the outcome variable. If the vision improved to 20/60 or better, we defined it as a complete success. If the vision at 6 months follow up was <20/60 to 20/400, we considered it a relative success.

The presence of ocular comorbidities was associated to the success of keratoplasty. The data were collected using a pretested form. Then it was transferred to a Microsoft Excel spreadsheet. We used the Statistical Package for Social Sciences version 16 (SPSS Inc., Chicago, IL, USA) and univariate analysis by parametric method to calculate the frequencies and percentage proportions for qualitative variables. For normally distributed quantitative variables, we calculated the mean and standard deviation (SD). However if the variable was not normally distributed, we presented the median 25% quartile, minimum and maximum value of the variable. To compare the visual status of 2 dependent variables we used the chi square values and 2 sided *p*-values.

Results. There were 30 cases in our study. Their mean age was 52.3 (standard deviation [SD]: 22.9 years). The median of the interval between present PKP and past corneal surgery was 3 months (25% quartile = 1.2 months, minimum = one month and maximum = 33 months). Male participants were 19 (63%) and

female were 11 (37%). Sixteen right eyes and 14 left eyes were operated for repeat PKP. Ocular pathologies for which keratoplasty surgeries were performed in the past included; pseudophakic bullous keratopathy (2), keratoconous (5), corneal scar (8), macular dystrophy (1), congenital hereditary endothelial dystrophy (3), fuchs endothelial dystrophy (3), therapeutic graft (8). Systemic morbidity included hypertension (4), and diabetes (4).

Nineteen eyes underwent keratoplasty once, 6 eyes were operated on twice, while 5 eyes had undergone keratoplasty surgeries 3 or more times. Cases were grouped according to ocular comorbidities. Among eyes with failed graft, ocular comorbidities included; glaucoma (12), high myopia (1), vernal keratoconjunctivitis (10), and aniridia (1). In 13 eyes, we did not find any associated ocular comorbidity.

One eye had a temporary wound leak, while 6 eyes showed early signs of rejection within 4 weeks of surgery. One case resulted in blindness, while the rest had vision <20/200 at 6 months after repeat PKP. The best-corrected visions at different follow up visits following the repeat keratoplasty surgery were compared with the best corrected visual acuity before surgery (Figure 1). In our study, at 2 years after surgery, the complete success rate was 73% (95% confidence interval [CI]: 57-89) and the relative success rate was 86% (95% CI: 74-98) in our study. At 6 months, the complete success rate was

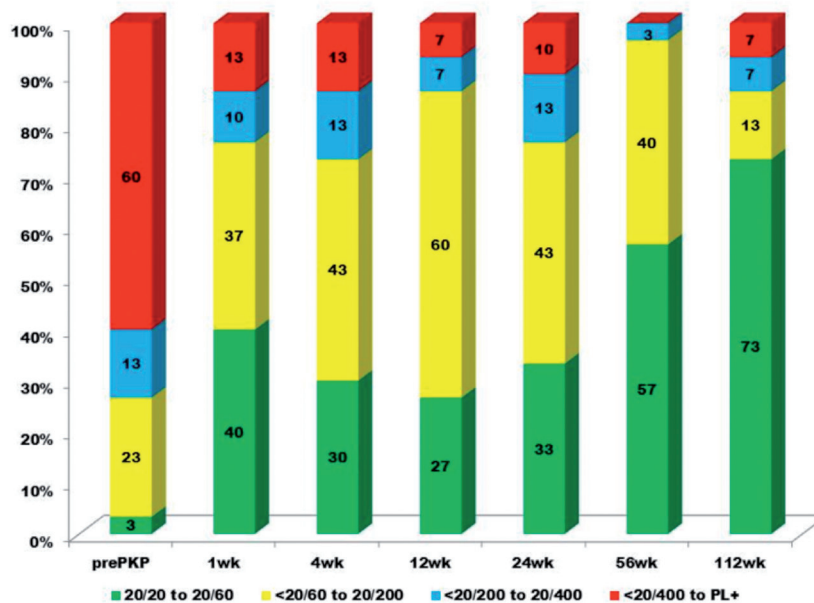


Figure 1 - Visual acuity in eyes with failed graft before and at different times of follow up after repeat penetrating keratoplasty, X axis shows different follow up periods after surgery, Y axis shows the percentage proportion of eyes with different visual acuity grades, Red color suggests vision <20/400, Blue color depicts vision <20/200 to 20/400, Yellow color symbolizes vision <20/60 to 20/200, and Green color reveals ‘function normal vision’ 20/20 to 20/60.

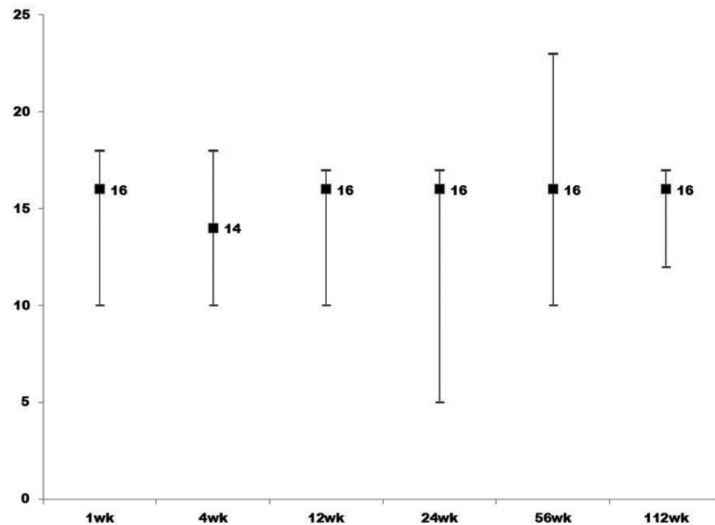


Figure 2 - Intraocular pressure (IOP) in eyes with failed graft before and at different times of follow up after repeat penetrating keratoplasty, X axis shows different follow up periods after surgery, Y axis shows IOP in mm Hg, Central square denotes median IOP, upper and lower end of high-low line denote 25% and 75% quartile of IOP. wk - week

33% and the relative success rate was 76%. The IOP at 1, 4, 12, 24, 56, and 112 weeks following surgery are shown in Figure 2. The variation in IOP following repeat PKP was not significant ($p=0.4$).

In 11 eyes, additional surgeries such as the repositioning of iris, air injection, cautery of conjunctival vessels, trabeculectomy, and cataract surgery had to be performed. Four (36.4%) eyes had complete success, while 8/11 (73%) had relative success following additional procedure.

Among the 18 eyes that did not need additional surgical procedure, 6/18 (33.3%) had complete success and 15/18 (83.3%) had relative success. The difference in visual status of the 2 groups was not significant ($p=0.2$). Among the 14 eyes with ocular comorbidities, a complete success was found in 4 (40%), and relative success in 10 (87%) at 6 months following repeat PKP. In the 16 eyes without ocular comorbidities, the complete and relative success rate was same.

Of the 18 eyes having undergone one surgery in the past, 7(39%) had complete success and 14 (78%) had relative success. Of the 11 eyes that had more than one surgery in the past, a complete success was found in one (9%) and relative success in 3 (27%) eyes after 6 months of repeat PKP ($p=0.03$).

Discussion. Our study showed the importance of repeat PKP in the management of failed corneal grafts. Repeat PKP could provide functional vision in three fourth of eyes in 2 years. Six eyes showed early

signs of graft rejection and needed long-term intense immunosuppressive management. The variation of IOP was not significant in operated eyes. The number of past corneal surgeries significantly and negatively affected the visual outcome of operated eyes.

In our study, vision was 20/60 or better in 73% of cases after 2 years of repeat PKP. In a study carried out in Turkey,⁵ only 21% of the eyes undergoing PKP as a repeat procedure had visual acuity of 20/100. The short-term vision gain in this study was less compared with the long-term visual gain. It is perhaps the detection of signs for early rejection and additional surgical procedures to address comorbidities that are responsible for the long-term success in our study.

In spite of the use of immunosuppressive strategies, 6 eyes demonstrated signs of graft rejection. A guarded prognosis should be offered to those showing early signs of rejection. Although studies with smaller samples showed the use of prophylactic immunosuppressant in avoiding graft rejection in repeat PKP, the Cochrane review did not support this benefit.⁹

The variation in IOP was not significant at different times of follow up until 2 years in the present study. In contrast, the rise in IOP in the first year following repeat PKP was significant in eyes managed by femtosecond assisted keratoplasty.⁴ The rise of IOP along with fixed dilated pupils following PKP was noted by Jastaneiah et al.¹⁰ The use of Healon as viscoelastics is blamed for the persistent rise in IOP during the one-year follow up period.¹¹ Modern and safer viscoelastics that were used

in the present study could have reduced the risk of rise in IOP.

Glaucoma was a comorbidity in 40% of our cases. Ongoing glaucoma medication in these eyes could also be responsible for less variation in IOP observed during the postoperative period.

The study had a few limitations. The numbers of eyes undergoing the proposed surgery were few. Therefore, the outcomes of subgroups could be influenced by statistical error and should be looked at with caution. Although short-term outcomes of 6 months were available in all but one case, long-term outcomes like one year and 2 year after repeat PKP had large dropout rates. This could be due to the development of medical centers with high levels of eye care units in other areas of Saudi Arabia where these cases might be visiting for follow ups instead of returning to KKESH.

In conclusion, until the corneal tissue is cultured and available for legally transplantation in the human eye, corneal tissue from cadavers will continue, and failed graft management by keratoplasties will be the only solution available to care givers.¹² Until alternative methods for keratoplasty like Descemet stripping automated endothelial keratoplasty,¹³ Descemet's membrane endothelial keratoplasty,¹⁴ and artificial corneas become available, PKP could be the only proven mode of management of failed graft.¹⁵ A comparative study is recommended to study the success rates in these different procedures for failed PKP.

Received 23rd November 2015. Accepted 22nd June 2016.

From the Division of Ophthalmology, Department of Surgery, College of Medicine, King Khalid University, Abha, and King Khaled Eye Specialist Hospital, Riyadh, Kingdom of Saudi Arabia. Address correspondence and reprints request to: Dr. Abdulrahman S. Khairallah, Division of Ophthalmology, Department of Surgery, College of Medicine, King Khalid University, Abha, Kingdom of Saudi Arabia. E-mail: Dr.akhairallah@gmail.com

References

- Williams KA, Esterman AJ, Bartlett C, Holland H, Hornsby NB, et al. How effective is penetrating corneal transplantation? Factors influencing long-term outcome in multivariate analysis. *Transplantation* 2006; 81: 836-901.
- Nguyen P, Barte F, Shinada S, Yiu SC. Management of Corneal Graft Rejection - A Case Series Report and Review of the Literature. *J Clin Exp Ophthalmol* 2010; 1: 103.
- Chow SP, Cook SD, Tole DM. Long-Term Outcomes of High-Risk Keratoplasty in Patients Receiving Systemic Immunosuppression. *Cornea* 2015; 34: 1395-1399.
- Rush SW, Fraunfelder FW, Mathers WD, Chamberlain WD. Femtosecond laser-assisted keratoplasty in failed penetrating keratoplasty and globe trauma. *Cornea* 2011; 12: 1358-13562.
- Yalniz-Akkaya Z, Burcu Nurozler A, Yildiz E, Onat M, Budak K, Duman S. Repeat penetrating keratoplasty: indications and prognosis, 1995-2005. *Eur J Ophthalmol* 2009; 19: 362-368.
- Dobbins KR, Price FW Jr, Whitson WE. Trends in the indications for penetrating keratoplasty in the midwestern United States. *Cornea* 2000; 19: 813-816.
- Ministry of Health. Annual statistical report of KKESH 2014. 2015 p. 49. Arabic
- Wagoner MD, Ba-Abbad R, Al-Mohaimed M, Al-Swailem S, Zimmerman MB; King Khaled Eye Specialist Hospital Corneal Transplant Study Group. Postoperative complications after primary adult optical penetrating keratoplasty: prevalence and impact on graft survival. *Cornea* 2009; 28: 385-394.
- Abudou M, Wu T, Evans JR, Chen X. Immunosuppressants for the prophylaxis of corneal graft rejection after penetrating keratoplasty. *Cochrane Database Syst Rev* 2015 27; 8: CD007603.
- Jastaneiah S, Al-Towerki AE, Al-Assiri A. Fixed dilated pupil after penetrating keratoplasty for macular corneal dystrophy and keratoconus. *Am J Ophthalmol* 2005; 140: 484-489.
- Burke S, Sugar J, Farber MD. Comparison of the effects of two viscoelastic agents, Healon and Viscoat, on postoperative intraocular pressure after penetrating keratoplasty. *Ophthalmic Surg* 1990; 21: 821-816.
- de Araujo AL, Gomes JÁ. Corneal stem cells and tissue engineering: Current advances and future perspectives. *World J Stem Cells* 2015; 7: 806-814.
- Tarantino-Scherrer JN, Kaufmann C, Bochmann F, Bachmann LM, Thiel MA. Visual Recovery and Endothelial Cell Survival After Descemet Stripping Automated Endothelial Keratoplasty for Failed Penetrating Keratoplasty Grafts—A Cohort Study. *Cornea* 2015; 34: 1024-1029.
- Price MO, Feng MT, McKee Y, Price FW Jr. Repeat Descemet Membrane Endothelial Keratoplasty: Secondary Grafts with Early Intervention Are Comparable with Fellow-Eye Primary Grafts. *Ophthalmology* 2015; 122: 1639-644.
- Akpek EK, Alkharashi M, Hwang FS, Ng SM, Lindsley K. Artificial corneas versus donor corneas for repeat corneal transplants. *Cochrane Database Syst Rev* 2014; 11: CD009561.