

Correlation Between the Immediate Remnant Stump Length and Vein Diameter After Cyanoacrylate Closure Using the VenaSeal System During Treatment of an Incompetent Great Saphenous Vein

Vascular and Endovascular Surgery
2020, Vol. 54(1) 47-50
© The Author(s) 2019



Article reuse guidelines:
sagepub.com/journals-permissions
DOI: 10.1177/1538574419879563
journals.sagepub.com/home/ves



Insoo Park, MD¹ , and Daehwan Kim, MD¹

Abstract

Objectives: Cyanoacrylate glue is injected for incompetent great saphenous vein (GSV) treatment 5 cm distal to the saphenofemoral junction (SFJ). Although a few reports have investigated the postprocedural remnant stump length, none have focused on the factors affecting glue extension length and the consequent remnant stump length. **Methods:** Seventy-nine patients undergoing cyanoacrylate closure using the VenaSeal system at our clinic between August 2018 and November 2018 were investigated. The GSV diameter was measured just before treatment in the supine position 3 cm distal to the SFJ. Cyanoacrylate glue was injected 5 cm distal to the SFJ. **Results:** The mean glue extension length was 1.13 ± 1.12 cm. The GSV diameter and glue extension length exhibited a significant inversely proportional relationship ($P < .001$). More specifically, patients with a GSV diameter ≥ 0.7 cm had a longer remnant stump length than those with a smaller GSV diameter ($P < .001$). **Conclusions:** An increased GSV diameter is likely associated with a decreased glue extension length and, consequently, a longer remnant stump.

Keywords

cyanoacrylate closure, VenaSeal, varicose veins, stump length, great saphenous vein, GSV

Introduction

Cyanoacrylate closure (CAC), unlike traditional endothermal ablation, is a revolutionary nonthermal and nontumescent technique that does not cause thermal damage and thus results in minimal posttreatment pain and a faster posttreatment recovery.¹⁻³ Although the traditional thermal technique induces vein occlusion via thermal damage, CAC involves the intravenous (IV) injection of cyanoacrylate (CA), which acts like a “glue” to block the vein and induce occlusion.¹

Previous studies of the CAC technique, VenaSeal Closure System (Medtronic, Minneapolis, Minnesota), have commonly suggested that the catheter for CA injection should be positioned 5 cm distal to the saphenofemoral junction (SFJ)²⁻⁵ with compression 2.5 cm distal to the SFJ. These parameters are recommended because direct CA extension to the deep vein can result in deep vein thrombosis. Few studies have investigated the remnant stump length after CAC according to the above procedure. Kolluri and Morrison et al reported a mean remnant stump length of 2.25 (0-8.3) cm.^{3,6} Gibson and Ferris reported a remnant stump length of 3.3 ± 1.6 cm.⁴

Even if the catheter is positioned accurately 5 cm distal to the SFJ as described, a constant remaining stump length cannot be guaranteed because the CA extension is not uniform in every

case. To date, no previous study has focused on the factors affecting this inconsistency. Here, we hypothesized that a larger vein diameter would lead to a shorter glue extension, and consequently, a longer remnant stump. This was the first study that aimed to investigate the association between the great saphenous vein (GSV) diameter and remnant stump length after CAC.

Methods

Patients

All patients with incompetent GSV who were treated using CAC with the VenaSeal Closure System (Medtronic) at the Charm Vein Center (Seoul, Korea) between August 2018 and November 2018 were assessed. Fifty patients with 79 incompetent GSVs were enrolled in this study.

¹Charm Vein Center, Gwanak-gu, Seoul, Republic of Korea

Corresponding Author:

Insoo Park, Charm Vein Center, 1814, Nambusunhwan-ro, Gwanak-gu, Seoul 08738, Republic of Korea.
Email: insoo.park.md@gmail.com

Table 1. Patient Demographics.

No. of patients	50
Female, no (%)	40 (80%)
Age, mean (\pm SD)	47.4 \pm 13.8
BMI, mean (\pm SD)	22.7 \pm 3.4
CEAP no.	
C1	2
C2	25
C3	19
C4	3
C5	1

Abbreviations: BMI, body mass index; CEAP, clinical etiologic anatomic pathophysiologic classification; SD, standard deviation.

All treated GSVs exhibited a reflux of ≥ 0.5 seconds and a vein diameter of ≥ 0.3 cm at 3 cm distal to the SFJ when measured in a standing position. The preoperative clinical, etiologic, anatomic, and pathophysiologic classifications ranged from C1 to C5 (C1, telangiectasia or reticular veins; C2, varicose veins; C3, edema; C4a, pigmentation or eczema; C4b, lipodermatosclerosis or atrophie blanche; and C5, healed ulcer; Table 1). Two patients with C1 who experienced symptoms such as aching, cramping, and heaviness were included. This study was approved by the Korea National Institution for Bioethics Policy (approval number P01-201901-21-007) in 2018 and conforms to the Declaration of Helsinki. Patients were provided with sufficient information about the study and provided informed consent prior to treatment.

Procedure

The treatment was performed in the supine position and under local anesthesia. Per the patient's request, light IV sedation was induced under the supervision of an experienced anesthesiologist. The procedure was similar to a previously published procedure by our group.⁵

Prior to the procedure, the GSV (in centimeters) diameter 3 cm distal to the SFJ was measured using ultrasound (LOGIQe; GE, Milwaukee, Wisconsin) while the patient was in the supine position, with abduction and external rotation of the hip joint to ensure full exposure of the inguinal area. Under real-time ultrasound guidance, a 5F delivery catheter in a 7F introducer sheath was inserted into the SFJ region and positioned 5.0 cm distal to the SFJ. While the left hand held the ultrasound probe, the region 2.5 cm distal to the SFJ was compressed to ensure that glue did not flow into the deep vein. Under this condition, two 0.10-mL volumes of CA glue were injected (1 cm intervals), and the vein was compressed using the right hand for 3 minutes to induce sealing. The injections were then repeated (3 cm interval, 1 dose; 30-second interval between injections) to complete the treatment. Areas with large diameters and communicating or perforating veins were treated with additional injections at the author's discretion. If needed, concomitant treatment (mini-phlebectomy or sclerotherapy) was administered after the common treatment described above. After completing all

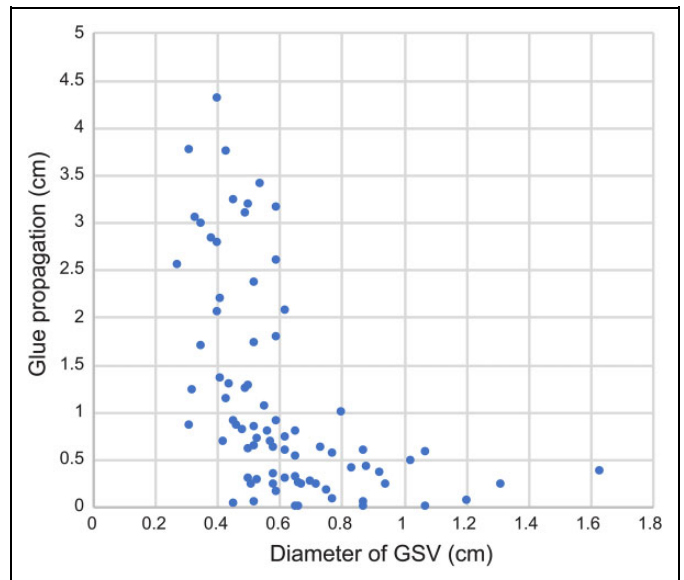


Figure 1. Association between the GSV diameter and glue propagation length. GSV indicates great saphenous vein.

treatments, the immediate remnant stump length was measured via ultrasound in the supine position with abduction and external rotation of hip joint before transporting the patient from the operating room. Moreover, the glue extension length was calculated by subtracting the remnant stump length from 5 cm.

Statistical Analysis

All statistical analyses were performed using SPSS version 18.0 (IBM, Armonk, New York). Data were analyzed using Pearson correlation and *t* test methods. Statistical significance was assumed at a *P* value $< .05$. Pearson correlation analysis was performed to assess the association between the GSV diameter and glue extension length (Figure 1).

Results

The patient demographics, vein diameter, and remnant stump length are outlined in Tables 1 and 2. The association between the GSV diameter (3 cm distal to the SFJ in the supine position) and glue extension length was analyzed using a Pearson correlation analysis (Figure 1). The GSV diameter was inversely proportional to the glue extension length (coefficient = $-.509$), and this relationship was statistically significant ($P < .001$).

More specifically, the glue extension length tended to increase at a GSV diameter < 0.70 cm. However, the glue extension length was marginal at a GSV diameter ≥ 0.70 cm. This difference was also statistically significant ($P < .001$; Table 3).

Discussion

An unnecessarily long saphenous vein remnant stump length after varicose vein treatment may indicate reflux involving the

Table 2. Treatment Characteristics.

No. of treated GSV	79
GSV diameter in supine position (cm) mean \pm SD (range)	0.61 \pm 0.24 (0.30-1.63)
Glue extension length (cm) mean \pm SD (range)	1.13 \pm 1.12 (0-4.31)
Remnant stump length (cm) mean \pm SD (range)	3.87 \pm 1.12 (0.69-5.0)

Abbreviations: GSV, great saphenous vein; SD, standard deviation.

Table 3. Mean Glue Extension and Remnant Stump Length According to Vein Diameter.

Variables	GSV Diameter <0.7 cm (N = 59)	GSV Diameter \geq 0.7 cm (N = 20)	P Value
Mean glue extension length	1.40 \pm 1.17	0.34 \pm 0.25	<.001
Mean remnant stump length	3.60 \pm 1.17	4.67 \pm 0.25	<.001

Abbreviation: GSV, great saphenous vein.

nearby tributaries and potential recurrence. Therefore, traditional endothermal ablation is commonly initiated 2 to 3 cm distal to the SFJ⁷⁻¹¹ after placement of the fiber or catheter at the exact desired position 2 to 3 cm distal to the SFJ under real-time ultrasound guidance. However, CAC using the VenaSeal system is entirely different from traditional endothermal ablation. Specifically, the author's experiences suggest that accurate catheter positioning would not guarantee the operator full control at the ablation starting point because the glue (in liquid form) spreads after the injection, which determines the area of occlusion. Hence, it would be impossible to control the remnant stump length accurately with CAC.

As mentioned above, few previous studies have reported the remnant stump length after CAC using the VenaSeal system, and a careful investigation revealed a large gap between the minimum and maximum remnant stump length. Kolluri and Morrison et al reported minimum and maximum lengths of 0 and 8.3 cm, respectively,^{3,6} while Gibson and Ferris reported a mean remnant stump length of 3.3 \pm 1.6 cm.⁴ Similarly, we observed a large gap between the minimum and maximum remnant stump lengths, with respective values of 0.69 and 5.0 cm. We hypothesized that an unknown factor might affect the glue extension length and consequent stump length.

The findings of this study demonstrate that the glue extension distance becomes marginal at larger GSV diameters. Although the word "glue" is used frequently to facilitate understanding, CAC does not involve venous wall adhesion. However, in one study, it has been shown that the CA glue polymerizes with blood to affect the lumen, leading to non-compressible mechanical occlusion.³ Therefore, it is possible that if the volume of the polymerized material is too small relative to the internal vein diameter, the extension will be very

marginal. In contrast, the extension within a small-diameter vein would be relatively greater.

The findings of this study support our hypothesis; specifically, the mean glue extension distance in veins with a diameter of \geq 0.70 cm in the supine position was marginal, with a consequent long stump. In contrast, the mean glue extension distance was significantly greater in veins with a diameter of <0.70 cm in the supine position. Therefore, we believe that the vein diameter significantly affects the glue extension length, and consequently, the stump length.

Additionally, we suppose that the following points should be explained although they may be difficult to assess numerically. While performing the 3-minute compression, if the glue compression pressure (usually applied using the right hand) is much stronger than the pressure applied for guarding the SFJ (usually with the left hand), the glue may extend past the guarded point resulting in a longer extension. Therefore, when performing compression at 2 different locations simultaneously, adjusting the pressure at the 2 sites in order to ensure that the guarding pressure is adequately strong will be important to prevent long glue extension. Moreover, even if the GSV diameter is <0.70 cm at 3 cm from the SFJ and \geq 0.70 cm at 4 cm or 5 cm from the SFJ, the degree of extension tends to decrease. This may explain why 15 "dots" of diameter <0.7 cm had minimal glue extension of less than 0.5 cm (Figure 1). Therefore, observing the maximal diameter between the catheter tip and SFJ is recommended rather than strictly focusing on the diameter at 3 cm from SFJ.

This study was limited by the single-center design and relatively small sample size. Moreover, only the immediate post-procedural stump length was measured in the supine position. This parameter was not measured in a standing position and/or after a longer follow-up period. Another potential limitation of this study was that we could not evaluate the changes in the stump length or whether the stump length caused any recurrence and/or any complications. We hope that future studies can evaluate these aspects in greater detail.

Conclusion

Although the catheter tip is positioned 5 cm distal to the SFJ during CAC, the lengths of glue extension and the consequent remnant stump may vary. Our study suggests that the vein diameter is a significant factor affecting the glue extension length. Specifically, the glue extension was marginal in veins with a diameter of \geq 0.70 cm in the supine position, which resulted in a long remnant stump.

Authors' Note

I.P. and D.K. researched literature and conceived the study. I.P. developed the study protocol, obtained ethical approval, recruited patients for the study, and analyzed data. I.P. and D.K. wrote the first draft of the manuscript. All authors reviewed and approved the final version of this manuscript. Correlation between the immediate remnant stump length and vein diameter after cyanoacrylate closure using the VenaSeal system during treatment of an incompetent great saphenous vein.

Declaration of Conflicting Interests

The author(s) declared no potential conflicts of interest with respect to the research, authorship, and/or publication of this article.

Funding

The author(s) received no financial support for the research, authorship, and/or publication of this article.

ORCID iD

Insoo Park  <https://orcid.org/0000-0003-0563-9105>

References

- Almeida JJ, Javier JJ, Mackay EG, Bautista C, Cher DJ, Proebstle TM. Two-year follow-up of first human use of cyanoacrylate adhesive for treatment of saphenous vein incompetence. *Phlebology*. 2015;30(6):397-404.
- Proebstle TM, Alm J, Dimitri S, et al. The European multicenter cohort study on cyanoacrylate embolization of refluxing great saphenous veins. *J Vasc Surg Venous Lymphat Disord*. 2015; 3(1):2-7.
- Morrison N, Gibson K, McEnroe S, et al. Randomized trial comparing cyanoacrylate embolization and radiofrequency ablation for incompetent great saphenous veins (VeClose). *J Vasc Surg*. 2015;61(4):985-994.
- Gibson K, Ferris B. Cyanoacrylate closure of incompetent great, small and accessory saphenous veins without the use of post-procedure compression: initial outcomes of a post-market evaluation of the VenaSeal System (the WAVES Study). *Vascular*. 2017;25(2):149-156.
- Park I. Initial outcomes of cyanoacrylate closure, VenaSeal system, for the treatment of the incompetent great and small saphenous veins. *Vasc Endovascular Surg*. 2017;51(8):545-549.
- Kolluri R, Gibson K, Cher D, Madsen M, Weiss R, Morrison N. Roll-in phase analysis of clinical study of cyanoacrylate closure for incompetent great saphenous veins. *J Vasc Surg Venous Lymphat Disord*. 2016;4(4):407-415.
- De Maeseneer M, Pichot O, Cavezzi A, et al. Duplex ultrasound investigation of the veins of the lower limbs after treatment for varicose veins—UIP consensus document. Union Internationale de Phlebologie. *Eur J Vasc Endovasc Surg*. 2011;42(1):89-102.
- Proebstle TM, Vago B, Alm J, Göckeritz O, Lebard C, Pichot O. Treatment of the incompetent great saphenous vein by endovenous radiofrequency powered segmental thermal ablation: first clinical experience. *J Vasc Surg*. 2008;47(1):151e6.
- Puggioni A, Marks N, Hingorani A, Shiferson A, Alhalbouni S, Ascher E. The safety of radiofrequency ablation of the great saphenous vein in patients with previous venous thrombosis. *J Vasc Surg*. 2009;49(5):1248e55.
- Rasmussen LH, Bjoern L, Lawaetz M, Lawaetz B, Blemings A, Eklöf B. Randomised clinical trial comparing endovenous laser ablation with stripping of the great saphenous vein: clinical outcome and recurrence after 2 years. *Eur J Vasc Endovasc Surg*. 2010;39(5):630e5.
- Theivacumar NS, Dellagrammaticas D, Beale RJ, Mavor AI, Gough MJ. Factors influencing the effectiveness of endovenous laser ablation (EVLA) in the treatment of great saphenous vein reflux. *Eur J Vasc Endovasc Surg*. 2008;35(1):119e23.