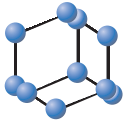
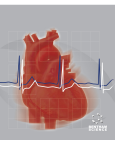

REVIEW ARTICLE


**BENTHAM
SCIENCE**

Twenty Years of Alcohol Septal Ablation in Hypertrophic Obstructive Cardiomyopathy

 Current
Cardiology
Reviews


Angelos G. Rigopoulos* and Hubert Seggewiss

Medizinische Klinik 1, Leopoldina Krankenhaus, Schweinfurt, Germany

Abstract: Hypertrophic obstructive cardiomyopathy is the most common genetic cardiac disease and is generally characterised by asymmetric septal hypertrophy and intraventricular obstruction. Patients with severe obstruction and significant symptoms that persist despite optimal medical treatment are candidates for an invasive septal reduction therapy. Twenty years after its introduction, percutaneous transluminal alcohol septal ablation has been increasingly preferred for septal reduction in patients with drug refractory hypertrophic obstructive cardiomyopathy. Myocardial contrast echocardiography and injection of reduced alcohol volumes have increased safety, while efficacy is comparable to the surgical alternative, septal myectomy, which has for decades been regarded as the ‘gold standard’ treatment. Data on medium- and long-term survival show improved prognosis with survival being similar to the general population. Current guidelines have supported its use by experienced operators in centres specialised in the treatment of patients with hypertrophic obstructive cardiomyopathy.



Angelos G. Rigopoulos

ARTICLE HISTORY

 Received: November 6, 2014
 Revised: December 14, 2014
 Accepted: December 17, 2014

DOI: 10.2174/1573403x11666150107160344

Keywords: Alcohol septal ablation, hypertrophic cardiomyopathy, hypertrophy, myocardial contrast echocardiography, septal reduction, survival.

INTRODUCTION

Hypertrophic cardiomyopathy (HCM) is the most common genetic cardiac disease occurring in 1 of 500 individuals. The diagnosis is based on identification of left ventricular hypertrophy that cannot be explained by the presence of another cardiac defect or abnormal loading conditions [1].

The variable genetic aetiology and penetrance as well as the influence of various largely unidentified modifying factors lead to considerable temporal and anatomical heterogeneity of the appearance and amount of hypertrophy. Although most patients remain asymptomatic, others may develop debilitating symptoms of dyspnoea on exertion, angina on exertion or atypically presenting at rest, reduced exercise capacity and syncope. A small proportion of patients are prone to develop life threatening ventricular arrhythmias leading to sudden death. The primary determinants of symptomatic status are diastolic dysfunction, which is typically present in patients with symptoms, and left ventricular obstruction. The latter appears in approximately two thirds of patients at rest or with provocative manoeuvres (hypertrophic obstructive cardiomyopathy, HOCM) [2].

Despite the substantial phenotypic and pathophysiologic heterogeneity of the disease, treatment of symptomatic

patients is dependent on the existence of obstruction [3, 4]. Symptomatic patients without obstruction are treated with beta-blockers or verapamil aiming at relief of diastolic dysfunction and reduction of myocardial energy consumption. Treatment of patients with symptoms and left ventricular obstruction aims at the reduction of the pressure gradient. Beta-blockers are the first line of treatment but are probably more effective in exercise-related obstruction, while addition of disopyramide seems to offer additional relief of the resting gradient [5-8]. Calcium-channel antagonist verapamil, although advocated by some [9, 10], can lead to paradoxical increase of the gradient caused by reduction of systemic vascular resistance [11].

Patients with high left ventricular gradients with persistent symptoms despite optimal medical treatment (up to 10% of patients) [11] are referred to septal reduction treatment. Septal myectomy-myotomy has been the traditional “gold standard” for decades with excellent results in several highly experienced (mostly North American) centres [12]. In-hospital mortality of isolated myectomy in such centres is very low (<1%) and long-term survival compares with survival in the general non-HCM population [13]; it is therefore considered the first option for HOCM not amenable to medical therapy according to American guidelines [3]. Beyond these excellent results, however, surgical treatment has been practically reserved for younger, lower-risk patients, while older patients with comorbidities and higher operative risk have been almost certainly excluded. Indeed, with the prob-

*Address correspondence to this author at the Medizinische Klinik 1, Leopoldina Krankenhaus Schweinfurt, Gustav-Adolf-Str. 8, 97422 Schweinfurt, Germany; Tel: +49 9721 7206251; Fax: +49 9721 3703317; E-mail: angelos.rigopoulos@gmail.com

able exclusion of one large study [14], mean age of patients in most myectomy studies lies in the mid- to late-forties [15-23]. Dual chamber pacing from the right ventricular apex with short AV-delay has been introduced in the 1990s as a promising alternative for such patients with the aim to reduce the left ventricular gradient and improve exercise capacity. Despite the initial enthusiasm, randomised cross-over trials have convincingly shown that pacing is associated with a marvellous placebo effect and only a modest effect on obstruction especially in patients >65 years of age [24].

Alcohol septal ablation (ASA) was introduced 20 years ago as a percutaneous interventional option for patients with drug refractory HOCM. The emergence of a nonsurgical treatment has initiated widespread enthusiasm because it could be offered to patients usually excluded from surgery because of advanced age or comorbidities [25] as well as to those rejecting open heart surgery [26]. On the other hand, the availability of an interventional treatment with continuously proven efficacy has promoted awareness about HOCM which led to increasing frequency of application of both interventional and surgical treatment in the last years.

HISTORICAL PERSPECTIVE

Several observations in the 1980s in conjunction with the advances of interventional cardiology have led to the concept of a nonsurgical septal reduction technique for HOCM (Fig. 1). After the advent of coronary angioplasty, it was realised that temporary balloon occlusion of a coronary artery could lead to reduced systolic function of the supplied left ventricular area [27]. Besides, left ventricular obstruction disappears in some patients with HOCM after a myocardial infarction [28]. The idea to create septal ablation with alcohol was inspired by the parallel efforts of Brugada *et al.* to treat ventricular arrhythmias by ablating the septal territory in patients with coronary artery disease [29]. These first observations led to the original description of the technique in 1989 by a German cardiologist (G. Berghofer, personal communication). The idea was further developed by others, who have shown that temporary balloon occlusion of the first septal branch leads to gradient reduction in some pa-

tients with HOCM [30, 31]. Dr. Sigwart was the first to treat patients with the new method and published the results of the first 3 patients in 1995 [31]. Despite initial scepticism [32], the new interventional treatment has become very popular with an increasing number of patients being treated worldwide [12]. The modification of the original technique with the addition of myocardial contrast echocardiography for identification of the appropriate target septal branch has rendered alcohol septal ablation a highly sophisticated modality and dissolved original fears of an “uncontrolled manoeuvre” that would lead to deterioration of left ventricular function [32, 33].

INDICATIONS AND PATIENT SELECTION

Careful and precise patient selection for alcohol septal ablation will ensure maximum benefit from gradient reduction [34]. Indication is established by the presence of appropriate clinical as well as anatomical and physiological characteristics (Table 1). Clinical symptoms are sometimes vague and patients tend to accommodate their limitations and adapt themselves to them. Cardiopulmonary exercise test can unmask the degree of limitation in patients with unresolved symptoms or limited activity and should be performed in every patient who is a candidate for septal reduction procedures [4].

Interventional treatment of HOCM is indicated in patients who meet all necessary clinical, morphological and haemodynamic criteria. Evaluation before intervention is based on history, cardiac imaging (echocardiography, MRI), cardiac catheterization and coronary arteriography. Existence and degree of left ventricular obstruction is largely variable and can depend on changes of preload, afterload or cardiac contractility invoked by physiological or pharmacological provocation. Provocative manoeuvres (Valsalva, exercise) can reveal latent obstruction and should always be performed, especially in patients without substantial obstruction at rest [2].

According to the European Guidelines for HCM, a gradient ≥ 50 mmHg either at rest or with provocation signifies

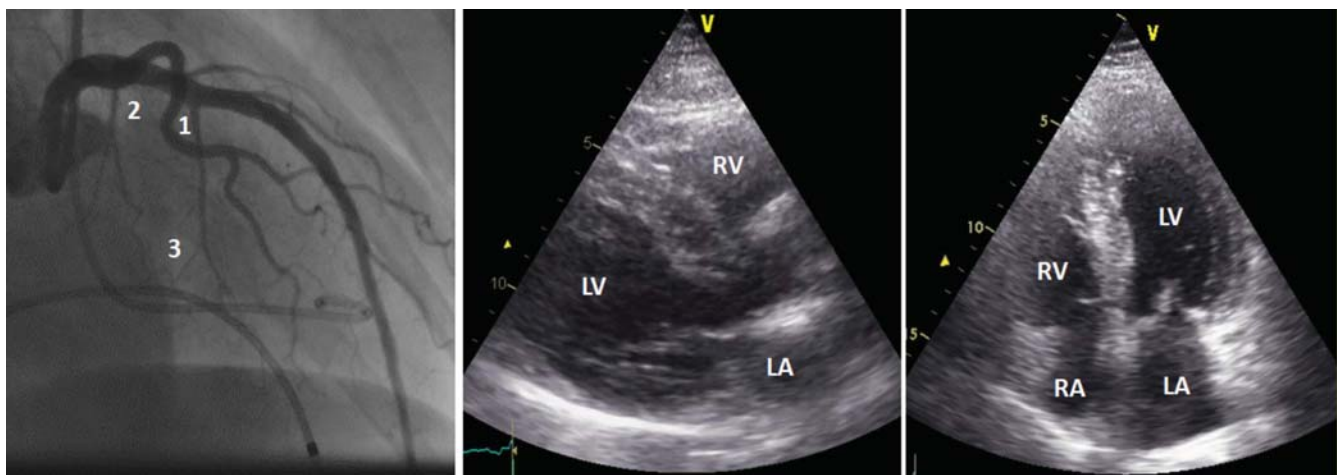


Fig. (1). Left coronary angiography (left) shows a dominant septal branch (1) and a tiny proximal septal branch (2). The large septal branch (1) is divided in several ending branches, two of which are pointing proximally (3). Transthoracic echocardiography before alcohol septal ablation shows the typical septal hypertrophy in long axis parasternal (middle) and apical 4-chamber (right) views. LV: left ventricle, RV: right ventricle, LA: left atrium, RA: right atrium.

Table 1. Indication for alcohol septal ablation.

<p>Clinical Characteristics</p> <p>Symptomatic patients with</p> <ul style="list-style-type: none"> - Drug-refractory symptoms and/or severe side effects of drugs - Functional class III and IV or functional class II with objective exercise limitation - Recurrent exercise-induced syncope <p><i>Additional features:</i></p> <ul style="list-style-type: none"> - Failure of prior myectomy or pacemaker - Comorbidity-related increased surgical risk
<p>Haemodynamic Characteristics</p> <p>Intracavitary gradient at rest and/or with provocation ≥ 50 mmHg</p> <p>Methods of provocation:</p> <ul style="list-style-type: none"> - Valsalva manoeuvre - Physiologic stress test (Echocardiography) - Post extrasystole (Brockenbrough phenomenon)
<p>Morphological Characteristics</p> <p>Echocardiography</p> <ul style="list-style-type: none"> - Subaortic, SAM – associated gradient - Mid-cavitary gradient - Exclusion of intrinsic mitral valve apparatus disorders - Septal thickness at region of obstruction > 15 mm <p>Coronary angiography</p> <ul style="list-style-type: none"> - Suitable septal branch

significant obstruction that should be managed interventionally or surgically in highly symptomatic patients (NYHA functional class II-IV) despite maximum tolerated medical therapy (Class I, level of evidence B) [4]. In addition, patients with recurrent exertional syncope caused by resting or provoked left ventricular obstruction with a significant gradient (≥ 50 mmHg) should also be considered for septal reduction treatment (Class IIa, Level of evidence C) [4]. Although survival after alcohol septal ablation and myectomy is excellent in long-term reports, there are no data to support the use of invasive procedures in asymptomatic patients with good exercise capacity, irrespective of the degree and location of left ventricular obstruction [3, 4, 35]. Such patients should be followed regularly for signs of cardiac decompensation as well as for clinical risk stratification for sudden cardiac death.

Indication for alcohol septal ablation entails a suitable left ventricular morphology which undoubtedly predicts that septal reduction will reduce LVOT gradient. A typical morphology in patients with subaortic obstruction includes asymmetric hypertrophy of the basal septum with systolic anterior motion of the anterior mitral valve leaflet and associated mitral regurgitation directed posteriorly. Additionally, patients with midventricular obstruction (located in the mid-to apical part of the left ventricle) can also be considered for alcohol septal ablation with echocardiographic guidance [35, 36]. Anyhow, septal thickness at the region of obstruction should be > 15 mm.

On the other hand, an unfavourable morphology would indicate surgical treatment as more appropriate. Obstruction caused by abnormalities of the mitral valve (extremely long or flail leaflets) or mitral valve apparatus (anomalous papillary muscle insertion) can only be corrected surgically [37]. Existence of discreet abnormal membrane in the outflow tract is an indication for surgery and should be identified vigorously before decision of further treatment [38]. Likewise, other severe valvular disease (i.e. aortic stenosis) requiring surgical correction shifts the decision towards surgery. Significant coronary artery disease warranting coronary artery bypass grafting also indicates surgery. In less severe coronary artery disease, alcohol septal ablation can be considered after effective percutaneous treatment of all coronary lesions and documented persistence of symptoms. In the exceptional case of a significant stenosis of the left anterior descending artery at the origin of the target septal branch, alcohol septal ablation can be followed by coronary angioplasty at the same session [39].

Hypertrophy not involving the interventricular septum (apical or limited to the free wall) is a definite contraindication for alcohol septal ablation.

TECHNIQUE

Admission of patients the day before the intervention allows safe withdrawal of medications (β -blockers, verapamil, disopyramide) on the day of treatment. Alcohol septal

ablation is performed in the catheterization laboratory by an experienced interventional cardiologist who is part of a multidisciplinary team with expertise in the management of HCM. Recent American guidelines consider a number of 10 procedures per year as a minimum standard for maintenance of skills [40].

A diagnostic cardiac catheterization is necessary and can be performed before the alcohol septal ablation, in order to secure diagnosis of significant left ventricular obstruction in HCM and determine its location (Fig. 1). In patients without aortic stenosis simultaneous measurement of left ventricular inflow pressure with a 5F special pigtail catheter (with holes only on the distal part, Cordis®) and of the pressure in the descending aorta through a 6F long (≥ 45 cm) sheath permits accurate gradient measurement at rest, during the strain phase of the Valsalva manoeuvre and after an extrasystole (Brockenbrough phenomenon) with only one femoral arterial puncture. In unresolved cases of obstruction, slow pullback of the special pigtail catheter can determine the site of maximal gradient. For diagnostic purposes, the use of a special two-lumen pigtail catheter (Langston®, Vascular Solutions Inc., Minneapolis, USA) can also be recommended.

A temporary pacemaker lead is mandatory in patients without pacemaker or ICD and can be inserted through a femoral venous access. To avoid loss of capture, especially in high risk patients (previous myectomy, baseline LBBB, septal pacing) increase in the pacing output of a permanent pacemaker/ICD is advisable. For the alcohol septal ablation procedure we prefer two arterial accesses (for the guide catheter and the special pigtail). A coronary angioplasty guide catheter is inserted via the right femoral sheath and placed at the left coronary artery ostium. Although 6 Fr is adequate, a 7 Fr guide catheter offers better support and accurate pressure measurement. Although special catheters with extra backup potential can be used, standard Judkins left catheters are sufficient in most cases. Simultaneous recording of the aortic pressure through the guide catheter and the left ventricular pressure through the pigtail catheter enables continuous monitoring of the left ventricular gradient throughout the procedure. To avoid (rarely seen) complications from the femoral puncture site, a transradial access with subclavian approach for active fixation of the temporary

pacemaker lead has been advocated [41]. It must be stressed, however, that the transradial approach precludes the option of constant gradient recording throughout the procedure.

Weight adjusted heparin as well as opiate analgesia before alcohol injection are administered intravenously as a routine. Left coronary angiography (usually in RAO cranial view) permits the identification of possible target septal branches. Nonetheless, the diagonal and intermediate branches and, rarely, the proximal right coronary artery should also be carefully inspected for the existence of atypically originating septal branches. In left ventricular outflow tract obstruction commonly the first large septal branch is considered as target artery. An angioplasty floppy guidewire with standard length is advanced in the supposed target septal branch and a short (6-10 mm) compliant over-the-wire balloon is advanced in the septal branch and inflated at the nominal pressure. Such a balloon is usually 1.5-2.5 mm large and should be compatible with injection of absolute alcohol. A slightly oversized balloon precludes alcohol backflow to the left anterior descending artery and should be positioned proximally after the takeoff of the septal branch but not in the parent vessel, in order to avoid dissection.

Because of excessive anatomic variety and potential collateralisation in the septal artery system angiographic identification is not sufficient to guarantee correct positioning of alcohol in the target myocardial area [42, 43]. It is therefore necessary to test each target septal branch with myocardial contrast echocardiography (Figs. 2-4) [33, 44]. After withdrawal of the guidewire 1-2 ml of echocardiographic contrast agent is injected through the balloon catheter with simultaneous transthoracic echocardiography. Multiple views (parasternal, apical and subcostal) are used and compared with the same views recorded at baseline. Since the historically most broadly used Levovist® (Bayer, Germany) has been unavailable, we have been using cold (4 °C) agitated gelatine polysuccinate (Gelafundin®, BBraun, Melsungen, Germany), a colloid plasma volume substitute with comparable contrasting properties and stability [44, 45]. Comparison with other widely used agents (i.e. Sonovue®) has proved favourable for Gelatine polysuccinate in the context of alcohol septal ablation [46]. It is very important, not only to determine that the target septal

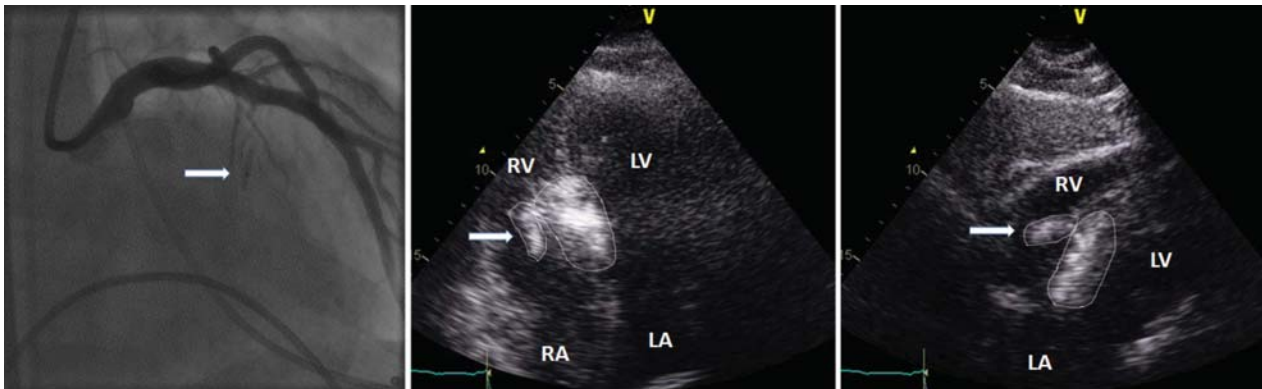


Fig. (2). Alcohol septal ablation in the patient shown in (Fig. 1). Left, an over-the-wire balloon (arrow) is inflated in the dominant septal branch (number 1 in Fig. 1). Transthoracic myocardial contrast echocardiography in the apical 4-chamber (middle) and subcostal (right) views is shown after injection of Gelafundin® (BBraun, Melsungen, Germany) in the target septal branch. There is good demarcation of the basal septum (i.e. the target area for ablation) but also clear opacification of the right ventricular papillary muscle (arrow, both areas demarcated with a dotted line). LV: left ventricle, RV: right ventricle, LA: left atrium, RA: right atrium.

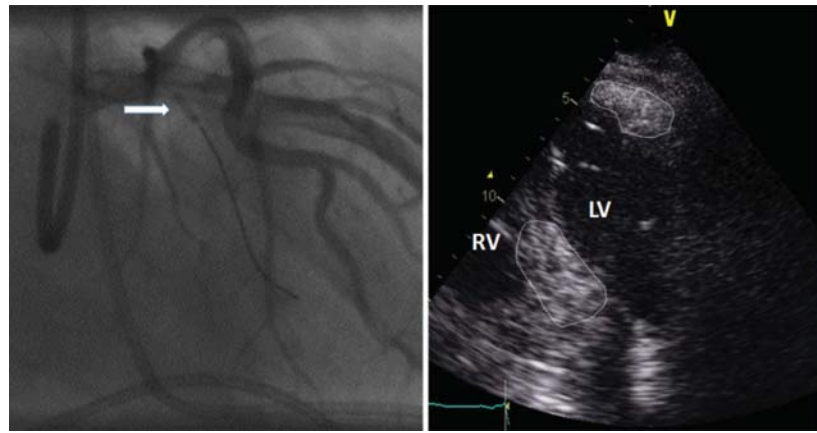


Fig. (3). Change of strategy after misplacement of contrast in the patient of (Figs. 1 and 2). The most proximal septal branch (arrow, hardly noticeable in coronary angiography of Fig. 1) is wired and an over-the-wire balloon is inserted and inflated at its proximal part (left). After contrast injection (right) a modified apical 4-chamber view shows opacification of the basal septum but at the same time the apical lateral wall is also demarcated (right). LV: left ventricle, RV: right ventricle.

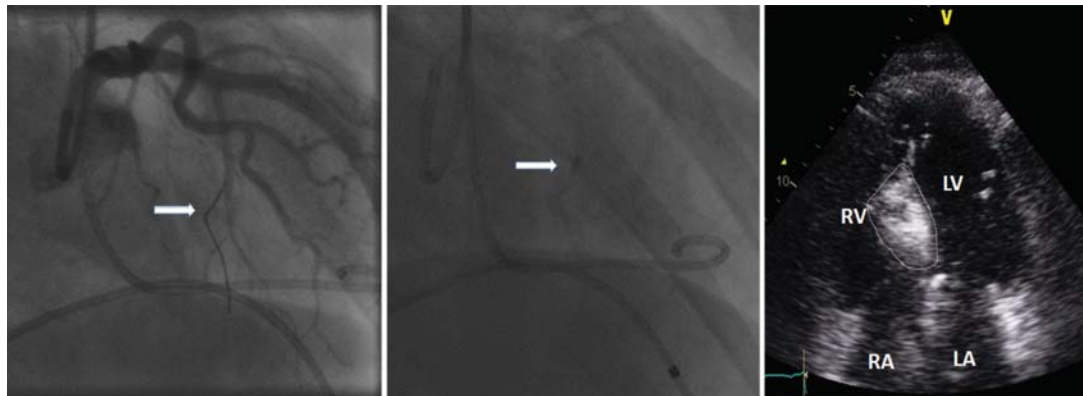


Fig. (4). Once again change of interventional strategy in the patient of (Figs. 1-3) after documented misplacement twice in myocardial contrast echocardiography (Figs. 2 and 3). The proximal proximally pointing final branch of the dominant septal branch (number 3 in Fig. 1) is inserted with the guidewire (left, arrow) and selective septal angiography is performed (middle, arrow) after myocardial contrast echocardiography (right) has depicted precise opacification of the target septal area without any misplacements. LV: left ventricle, RV: right ventricle, LA: left atrium, RA: right atrium.

branch perfuses the septal area adjacent to the obstruction (Fig. 4) but also to reliably exclude contrast opacification of any other cardiac structure (right ventricle, papillary muscle, other areas of left ventricle, Figs. 2 and 3). Furthermore, after confirmation with myocardial contrast echocardiography, selective angiography of the target septal branch documents the adequate sealing of the septal branch by the inflated balloon and the lack of collateral flow to distant locations [47]. After choice of the ideal septal branch has been confirmed, 1-3 ml of absolute alcohol is injected into the septal branch at a rate of 1ml/min. As a rule of thumb, the amount of alcohol is 1ml for every 10 mm of echocardiographically measured septal thickness [48]. Continuous fluoroscopic imaging during alcohol injection documents stability of the balloon catheter, while any catheter dislocation or resistance in injection should lead to prompt cessation of further injection. After last alcohol injection, the balloon is left in place for another ten minutes, as shorter times have been associated with higher complication risk [49, 50]. After balloon withdrawal, a final angiogram documents occlusion of the septal branch and normal flow in the LAD. The gradients at rest and with provocation are recorded again. Some operators advocate

occlusion of other septal branches in the same session if the gradient reduction is suboptimal [51]. If the opacified area in echocardiography after alcohol injection is satisfactory, we tend to await the haemodynamic effect after 3-6 months, as remodelling and scar formation can lead to further gradient reduction at follow-up [34]. In case the ablated area is not homogeneously demarcated after alcohol injection and the gradient is not reduced we go on to test another septal branch that would perfuse the omitted part.

After removal of the right femoral sheath and arterial closure with Angioseal[®], the patient will subsequently stay in the coronary care unit for at least 48 hours under constant haemodynamic and rhythm surveillance. Cardiac enzyme measurements every 6-8 hours will allow documentation of peak CK value. In absence of AV block, the temporary pacemaker can be removed the day after the procedure. In case a longer time of temporary pacing is required or ambulatory rhythm monitoring is not available, the jugular or subclavian venous access is preferable. Ventricular arrhythmias in the early hospital phase are considered to be benign as in the context of an acute ischaemia. Arrhythmias occurring later may be considered as a risk factor for sudden cardiac death. Decision to implant an ICD should be based on the

Table 2. Alcohol septal ablation techniques with different acronyms.

Acronym	Name	Identification of Target Septal Branch		Criterion of Completion
PTSMA [1, 2]	Percutaneous Transluminal Septal Myocardial Ablation	Transthoracic myocardial contrast echocardiography		Alcohol depot in echocardiography
TASH [3]	Transcoronary Ablation of Septal Hypertrophy	Haemodynamic effect of temporary branch occlusion		Until gradient is abolished
NSRT [4]	NonSurgical Septal Reduction	Echocardiographic study with the use of angiographic contrast dye		Until gradient is abolished
NSMR [5]	NonSurgical Myocardial Reduction	Haemodynamic effect of temporary branch occlusion	Occlusion of several septal branches	Until gradient is abolished
PTSA [6]	Percutaneous Transluminal Septal Ablation	Transthoracic myocardial contrast echocardiography	Repeated alcohol injection in the same branch	Until gradient is abolished
ASA [7-9]	Alcohol Septal Ablation	Lately prevalent general term mainly (but not always) [10] referring to the echocardiography guided technique		

Adapted from Rigopoulos AG, Seggewiss H. A decade of percutaneous septal ablation in hypertrophic cardiomyopathy. *Circ J*. 2010; 75(1): 28-37.

- [1] Seggewiss H, Gleichmann U, Faber L, Fassbender D, Schmidt HK, Strick S. Percutaneous transluminal septal myocardial ablation in hypertrophic obstructive cardiomyopathy: acute results and 3-month follow-up in 25 patients. *J Am Coll Cardiol* 1998; 31: 252-8.
- [2] Seggewiss H, Faber L, Gleichmann U. Percutaneous transluminal septal ablation in hypertrophic obstructive cardiomyopathy. *Thorac Cardiovasc Surg* 1999; 47: 94-100.
- [3] Kuhn H, Gietzen FH, Leuner C, *et al*. Transcoronary ablation of septal hypertrophy (TASH): a new treatment option for hypertrophic obstructive cardiomyopathy. *Z Kardiol* 2000; 89 Suppl 4: IV41-54.
- [4] Lakkis NM, Nagueh SF, Dunn JK, Killip D, Spencer WH, 3rd. Nonsurgical septal reduction therapy for hypertrophic obstructive cardiomyopathy: one-year follow-up. *J Am Coll Cardiol* 2000; 36: 852-5.
- [5] Boekstegers P, Steinbigler P, Molnar A, *et al*. Pressure-guided nonsurgical myocardial reduction induced by small septal infarctions in hypertrophic obstructive cardiomyopathy. *J Am Coll Cardiol* 2001; 38: 846-53.
- [6] de la Torre Hernandez JM, Masotti Centol M, Lereña Saenz P, *et al*. Effectiveness and Safety Beyond 10 Years of Percutaneous Transluminal Septal Ablation in Hypertrophic Obstructive Cardiomyopathy. *Rev Esp Cardiol* 2014; 67: 353-8.
- [7] Khouzam RN, Naidu SS. Current status and future perspectives on alcohol septal ablation for hypertrophic obstructive cardiomyopathy. *Curr Cardiol Rep* 2014; 16: 478.
- [8] Veselka J, Krejci J, Tomasov P, Zemanek D. Long-term survival after alcohol septal ablation for hypertrophic obstructive cardiomyopathy: a comparison with general population. *Eur Heart J* 2014; 35: 2040-5.
- [9] Jensen MK, Prinz C, Horstkotte D, *et al*. Alcohol septal ablation in patients with hypertrophic obstructive cardiomyopathy: low incidence of sudden cardiac death and reduced risk profile. *Heart* 2013; 99: 1012-7.
- [10] Veselka J, Lawrenz T, Stellbrink C, *et al*. Low incidence of procedure-related major adverse cardiac events after alcohol septal ablation for symptomatic hypertrophic obstructive cardiomyopathy. *Can J Cardiol* 2013; 29: 1415-21.

clinical risk stratification based on established risk factors for sudden death [4].

Many aspects of the above described technique have arbitrarily evolved through the years, mainly driven by the urge to deliver a safe and effective procedure, albeit without having been meticulously investigated [52]. MCE and use of lower alcohol volumes have been incorporated in the technique as they convincingly improved efficacy and safety of the treatment. Intracardiac echocardiography has been proposed as an alternative that could give full control of imaging to the interventionalist; it is however not free of complications or suboptimal results [53]. Preprocedure CT image acquisition for choosing the optimal septal branch has been proposed but has not gained acceptance, to a certain extent due to the additional ionising radiation burden [54, 55].

ALTERNATIVE INTERVENTIONAL TREATMENTS

Alcohol septal ablation has been referred in the literature under various acronyms which represent significantly different techniques (Table 2). Besides, various efforts have been made to ablate the septum without the use of alcohol. Covered stents in the LAD with occlusion of the septal branch

have resulted in failure to reduce the gradient due to collateral formation. Occlusion of the septal branch with coils [56], polyvinyl alcohol particles [57], used angioplasty wires [58], cyanoacrylate glue [59], gelatine particles or microspheres [60], as well as radiofrequency ablation [61] and cryoablation [62] have been tried but not gained unanimous enthusiasm.

COMPLICATIONS

Increased experience with the technique has reduced observed complications over the last two decades. The most common complication after alcohol septal ablation is complete heart block which could require permanent pacing. Up to 50% of patients may develop conduction defects in the first hours after alcohol injection, which resolves spontaneously in most cases (either in the cathlab or in the coronary care unit) [63]. This is due to the close proximity of the first septal branch with the His bundle or the right bundle branch [35, 64]. It is therefore vital to place a temporary pacemaker for the procedure, but only 5-10% of the patients will eventually need a permanent pacemaker [65, 66]. A scoring system based on ECG parameters, haemodynamic variables and myocardial enzyme release has been proposed for the predic-

tion of pacemaker dependency after alcohol septal ablation [67]. Essentially, patients with preexisting atrioventricular conduction abnormalities or left bundle branch block are at higher risk to develop complete heart block. In such patients implantation of a permanent pacemaker before alcohol septal ablation can be recommended [52]. In case the patient has an indication for ICD, preprocedural implantation is certainly practical.

It must be stressed that evolution of the original alcohol septal ablation technique with the addition of myocardial contrast echocardiography and use of lower alcohol volumes has led to a diminishing need for permanent pacing after the intervention [26, 33, 68].

Complications associated with the technical part of the procedure are influenced by the considerable learning curve and are rare in high-volume centres. Reported complications of this kind include coronary dissection, coronary spasm, cardiac tamponade, pulmonary embolism, cardiogenic shock, stroke and problems with the puncture site [69]. Special care should be taken to avoid alcohol leakage to the left anterior descending artery due to retrograde flow through an incompletely sealed septal branch or through collateral flow to other septal branches that could lead to an unwanted remote infarction [47]. Slippage or rupture of the balloon as well as premature retraction are also possible causes of alcohol spilling in the LAD [50, 70]. Although dreadful, these complications can be avoided by following a thorough interventional protocol (use of slightly oversized balloon, careful angiographic scrutiny of the septal branch, thorough observation of the balloon during slow alcohol injection, well-timed deflation 10 minutes after alcohol injection) [47, 49].

Imaging of the scar created by septal ablation with MRI has initiated a theoretical concern about the risk of malignant ventricular arrhythmias [71]. This anxiety has been further amplified by studies relating presence of late enhancement in MRI with non-sustained ventricular tachycardia in patients with HCM [72], as well as studies presenting data on ICD discharges after alcohol septal ablation [73]. Long-term follow-up studies have not, however, confirmed this concern, with sudden death or ICD discharge rates being very low [65, 66, 74-76]. On the contrary, both early [77] and late follow-up [65] studies have shown improvement of the sudden death risk profile after alcohol septal ablation with decrease of the number of risk factors for sudden death.

CLINICAL OUTCOME

From the beginning of alcohol septal ablation era numerous studies have shown relief of obstruction in $\geq 90\%$ of patients, which is associated with symptomatic improvement and increased exercise capacity [35, 78]. The subjectively valued improvement of the NYHA class has been repeatedly verified by objective measurements of cardiopulmonary exercise testing [48, 50, 79]. Long-term follow-up studies have shown an ongoing haemodynamic improvement with further reduction of the gradient after the first year that does not reappear after successful treatment [74]. Clinical improvement is in accordance with the observed reduction of degree of mitral regurgitation [74] and pulmonary artery pressure [33, 80]. In some patients treated for subaortic obstruction we might see an 'emerging' midventricular obstruction in

follow-up, signifying probably an originally larger area of obstruction. Accordingly, in about 3-14% of patients a second alcohol septal ablation procedure may be needed during follow-up [65, 66, 81], with most patients achieving relief of symptoms [81]. Adoption of a conservative approach with treatment of only one septal branch at every attempt and awaiting the result of remodeling can lead to increased number of procedures [82].

The first published long term (up to 8 years) follow-up study included all first 100 highly symptomatic patients (NYHA 2.8 \pm 0.6) treated with the echocardiography guided technique (Table 3) [74]. One patient died of pulmonary embolism in-hospital, while 8 patients received a permanent pacemaker. Survival at the end of follow-up (mean 58 \pm 14 months) was 99%, while survival without atrial fibrillation, stroke, ICD implantation and no or only mild symptoms was 74%.

In an early study from the Mayo Clinic of 601 patients referred for invasive therapy, 138 underwent alcohol septal ablation [83]. There were more procedural complications with alcohol septal ablation as compared to myectomy (death 1.4%, tamponade 3%, ventricular arrhythmias 3%, pacemaker implantation in 20%). Despite the assumed higher risk of the alcohol septal ablation patients, four-year survival was similar to myectomy patients (88%, $P=0.18$), while survival free of death and severe NYHA III/IV symptoms was 76.4%, with more than half of the patients becoming asymptomatic. The study was nonrandomized and included the early experience with alcohol septal ablation. Although procedural complications were high and patients under 65 years had better symptom resolution with myectomy, this study has illustrated the efficacy of alcohol septal ablation in a renowned myectomy centre.

In a more recent nonrandomized study from the same centre, 177 patients who underwent alcohol septal ablation were followed for 5.7 years and compared to an age- and sex-matched cohort of patients who underwent isolated myectomy [75]. Survival after alcohol septal ablation was similar to that after surgical myectomy (79% versus 79%, $P=0.64$), while it did not differ from survival in age- and sex-matched general population ($P=0.92$). Age and residual left ventricular gradient were independent predictors of long-term survival free of all-cause death. This study signifies an important milestone in the history of HCM, as it indicates that invasive treatments for HOCM not only improve symptoms but may influence the natural history of the disease by improving survival.

A recent study on 178 consecutive patients treated with alcohol septal ablation showed more or less comparable results [66]. Survival after 1, 5 and 10 years was 97%, 92% and 82% respectively and did not differ from survival in age- and sex-matched general population. The only independent predictor of all-cause mortality was age at alcohol septal ablation.

A European observational study on 470 consecutive patients treated with echo-guided alcohol septal ablation between 1996 and 2010 in Germany and Denmark showed 10-year survival of 88% and survival free of sudden death of 95%, which was similar to a matched general population

Table 3. Long-term follow-up studies after alcohol septal ablation.

Study	No. of patients	Age (years)	Pacemaker in-hospital (%)	Mean follow-up time (years)	In-hospital mortality (%)	Long-term all-cause mortality (%)	Redo procedures (%)	Myectomy (%)	Survival	Survival without symptoms
Seggewiss 2007 [1]	100	52.7±15.7	8	4.8±1.2	1	3			96% @ 8y	74%
Welge 2008 [2]	347	54±15	7	4.8±2.9	1	8	5	3	92%	74%
Sorajja 2008 [3]	138	64±21	20	2.2±2.8	1.4	8	4		88% @ 4y	76.4%
Kuhn 2008 [4]	329	58±15	17	2.1	1.8	7	13		91.1%	
Fernandes 2008 [5]	619	53.9±15.0	8.2	4.6±2.5	1	8	14	25	89% @ 8y	
Kwon 2008 [6]	55	63±13	25.5	8±1	0	24	5.5	5	76% @10y	
Noseworthy 2009 [7]	89			5.0±2.3		9	10	11	91%	
tenCate 2010 [8]	91	54±15	4	5.4±2.5	2	10	5	5	88%	
Lyne 2010 [9]	12	49±22	0	11.75	0	3	17	0		73% @ 10y
Sorajja 2012 [10]	177	63±13	20.3 @ 30d	5.7 (median)	1.2 @ 30d	14.7	2.8	5.6	79.4% @ 8y	78% @ 8y
Jensen 2013[11]	470	56±14	10	8.4±3.9	1.1	12			88% @10y	
Veselka 2014 [12]	178	58±12	8	5.2±3.7	0.6	11	3.6	1.1	82% @10y	
de la Torre 2014 [13]	45	62.4±14	6.6	12.3	0	20		0	82% @10y	

Adapted from Rigopoulos AG, Seggewiss H. A decade of percutaneous septal ablation in hypertrophic cardiomyopathy. *Circ J* 2010; 75(1): 28-37.

- [1] Seggewiss H, Rigopoulos A, Welge D, Ziemssen P, Faber L. Long-term follow-up after percutaneous septal ablation in hypertrophic obstructive cardiomyopathy. *Clin Res Cardiol* 2007; 96: 856-63.
- [2] Welge D, Seggewiss H, Fassbender D, Schmidt HK, Horstkotte D, Faber L. Long-term follow-up after percutaneous septal ablation in hypertrophic obstructive cardiomyopathy. *Dtsch Med Wochenschr* 2008; 133: 1949-54.
- [3] Sorajja P, Valeti U, Nishimura RA, *et al.* Outcome of alcohol septal ablation for obstructive hypertrophic cardiomyopathy. *Circulation* 2008; 118: 131-9.
- [4] Kuhn H, Lawrenz T, Lieder F, *et al.* Survival after transcatheter ablation of septal hypertrophy in hypertrophic obstructive cardiomyopathy (TASH): a 10 year experience. *Clin Res Cardiol* 2008; 97: 234-43.
- [5] Fernandes VL, Nielsen C, Nagueh SF, *et al.* Follow-up of alcohol septal ablation for symptomatic hypertrophic obstructive cardiomyopathy the Baylor and Medical University of South Carolina experience 1996 to 2007. *JACC* 2008; 1: 561-70.
- [6] Kwon DH, Kapadia SR, Tuzcu EM, *et al.* Long-term outcomes in high-risk symptomatic patients with hypertrophic cardiomyopathy undergoing alcohol septal ablation. *JACC* 2008;1: 432-8.
- [7] Noseworthy PA, Rosenberg MA, Fifer MA, *et al.* Ventricular arrhythmia following alcohol septal ablation for obstructive hypertrophic cardiomyopathy. *Am J Cardiol* 2009; 104: 128-32.
- [8] ten Cate FJ, Soliman OI, Michels M, *et al.* Long-term outcome of alcohol septal ablation in patients with obstructive hypertrophic cardiomyopathy: a word of caution. *Circ Heart Fail* 2010; 3: 362-9.
- [9] Lyne JC, Kilpatrick T, Duncan A, Knight CJ, Sigwart U, Fox KM. Long-term follow-up of the first patients to undergo transcatheter alcohol septal ablation. *Cardiology* 2010; 116: 168-73.
- [10] Sorajja P, Ommen SR, Holmes DR, Jr., *et al.* Survival after alcohol septal ablation for obstructive hypertrophic cardiomyopathy. *Circulation* 2012; 126: 2374-80.
- [11] Jensen MK, Prinz C, Horstkotte D, *et al.* Alcohol septal ablation in patients with hypertrophic obstructive cardiomyopathy: low incidence of sudden cardiac death and reduced risk profile. *Heart* 2013; 99: 1012-7.
- [12] Veselka J, Krejci J, Tomasov P, Zemanek D. Long-term survival after alcohol septal ablation for hypertrophic obstructive cardiomyopathy: a comparison with general population. *Eur Heart J* 2014; 35: 2040-5.
- [13] de la Torre Hernandez JM, Masotti Centol M, Lereña Saenz P, *et al.* Effectiveness and Safety Beyond 10 Years of Percutaneous Transluminal Septal Ablation in Hypertrophic Obstructive Cardiomyopathy. *Rev Esp Cardiol* 2014; 67: 353-8.

cohort [65]. Patients after alcohol septal ablation showed significant reduction of several risk factors for sudden death as abnormal blood pressure response (23% to 9%, $P<0.001$), syncope (26% to 2%, $P<0.001$), nonsustained ventricular tachycardia (23% to 17%, $P<0.05$), and maximal wall thick-

ness ≥ 30 mm (7% to 2%, $P<0.001$). Likewise, the absolute number of risk factors was significantly reduced, as was the proportion of patients at high risk, i.e. with ≥ 2 risk factors.

Furthermore, a recent multicentre study from Spain reported on the very long term (> 10 years) results including

the initial experience with alcohol septal ablation (45 patients treated from 1998 until 2003) [76]. Only one septal branch was ablated per patient and mean alcohol volume was 3.7 ml (2-7 ml). 10-year survival was 82%, while survival free from cardiac death or death from undetermined cause, re-intervention (either alcohol septal ablation or myectomy), symptomatic ventricular arrhythmia or advanced symptomatic recurrence associated with a high gradient was 84.1%.

So far, only one study has reported on an adverse outcome after alcohol septal ablation [84]. This study compared the outcomes between 91 patients treated with alcohol septal ablation and 40 patients who underwent myectomy. Primary endpoint was cardiac death and aborted sudden death including appropriate ICD discharges while secondary endpoints were noncardiac death and other nonfatal complications. After a follow-up of 5.4 ± 2.5 years 21 of patients met the primary endpoint. Survival free of the primary endpoint was 96%, 86% and 67% at 1, 5, and 8 years for septal ablation patients versus 100%, 96%, and 96%, respectively, for myectomy patients ($P=0.01$). The annual endpoint rate was roughly 5 times (4.4% vs. 0.9%) increased in the alcohol septal ablation group in comparison with myectomy group. This study has been however criticised for some technical aspects of alcohol septal ablation, as the large amount of ethanol volume administered, the use of saline flush between alcohol injections and the aim to abolish the gradient in the cath-lab [52, 65]. On the other hand, the use of ICD discharges as a surrogate for survival is questionable, as half of such events are not clinically significant whereas the increased number of ICDs in the alcohol septal ablation group may have led to overestimation bias [51].

Prediction of the late outcome after alcohol septal ablation has been the topic of various studies. Elimination of the gradient in the catheterisation laboratory and peak CK were deemed in an early study as independent predictors of haemodynamic success in one year [85]. Another study has described a biphasic course of the gradient in the first week after alcohol septal ablation with reappearance of a high gradient in many patients irrespective of late success or failure [86]. Peak CK rise combined with gradient measurement one week after the procedure were found to predict late outcome in most patients. Increasing experience has been shown to decrease complication rate and increase possibility of clinical success [87]. In a recent study from the Mayo Clinic, predictors of clinical success with alcohol septal ablation were older age (≥ 65 years), lower LVOT gradient (< 100 mmHg), less severe septal hypertrophy (≤ 18 mm) and smaller left atrium (left atrial diameter < 40 mm) [88]. Case volume with > 50 patients was also an independent predictor of survival free of symptoms. Morphology of mitral valve or interventricular septum as well as amount of ethanol, number of arteries treated and diameter of septal artery showed no predictive merit.

COMPARISON WITH SURGERY

Surgery is still considered the gold standard treatment for HOCM in the USA (given a class IIa recommendation in the latest American Guidelines for HOCM in comparison to Class IIb recommendation for alcohol septal ablation) [3]. The recent European recommendations have adopted a

common attitude towards septal reduction therapies distinguishing between them only in specific indications requiring surgical treatment of concomitant lesions [4]. In absence of an - anyhow improbable to organise - randomised trial [89], comparison between these treatment modalities is based on non-randomised and retrospective studies. Meta-analyses of these trials have shown comparable results in terms of in-hospital and long-term mortality, gradient reduction and symptomatic improvement, with alcohol septal ablation patients having a higher proportion of complete heart block requiring pacemaker implantation [90-92]. Long-term follow-up studies of alcohol septal ablation with judicious and unselective use of myocardial contrast echocardiography have shown, however, lower rates of pacemaker dependency [65, 66, 74, 93].

The decision to prefer the surgical or interventional treatment should be made in centres of excellence for the treatment of HOCM and septal reduction therapies should be performed by experienced operators [3, 4]. As many patients increasingly prefer the interventional treatment, a detailed discussion with the patient about the advantages and disadvantages of both therapies is essential for reaching an informed decision [94].

CONCLUSIONS & FUTURE PERSPECTIVE

In the twenty years after its introduction alcohol septal ablation has proved its merit and has evolved in an increasingly preferred treatment for drug refractory HOCM, not only for patients with increased surgical risk but also as a primarily selected option. Major technical advancements, as use of MCE and reduction of alcohol volumes have increased effectiveness and safety of the procedure and reduced complications. Most importantly, the advent of an interventional treatment has stimulated interest in the treatment of patients with a condition that previously was associated with high surgical risk.

Data on satisfactory long-term survival after alcohol septal ablation will undeniably increase acceptability of the interventional technique in the cardiological community. Moreover, further elucidation of the role of obstruction in long-term survival of patients with HOCM will probably lower the indication threshold for patients with fewer symptoms. One is certain, surgical myectomy and alcohol septal ablation should be regarded as complementary treatment modalities with different absolute indications, contraindications, risks and predilections [95].

CONFLICT OF INTEREST

The authors confirm that this article content has no conflict of interest.

ACKNOWLEDGEMENTS

Declared none.

REFERENCES

- [1] Elliott P, McKenna WJ. Hypertrophic cardiomyopathy. *Lancet* 2004; 363(9424): 1881-91.

- [2] Maron MS, Olivetto I, Zenovich AG, *et al.* Hypertrophic cardiomyopathy is predominantly a disease of left ventricular outflow tract obstruction. *Circulation* 2006; 114(21): 2232-9.
- [3] Gersh BJ, Maron BJ, Bonow RO, *et al.* 2011 ACCF/AHA Guideline for the Diagnosis and Treatment of Hypertrophic Cardiomyopathy: a report of the American College of Cardiology Foundation/American Heart Association Task Force on Practice Guidelines. Developed in collaboration with the American Association for Thoracic Surgery, American Society of Echocardiography, American Society of Nuclear Cardiology, Heart Failure Society of America, Heart Rhythm Society, Society for Cardiovascular Angiography and Interventions, and Society of Thoracic Surgeons. *J Am Coll Cardiol* 2011; 58(25): e212-260.
- [4] Elliott PM, Anastakis A, Borgers MA, *et al.* 2014 ESC Guidelines on diagnosis and management of hypertrophic cardiomyopathy: The Task Force for the Diagnosis and Management of Hypertrophic Cardiomyopathy of the European Society of Cardiology (ESC). *Eur Heart J* 2014; 35(39): 2733-79.
- [5] Cohen LS, Braunwald E. Amelioration of angina pectoris in idiopathic hypertrophic subaortic stenosis with beta-adrenergic blockade. *Circulation* 1967; 35(5): 847-51.
- [6] Harrison DC, Braunwald E, Glick G, Mason DT, Chidsey CA, Ross J, Jr. Effects of Beta Adrenergic Blockade on the Circulation with Particular Reference to Observations in Patients with Hypertrophic Subaortic Stenosis. *Circulation* 1964; 29: 84-98.
- [7] Cabrera-Bueno F, Garcia-Pinilla JM, Gomez-Doblas JJ, Montiel-Trujillo A, Rodriguez-Bailon I, de Teresa-Galvan E. Beta-blocker therapy for dynamic left ventricular outflow tract obstruction induced by exercise. *Int J Cardiol* 2007; 117(2): 222-6.
- [8] Sherrid MV, Barac I, McKenna WJ, *et al.* Multicenter study of the efficacy and safety of disopyramide in obstructive hypertrophic cardiomyopathy. *J Am Coll Cardiol* 2005; 45(8): 1251-8.
- [9] Kaltenbach M, Hopf R, Kober G, Bussmann WD, Keller M, Petersen Y. Treatment of hypertrophic obstructive cardiomyopathy with verapamil. *Br Heart J* 1979; 42(1): 35-42.
- [10] Rosing DR, Kent KM, Maron BJ, Epstein SE. Verapamil therapy: a new approach to the pharmacologic treatment of hypertrophic cardiomyopathy. II. Effects on exercise capacity and symptomatic status. *Circulation* 1979; 60(6): 1208-13.
- [11] Maron BJ. Appraisal of dual-chamber pacing therapy in hypertrophic cardiomyopathy: too soon for a rush to judgment? *J Am Coll Cardiol* 1996; 27(2): 431-2.
- [12] Maron BJ. Controversies in cardiovascular medicine. Surgical myectomy remains the primary treatment option for severely symptomatic patients with obstructive hypertrophic cardiomyopathy. *Circulation* 2007; 116(2): 196-206; discussion 206.
- [13] Ommen SR, Maron BJ, Olivetto I, *et al.* Long-term effects of surgical septal myectomy on survival in patients with obstructive hypertrophic cardiomyopathy. *J Am Coll Cardiol* 2005; 46(3): 470-6.
- [14] Heric B, Lytle BW, Miller DP, Rosenkranz ER, Lever HM, Cosgrove DM. Surgical management of hypertrophic obstructive cardiomyopathy. Early and late results. *J Thorac Cardiovasc Surg* 1995; 110(1): 195-206; discussion 206-198.
- [15] Morrow AG, Reitz BA, Epstein SE, *et al.* Operative treatment in hypertrophic subaortic stenosis. Techniques, and the results of pre and postoperative assessments in 83 patients. *Circulation* 1975; 52(1): 88-102.
- [16] Williams WG, Wigle ED, Rakowski H, Smallhorn J, LeBlanc J, Trusler GA. Results of surgery for hypertrophic obstructive cardiomyopathy. *Circulation* 1987; 76(5 Pt 2): V104-8.
- [17] Schoendube FA, Klues HG, Reith S, Flachskampf FA, Hanrath P, Messmer BJ. Long-term clinical and echocardiographic follow-up after surgical correction of hypertrophic obstructive cardiomyopathy with extended myectomy and reconstruction of the subvalvular mitral apparatus. *Circulation* 1995; 92(9 Suppl): II122-7.
- [18] McCully RB, Nishimura RA, Tajik AJ, Schaff HV, Danielson GK. Extent of clinical improvement after surgical treatment of hypertrophic obstructive cardiomyopathy. *Circulation* 1996; 94(3): 467-71.
- [19] Schonbeck MH, Brunner-La Rocca HP, Vogt PR, *et al.* Long-term follow-up in hypertrophic obstructive cardiomyopathy after septal myectomy. *Ann Thorac Surg* 1998; 65(5): 1207-14.
- [20] Schulte HD, Borisov K, Gams E, Gramsch-Zabel H, Losse B, Schwartzkopff B. Management of symptomatic hypertrophic obstructive cardiomyopathy--long-term results after surgical therapy. *Thorac Cardiovasc Surg* 1999; 47(4): 213-8.
- [21] Yu EH, Omran AS, Wigle ED, Williams WG, Siu SC, Rakowski H. Mitral regurgitation in hypertrophic obstructive cardiomyopathy: relationship to obstruction and relief with myectomy. *J Am Coll Cardiol* 2000; 36(7): 2219-25.
- [22] Deb SJ, Schaff HV, Dearani JA, Nishimura RA, Ommen SR. Septal myectomy results in regression of left ventricular hypertrophy in patients with hypertrophic obstructive cardiomyopathy. *Ann Thorac Surg* 2004; 78(6): 2118-22.
- [23] Woo A, Williams WG, Choi R, *et al.* Clinical and echocardiographic determinants of long-term survival after surgical myectomy in obstructive hypertrophic cardiomyopathy. *Circulation* 2005; 111(16): 2033-41.
- [24] Maron BJ, Nishimura RA, McKenna WJ, Rakowski H, Josephson ME, Kieval RS. Assessment of permanent dual-chamber pacing as a treatment for drug-refractory symptomatic patients with obstructive hypertrophic cardiomyopathy. A randomized, double-blind, crossover study (M-PATHY). *Circulation* 1999; 99(22): 2927-33.
- [25] Kwon DH, Kapadia SR, Tuzcu EM, *et al.* Long-term outcomes in high-risk symptomatic patients with hypertrophic cardiomyopathy undergoing alcohol septal ablation. *JACC Cardiovasc Interv* 2008; 1(4): 432-8.
- [26] Fifer MA. Controversies in cardiovascular medicine. Most fully informed patients choose septal ablation over septal myectomy. *Circulation* 2007; 116(2): 207-16; discussion 216.
- [27] Sigwart U, Grbic M, Essinger A, Rivier J. L'effet aigu d'une occlusion coronarienne par ballonnet de la dilatation transluminale. *Schweiz Med Wochenschr* 1982; 45: 1631.
- [28] Come PC, Riley MF. Hypertrophic cardiomyopathy. Disappearance of auscultatory, carotid pulse, and echocardiographic manifestations of obstruction following myocardial infarction. *Chest* 1982; 82(4): 451-4.
- [29] Brugada P, de Swart H, Smeets JL, Wellens HJ. Transcatheter chemical ablation of ventricular tachycardia. *Circulation* 1989; 79(3): 475-82.
- [30] Kuhn H, Gietzen F, Leuner C, Gerenkamp T. Induction of subaortic septal ischaemia to reduce obstruction in hypertrophic obstructive cardiomyopathy. Studies to develop a new catheter-based concept of treatment. *Eur Heart J* 1997; 18(5): 846-51.
- [31] Sigwart U. Non-surgical myocardial reduction for hypertrophic obstructive cardiomyopathy. *Lancet* 1995; 346(8969): 211-4.
- [32] Goodwin JF, Oakley CM. Non-surgical myocardial reduction for hypertrophic obstructive cardiomyopathy. *Lancet* 1995; 346(8990): 1624.
- [33] Faber L, Seggewiss H, Gleichmann U. Percutaneous transluminal septal myocardial ablation in hypertrophic obstructive cardiomyopathy: results with respect to intraprocedural myocardial contrast echocardiography. *Circulation* 1998; 98(22): 2415-21.
- [34] Rigopoulos AG, Seggewiss H. A decade of percutaneous septal ablation in hypertrophic cardiomyopathy. *Circ J* 2011; 75(1): 28-37.
- [35] Seggewiss H, Rigopoulos A. Alcohol septal ablation for hypertrophic obstructive cardiomyopathy. *Percutaneous Interventional Cardiovascular Medicine, The PCR-EAPCI Textbook, Vol III*. Toulouse, France: Europa Edition; 2012: 461-76.
- [36] Seggewiss H, Faber L. Percutaneous septal ablation for hypertrophic cardiomyopathy and mid-ventricular obstruction. *Eur J Echocardiogr* 2000; 1(4): 277-80.
- [37] Cavalcanti JL, Barboza JS, Lever HM. Diversity of mitral valve abnormalities in obstructive hypertrophic cardiomyopathy. *Prog Cardiovasc Dis* 2012; 54(6): 517-22.
- [38] Pfeiffer B, Rigopoulos A, Neugebauer A, Seggewiss H. Clandestine subaortic stenosis as a cause of left ventricular outflow tract obstruction in patients with hypertrophic obstructive cardiomyopathy. *Eur Heart J* 2014; 35(Abstr Suppl): 1096 (Abstract).
- [39] Seggewiss H, Faber L, Meyners W, Bogunovic N, Odenthal HJ, Gleichmann U. Simultaneous percutaneous treatment in hypertrophic obstructive cardiomyopathy and coronary artery disease: a case report. *Cathet Cardiovasc Diagn* 1998; 44(1): 65-69.
- [40] Harold JG, Bass TA, Bashore TM, *et al.* ACCF/AHA/SCAI 2013 update of the clinical competence statement on coronary artery interventional procedures: a report of the American College of Cardiology Foundation/American Heart Association/American College of Physicians Task Force on Clinical Competence and Training (Writing Committee to Revise the 2007 Clinical Competence Statement on Cardiac Interventional Procedures). *J Am Coll Cardiol* 2013; 62(4): 357-96.

- [41] Cuisset T, Franceschi F, Prevot S, *et al.* Transradial approach and subclavian wired temporary pacemaker to increase safety of alcohol septal ablation for treatment of obstructive hypertrophic cardiomyopathy: the TRASA trial. *Archiv Cardiovasc Dis* 2011; 104(8-9): 444-9.
- [42] Singh M, Edwards WD, Holmes DR, Jr., Tajil AJ, Nishimura RA. Anatomy of the first septal perforating artery: a study with implications for ablation therapy for hypertrophic cardiomyopathy. *Mayo Clin Proc* 2001; 76(8): 799-802.
- [43] Angelini P. The "1st septal unit" in hypertrophic obstructive cardiomyopathy: a newly recognized anatomic-functional entity, identified during recent alcohol septal ablation experience. *Tex Heart Inst J* 2007; 34(3): 336-46.
- [44] Rigopoulos AG, Pfeiffer B, Seggewiss H. Serial septal branch assessment in hypertrophic obstructive cardiomyopathy: New echocardiographic contrast agent for alcohol septal ablation. *Herz* 2014; 39(2): 219-21.
- [45] Pfeiffer B, Rigopoulos A, Seggewiss H. Myocardial contrast echocardiography guided alcohol septal ablation in hypertrophic obstructive cardiomyopathy with a new echocardiographic contrast agent. *Dtsch Med Wochenschr* 2012; 137(41): 2093-6.
- [46] Pfeiffer B, Rigopoulos A, Seggewiss H. Myocardial contrast echocardiography in alcohol septal ablation for hypertrophic obstructive cardiomyopathy: a comparison of three different contrast agents. *Eur J Echocardiography Abstracts Supplement* 2012; 13(S1): i177 (abstract).
- [47] Rigopoulos A, Sepp R, Palinkas A, Ungi I, Kremastinos DT, Seggewiss H. Alcohol septal ablation for hypertrophic obstructive cardiomyopathy: collateral vessel communication between septal branches. *Int J Cardiol* 2006; 113(2): e67-69.
- [48] Faber L, Seggewiss H, Welge D, *et al.* Echo-guided percutaneous septal ablation for symptomatic hypertrophic obstructive cardiomyopathy: 7 years of experience. *Eur J Echocardiogr* 2004; 5(5): 347-55.
- [49] Seggewiss H. Current status of alcohol septal ablation for patients with hypertrophic cardiomyopathy. *Curr Cardiol Rep* 2001; 3(2): 160-6.
- [50] Ruzyllo W, Chojnowska L, Demkow M, *et al.* Left ventricular outflow tract gradient decrease with non-surgical myocardial reduction improves exercise capacity in patients with hypertrophic obstructive cardiomyopathy. *Eur Heart J* 2000; 21(9): 770-7.
- [51] Khouzam RN, Naidu SS. Current status and future perspectives on alcohol septal ablation for hypertrophic obstructive cardiomyopathy. *Curr Cardiol Rep* 2014; 16(5): 478.
- [52] Gimeno JR, Tome MT, McKenna WJ. Alcohol septal ablation in hypertrophic cardiomyopathy: an opportunity to be taken. *Rev Esp Cardiol (English ed)* 2012; 65(4): 314-8.
- [53] Alfonso F, Martin D, Fernandez-Vazquez F. Intracardiac echocardiography guidance for alcohol septal ablation in hypertrophic obstructive cardiomyopathy. *J Invasive Cardiol* 2007; 19(5): E134-6.
- [54] Ghersin E, Soto V, Heldman AW. Multidetector computerized tomography can guide and document alcohol septal ablation in hypertrophic obstructive cardiomyopathy. *Circulation* 2011; 123(2): e5-7.
- [55] Krishnaswamy A, Tuzcu EM, Kapadia SR. Use of intraprocedural CT imaging to guide alcohol septal ablation of hypertrophic cardiomyopathy in the cardiac catheterization laboratory. *Catheter Cardiovasc Interv* 2012; 80(6): 991-4.
- [56] Durand E, Mousseaux E, Coste P, *et al.* Non-surgical septal myocardial reduction by coil embolization for hypertrophic obstructive cardiomyopathy: early and 6 months follow-up. *Eur Heart J* 2008; 29(3): 348-55.
- [57] Gross CM, Schulz-Menger J, Kramer J, *et al.* Percutaneous transluminal septal artery ablation using polyvinyl alcohol foam particles for septal hypertrophy in patients with hypertrophic obstructive cardiomyopathy: acute and 3-year outcomes. *J Endovasc Ther* 2004; 11(6): 705-11.
- [58] Trehan V, Mukhopadhyay S, Rangasetty UC. Percutaneous transseptal myocardial ablation with wire (PTSAW): a new technique. *J Invasive Cardiol* 2004; 16(4): 204-6.
- [59] Oto A, Aytemir K, Deniz A. New approach to septal ablation: glue (cyanoacrylate) septal ablation. *Catheter Cardiovasc Interv* 2007; 69(7): 1021-5.
- [60] Latsios G, Gerckens U, Mueller R, Grube E. Substitution of ethanol with specially designed microspheres in a TASH procedure. *Euro-Intervention* 2011; 6(7): 889-92.
- [61] Lawrenz T, Borchert B, Leuner C, *et al.* Endocardial radiofrequency ablation for hypertrophic obstructive cardiomyopathy acute results and 6 months' follow-up in 19 patients. *J Am Coll Cardiol* 2001; 37(5): 572-6.
- [62] Cheng TO. Percutaneous septal cryoablation for the treatment of hypertrophic cardiomyopathy. *J Invasive Cardiol* 2007; 19(8): 357.
- [63] Reinhard W, Ten Cate FJ, Scholten M, De Laat LE, Vos J. Permanent pacing for complete atrioventricular block after nonsurgical (alcohol) septal reduction in patients with obstructive hypertrophic cardiomyopathy. *Am J Cardiol* 2004; 93(8): 1064-6.
- [64] Talreja DR, Nishimura RA, Edwards WD, *et al.* Alcohol septal ablation versus surgical septal myectomy: comparison of effects on atrioventricular conduction tissue. *J Am Coll Cardiol* 2004; 44(12): 2329-32.
- [65] Jensen MK, Prinz C, Horstkotte D, *et al.* Alcohol septal ablation in patients with hypertrophic obstructive cardiomyopathy: low incidence of sudden cardiac death and reduced risk profile. *Heart* 2013; 99(14): 1012-7.
- [66] Veselka J, Krejci J, Tomasov P, Zemanek D. Long-term survival after alcohol septal ablation for hypertrophic obstructive cardiomyopathy: a comparison with general population. *Eur Heart J* 2014; 35(30): 2040-5.
- [67] Faber L, Welge D, Fassbender D, Schmidt HK, Horstkotte D, Seggewiss H. Percutaneous septal ablation for symptomatic hypertrophic obstructive cardiomyopathy: managing the risk of procedure-related AV conduction disturbances. *Int J Cardiol* 2007; 119(2): 163-7.
- [68] Veselka J, Zemanek D, Tomasov P, Homolova S, Adlova R, Tesar D. Complications of low-dose, echo-guided alcohol septal ablation. *Catheter Cardiovasc Interv* 2010; 75(4): 546-50.
- [69] Alam M, Dokainish H, Lakkis N. Alcohol septal ablation for hypertrophic obstructive cardiomyopathy: a systematic review of published studies. *J Interv Cardiol* 2006; 19(4): 319-27.
- [70] Antolin Perez MJ, de la Morena Valenzuela G, Gimeno Blanes JR, *et al.* Balloon rupture and alcohol leakage into the left anterior descending coronary artery during percutaneous septal ablation for hypertrophic obstructive cardiomyopathy. *Rev Esp Cardiol* 2005; 58(7): 872-4.
- [71] Valeti US, Nishimura RA, Holmes DR, *et al.* Comparison of surgical septal myectomy and alcohol septal ablation with cardiac magnetic resonance imaging in patients with hypertrophic obstructive cardiomyopathy. *J Am Coll Cardiol* 2007; 49(3): 350-7.
- [72] Moon JC, McKenna WJ, McCrohon JA, Elliott PM, Smith GC, Pennell DJ. Toward clinical risk assessment in hypertrophic cardiomyopathy with gadolinium cardiovascular magnetic resonance. *J Am Coll Cardiol* 2003; 41(9): 1561-7.
- [73] Noseworthy PA, Rosenberg MA, Fifer MA, *et al.* Ventricular arrhythmia following alcohol septal ablation for obstructive hypertrophic cardiomyopathy. *Am J Cardiol* 2009; 104(1): 128-32.
- [74] Seggewiss H, Rigopoulos A, Welge D, Ziemssen P, Faber L. Long-term follow-up after percutaneous septal ablation in hypertrophic obstructive cardiomyopathy. *Clin Res Cardiol* 2007; 96(12): 856-63.
- [75] Sorajja P, Ommen SR, Holmes DR, Jr., *et al.* Survival after alcohol septal ablation for obstructive hypertrophic cardiomyopathy. *Circulation* 2012; 126(20): 2374-80.
- [76] de la Torre Hernandez JM, Masotti Centol M, Lerena Saenz P, *et al.* Effectiveness and Safety Beyond 10 Years of Percutaneous Transluminal Septal Ablation in Hypertrophic Obstructive Cardiomyopathy. *Rev Esp Cardiol* 2014; 67(5): 353-8.
- [77] Seggewiss H, Faber L, Ziemssen P, Gleichmann U. One-year follow-up after echocardiographically-guided percutaneous septal ablation in hypertrophic obstructive cardiomyopathy. *Dtsch Med Wochenschr* 2001; 126(15): 424-30.
- [78] Rigopoulos AG, Panou F, Kremastinos DT, Seggewiss H. Alcohol septal ablation in hypertrophic obstructive cardiomyopathy. *Hellenic J Cardiol* 2009; 50(6): 511-22.
- [79] Faber L, Welge D, Fassbender D, Schmidt HK, Horstkotte D, Seggewiss H. One-year follow-up of percutaneous septal ablation for symptomatic hypertrophic obstructive cardiomyopathy in 312 patients: predictors of hemodynamic and clinical response. *Clin Res Cardiol* 2007; 96(12): 864-73.
- [80] Gietzen FH, Leuner CJ, Raute-Kreinsen U, Dellmann A, Hegselmann J, Strunk-Mueller C, Kuhn HJ. Acute and long-term results after transcatheter ablation of septal hypertrophy (TASH). *Cathe-*

- ter interventional treatment for hypertrophic obstructive cardiomyopathy. *Eur Heart J* 1999; 20(18): 1342-54.
- [81] Fernandes VL, Nielsen C, Nagueh SF, *et al.* Follow-up of alcohol septal ablation for symptomatic hypertrophic obstructive cardiomyopathy the Baylor and Medical University of South Carolina experience 1996 to 2007. *JACC Cardiovasc Interv* 2008; 1(5): 561-70.
- [82] Rigopoulos A, Neugebauer A, Pfeiffer B, Seggewiss H. Survival after alcohol septal ablation in hypertrophic obstructive cardiomyopathy: results from a consecutive patient cohort. *Eur Heart J* 2014; 35(Abstract Supplement): 921-2 (Abstract).
- [83] Sorajja P, Valeti U, Nishimura RA, *et al.* Outcome of alcohol septal ablation for obstructive hypertrophic cardiomyopathy. *Circulation* 2008; 118(2): 131-9.
- [84] ten Cate FJ, Soliman OI, Michels M, *et al.* Long-term outcome of alcohol septal ablation in patients with obstructive hypertrophic cardiomyopathy: a word of caution. *Circ Heart Fail* 2010; 3(3): 362-9.
- [85] Chang SM, Lakkis NM, Franklin J, Spencer WH, 3rd, Nagueh SF. Predictors of outcome after alcohol septal ablation therapy in patients with hypertrophic obstructive cardiomyopathy. *Circulation* 2004; 109(7): 824-7.
- [86] Keren A, Poteckin M, Mazouz B, *et al.* Late in-hospital pressure gradient measurements improve prediction of long-term outcome of alcohol septal ablation in hypertrophic cardiomyopathy. *Isr Med Assoc J* 2007; 9(4): 239-42.
- [87] van der Lee C, Scholzel B, ten Berg JM, *et al.* Usefulness of clinical, echocardiographic, and procedural characteristics to predict outcome after percutaneous transluminal septal myocardial ablation. *Am J Cardiol* 2008; 101(9): 1315-20.
- [88] Sorajja P, Binder J, Nishimura RA, *et al.* Predictors of an optimal clinical outcome with alcohol septal ablation for obstructive hypertrophic cardiomyopathy. *Catheter Cardiovasc Interv* 2013; 81(1): E58-67.
- [89] Olivetto I, Ommen SR, Maron MS, Cecchi F, Maron BJ. Surgical myectomy versus alcohol septal ablation for obstructive hypertrophic cardiomyopathy. Will there ever be a randomized trial? *J Am Coll Cardiol* 2007; 50(9): 831-4.
- [90] Alam M, Dokainish H, Lakkis NM. Hypertrophic obstructive cardiomyopathy-alcohol septal ablation vs. myectomy: a meta-analysis. *Eur Heart J* 2009; 30(9): 1080-7.
- [91] Leonardi RA, Kransdorf EP, Simel DL, Wang A. Meta-analyses of septal reduction therapies for obstructive hypertrophic cardiomyopathy: comparative rates of overall mortality and sudden cardiac death after treatment. *Circ Cardiovasc Interv* 2010; 3(2): 97-104.
- [92] Agarwal S, Tuzcu EM, Desai MY, *et al.* Updated meta-analysis of septal alcohol ablation versus myectomy for hypertrophic cardiomyopathy. *J Am Coll Cardiol* 2010; 55(8): 823-34.
- [93] Welge D, Seggewiss H, Fassbender D, Schmidt HK, Horstkotte D, Faber L. Long-term follow-up after percutaneous septal ablation in hypertrophic obstructive cardiomyopathy. *Dtsch Med Wochenschr* 2008; 133(39): 1949-54.
- [94] Fifer MA, Sigwart U. Controversies in cardiovascular medicine. Hypertrophic obstructive cardiomyopathy: alcohol septal ablation. *Eur Heart J* 2007; 32(9): 1059-64.
- [95] Rigopoulos AG, Seggewiss H. Hypertrophic cardiomyopathy. *Lancet* 2013; 381(9876): 1456.