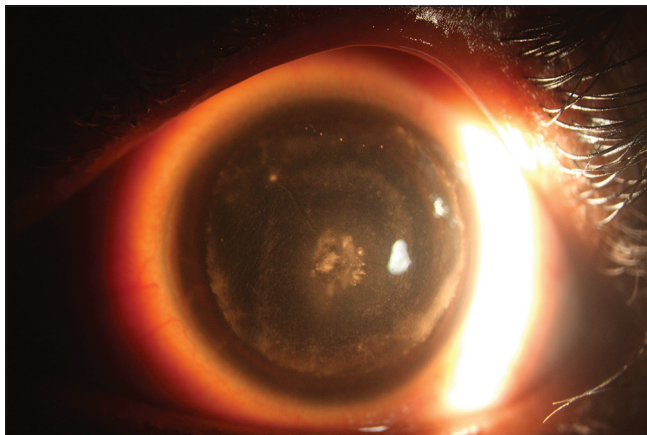


## Multi-drug resistant *Burkholderia cepacia* keratitis following laser *in situ* keratomileusis complicated by interface fluid syndrome

Vaibhav Kanduri, Bhagyashree Madduri<sup>1</sup>,  
Nitin Mohan<sup>1</sup>, Merle Fernandes

**Key words:** *Burkholderia cepacia*, interface fluid syndrome, post LASIK microbial keratitis

A 26-year-old female was referred to us with left eye microbial keratitis following laser in-situ keratomileusis (LASIK) done a month ago. The vision was 20/1200. The left eye had a central infiltrate involving the flap and beyond [Fig. 1]. Corneal scrapings revealed short gram-negative bacilli. Hourly topical



**Figure 1:** Image of the left eye with sclerotic scatter, showing a central epithelial defect, underlying patchy infiltrate (2.8 × 2.5 mm) involving flap and interface, dense cellular reaction in the interface in the form of an incomplete ring with dense cellularity at the flap margins involving the flap as well as the interface

Access this article online	
<b>Quick Response Code:</b>	<b>Website:</b> www.ijo.in
	<b>DOI:</b> 10.4103/ijo.IJO_1633_19

Cornea and Anterior Segment, LV Prasad Eye Institute, GMR Varalakshmi Campus, <sup>1</sup>Ocular Microbiology Service, LV Prasad Eye Institute, GMR Varalakshmi Campus, Visakhapatnam, Andhra Pradesh, India

**Correspondence to:** Dr. Merle Fernandes, Cornea and Anterior Segment Service, L V Prasad Eye Institute, GMR Varalakshmi Campus, Hanumanthawaka Jn, Visakhapatnam - 530 040, Andhra Pradesh, India. E-mail: merle@lvpei.org

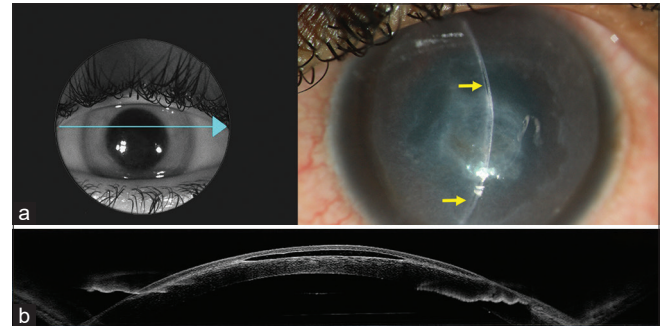
Received: 05-Sep-2019

Revision: 27-Oct-2019

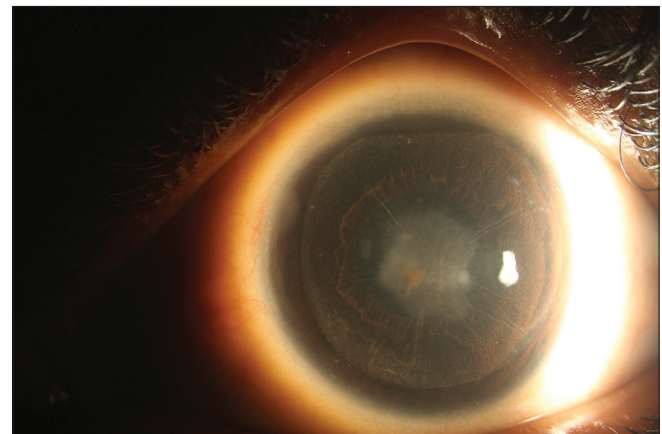
Accepted: 20-Feb-2020

Published: 25-Jun-2020

fortified cefuroxime sodium (5%) and ofloxacin (0.3%) were commenced. *Burkholderia cepacia* cultures were sensitive to imipenem and amikacin, intermediate sensitivity to ceftazidime, and resistant to all other antibiotics using the VITEK 2 system (bioMerieux, USA). Therapy was switched to fortified amikacin sulfate (2.5%) eye drops, ceftazidime sodium (5%) eye drops hourly, and betamethasone sodium phosphate (0.1%) eye drops 4 times daily. Two weeks later, her vision deteriorated with the appearance of interface fluid [Fig. 2]. Digital tension was elevated. Interface fluid disappeared following steroid discontinuation. The complete resolution took 3 months [Fig. 3] with a vision of 20/50.



**Figure 2:** (a) (upper right corner): Slit lamp image of the left eye showing interface fluid causing separation of the flap superiorly and inferiorly (arrow) and patchy infiltrate involving the flap and interface with anterior stromal scarring and diffuse cellularity in the interface extending till the flap edge without increase in congestion or anterior chamber reaction. (b) Anterior segment OCT (DRI OCT Triton, Topcon, Tokyo, Japan) of the cornea showing an elevated flap with fluid in the interface, and interface haze



**Figure 3:** Image of the left eye with sclerotic scatter, 4 months later, showing a central scar, with interface haze

This is an open access journal, and articles are distributed under the terms of the Creative Commons Attribution-NonCommercial-ShareAlike 4.0 License, which allows others to remix, tweak, and build upon the work non-commercially, as long as appropriate credit is given and the new creations are licensed under the identical terms.

**For reprints contact:** reprints@medknow.com

**Cite this article as:** Kanduri V, Madduri B, Mohan N, Fernandes M. Multi-drug resistant *Burkholderia cepacia* keratitis following laser *in situ* keratomileusis complicated by interface fluid syndrome. Indian J Ophthalmol 2020;68:1443-4.

## Discussion

*B. cepacia* is a notorious multidrug resistant organism and a significant cause of morbidity and mortality.<sup>[1]</sup> Keratitis due to *Burkholderia* species is uncommon. The risk factors include corneal transplants,<sup>[2,3]</sup> prior herpes simplex virus (HSV) keratitis,<sup>[4]</sup> orthokeratology lens wear<sup>[5]</sup>, and cataract surgery.<sup>[6]</sup> Microbial keratitis post LASIK is about 0–1.5%.<sup>[7]</sup> *Burkholderia pickettii* was responsible for diffuse lamellar keratitis following LASIK.<sup>[8]</sup> However, *B. cepacia* keratitis following LASIK is extremely rare with only one case reported prior.<sup>[9]</sup> Our patient had a patchy central infiltrate with a dense cellular reaction in the interface similar to an immune ring, hence topical steroids were started. This led to interface fluid syndrome (IFS), which resolved on discontinuation of steroids. IFS can occur following a steroid response, toxic anterior segment syndrome, herpetic keratouveitis, or dysfunctional endothelium<sup>[10]</sup> but has not been reported with microbial keratitis. Fluid accumulates in the potential space in the interface. Topical steroids or intraocular inflammation could have precipitated a rise in intraocular pressure and IFS in our case.

*B. cepacia* in our patient was multidrug resistant similar to a previous report.<sup>[9]</sup> However, a relapse was noted in the latter 3 weeks after treatment initiation. Our patient recovered completely over 3 months with a combination of ceftazidime and amikacin.

Multidrug resistant *B. cepacia* keratitis following LASIK is extremely rare necessitating prompt microbiological work-up with combination drug therapy for resolution of infection. IFS may occur due to topical steroids or intraocular inflammation and hence concomitant inflammation requires judicious use of steroids.

### Declaration of patient consent

The authors certify that they have obtained all appropriate patient consent forms. In the form the patient(s) has/have given his/her/their consent for his/her/their images and other clinical information to be reported in the journal. The patients understand that their names and initials will not be published

and due efforts will be made to conceal their identity, but anonymity cannot be guaranteed.

### Financial support and sponsorship

This work was supported by the Hyderabad Eye Research Foundation.

### Conflicts of interest

There are no conflicts of interest.

## References

1. Gautam V, Singhal L, Ray P. *Burkholderia cepacia* complex: Beyond pseudomonas and acinetobacter. *Indian J Med Microbiol* 2011;29:4-12.
2. Ritterband D, Shah M, Cohen K, Lawrence J, Seedor J. *Burkholderia gladioli* keratitis associated with consecutive recurrent endophthalmitis. *Cornea* 2002;21:602-3.
3. Chaurasia S, Muralidhar R, Das S, Sangwan VS, Reddy AK, Gopinathan U. Keratitis caused by *Burkholderia cepacia*. *Br J Ophthalmol* 2011;95:746-7.
4. Matoba AY. Polymicrobial keratitis secondary to *Burkholderia ambifaria*, *Enterococcus*, and *Staphylococcus aureus* in a patient with herpetic stromal keratitis. *Am J Ophthalmol* 2003;136:748-9.
5. Ying-Cheng L, Chao-Kung L, Ko-Hua C, Wen-Ming H. Daytime orthokeratology associated with infectious keratitis by multiple Gram-negative bacilli: *Burkholderia cepacia*, *Pseudomonas putida*, and *Pseudomonas aeruginosa*. *Eye Contact Lens* 2006;32:19-20.
6. Ornek K, Ozdemir M, Ergin A. *Burkholderia cepacia* keratitis with endophthalmitis. *J Med Microbiol* 2009;58:1517-8.
7. Chang MA, Jain S, Azar DT. Infections following laser *in situ* keratomileusis: An integration of the published literature. *Surv Ophthalmol* 2004;49:269-80.
8. Holland SP, Mathias RG, Morck DW, Chiu J, Slade SG. Diffuse lamellar Keratitis related to endotoxins released from sterilizer reservoir biofilms. *Ophthalmology* 2000;107:1227-33.
9. Reddy JC, Tibbetts MD, Hammersmith KM, Nagra PK, Rapuano CJ. Successful management of *Burkholderia cepacia* keratitis after LASIK. *J Refract Surg* 2013;29:8-9.
10. Randleman JB, Shah RD. LASIK Interface complications: Etiology, risk factors and outcomes. *J Refract Surg* 2012;28:575-86.