



Case Report

Primary umbilical cutaneous endometriosis: The first case report in Syria

Hidar Alibrahim^a, Mouhammad Albattour^b, Sarya Swed^{a,*}, Bisher Sawaf^c,
Maher Ali Hussein Al-Janabi^d

^a Faculty of Human Medicine, Aleppo University, Aleppo, Syria

^b Department of General Surgery, Alrazi Hospital, Aleppo, Syria

^c Department of Internal Medicine, Syrian Private University, Damascus, Syria

^d Department of Oncology, Aleppo University Hospital, Aleppo, Syria

ARTICLE INFO

Keywords:

Cutaneous endometriosis

Case report

Uterus

Navel

ABSTRACT

Endometriosis in the umbilical region is a very rare case. Although it is possible to have migrating endometrial glands and stroma outside the uterus, for example, the ovaries, fallopian tubes, and other pelvic organs, the umbilicus is a unique place. In our case it was a 40-year-old female patient with no surgical history. She has been suffering for years from symptoms that are very consistent with endometriosis in terms of pain, mass and bleeding. but the diagnostic procedures from imaging and pathology have been taken completely up, then the case was managed while preserving the patient's reproductive function.

1. Introduction

Endometriosis is a rare condition where endometrial glands and stroma that are located outside their original location. Endometriosis was first determined to be a separate condition in the 1920s [1]. Before that time, endometriosis and adenomyosis were considered one entity. But in general, endometriosis can be classified into two types. Primary, which is the presence of ectopic endometrial tissue outside the uterus in the absence of previous surgical procedures in that area. Secondary, which can result from laparoscopic or open surgery. The most common symptom is pelvic pain that increases during menstruation, there are also other symptoms such as pain during intercourse, dysmenorrhea, and infertility, although 20–25% of women are asymptomatic [2]. For the diagnosis, we need to combine information from physical exam findings and imaging studies represented by ultrasound and computed tomography, but the cornerstone in confirming the diagnosis is the histopathology that shows the endometrial tissue. The management of endometriosis depends on many factors. The most important ones are the patient's age and whether or not she wants to have children. But in many cases, menopause (natural or surgical) will abate the process [3]. We present a typical case of umbilical endometriosis in a woman with previous deliveries with symptoms of pain and bleeding for three years. (see Figs. 1–3)

This case report has been reported in line with the SCARE criteria

2020.

2. Case presentation

A 40-year-old woman was admitted to the General Surgery Clinic of the AL Razy Hospital complaining of pain with bleeding started three years ago in the umbilical region concomitant to the menstrual period. The patient medical history shows that she had six previous pregnancies, including five live births and one miscarriage. The patient denied using cigarettes or alcohol. She had no previous surgery or allergy to any drugs. She has no family history that may suggest genetic factors for umbilical endometriosis. On physical examination, we found: Globose abdomen, flaccid, peristalsis present, painless to the superficial palpation and without signs of peritoneal irritation. In the umbilical region, painful bulging was observed on palpation, adhered to the deep plane and of 3 hardened consistency of about 2.5 cm in diameter. Deep palpation did not reveal visible pulsatile or signs of other abdominal pathology. As a further investigation, we conducted comprehensive diagnostic imaging, including ultrasonography of the pelvis and abdomen. The first imaging study revealed no alterations in the pelvic organs, thus excluding endometriosis in this cavity. The second one showed subcutaneous and muscular tissue of normal aspects. Only mass is measuring about 3.5 cm in the umbilical region, without signs of rupture. Finally, in order to confirm the diagnosis, we requested a biopsy

* Corresponding author.

E-mail addresses: haideralibrahem1999@gmail.com (H. Alibrahim), battour2017@gmail.com (M. Albattour), saryaswed1@gmail.com (S. Swed), bishersawaf.94@gmail.com (B. Sawaf), mahoriali@yahoo.com (M.A. Hussein Al-Janabi).

<https://doi.org/10.1016/j.amsu.2021.103106>

Received 21 October 2021; Received in revised form 20 November 2021; Accepted 21 November 2021

Available online 25 November 2021

2049-0801/© 2021 The Authors. Published by Elsevier Ltd on behalf of IJS Publishing Group Ltd. This is an open access article under the CC BY-NC-ND license

(<http://creativecommons.org/licenses/by-nc-nd/4.0/>).

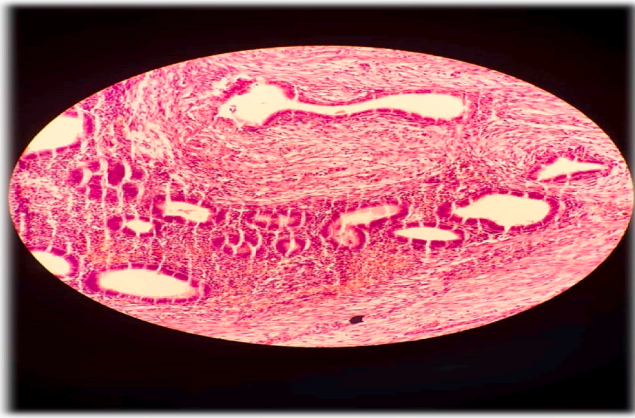


Fig. 1. Cutaneous endometriosis - microscopic features: Cystic cavity lined by monomorphous cuboidal cells. Haematoxylin and eosin, original magnification.

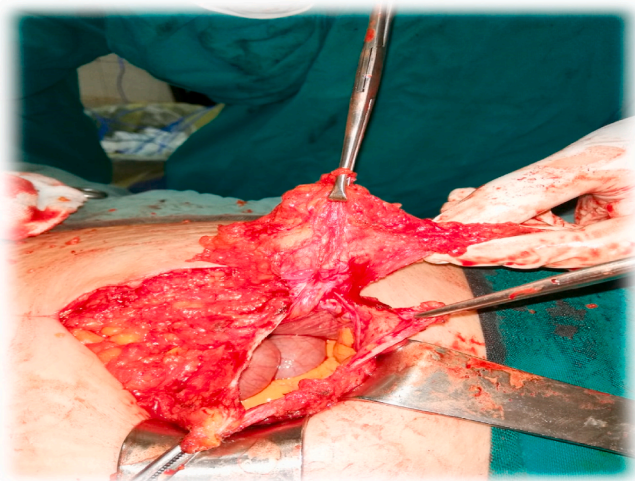


Fig. 2. This image is during the resection of the umbilical endometriosis.

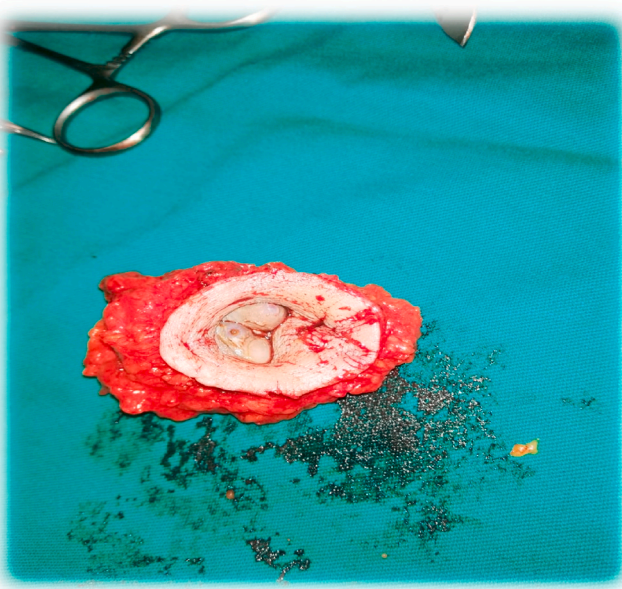


Fig. 3. This image shows the removed umbilical endometriosis.

from the umbilical region and sent it to pathology lab. Furthermore, it is important to exclude other pathologies such as malignant melanoma. The Sister Joseph nodule is a manifestation of intra-abdominal malignancy or other dermatological conditions. The histopathology report confirmed endometriosis in the umbilical region. A specimen stained with Hamtoxylin & Eosin showed the presence of endometrial type stroma and endometrial epithelium with glands. In the course of treatment, we performed surgery with complete excision and umbilical reconstruction. After that, the patient remained in the hospital for 48 hours, covered with antibiotics to prevent any infection in the surgical site, where her condition stabilized and she was discharged in good health.

3. Discussion

Endometriosis is a disease of the female reproductive system in which cells similar to those in the endometrium, the layer of tissue that normally covers the inside of the uterus; grow outside the uterus [4]. The main reason for this condition is still not entirely clear, but several theories suggest some causes, including retrograde menstruation, direct spread, embryonal rest, coelomic metaplasia, and lymphatic or haematogenous spreading [5]. In most cases, endometriosis is found in the pelvis, specifically in the ovaries, fallopian tubes, or other pelvic organs. However, in very rare cases, it is found in the umbilical region. This rare location raises the suspicion of many conditions, the most important one is malignant melanoma and some other diseases that make the final diagnosis difficult and requires many investigations. The umbilical form accounts for 1% of all cases of extra pelvic endometriosis. Other sites may be affected, such as the perineum, articular regions, pericardium, pleura, and central nervous system. Generally, It is characterized by a nodule of variable size having colors ranging from red to blue or black. It is almost always cyclical in nature, and there is an increase in volume and pain in the premenstrual and menstrual periods. Diagnosis is usually based on symptoms in combination with medical imaging; however, the biopsy is the confirming method of diagnosis [6]. Initially, the clinical symptoms such as pelvic pain, heavy periods, pain with bowel movements, and infertility, in addition to the careful clinical exam, guide us towards the disease. However, this does not mean that effective methods such as ultrasound and CT scans are not used. As we mentioned above, the biopsy that shows under the microscope the presence of the endometrial stroma and glands is the cornerstone. There are many things that can be taken in the context of managing endometriosis. The most important one is whether the woman wants to have children or not. In the reproductive years, endometriosis is merely managed: the goal is to provide pain relief, to restrict progression of the process, and to restore or preserve fertility when needed. As for the complete treatment, it consists of the ablation or excision of the endometriosis, electrocoagulation lysis of adhesions, resection of endometriomas, and restoration of normal pelvic anatomy as much as possible. In our case, the patient complained of pain in the umbilical region with bleeding associated with the menstrual period. This complaint has been going on for three years. The patient has no past medical history. She had not undergone any previous surgery and was not a smoker or alcoholic. This unique case required many investigations, from careful clinical examination to imaging by ultrasound, and then all the diagnosis was confirmed by histopathology. In order to manage, we performed an open surgery in the navel area and removed the uterine tissue with a reconstruction of the area. In summary, in this case, we presented a typical presentation of a very rare manifestation of endometriosis in terms of symptoms and management, so it could be a comprehensive guide for dealing with such cases.

4. Conclusion

Umbilical cutaneous endometriosis is a rare pathologic entity representing 0.5%–1.0% of cases of extrapelvic endometriosis. Therefore, it

should be considered one of the differential diagnoses of a lesion in this region in a woman of childbearing age, especially if the symptoms are related to the menstrual period. The clinician must have a high index of suspicion with any patient who has cyclical symptoms involving the GI tract, urinary tract, lung, or other sites. The management options are dependent on the severity of symptoms, the location, the extent of the disease, and the patient's wishes for future childbearing.

Provenance and peer review

Not commissioned, externally peer-reviewed.

Sources of funding

This research did not receive any specific grant from funding agencies in the public, commercial, or not-for-profit sectors.

Ethical approval

This case report didn't require review by Ethics committee, Aleppo university hospital, Aleppo university, Aleppo-Syria.

Registration of research studies

Not applicable.

Guarantor

Sarya Swed.

Consent for publication

Written informed consent was obtained from the patient for publication of this case report and accompanying images. A copy of the

written consent is available for review by the Editor-in-Chief of this journal.

Author contribution

Hidar Alibrahim: contributed in study concept and design, data collection. MOUHAMMAD ALBATTOUT: contributed in writing the paper. Sarya Swed: contributed in writing the paper. Bisher Sawaf: contributed in writing the paper. Maher Ali Hussein Al-Janabi: contributed in reviewing the manuscript.

Declaration of competing interest

All authors declared no conflict of interest.

Appendix A. Supplementary data

Supplementary data to this article can be found online at <https://doi.org/10.1016/j.amsu.2021.103106>.

References

- [1] A. Czyzyk, A. Podfigurna, A. Szeliga, B. Meczekalski, Update on endometriosis pathogenesis, *Minerva Ginecol.* 69 (5) (2017) 447–461.
- [2] C. Bulletti, M.E. Coccia, S. Battistoni, A. Borini, Endometriosis and infertility, *J. Assist. Reprod. Genet.* 27 (8) (2010) 441–447.
- [3] T. Tanbo, P. Fedorcsak, Endometriosis-associated infertility: aspects of pathophysiological mechanisms and treatment options, *Acta Obstet. Gynecol. Scand.* 96 (6) (2017) 659–667.
- [4] P. Vercellini, P. Viganò, E. Somigliana, L. Fedele, Endometriosis: pathogenesis and treatment, *Nat. Rev. Endocrinol.* 10 (5) (2014) 261–275.
- [5] H. Bektaş, Y. Bilsel, Y.S. Sari, et al., Abdominal wall endometrioma; a 10-year experience and brief review of the literature, *J. Surg. Res.* 164 (1) (2010 Nov 1) e77–81.
- [6] L. Kiesel, M. Sourouni, Diagnosis of endometriosis in the 21st century, *Climacteric* 22 (3) (2019) 296–302.