

Review

Open Access

Surgical management of penetrating pulmonary injuries

Patrizio Petrone*¹ and Juan A Asensio²

Address: ¹Department of Surgery, University of Southern California Keck School of Medicine, Los Angeles, CA, USA and ²Department of Surgery, University of Miami Miller School of Miami, Miami, FL, USA

Email: Patrizio Petrone* - petrone@usc.edu; Juan A Asensio - jasensio@med.miami.edu

* Corresponding author

Published: 23 February 2009

Received: 8 January 2009

Scandinavian Journal of Trauma, Resuscitation and Emergency Medicine 2009, **17**:8 doi:10.1186/1757-7241-17-8

Accepted: 23 February 2009

This article is available from: <http://www.sjtem.com/content/17/1/8>

© 2009 Petrone and Asensio; licensee BioMed Central Ltd.

This is an Open Access article distributed under the terms of the Creative Commons Attribution License (<http://creativecommons.org/licenses/by/2.0>), which permits unrestricted use, distribution, and reproduction in any medium, provided the original work is properly cited.

Abstract

Chest injuries were reported as early as 3000 BC in the Edwin Smith Surgical Papyrus. Ancient Greek chronicles reveal that they had anatomic knowledge of the thoracic structures. Even in the ancient world, most of the therapeutic modalities for chest wounds and traumatic pulmonary injuries were developed during wartime.

The majority of lung injuries can be managed non-operatively, but pulmonary injuries that require operative surgical intervention can be quite challenging. Recent progress in treating severe pulmonary injuries has relied on finding shorter and simpler lung-sparing techniques. The applicability of stapled pulmonary tractotomy was confirmed as a safe and valuable procedure.

Advancement in technology have revolutionized thoracic surgery and ushered in the era of video-assisted thoracoscopic surgery (VATS), providing an alternative method for accurate and direct evaluation of the lung parenchyma, mediastinum, and diaphragmatic injuries.

The aim of this article is to describe the incidence of the penetrating pulmonary injuries, the ultimate techniques used in its operative management, as well as the diagnosis, complications, and morbidity and mortality.

Introduction

Chest injuries were reported as early as 3000 BC in the Edwin Smith Surgical Papyrus [1]. Ancient Greek chronicles reveal that they had anatomic knowledge of the thoracic structures and the position of the lungs inside the hemithoracic cavities, being proof of that the Homer's Iliad [2] with the vivid description of the death of Sarpedon.

Galen, one of the most prominent physicians of antiquity, described packing of chest wounds in gladiators with thoracic injuries [3].

Even in the ancient world, most of the therapeutic modalities for chest wounds and traumatic pulmonary injuries were developed during wartime, especially by Ambrose Paré [4], John Hunter [4], and Jean-Dominique Larrey [4].

The liberal use of thoracentesis in the management of hemothorax, the creation of the Mobile Army Surgical Hospital (MASH) units, and early evacuation from the combat zone directly to well-organized trauma centers operated under strict resuscitative protocols during World War II, and the Korean and Vietnam conflicts, have contributed to lower the mortality [5,6]. Tube thoracostomy remains the cornerstone for the treatment of traumatic injuries to the lung [7].

Recent awareness based on civilian and military experience has led to recognition that complex procedures in critically injured patients often develop hypothermia, acidosis, coagulopathy, and dysrhythmias [8-10]. Recent progress in treating severe pulmonary injuries has relied on finding shorter and simpler lung-sparing techniques [5,11]. The applicability of stapled pulmonary tractotomy was confirmed as a safe and valuable procedure [12,13], and the lung-sparing techniques are associated with an improved morbidity and mortality [14].

Advancement in technology have revolutionized thoracic surgery and ushered in the era of video-assisted thoracoscopic surgery (VATS), providing an alternative method for accurate and direct evaluation of the lung parenchyma, mediastinum, and diaphragmatic injuries, with the advantage of allowing definitive treatment of such injuries [15]. VATS also has been demonstrated to be a reliable operative therapy for complications, including post-traumatic pleural collections [16].

Incidence

The true incidence of pulmonary injuries is unknown and difficult to estimate from the literature [17-19]. The reported incidence of pulmonary injuries in the civilian arena varies according to authors and institutions. Graham et al [20] reported 1-year experience, consisting of 373 patients sustaining penetrating pulmonary injuries. Robison et al [21] described a 13-year civilian experience in the management of pulmonary injuries in 1168 patients. Tominaga and colleagues [22] described a 7-year single institutional experience of 2934 patients sustaining both blunt and penetrating chest trauma. Recently, our

group [23] described 101 patients who sustained complex penetrating pulmonary injuries. In the military arena, Zakharia et al [24] reported 1992 casualties during the Lebanon's conflict, with an incidence of 11%. Petricevic and associates [25] reported on 2547 casualties from the Balkan war experience, 16% of those sustained both blunt and penetrating chest wounds.

Etiology

The majority of thoracic injuries requiring surgical intervention are due to penetrating mechanisms of injury such as gunshot wounds (GSW), stab wounds (SW) and shotgun wounds (SGW). Much less common are blunt thoracic injuries requiring operative intervention, but this mechanism of injury is in gradual rise from 3% before 1994 to 12% in the latter period, mostly from motor vehicle collisions [26]. Tominaga et al [22] accounted in their series 25% as blunt mechanism.

Gunshot wounds represent the major penetrating mechanism of injury for patients requiring surgical treatment, ranging from 33% to 80% of the cases [13,14,20-22], while stab wounds account for 17% to 67% of these injuries [13,14]. Other mechanisms such as impalement and shotgun wounds are reported with a lower frequency of 1% to 5% of cases [13,14].

Classification

In 1994 the American Association for the Surgery of Trauma – Organ Injury Scaling Committee (AAST-OIS) describes the lung injury scale (Table 1) [27]. This scale facilitates clinical research and provides a common

Table 1: American Association for the Surgery of Trauma – Organ Injury Scaling: Lung Injury [27]

Grade ^a	Injury Type	Description ^b
I	Contusion	Unilateral, < 1 lobe
II	Contusion Laceration	Unilateral, single lobe Simple pneumothorax
III	Contusion Laceration Hematoma	Unilateral, > 1 lobe Persistent (> 72 hours), air leak from distal airway Non-expanding intraparenchymal
IV	Laceration Hematoma Vascular	Major (segmental or lobar) air leak Expanding intraparenchymal Primary branch intrapulmonary vessel disruption
V	Vascular	Hilar vessel disruption
VI	Vascular	Total, uncontained transection of pulmonary hilum

^a Advance one grade for multiple injuries up to grade III. Hemothorax is scored under thoracic vascular organ injury scale.

^b Based on most accurate assessment at autopsy, operation, or radiological study.

nomenclature by which trauma surgeons may describe lung injuries and their severity.

Diagnosis

Physical examination

The clinical presentation of patients sustaining penetrating pulmonary injuries ranges from hemodynamic stability to cardiopulmonary arrest [28]. Patients with penetrating pulmonary injuries may present with symptoms and signs of pneumohemothorax or an open pneumothorax with a partial loss of the chest wall, or may also present with a tension pneumothorax [28,29].

Patients with penetrating pulmonary injuries may rarely present with a pneumomediastinum upon auscultation. Hamman's Crunch – a systolic crunch – may be detected upon auscultation in these patients. Similarly, as they may also present with a pneumopericardium detected by auscultating Brichiteau's windmill bruit (bruit de moulin). Patients with penetrating pulmonary injuries may rarely present with true hemoptysis, and sometimes with symptoms and signs of associated cardiac injuries [17,18,28].

During the evaluation of these patients, the trauma surgeon must be cognizant that the thoracic cavity is composed of both right and left hemithoracic cavity as well as an anterior, posterior and superior mediastinum, as often missiles or other wounding agents may traverse one or both cavities [28,30-33]. Similarly, missile trajectories are often unpredictable and frequently create secondary missiles if they impact on hard bony structures such as the ribs, spine and sternum thus creating the potential for associated injuries and greater damage.

Non-invasive diagnostic modalities

Trauma ultrasound

The Focused Assessment Sonogram for Trauma (FAST) is performed as part of the secondary survey. It diagnoses and excludes an associated cardiac injury and can also diagnose the presence of a hemothorax. On the basis of these findings, Knudson et al [34] concluded that ultrasound is a reliable modality for the diagnosis of pneumothorax, and it may serve as an adjunct or precursor to routine chest radiograph in the evaluation of injured patients.

Chest X-Ray (CXR)

A standard supine posteroanterior CXR is the most frequently used diagnostic modality in patients who sustain traumatic lung injury. Radiological diagnosis of traumatic pulmonary injuries is based on the presence of pneumothorax, pleural fluid collections, intrapulmonary hematomas, traumatic pneumatoceles, and pulmonary parenchymal contusions [7,17,18,20,28,29,35].

Computed Tomography (CT)

The most common types of abnormalities seen on CT scans include parenchymal lacerations, post-traumatic hemothorax and pneumothorax, atelectasis, subcutaneous emphysema, pneumopericardium and hemopericardium, and chest wall fractures. CT scans are also able to detect the presence of associated thoracic and mediastinal vascular injuries, as well as associated cervical spine and intra-abdominal injuries in about 30% of cases [36].

Electrocardiogram (EKG)

In some cases, EKG may exhibit changes caused by associated injuries, most commonly penetrating or blunt cardiac trauma consisting of findings related to myocardial injury [37,38]. However, nonspecific EKG abnormalities are more often seen, and are related to systemic factors such as pain, decreased intravascular volume, hypoxia, abnormal concentration of serum electrolytes, and changes in sympathetic or parasympathetic tone [37,38].

Invasive diagnostic modalities

Thoracostomy

Chest tube placement may be diagnostic as well as therapeutic [7]. It will serve to evacuate air, evacuate and quantify blood, detect massive air leaks, and establish an indication for thoracotomy [32,33]. Drainage of gastrointestinal contents implies an esophageal [31], gastric, or intestinal injury [30].

Video-Assisted Thoracoscopic Surgery (VATS)

VATS has provided the trauma surgeon with an alternative method for the accurate and direct evaluation of the lung parenchyma, mediastinum, and diaphragmatic injuries [39,40], with the advantage of simultaneously allowing definitive treatment of such injuries [15]. VATS also has been demonstrated to be an accurate, safe and reliable operative therapy for complications of lung trauma, including post-traumatic pleural collections [16].

Operative Management

Instruments

Special instruments are needed to access the thoracic cavity as well as to retract, manipulate, and surgically intervene in the thoracic structures and lungs (Figure 1 and Figure 2).

Adjuncts

Double lumen tubes are invaluable adjuncts in the management of penetrating pulmonary injuries (Figure 3). Although more difficult to insert by the anesthesiologist, double lumen tubes are designed to ventilate either the right or left lung selectively [41]. There are two types of double lumen tubes, one designed for the left and one designed for the right mainstem bronchus. By inflating the balloon which occludes either the right or the left

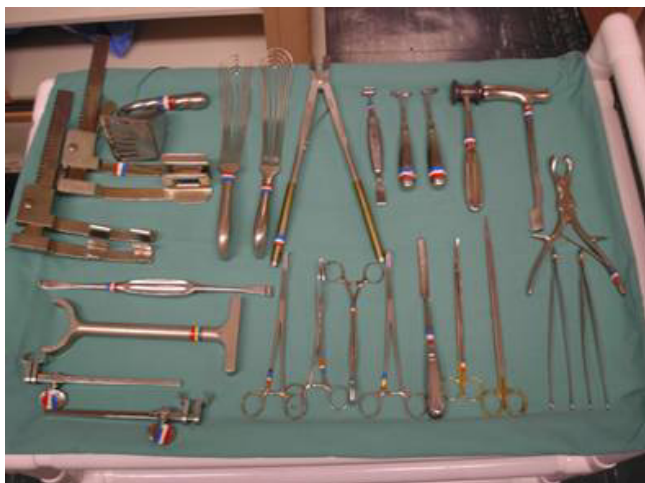

Figure 1
Thoracic instrument tray.

mainstem bronchus, the lung can be collapsed, thus allowing the trauma surgeon to operate on a collapsed and still lung [41]. Bronchoscopy is also an invaluable adjunct when utilized intraoperatively. It can serve as a diagnostic tool by locating injured bronchi at the lobar and even segmental levels. It can also be therapeutic by removing blood within the tracheobronchial tree which tends to cause bronchospasm.

Ventilation

The conventional ventilation method intermittently allows for a periodic inflation and deflation of the lung or high frequency jet ventilation which allows the trauma surgeon to operate on a non-moving still lung [41].




Figure 2
Duval lung forceps.

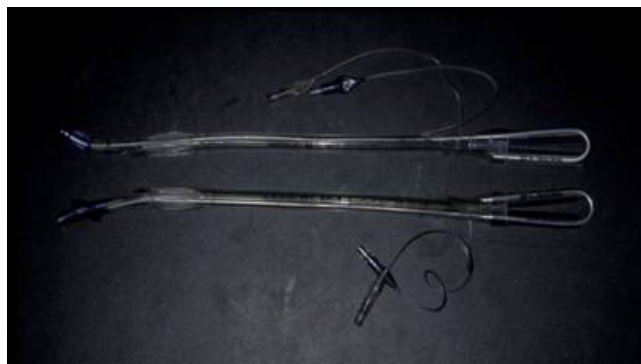

Figure 3
Double lumen endotracheal tubes.

Surgical incisions and exposures

The three most commonly used incisions in the management of penetrating cardi thoracic injuries are: the left anterolateral thoracotomy, the posterolateral thoracotomy, and median sternotomy. Each incision has its specific indications, advantages and disadvantages.

The left anterolateral thoracotomy (Spangaro's incision) is the incision of choice for the management of patients with penetrating pulmonary or cardiac injuries who arrive "in extremis". This incision is most often used in the ED for resuscitative purposes. Similarly, it is the incision of choice in patients undergoing celiotomy who deteriorate secondary to possible or unsuspected pulmonary or cardiac injuries. It can be extended across the sternum as bilateral anterolateral thoracotomies if the patient's injuries extend into the right hemithoracic cavity. This is the incision of choice in a patient who is hemodynamically unstable owing to injuries that have traversed the mediastinum or one who has sustained associated abdominal injuries. It allows full exposure of the anterior mediastinum and pericardium and both hemithoracic cavities [42-44].

The classic posterolateral thoracotomy incision is the most useful of all incisions for the management of all pulmonary injuries [42-44]. This incision is ideal for the management of thoracic injuries, such as aortic or pulmonary (left posterolateral) or pulmonary or esophageal (right posterolateral) injuries. However, it is time consuming to position the patient and can only be used if the patient is hemodynamically stable and the trauma surgeon is absolutely sure that the injury is confined to an ipsilateral hemithoracic cavity.

The median sternotomy (Duval's incision) is the incision of choice for the management of patients with associated cardiac injuries that arrive with vital signs in the operating room [42-44]. The right or left hemithoracic cavities can

be accessed if the mediastinal pleura is sharply transected. This provides access to the anterior portions of either the right or left lung although exposure of the posterior aspects of the pulmonary lobes is suboptimal.

Surgical techniques of repair and resection

The high mortality rates reported for lobectomy and pneumonectomy when performed after traumatic lung injuries, has served to develop less extensive resection techniques [5,11-14,19,21,22,26]. These techniques have been denominated 'lung-sparing techniques', and include suture pneumorrhaphy, stapled and clamp pulmonary tractotomy with selective vessel ligation, and non-anatomic resection.

These procedures are indicated for control of hemorrhage, control of small air leaks, to preserve pulmonary tissue, and/or when the pulmonary injury is amenable to reconstruction. It is estimated that approximately 85% of all penetrating pulmonary injuries can be managed with these techniques [5,12-14].

Suture pneumorrhaphy

The lung is stabilized with Duval lung forceps. Stay absorbable sutures are placed in the superior and inferior aspect of the wound as well as in the lateral aspects, and they are used to gently retract the edges. Very fine malleable ribbon retractors are placed to separate the wound and to provide visualization of the injured vessels which are then selectively ligated. The same is done for small bronchi. The edges of the wound are then approximated with a running locked suture [45,46].

Stapled pulmonary tractotomy

Orifices of entrance and exit are defined. If need be, the overlying visceral pleura is sharply incised with Nelson scissors. A GIA 55 or 75 stapler with 3.8 mm staples is placed through the orifices of entrance and exit and fired (Figure 4 and Figure 5). This will open the tract traversed by the missile or other wounding agent effectively exposing the injured vessels and bronchi which are then selectively ligated utilizing absorbable suture (Figure 6). The lung parenchyma can then be approximated with a single running locked suture. The orifices of entry and exit are left open for the egress of air and/or blood. The integrity of the suture line is tested by having the anesthesiologist inflate the lung, and the air leaks are then detected and repaired [11,46].

Clamp pulmonary tractotomy

The same technique as stapled pulmonary tractotomy, but instead of stapler two Crafoord-DeBakey clamps are placed through the orifices of entrance and exit and the pulmonary tissue between the clamps is sharply

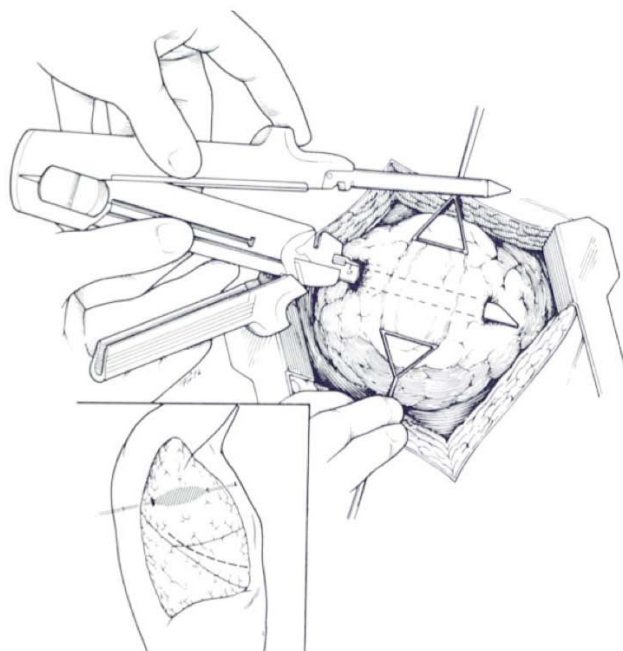


Figure 4
 Depicts the cavitory effect created by a missile traversing the lung. Stapling device is placed through the orifices of entry and exit wounds.

transected with scissors. The use of clamps may crush pulmonary tissue.

Non-anatomic resection

This procedure is indicated when a very small and peripheral portion of a lobe or segment is devitalized. The area of resection is stabilized between Duval lung forceps and a stapler is fired across, thus resecting the injured portion of the lung. The staple line may be over sewn with a run-

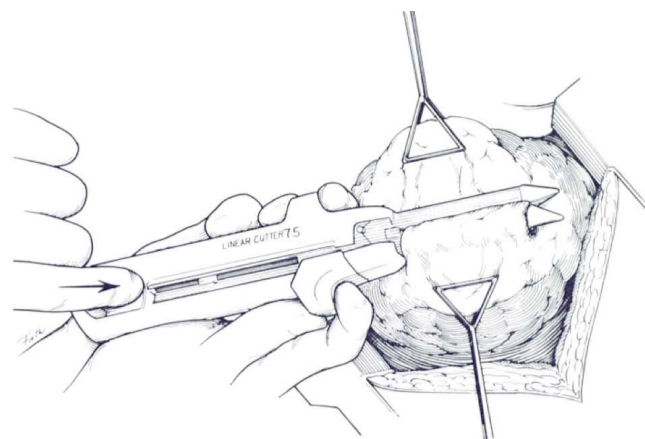


Figure 5
 Stapling device is closed and fired to create the tractotomy.

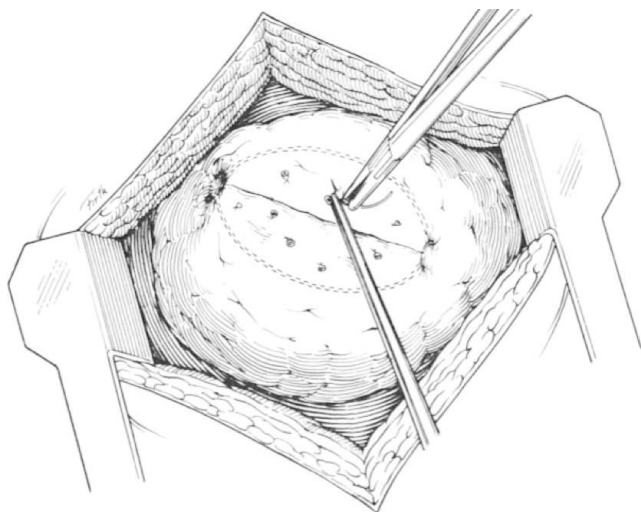


Figure 6
The tract is open and the deep bleeding vessels are selectively ligated.

ning locked suture, although this is not generally necessary. Non-anatomic resection can also be complex and require resection of major segments with complex reconstruction.

Resectional procedures

Resectional procedures include formal lobectomy and formal pneumonectomy. These procedures are indicated for control of hemorrhage, resection of devitalized or destroyed pulmonary tissue, control of major air leaks not amenable to repair, and control of life-threatening hemorrhage [45,46].

Formal lobectomy

To perform a lobectomy the fissure must be separated. In the case of the right lung the oblique fissure separates the upper and middle lobe from the lower lobe while the horizontal fissure separates the upper lobe from the middle lobe. In the left lung the oblique fissure divides the left upper from the left lower lobe. The lingula of the left upper lobe corresponds to the middle lobe on the right, but it is fused with the upper lobe in most cases [45,46].

Vascular dissection should be initiated extrapleurally at the hilum through a perivascular plane to find the major pulmonary vessels. Vascular dissection in the fissures identifies the lobar vessels. Transection of the inferior pulmonary ligament distally will allow greater mobility of the lower lobes of both lungs. All pulmonary vessels whether they be the main lobar vessels or segmental vessels can be ligated in continuity and transfixed with non-

absorbable sutures. Alternatively, they may be stapled or may also be over sewn [45,46].

The bronchi, whether they are the main, lobar or segmental bronchi should be stapled and transected. Bronchi may also be transected utilizing Sarot lung clamps and sutured with 4-0 Tev-Dek synthetic sutures. The suture technique involves clamping the bronchus distal to the intended point of transection. The bronchus is cut transversely for 4-5 mm, and the cut end is sutured, and should be tied very carefully to avoid cutting or unnecessarily devascularization. After placement of two sutures, the cut end is extended and additional sutures are placed 2-3 mm apart. While for a main bronchus, seldom are more than six sutures required, for a lobar bronchus three to four sutures are usually enough. Too many sutures devascularized the transected bronchus. After closure is complete, the suture line is tested, and additional sutures are placed if there is an air leak detected. To prevent lung torsion the remaining lobes are pexed to the thoracic wall [45,46].

Pneumonectomy

A) Right Pneumonectomy

A thorough exploration of the right hemithoracic cavity is carried out. The azygous vein is identified, and the right pulmonary hilum is located. Utilizing a meticulous combination of sharp and blunt dissection the right main pulmonary artery is identified and encircled with a vessel loop. The right inferior pulmonary ligament is sharply transected. Both superior and inferior pulmonary veins are identified and encircled with a vessel loops. All vessels may be either ligated in continuity or stapled individually. The right mainstem bronchus is then identified and encircled. The trauma surgeon must be careful not to apply undue traction to avoid tearing subcarinal structures. The bronchus is then transected [45,46].

B) Left Pneumonectomy

The same steps as the right pneumonectomy are taken, paying special attention with the phrenic, vagus and left recurrent laryngeal nerves which are identified and preserved, and the left pulmonary hilum is located [45,46].

Morbidity

The most common intraoperative complication is heart failure, while the physiological post-operative complications include right ventricular failure, pulmonary artery hypertension, and "run-away" pulmonary artery hypertension.

The most common technical complications include lung hernia, lung torsion, bronchopleural fistulas, arteriovenous fistulas, bronchial stump leaks, bronchial stump blow-outs, bronchial stenosis, empyema, and lung

abscess. These complications will often require surgical reintervention. Fortunately, they are infrequent.

Mortality

The estimated mortality for these procedures is very variable. The overall mortality rate reported in the literature for patients with traumatic pulmonary injuries ranges from 1.7% to 37%. For stapled procedures the mortality is 10%, for non-anatomic resections is 20%, for lobectomies it can range from 30% to 50%, and for pneumonectomies the mortality rate is between 50% to 100% [5,12,14,22,26].

Conclusion

Pulmonary injuries requiring thoracotomy are uncommon even in busy urban trauma centers. Simpler surgical techniques are frequently used for their management. Stapled pulmonary tractotomy has become the most frequently used lung sparing technique, and can manage 85% of all pulmonary injuries requiring surgical interventions. Despite recent advances, pulmonary injuries requiring resective procedures are marked by high morbidity and mortality.

Competing interests

The authors declare that they have no competing interests.

Authors' contributions

PP drafted the manuscript. PP and JAA critically revised the manuscript. PP and JAA have read and approved the final manuscript.

References

- Breasted JH, (Ed): **The Edwin Smith Surgical Papyrus. Volume 1.** University of Chicago Press, Chicago, IL; 1930:369-373.
- Homer : **The Iliad. Translated by Alexander Pope.** George Bell & Sons, London 1904, **XVI**:299-lines 588-625.
- Menenakos E, Alexakis N, Leandros E, et al.: **Fatal chest injury with lung evisceration during athletic games in ancient Greece.** *World J Surg* 2005, **29**:1348-51.
- Bellamy RF, Zajtczuk R: **The evolution of wound ballistics: a brief history.** In *Textbook of Military Medicine, Office of the General Surgeon* Edited by: Bellamy RF, Zajtczuk R. Department of the Army. Washington, DC; 1989:83-106.
- Wall MJ Jr, Hirshberg A, Mattox KL: **Pulmonary tractotomy with selective vascular ligation for penetrating injuries to the lung.** *Am J Surg* 1994, **168**:665-9.
- Fallon WF: **Surgical lessons learned on the battlefield.** *J Trauma* 1997, **43**:209-13.
- Mattox KL, Allen MK: **Systematic approach to pneumothorax, hemothorax, pneumomediastinum and subcutaneous emphysema.** *Injury* 1986, **17**:309-12.
- Asensio JA, Petrone P, Roldan G, et al.: **Has evolution in awareness of guidelines for institution of damage control improve outcome in the management of the post-traumatic open abdomen?** *Arch Surg* 2004, **139**:209-14.
- Asensio JA, Petrone P, O'Shanahan G, Kuncir E: **Managing exsanguination: what we know about damage control/bailout is not enough.** *Baylor U Med Ctr Proc* 2003, **16**:294-6.
- Asensio JA, McDuffie L, Petrone P, et al.: **Reliable variables in the exsanguinated patient which indicate damage control and predict outcome.** *Am J Surg* 2001, **182**:743-51.
- Asensio JA, Demetriades D, Berne JD, et al.: **Stapled pulmonary tractotomy: a rapid way to control hemorrhage in penetrating pulmonary injuries.** *J Am Coll Surg* 1997, **185**:486-7.
- Velmahos GC, Baker C, Demetriades D, et al.: **Lung-sparing surgery after penetrating trauma using tractotomy, partial lobectomy, and pneumonorrhaphy.** *Arch Surg* 1999, **134**:186-9.
- Karmy-Jones R, Jurkovich GJ, Shatz DV, et al.: **Management of traumatic lung injury: a Western Trauma Association multicenter review.** *J Trauma* 2001, **51**:1049-53.
- Cothren C, Moore EE, Biffl WL: **Lung-sparing techniques are associated with improved outcome compared with anatomic resection for severe lung injuries.** *J Trauma* 2002, **53**:483-7.
- Manlulu AV, Lee TW, Thung KH, et al.: **Current indications and results of VATS in the evaluation and management of hemodynamically stable thoracic injuries.** *Eur J Cardiothorac Surg* 2004, **25**:1048-53.
- Navsaria PH, Vogel RJ, Nicol AJ: **Thoracoscopic evacuation of retained post-traumatic hemothorax.** *Ann Thorac Surg* 2004, **78**:282-6.
- Pezzella AT, Silva WE, Lancey RA: **Cardiothoracic trauma.** *Curr Prob Surg* 1998, **35**:647-790.
- Pezzella AT, Adebajo SA, Hooker SG, et al.: **Complications in general thoracic surgery.** *Curr Prob Surg* 2000, **37**:733-860.
- Powell RJ, Redan JA, Swan KG: **The hilar snare, an improved technique for securing rapid vascular control of the pulmonary hilum.** *J Trauma* 1990, **30**:208-10.
- Graham JM, Mattox KL, Beall AC: **Penetrating trauma of the lung.** *J Trauma* 1979, **19**:665-9.
- Robison PD, Harman PK, Tringle JK, Grover FL: **Management of penetrating lung injuries in civilian practice.** *J Thorac Cardiovasc Surg* 1998, **95**:184-90.
- Tominaga GT, Waxman K, Scanell G, et al.: **Emerging thoracotomy with lung resection following trauma.** *Am Surg* 1993, **59**:834-7.
- Asensio JA, Garcia-Nuñez LM, Petrone P: **Penetrating pulmonary injuries.** In *Trauma. Contemporary Principles and Therapy* Edited by: Flint L, Meredith JW, Schwab CW, Trunkey DD, Rue LW, Taheri PA. Lippincott Williams & Wilkins, Philadelphia, PA; 2008:361-71.
- Zakharia AT: **Thoracic battle injuries in the Lebanon War: a review of the early operative approach in 1,992 patients.** *Ann Thorac Surg* 1985, **40**:209-13.
- Petricevic A, Ilic N, Bacic A, et al.: **War injuries of the lungs.** *Eur J Cardiothorac Surg* 1997, **11**:843-7.
- Huh J, Wall MJ, Estrera AL, et al.: **Surgical management of traumatic pulmonary injury.** *Am J Surg* 2003, **186**:620-4.
- Moore EE, Malangoni MA, Cogbill TH, et al.: **Organ injury scaling, IV: thoracic vascular, lung, cardiac, and diaphragm.** *J Trauma* 1994, **36**:299-300.
- Symbas PN: **Cardiothoracic trauma.** *Curr Prob Surg* 1991, **28**:741-96.
- Ayed AK, Shawaf EA: **Diagnosis and treatment of traumatic intrathoracic bronchial dysruption.** *Injury* 2004, **35**:484-99.
- Asensio JA, Arroyo H Jr, Veloz W, et al.: **Penetrating thoracoabdominal injuries: ongoing dilemma -which cavity and when?** *World J Surg* 2002, **26**:539-43.
- Asensio JA, Berne J, Demetriades D, et al.: **Penetrating esophageal injuries: time interval of safety for preoperative evaluation - how long is safe?** *J Trauma* 1997, **43**:319-24.
- Cornwell EE 3rd, Kennedy F, Ayad IA, et al.: **Transmediastinal gunshot wounds. A reconsideration of the role of aortography.** *Arch Surg* 1996, **131**:949-52.
- Hanpeter DE, Demetriades D, Asensio JA, et al.: **Helical computed tomography scan in the evaluation of mediastinal gunshot wounds.** *J Trauma* 2000, **49**:689-95.
- Knudson JL, Dort JM, Helmer SD, Smith S: **Surgeon-performed ultrasound for pneumothorax in the trauma suite.** *J Trauma* 2004, **56**:527-30.
- Mann FA, Linnau KF: **Diagnostic and interventional radiology.** In *Trauma* 5th edition. Edited by: Moore EE, Feliciano DV, Mattox KL. McGraw-Hill, New York; 2004:255-310.
- Karaaslan T, Meuli R, Androux R, et al.: **Traumatic chest lesions in patients with severe head trauma: a comparative study with computed tomography and conventional chest roentgenograms.** *J Trauma* 1995, **39**:1081-6.
- Eisenberg MJ, Muñoz de Romeral L, Heidenreich PA, et al.: **The diagnosis of pericardial effusion and cardiac tamponade by 12-lead ECG.** *Chest* 1996, **110**:318-24.

38. Bruch C, Schmermund A, Bagres N, et al.: **Changes in QRS voltaje in cardiac tamponade and pericardial effusion: reversibility after pericardiocentesis and alter anti-inflammatory drug treatment.** *J Am Coll Cardiol* 2001, **38**:219-26.
39. Asensio JA, Petrone P, Demetriades D: **Injury to the diaphragm.** In *Trauma* 5th edition. Edited by: Moore EE, Feliciano DV, Mattox KL. McGraw-Hill, New York; 2004:613-36.
40. Petrone P, Leppäniemi A, Inaba K, et al.: **Diaphragmatic injuries: challenges in the diagnosis and management.** *Trauma* 2007, **9**:227-36.
41. Duke JC: **Anesthesia.** In *Trauma* 5th edition. Edited by: Moore EE, Feliciano DV, Mattox KL. McGraw-Hill, New York; 2004:329-54.
42. Asensio JA, Stewart BM, Murray J, et al.: **Penetrating cardiac injuries.** *Surg Clin North Am* 1996, **76**:685-724.
43. Asensio JA, Murray J, Demetriades D, et al.: **Penetrating cardiac injuries: a prospective study of variables predicting outcomes.** *J Am Coll Surg* 1998, **186**:24-34.
44. Asensio JA, Berne J, Demetriades D, et al.: **One hundred five penetrating cardiac injuries. A two year prospective evaluation.** *J Trauma* 1998, **44**:1073-82.
45. Blaisdell FW: **Pulmonary injury: laceration, contusion, hematoma, pneumatocele, and traumatic asphyxia blast injury.** In *Trauma Management III: Cervicothoracic Trauma* Edited by: Blaisdell FW, Trunkey DD. Thieme Medical Publishers, New York; 1994:234-61.
46. Asensio JA, Garcia-Nuñez LM, Petrone P, et al.: **Operative management of pulmonary injuries: Lung-sparing and formal resections.** In *Current Therapy of Trauma and Surgical Critical Care* 5th edition. Edited by: Asensio JA, Trunkey DD. Mosby, Philadelphia; 2008:282-97.

Publish with **BioMed Central** and every scientist can read your work free of charge

"BioMed Central will be the most significant development for disseminating the results of biomedical research in our lifetime."

Sir Paul Nurse, Cancer Research UK

Your research papers will be:

- available free of charge to the entire biomedical community
- peer reviewed and published immediately upon acceptance
- cited in PubMed and archived on PubMed Central
- yours — you keep the copyright

Submit your manuscript here:
http://www.biomedcentral.com/info/publishing_adv.asp

