

# Vasculitis and long standing ankylosing spondylitis in a patient with familial Mediterranean fever

Ali Taylan<sup>1</sup>, Yasar Yildiz<sup>2</sup>, Ismail Sari<sup>2</sup>, Guliz Ozkok<sup>3</sup>

<sup>1</sup>Department of Rheumatology, Izmir Tepecik Training and Research Hospital, Izmir, <sup>2</sup>Departments of Internal Medicine, <sup>3</sup>Pathology, Izmir Bozyaka Training and Research Hospital, Izmir, Turkey

Coexistence of familial Mediterranean fever (FMF) and other inflammatory disorders has been frequently reported, but no specific underlying factor has been identified. We report a patient with FMF who is presented with long-standing ankylosing spondylitis (AS) and cutaneous leukocytoclastic vasculitis (LV) of the lower limbs. It is the first report on combination of FMF with AS and LV. The Mediterranean Fever (MEFV) gene mutation of heterozygote (R202Q/R726A) and HLA-B27 are detected in this case, and are believed to form genetic susceptibility to LV.

**Key words:** Ankylosing spondylitis, familial Mediterranean fever, leukocytoclastic vasculitis, vasculitis

**How to cite this article:** Taylan A, Yildiz Y, Sari I, Ozkok G. Vasculitis and long standing ankylosing spondylitis in a patient with familial Mediterranean fever. *B J Res Med Sci* 2014;19:1009-11.

## INTRODUCTION

Familial Mediterranean Fever (FMF) is an autoinflammatory autosomal recessive disease which is spread from the Mediterranean basin to some parts of the South and Far East Asia.<sup>[1-4]</sup> An association of FMF with systemic vasculitides, particularly Henoch-Schönlein purpura (HSP), polyarteritis nodosa (PAN), and Behçet disease has been reported worldwide. Coexistence of leukocytoclastic vasculitis (LV) along with ankylosing spondylitis (AS) is sporadic, while most comorbidities are linked to IgA nephropathy or HSP.<sup>[5]</sup> We report a FMF patient with long-standing undiagnosed AS presented with LV on the lower limbs.

## CASE REPORT

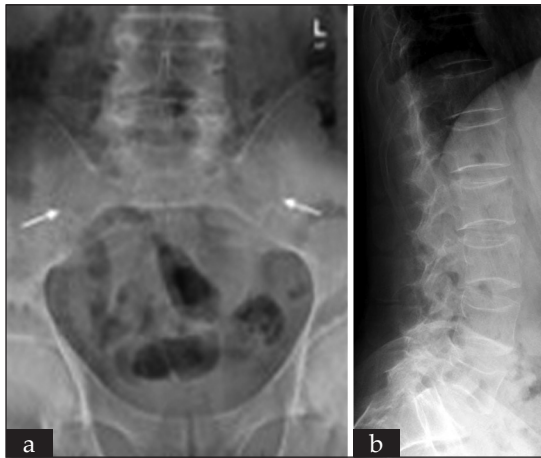A 35-year-old Caucasian male diagnosed with FMF in childhood was admitted to the hospital in 2010 with widespread cutaneous eruptions on the lower limbs, which gradually intensified within the 5 days prior to the admission. The patient also had swelling and pain over his right wrist and left knee. He was on regular colchicine treatment with 1.5 mg/day for the last 17 years. No recent exposure to other drugs was recorded. There were no symptoms of infectious diseases such as fever, abdominal pain, and diarrhea prior to the cutaneous disease. The main complaints for the past 10 years were low back pain and morning stiffness.

On physical examination there were macular, brown cutaneous eruptions with confluence on both legs. In addition to right wrist and left knee arthritis, the patient had restricted painful spinal movements in all directions, suggestive of AS with modified Schober test of 3 cm.<sup>[6]</sup> The rest of the physical examination was unremarkable.

On laboratory examination, level of hemoglobin was 9.3 g/dL (normal (N) -12-14 g/dL), consistent with anemia of chronic disease. Erythrocyte sedimentation rate (ESR) and C-reactive protein (CRP) were 59 mm/h (N -0-20 mm/h) and 7.27 mg/dL (N -0-0.8 mg/dL), respectively. Sacroiliac joints radiography was compatible with bilateral grade IV sacroiliitis [Figure 1a]. A skin biopsy from the frontal aspect of tibia showed fibrin deposits, nuclear debris, endothelial swelling and neutrophils infiltrating capillary wall, suggestive of small-vessel vasculitis [Figure 2]. Immune fluorescence staining did not detect immune deposits. Serum IgA level was elevated at 617 mg/dL (N -82-453 mg/dL). HLA-B27 antigen was positive. Antinuclear antibodies (ANA), antineutrophil cytoplasmic antibody (ANCA), and cryoglobulins were undetectable. Levels of complement fractions and urine examination were within normal limits. Biochemical profile, hepatitis B and C serology, chest X-ray, and abdominal ultrasonography were also unremarkable. Mutational genetic analysis of the MEFV gene was consistent with compound heterozygote state (R202Q/R726A).

**Address for correspondence:** Dr. Ali Taylan, Izmir Tepecik Teaching and Research Hospital, Rheumatology Section Yenisehir, Izmir, Turkey.  
E-mail: taylanally@yahoo.com

**Received:** 25-06-2013; **Revised:** 01-08-2013; **Accepted:** 22-08-2013



**Figure 1:** (a) Stage IV sacroiliitis. (b) Apophyseal joints involvement without vertebral squaring and bamboo spine

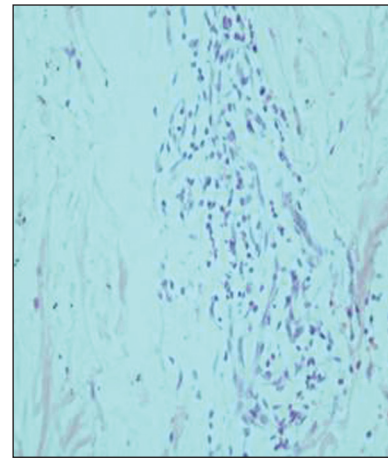
Treatment with oral prednisolone (15 mg/day), sulfasalazine (2 g/day), acemetacin (120 mg/day), and colchicine (1.5 mg/day) was commenced. After 10 days of the treatment the skin eruptions completely disappeared, arthritis and low back pain substantially subsided.

Subsequently, dose of prednisolone was tapered and then stopped. Other drugs were continued at lower doses.

## DISCUSSION

FMF is a common autoinflammatory disease which is presented with self-limited attacks of fever, peritonitis, pleuritis, and arthritis.<sup>[1]</sup> Most patients with FMF carry the MEFV gene mutations, which are implicated in the overexpression of interleukin (IL)-1.<sup>[2]</sup> Prolonged and intensive systemic inflammation is believed to lead to Henoch-Schönlein Purpura (HSP), polyarteritis nodosa (PAN), and other vasculitides in FMF patients.<sup>[5]</sup> Coexistence of FMF and AS is also frequently reported.<sup>[7]</sup> Sacroiliitis with apophyseal joint involvement without vertebral squaring and bamboo-like spine characterize FMF-related seronegative spondyloarthropathy (SNSA), while anterior radiologic involvement of the spine tend to show concomitant presence of AS with FMF.<sup>[8]</sup> Positivity for HLA-27 antigen contributes to the severity of SNSA in FMF.<sup>[9]</sup> Apophyseal joints affection without anterior vertebral column involvement in the current case supports the primacy of FMF-related pathogenic mechanisms opposed to that of AS [Figure 1b].

Combination of LV with AS and FMF in the current case is quite unusual. A few previous cases linked AS with IgA nephropathy or HSP.<sup>[10]</sup> Skin biopsy with fluorescent staining show no immune deposits and urinalyses negative for hematuria and proteinuria along with the absence of GI symptoms rule out both IgA nephropathy and HSP in the current case.



**Figure 2:** Microscopy of skin lesions suggestive of leukocytoclastic vasculitis: Fibrin deposits, nuclear debris, and neutrophils infiltrating capillary wall (hematoxylin and eosin (H and E), 200)

Some drugs may induce drug-related LV.<sup>[11]</sup> In the current case; however, there was no history of relevant drug exposure. Nonpuritic persistent rash without eosinophilia in blood and pathology specimens also rule out drug-related LV.

There is a single report on combination of AS with LV without systemic manifestations.<sup>[12]</sup> Pathogenesis of LV in AS has been linked to mucosal inflammation and increased IgA in blood, which is common in active AS, and resultant immune deposits in cutaneous vessels and kidneys.<sup>[13]</sup> The absence of IgA nephropathy, HSP, and immune deposits on skin biopsy make FMF the most probable trigger of LV in the current case.

The current patient was found to be compound heterozygote for the MEFV gene mutations (R202Q/R726A) and positive for HLA-B27, which could predispose to the development of cutaneous vasculitis and severe SNSA, respectively. There is a single report on cutaneous vasculitis with immune complex nephritis in FMF.<sup>[14]</sup> Our case is the first to report on cutaneous LV without immune deposits, most likely linked to severe long-standing SNSA and the MEFV mutations.

## AUTHORS' CONTRIBUTIONS

All authors have contributed in designing and conducting the study. All authors have assisted in preparation of the first draft of the manuscript or revising it critically for important intellectual content. All authors have read and approved the content of the manuscript and confirmed the accuracy or integrity of any part of the work.

## REFERENCES

1. Onen F. Familial Mediterranean fever. *Rheumatol Int* 2006;26:489-96.
2. Wilson SP, Cassel SL. Inflammasome-mediated autoinflammatory disorders. *Postgrad Med* 2010;122:125-33.

3. Esmaeili M, Bonyadi M, Rafeey M, Sakha K, Somi MH. Common MEFV mutation analysis in Iranian Azeri Turkish patients with familial Mediterranean fever. *Semin Arthritis Rheum* 2008;37:334-8.
4. Lim AL, Jang HJ, Han JW, Song YK, Song WJ, Woo HJ, *et al.* Familial Mediterranean fever: The first adult case in Korea. *J Korean Med Sci* 2012;27:1424-7.
5. Ozçakar ZB, Yalçınkaya F. Vascular comorbidities in familial Mediterranean fever. *Rheumatol Int* 2011;31:1275-81.
6. Rezvani A, Ergin O, Karacan I, Oncu M. Validity and reliability of the metric measurements in the assessment of lumbar spine motion in patients with ankylosing spondylitis. *Spine (Phila Pa 1976)* 2012;37:E1189-96.
7. Akar S, Soysal O, Balci A, Solmaz D, Gerdan V, Onen F, *et al.* High prevalence of spondyloarthritis and ankylosing spondylitis among familial Mediterranean fever patients and their first-degree relatives: Further evidence for the connection. *Arthritis Res Ther* 2013;15:R21.
8. Kaşifoğlu T, Çalışır C, Cansu DU, Korkmaz C. The frequency of sacroiliitis in familial Mediterranean fever and the role of HLA-B27 and MEFV mutations in the development of sacroiliitis. *Clin Rheumatol* 2009;28:41-6.
9. Langevitz P, Livneh A, Zemer D, Shemer J, Pras M. Seronegative spondyloarthritis in familial Mediterranean fever. *Semin Arthritis Rheum* 1997;27:67-72.
10. Beauvais C, Kaplan G, Mougnot B, Michel C, Marinho E. Cutaneous vasculitis and IgA glomerulonephritis in ankylosing spondylitis. *Ann Rheum Dis* 1993;52:61-2.
11. Mullick FG, McAllister HA Jr, Wagner BM, Fenoglio JJ Jr. Drug related vasculitis. Clinicopathologic correlations in 30 patients. *Hum Pathol* 1979;10:313-25.
12. Machet L, Jan V, Ouakil H, Vaillant L, Estève E, Lorette G. Cutaneous leukocytoclastic vasculitis in a case of ankylosing spondylitis. *Acta Derm Venereol* 1997;77:324.
13. Cowling P, Ebringer R, Ebringer A. Association of inflammation with raised serum IgA in ankylosing spondylitis. *Ann Rheum Dis* 1980;39:545-9.
14. Schlesinger M, Kopolovic J, Viskoper RJ, Ron N. A case of familial Mediterranean fever with cutaneous vasculitis and immune complex nephritis: Light, electron, and immunofluorescent study of renal biopsy. *Am J Clin Pathol* 1983;80:511-4.

**Source of Support:** Nil, **Conflict of Interest:** None declared.