

Spondylolysis repair using a pedicle screw hook or claw-hook system. —a comparison of bone fusion rates—

Ko Ishida¹⁾, Yoichi Aota²⁾, Naoto Mitsugi¹⁾, Takashi Kuniya¹⁾, Takaaki Morii¹⁾, Takuya Kawai²⁾, Katsutaka Yamada³⁾ and Tomoyuki Saito³⁾

1) Department of Orthopedic Surgery, Yokohama City University Medical Center, Kanagawa, Japan

2) Department of Spine Surgery, Yokohama City Brain and Spine Center, Kanagawa, Japan

3) Department of Orthopedic Surgery, Yokohama City University, Kanagawa, Japan

Abstract:

Introduction: To assess the bone fusion rates and clinical results of two surgical methods (pedicle screw claw-hook fixation and pedicle screw hook fixation) of lumbar spondylolysis repair.

Methods: A multicenter database of surgical patients with lumbar spondylolysis was reviewed. All patients < 20 years old with a minimum of 6 months of follow-up and computed tomography images were included. Operation time and blood loss amount were investigated. Visual analogue scale (VAS; 0-10) scores for lower back pain were evaluated to assess clinical results.

Results: A total of 17 patients met the inclusion criteria. Pedicle screw hook fixation was performed in five patients (the hook group), and pedicle screw claw-hook fixation was performed in 13 patients (the claw-hook group). One patient was included in both groups because each method was performed at different lumbar levels (L4 and L5). The bone fusion rates at 3, 6, and 9 months after surgery were significantly higher in the claw-hook group than those in the hook group. Operation time and blood loss amount were not significantly different between the groups. VAS scores improved in the claw-hook group but not in the hook group because of a small number of patients.

Conclusions: Pedicle screw claw-hook fixation was more effective than pedicle screw hook fixation in terms of bone fusion rates.

Keywords:

lumbar spondylolysis, pedicle screw claw hook fixation, pedicle screw hook fixation

Spine Surg Relat Res 2018; 2(2): 135-139
dx.doi.org/10.22603/ssrr.2017-0011

Introduction

Lumbar spondylolysis is a common cause of lower back pain in adolescents and young adults.

Conservative treatments are successful in most patients, but those who remain symptomatic may benefit from surgery. There are several surgical methods for the treatment of lumbar spondylolysis: the Buck's operation¹⁾, the Morscher hook screw system²⁾, the Scott wiring technique³⁾, and pedicle screw hook fixation⁴⁾. Pedicle screw hook fixation has been reported to provide good bone fusion rates⁵⁾. However, the fusion rate in our experience was 63% at one year after surgery⁶⁾. Pedicle screw claw-hook fixation was developed to allow more rigid fixation and a higher bone fusion rate.

The purpose of this study was to compare two surgical methods (pedicle screw hook fixation and pedicle screw claw-hook fixation) for the treatment of lumbar spondylolysis in terms of bone fusion rates and clinical results.

Materials and Methods

We designed this study to test the hypothesis that pedicle screw claw-hook fixation provides better bone fusion rates and clinical results than pedicle screw hook fixation. Seventeen patients were treated surgically for symptomatic spondylolysis between 2003 and 2014. Each patient met the following criteria: < 20 years old, symptomatic bilateral spondylolysis with sclerotic changes on computed tomography

Corresponding author: Ko Ishida, isikoh@yokohama-cu.ac.jp

Received: February 10, 2017, Accepted: September 10, 2017, Advance Publication: February 28, 2018

Copyright © 2018 The Japanese Society for Spine Surgery and Related Research

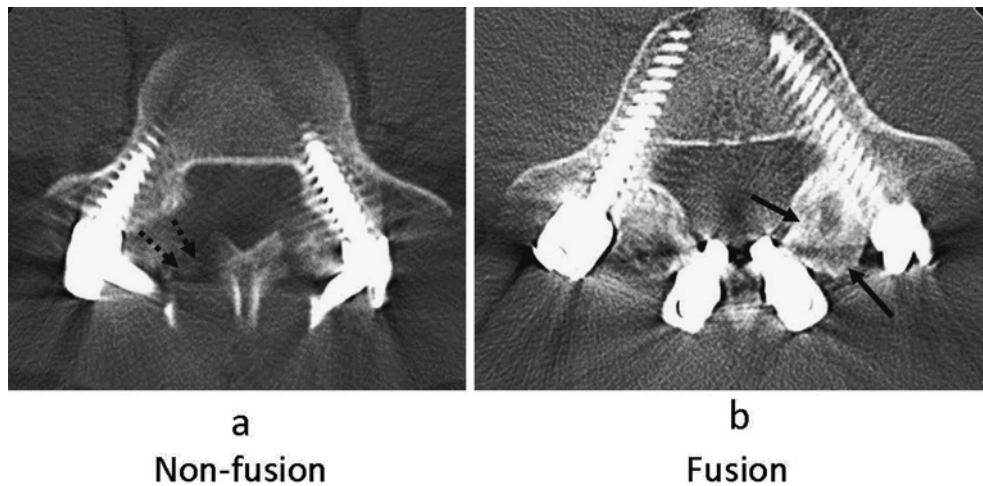


Figure 1. Bone fusion was evaluated by computed tomography. Non-fusion was defined as to be present when trabeculae did not pass across the lytic defect; (a) Fusion was defined as to be present when trabeculae passed across the lytic defect; (b) The dotted arrow shows the location of non-fusion. The black arrow shows the location of fusion.

(CT) images, debilitating lower back pain with or without leg pain, lack of response to conservative treatment for at least 6 months, < Thompson's grade 2 for disc degeneration, underwent one of the methods being assessed, and had been followed-up for 6 months using CT. The choice of operative procedures was made by the surgeons and institutes involved. CT images were obtained every 3 months after surgery until bone fusion was confirmed.

Bone fusion was evaluated using axial and sagittal CT images by two experienced spine surgeons. Bone fusion was defined to be present when trabeculae passed across the lytic defect (Fig. 1). The inter-observer concordance rate was evaluated. Operation time and blood loss amount were investigated. Visual analogue scale (VAS; 0-10) scores of lower back pain were evaluated to determine the clinical results. This study was approved by an Institutional Review Board, and the subjects and their parents, for those under-age, provided informed consent.

Surgical procedure

A midline longitudinal incision was made under general anesthesia. The paraspinal musculature was elevated laterally to expose the pars and transverse process base. After exposure of the pars interarticularis defect, the fibrocartilaginous defect was curetted completely. Iliac bone was harvested from the iliac crest and shaped to fit into the defect. The cancellous bone was packed into the defect and the cortical bone was placed on it and fit to the lamina surface. In the hook group, pedicle screws were inserted and lamina hooks were placed on laminae (Fig. 2a, 3a). Rods were bent to connect the screw and hook. The grafted bone was stabilized by compression between the screw and hook.

In the claw-hook group, a hook-rod complex and superior lamina hook were connected to produce a claw-hook in the first six patients (Fig. 2b). In two cases, the superior hook

was not placed appropriately. After these experiences, we decided to place separate hook-claws and then connect them to the pedicle screw using a maximally bent rod in the remaining patients (Fig. 2c, 3b). In both groups, a hard or soft corset was used for > 3 months after surgery and removed after bone fusion. The items evaluated were sex, age, follow-up duration, operation time, blood loss amount, bone fusion rates at each period, and VAS scores of lower back pain before surgery and at the final follow-up.

Statistical analysis.

The bone fusion rate was compared using the Fisher's exact probability test. The other parameters were compared using the Mann-Whitney *U*-test. Statistical significance was accepted at $p < 0.05$.

Results

In total, 17 patients were enrolled (14 male) with an average age of 16 (range 11-20) years.

The pars defect was at L3 in one case, L4 in three cases, and L5 in 15 cases. Concomitant defects at L3 and L4 occurred in one case and L4 and L5 in one case.

Five patients underwent pedicle screw hook fixation (the hook group) and thirteen patients underwent pedicle screw claw-hook fixation (the claw-hook group). One patient underwent the hook method at L4 and the claw-hook method at L5, and was therefore included in both groups.

There were five patients in the hook group (two men). The average age was 16 (range 16-20) years. The average follow-up period was 22 (range 9-39) months. There were 13 patients in the claw hook group (12 men). The average age was 16 (range 11-20) years. The average follow-up period was 12 (range 6-24) months. There were significant differences in the sex distributions of the groups (Table 1).

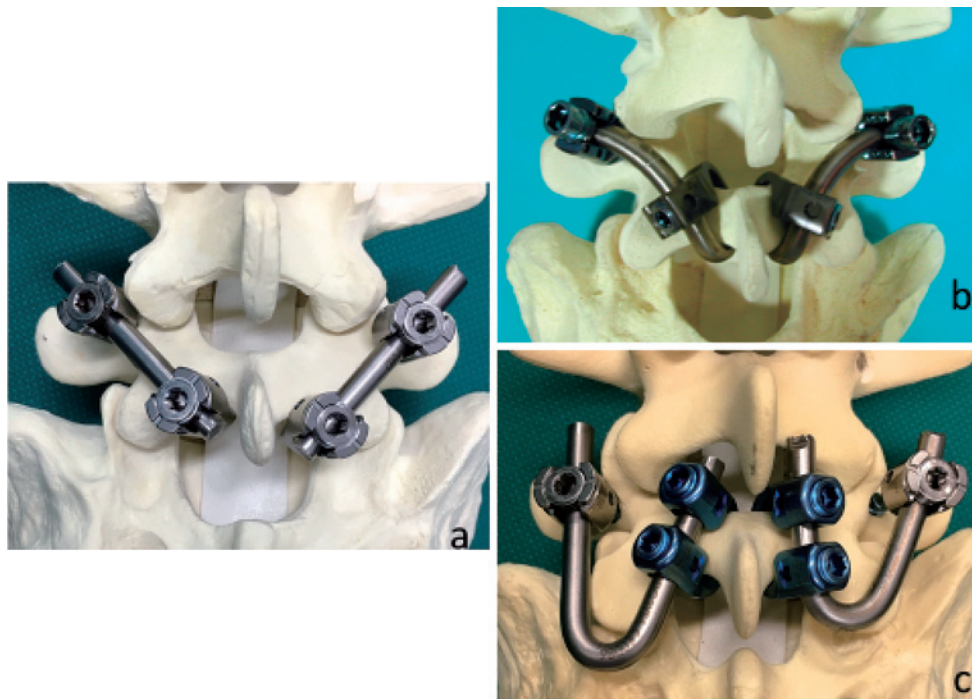


Figure 2. Pedicle screw hook fixation; (a) Pedicle screw claw-hook fixation: (b, c) The first six cases were treated using a rod-hook complex; (b) The remaining cases were treated using separate claw hooks; (c).

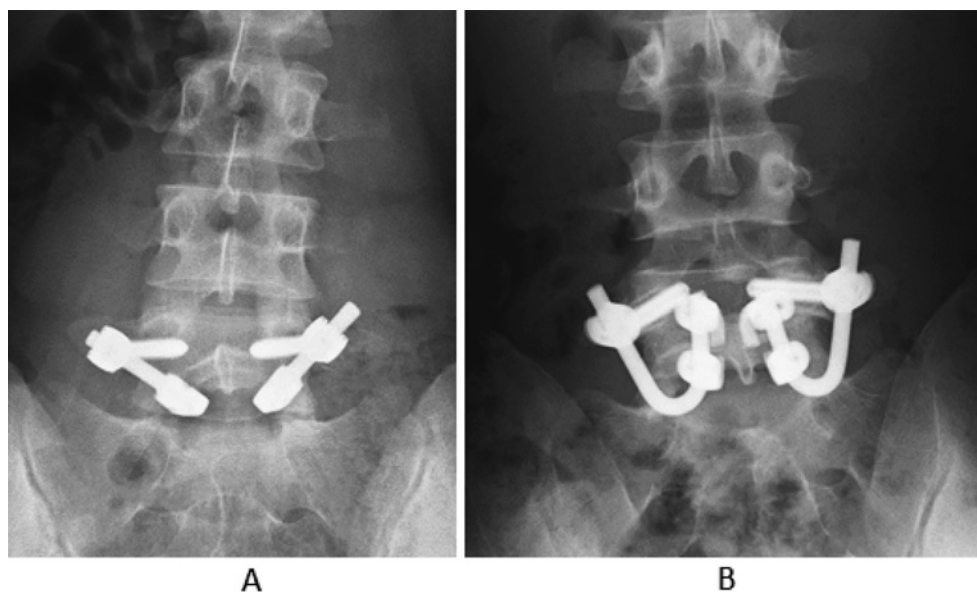


Figure 3. Antero-posterior radiographs of pedicle screw hook fixation (A) and pedicle screw claw-hook fixation (B).

The operation time was 215 ± 86 (average \pm SD) minutes in the hook group, and 271 ± 73 minutes in the claw-hook group. Blood loss amount was 78 ± 21 g in the hook group, and 353 ± 307 g in the claw-hook group. Surgical incision tended to be larger in the claw-hook group, but this difference was not statistically significant.

Operative complications included one case of dural puncture in the hook group and two cases of position failures of

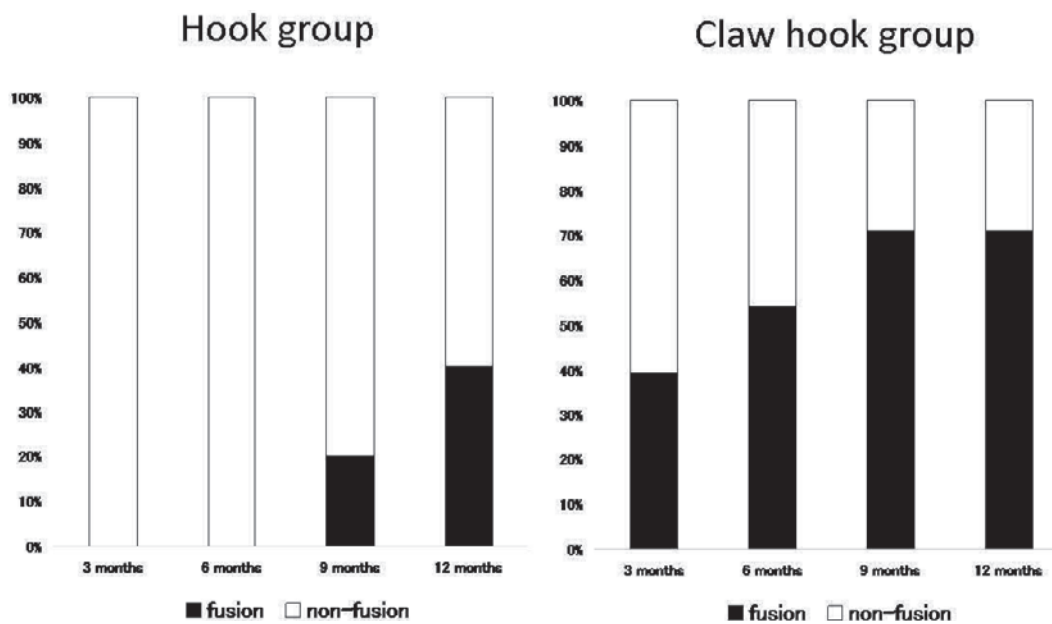
the superior lamina hook at the pars in the claw-hook group.

Bone fusion at the pars defect was evaluated by two spine surgeons based on serial axial and sagittal CT images. The inter-observer concordance rate was 93.8%.

The bone fusion rate at 3 months after surgery was 0% in the hook group and 39% in the claw-hook group ($p = 0.04$), 0% in the hook group and 54% in the claw-hook group ($p = 0.01$) at 6 months, 20% in the hook group and 71% in the

Table 1. Patient Characteristics and Operative Inventions.

	Hook group (N=5)	Claw hook group (N=13)	P value
Age	16+/-3	16+/-3	0.19
Sex (male:female)	2:3	12:1	0.04
Follow up periods (months)	22+/-15 (9-39)	12+/-6 (6-24)	0.30
Operation time (minutes)	215+/-86	271+/-73	0.17
Blood loss amount (g)	78+/-21 (50-100)	353+/-307 (50-835)	0.11
Complications	Dural puncture (N=1)	Positioning failure of hook (N=2)	

**Figure 4.** Graphs of bone fusion rates at each period in the two groups.

claw-hook group ($p < 0.01$) at 9 months, and 40% in the hook group and 71% in the claw-hook group ($p = 0.13$) at 12 months (Fig. 4).

In terms of clinical results, the VAS scores (0-10) before surgery were 8 ± 0 in the hook group ($n = 2$), and 5.8 ± 2.6 in the claw-hook group ($n = 7$). The VAS scores at the final follow up were 4 ± 0 in the hook group and 2.5 ± 2.3 in the claw-hook group. The VAS scores were significantly improved after surgery in the claw-hook group ($p = 0.03$), but those in the hook group were not comparable because of small sample size.

Discussion

Lumbar spondylolysis is generally thought of as a stress fracture, and symptoms such as, lower back pain and bone fusion, can mostly be improved in the early stages using conservative treatment. However, bone fusion at the terminal stage, such as pseudarthrosis, is difficult to resolve using conservative treatment⁷. All subjects in this study were at the terminal stage of spondylolysis at the pars interarticularis.

There are several operative methods for the treatment of

lumbar spondylolysis. The pedicle screw hook fixation is biomechanically stronger than wires in terms of flexion and extension stiffness^{8,9}. However, the pedicle screw hook fixation ends to provide weaker results in terms of torsion stiffness^{8,9}.

The bone fusion rate of pedicle screw hook fixation has been reported as 50%-92%^{4,5,10,11}; however, the definitions of bone fusion used in these studies were not consistent. In this study, bone fusion was defined by two spine surgeons based on axial and sagittal-view CT images.

In contrast to the previous surgical reports, the bone fusion rate at one year after surgery in the pedicle screw hook fixation group was 40%. A possible explanation for the low fusion rate may be the strict definition of bone fusion using CT images.

The pedicle screw claw-hook fixation was invented to allow stronger stabilization and higher bone fusion rates¹². However, connecting the rod-hook complex and the superior lamina hook was technically demanding in the present study. We therefore decided to place two separate hooks at the lamina to produce the claw before connecting the claw hooks and pedicle screw using a maximally bent rod. Although biomechanical tests comparing the pedicle screw and

claw-hook systems have not been performed yet, the bilateral claw-hooks should stabilize lamina motions in all directions and compensate the pedicle screw and hook method's weakness with respect to resisting torsion stiffness. The higher bone fusion rate in the pedicle screw claw-hook fixation group suggested that this system provided stronger fixation than the pedicle screw hook fixation system.

A disadvantage of the pedicle screw claw-hook fixation was that making the connection between the claw-hooks and pedicle screw was technically difficult. Furthermore, the system was too bulky to use for the treatment of consecutive spondylolysis, for example, if L4 and L5 levels was both affected.

In terms of the clinical results, the VAS scores improved in the claw-hook group and but those in the hook group did not, probably because the number of patients was too small (n=2).

In terms of the relationship between bone fusion and clinical results, Lee *et al* reported that there was no significant difference in the clinical outcomes between the fusion group and non-fusion group at the final follow-up¹³. However, bone fusion is a goal in the treatment of pseudarthrosis and important in the prevention of spondylolisthesis.

The limitations of this study were that the number of patients was small, the backgrounds of patients were different, the follow-up period was not long enough, and the choice of surgical methods was determined by the surgeons and institutes rather than being standardized. And the individual differences of the surgical technical skills were also limitations.

In conclusion, early bone fusion is important for treating adolescents and young adults with lumbar spondylolysis. The bone fusion rate of the claw-hook group was superior to that of the hook group, suggesting that this method should be used instead of the hook method when appropriate.

Conflicts of Interest: The authors declare that there are no conflicts of interest.

Acknowledgement: This study was approved by YCU IRB.

References

1. Buck JE. Direct repair of the defect in spondylolisthesis: preliminary report. *J Bone Joint Surg.* 1970;52:432-7.
2. Morscher E, Gerber B, Fasel J. Surgical treatment of spondylolisthesis by bone grafting and direct stabilization of spondylolysis by means of a hook screw. *Acta Orthop Trauma Surg.* 1984;103:175-8.
3. Bradford DS, Iza J. Repair of the direct in spondylolysis or minimal degree of spondylolisthesis by segmental wire fixation and bone grafting. *Spine.* 1985;10:673-9.
4. Tokuhashi Y, Matsuzaki H. Repair of defects in spondylolysis by segmental pedicle screw hook fixation. *Spine.* 1996;21:2041-5.
5. Roca J, Iborra M, Cavinilles-Walker JM, et al. Direct repair of spondylolysis using a new pedicle screw hook fixation: Clinical and CT- assessed Study. *J Spinal Disord Tech.* 2005;18:82-9.
6. Hara J, Aota Y, Watanabe K, et al. Surgical treatment of lumbar spondylolysis with pedicle screw hook fixation. Bone union diagnosed by plain computed tomography. *The Japan Spine Research Society.* 2004;15:208.
7. Fujii K, Katoh S, Sairyo K, et al. Union of defects in the pars interarticularis of the lumbar spine in children and adolescents. *J Bone Joint Surg (Br).* 2004;86:225-31.
8. Deguchi M, Rapoff AJ, Zdeblick TA. Biomechanical comparison of spondylolysis fixation techniques. *Spine.* 1999;24:328-33.
9. Ulibarri JA, Anderson PA, Escarcega T, et al. Biomechanical and clinical evaluation of a novel technique for surgical repair of spondylolysis in adolescents. *Spine.* 2006;31:2067-72.
10. Chung CH, Chiu HM, Wang SJ, et al. Direct repair of multiple levels lumbar spondylolysis by pedicle screw laminar hook and bone grafting: clinical, CT, and MRI- assessed study. *J Spinal Disord Tech.* 2007;20:399-402.
11. Pellise F, Toribio J, Ricas A, et al. Clinical and CT scan evaluation after direct defect repair in spondylolysis using segmental pedicular screw hook fixation. *J Spinal Disord.* 1999;12:363-7.
12. Aota Y. Direct repair of the defect in spondylolysis by pedicles screw claw hook fixation. *Arthritis (JPN).* 2009;7:70-5.
13. Lee GW, Lee SM, Suh BG. Direct repair surgery with screw fixation for young patients with lumbar spondylolysis: patient-reported outcomes and fusion rate in a prospective interventional study. *Spine.* 2015;40:234-41.

Spine Surgery and Related Research is an Open Access article distributed under the Creative Commons Attribution - NonCommercial - NoDerivatives 4.0 International License. To view the details of this license, please visit (<https://creativecommons.org/licenses/by-nc-nd/4.0/>).