



CASE REPORT

Acute myeloid leukemia synchronous with multiple myeloma successfully treated by azacytidine/lenalidomide and daratumumab without a decrease in myeloid clone size

Celine Berthon^{a,b}, Morgane Nudel^a, Eileen M. Boyle^a, Laure Goursaud^a, Thomas Boyer^{b,c}, Alice Marceau^{b,c}, Bruno Quesnel^{a,b,c,d,*}

^a CHU Lille, Service des Maladies du Sang, F-59000 Lille, FRANCE

^b CNRS, Inserm, UMR9020 – UMR-S 1277 - Canther – Cancer Heterogeneity, Plasticity and Resistance to Therapies, F-59000 Lille, FRANCE

^c CHU Lille, Laboratory of Hematology, F-59000 Lille, FRANCE

^d Univ. Lille, F-59000 Lille, FRANCE

ARTICLE INFO

Keywords:

Myeloma
AML
CMML
Azacytidine
Lenalidomide
Daratumumab
Clonality

ABSTRACT

Synchronous diagnosis of acute myeloid leukemia (AML) and symptomatic multiple myeloma (MM) is a rare situation that poses serious therapeutic difficulties. We report the case of a 68-year-old male which evolved simultaneously to symptomatic MM and AML. Both diseases first responded to treatment for 40 months after 7 + 3 induction and maintenance therapy of azacytidine + lenalidomide. MM relapsed first and was treated with azacytidine + daratumumab, which led an additional 15 months of progression-free survival. Little myeloid clonal size reduction over time was seen. This case shows that AML and MM can be effectively treated simultaneously using appropriate combinations.

1. Introduction

Secondary myeloid malignancies occurring after the treatment of multiple myeloma (MM) is a well-characterized risk, and numerous publications described the poor prognosis of these patients [1]. More recent evidence suggests that early myeloid minor clones carrying chromosomal abnormalities or gene mutations are present at the diagnosis of MM, which suggests that this malignant B-cell disease may also coexist with clonal or preclonal myeloid hematopoiesis [2]. Occasional reports described shared cytogenetic abnormalities between myeloid blast cells and malignant plasmocytes, but definitive indication of a shared common ancestor between these two lineages has not been discovered [3]. MM and monoclonal gammopathy of undetermined significance (MGUS) patients also present an intrinsic risk of developing acute myeloid leukemia (AML) independently of treatment [4].

The simultaneous occurrence of a characterized myeloid malignancy and MM clearly suggests that clonal or preclonal hematopoiesis and fully blown malignant myeloid cells may coexist and expand in parallel with malignant plasma cells. We report the occurrence of chronic myelomonocytic leukemia (CMML) and smoldering MM in a patient with subsequent synchronous evolution to AML and MM and the parallel long-term response of both diseases to azacytidine

combinations with lenalidomide then daratumumab.

2. Case report

In August 2012, a 68-year-old male presented with an IgA lambda paraprotein of 3.8 g/L and elevated lambda light chains (5.937 mg/L). Blood count showed only mild thrombocytopenia (143 G/L), and there was no renal impairment. A skeletal survey was performed, and it did not reveal any lytic lesions. An additional MRI of the spine in December 2012 showed only diffuse bone infiltrations without evidence of focal lesions. The final diagnosis was low/intermediate-risk smoldering myeloma, and a watch and wait policy was chosen. In April 2014, the patient developed peripheral blood monocytosis that reached 6.2 G/L, and a repeat bone marrow aspirate showed dual infiltration by 41% plasma cells and 65% dystrophic monocytes. A SNP array of CD138-sorted plasma cells revealed a pseudo-diploid karyotype with -18, +1q, +6p, del13q, del16p, del16q, del22q and delXp, which is consistent with high-risk disease. Diagnoses of a CMML-1 and high-risk ISS III MM with poor prognosis were made. In May 2014, a new bone marrow aspirate was performed before the initiation of MM therapy, and it showed 30% blasts. The myeloid karyotype was normal, and next-generation sequencing (NGS) revealed *TET2* and *NRAS* mutations and

* Corresponding author: Bruno QUESNEL, Service des Maladies du Sang, Centre Hospitalier et Universitaire de Lille, Rue Polonovski, F-59037, Lille, France.
E-mail address: bruno.quesnel@chru-lille.fr (B. Quesnel).

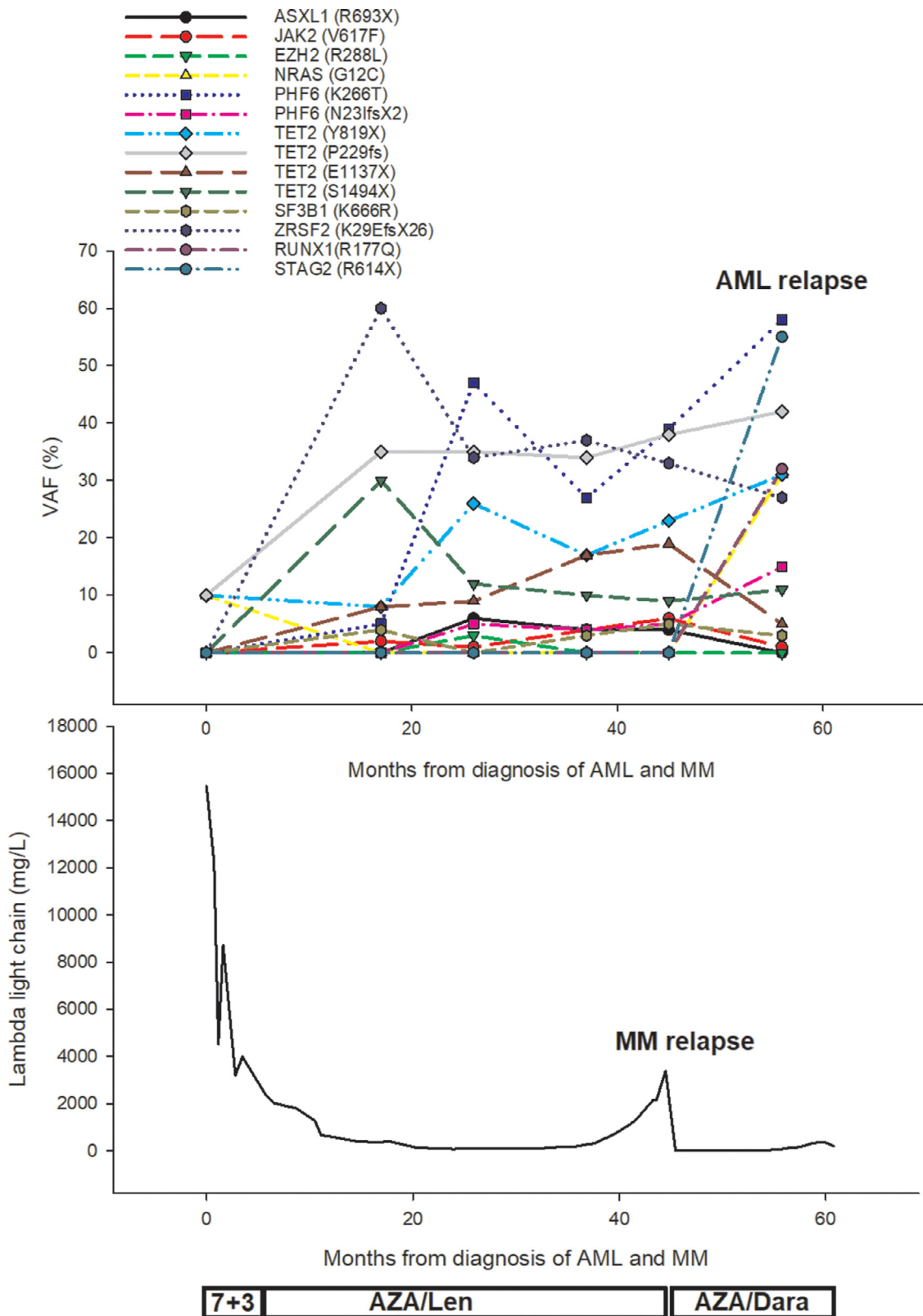


Figure 1. Myeloid clonal evolution during treatment. Variant allele frequency (VAF) of mutations evaluated using NGS and Serum Free Light Chain (SFLC) measurement during treatment with induction chemotherapy (7 + 3), AZA/Len, and AZA/daratumumab.

WT1 overexpression. These results provided evidence of AML and MM coevolving from precursor states. SFLCs were on the rise at 7200 mg/L, and blast and plasma cells were found at various levels on renewed bone marrow aspirates. It was therefore decided to treat the patient

with 7 + 3 induction chemotherapy, which led to a CR for AML, confirmed at day 35 with bone marrow aspirate showing 2% blast but still 7% dystrophic plasma cells. However, an episode of severe sepsis precluded any further intensive consolidation. A maintenance therapy with

Azacytidine (AZA) 75mg/m²×7d/4w combined with Lenalidomide (Len) 10mg d1-d21, was started and progressively increased to 25mg. After six cycles of AZA/Len, free light chain and bone marrow aspirate confirmed ongoing AML response and very good partial response (VGPR) for MM. After 12 cycles, bone marrow biopsy showed no blast excess and 10% plasma cells. AZA/Len was continued, and the lenalidomide dose was reduced to 15 mg/d, 21 d/4 w due to cytopenia until September 2017, when SLFC measurement showed MM relapse (Figure 1). Lenalidomide was discontinued and replaced with daratumumab 16 mg/kg once weekly during cycles 1 and 2, every 2 weeks during cycles 3 through 6, and every 4 weeks thereafter. Daratumumab was continued in parallel with azacytidine, and SFLC levels in December 2017 showed VGPR after 3 cycles of AZA/daratumumab. The patient received 15 further cycles until February 2019, when he presented with relapsed AML with 60% blasts on bone marrow aspirate and no evidence of dystrophic plasma cells. SLFC levels confirmed the stability of the MM response. The patient then received two cycles of low-dose cytarabine combined with venetoclax, but eventually died in May 2019 of leukemic progression.

Tolerance to the AZA/LEN and AZA/daratumumab regimens was excellent, with no occurrence of grade 3-4 toxicity.

Molecular follow-up of AML and MM showed clonal evolution at relapse for both diseases. NGS analysis of bone marrow cells showed major clonal evolution during the first year of treatment with AZA/Len. Mutations of *ASXL1*, *JAK2*, *PHF6*, *SF3B1*, and *ZRSF2*, as well as additional mutations of *TET2* with the disappearance of *NRAS*, were identified in September 2015 simultaneously with ongoing AML CR and MM VGPR (Figure 1). Clonal repartition remained remarkably stable after this time, except for the expansion of a *PHF6*-containing clone and additional mutations of *ASXL1*, *PHF6* and *TET2* in June 2016, with no evidence of disease progression for AML or MM. SNP-array of CD138-sorted plasma cells showed an additional del17p at MM relapse in September 2017. AML relapse in February 2019 showed additional mutations of *RUNX1*, *NRAS*, and *STAG2*.

3. Discussion

AML on most MM patients occurs as a therapy-related event, frequently in heavily pretreated subjects. The malignant myeloid and aggressive clone rapidly dominates in these patients, and the prognosis is mostly related to the possibility of bridging them to transplant. However, MM and AML may coexist in a few cases, and synchronous evolution of AML and MM were observed [5–11]. Cases reported in the literature were mostly published before 2000 with little detail about treatment or survival. Eleven selected cases with sufficient information showed a very poor outcome, except for one case who was bridged to

transplant (Table 1). These data highlight the adverse features of these cases. However, we here show that these patients may be effectively treated with combination of drugs active in both diseases. Lenalidomide is highly active against malignant plasma cells, and it showed some activities in AML. Azacytidine is the standard treatment for high-risk myelodysplastic syndrome and AML in unfit patients, and it recently showed some potential activity in multiple myeloma in combination with daratumumab, likely via an induced upregulation of CD38 [12]. We used the AZA/Len regimen as a maintenance therapy for AML after CR was obtained after a 7+3 induction regimen and as first-line therapy for MM, and this regimen remained efficient for more than 40 months before MM progression. Daratumumab demonstrated its activity in relapsed/refractory MM [13]. Here, daratumumab in combination with azacytidine led to a VGPR and a further 15 months PFS, until the patient fatally relapsed from AML. This accumulated 55 months of survival was the longest reported response to date (Table 1). Recent trials showing the dramatic efficacy of a daratumumab antibody as a first-line treatment also suggest that it may be a therapeutic option in this very rare and specific situation of codiagnosis of AML and MM.

Despite the efficacy of AZA/Len and AZA/daratumumab combinations, there was little evidence for a decrease in the myeloid clonal size. MM progression did not affect the mutated allele frequencies. We found no molecular evidence of common lineage between malignant plasma cells and the myeloid clone, but NGS panel and CGH used cannot rule out this hypothesis which could only be fully investigated by whole genome and epigenome sequencing. The limited impact of azacytidine on the size of malignant clones was reported in AML CMML and MDS, which indicates that the combined treatment should be continued as maintenance therapy if a response is obtained for AML and MM [14].

4. Conclusion

The difficult clinical situation of synchronous evolution of MM and AML may be efficiently treated with appropriate combinations of available drugs as ongoing therapy. A rational design of new drug associations that are potentially active in both diseases should be considered in this very specific and rare clinical situation, where data from clinical trials are unlikely to become available.

Author contributions

Celine Berthon: investigation, writing, Morgane Nudel: investigation, Eileen M. Boyle: investigation, writing-review and editing. Laure Goursaud: investigation and writing. Thomas Boyer: investigation and writing. Alice Marceau: investigation and writing. Bruno Quesnel: investigation, writing, review and editing, supervision and

Table 1

Selected list of patients with synchronous diagnoses of AML and myeloma reported in the literature with available information about treatment and survival.

Patient N°	Year of report	Age/sex	AML	MM	Treatment	OS (months)	Reference
1	1977	64/F	AML post-CMML	IgA κ	7 + 3	4	1
2	1980	74/M	M4	IgG κ	MP	1	1
3	1982	79/M	M4	IgG λ	7 + 3 + 6-TG	2	1
4	1990	73/M	AML	IgG	MP	4*	7
5	1998	73/M	M5	IgA κ	Hydroxyurea + Interferon	12	1
6	1998	70/M	M0	IgG κ	FLAG-IDA	4	1
7	2000	51/M	AML	κ	7 + 3 and Bortezomib, AlloSCT	13.5 +	2
8	2003	77/M	M5	λ	S.C.	1	5
9	2015	73/M	AML	IgA λ	Bortezomib + CAG	6 +	6
10	2016	55/F	M1	IgG κ	S.C.	NA	3
11	2017	73/F	AML post MDS 5q-	IgG	Azacytidine ^{&}	12	4

Abbreviations: CMML = Chronic Myelomonocytic Leukemia; AML = Acute Myeloid Leukemia; MM = Multiple Myeloma; MDS = Myelodysplastic Syndrome; OS = Overall Survival; MP = Melphalan Prednisone; FLAG-IDA = Fludarabine, Idarubicin; G-CSF, High-dose Cytarabine; AlloSCT = Allogeneic Stem Cell Transplantation; S.C. = Supportive Care; 6-TG = 6-Thioguanine; CAG = Low-dose Cytarabine, Aclarubicin, G-CSF,

* From diagnosis of AML made 3 months after MM

& 5q- MDS treated with lenalidomide

conceptualization.

Declaration of Competing Interest

None

Acknowledgement

This work has been supported by Institut pour la Recherche sur le Cancer de Lille, 2018

References

- [1] A Thomas, S Mailankody, N Korde, SY Kristinsson, I Turesson, O Landgren, Second malignancies after multiple myeloma: from 1960s to 2010s, *Blood* 119 (2012) 2731–2737, <https://doi.org/10.1182/blood-2011-12-381426>.
- [2] DM Reddi, CM Lu, G Fedoriw, et al., Myeloid neoplasms secondary to plasma cell myeloma: an intrinsic predisposition or therapy-related phenomenon? A clinicopathologic study of 41 cases and correlation of cytogenetic features with treatment regimens, *Am J Clin Pathol* 138 (2012) 855–866, <https://doi.org/10.1309/AJCPOP7APGDT9JIU>.
- [3] G Sashida, Y Ito, A Nakajima, et al., Multiple myeloma with monosomy 13 developed in trisomy 13 acute myelocytic leukemia: numerical chromosome abnormality during chromosomal segregation process, *Cancer Genet Cytogenet* 141 (2003) 154–156.
- [4] S Mailankody, RM Pfeiffer, SY Kristinsson, et al., Risk of acute myeloid leukemia and myelodysplastic syndromes after multiple myeloma and its precursor disease (MGUS), *Blood* 118 (2011) 4086–4092, <https://doi.org/10.1182/blood-2011-05-355743>.
- [5] CM Anderson, CE Bueso-Ramos, SA Wallner, M Albitar, TE Rosenzweig, CA Koller, Primary myeloid leukemia presenting concomitantly with primary multiple myeloma: two cases and an update of the literature, *Leuk Lymphoma* 32 (1999) 385–390, <https://doi.org/10.3109/10428199909167402>.
- [6] D Kim, B Kwok, A Steinberg, Simultaneous acute myeloid leukemia and multiple myeloma successfully treated with allogeneic stem cell transplantation, *South Med J* 103 (2010) 1246–1249, <https://doi.org/10.1097/SMJ.0b013e3181fa5eeb>.
- [7] R Kumar, VK Srinivasan, P Sharma, et al., Synchronous Plasma Cell Myeloma and Acute Myeloid Leukemia in a Therapy-Naive Patient: A Rare Occurrence, *Indian J Hematol Blood Transfus* 32 (2016) 168–172, <https://doi.org/10.1007/s12288-015-0628-9>.
- [8] S Oka, K Ono, M Nohgawa, Successful treatment with azacitidine for the simultaneous occurrence of multiple myeloma and acute myeloid leukemia with concomitant del(5q) and the JAK2 V617F mutation, *Ann Hematol* 96 (2017) 1411–1413, <https://doi.org/10.1007/s00277-017-3032-8>.
- [9] DC Luca, IY. Almanaseer, Simultaneous presentation of multiple myeloma and acute monocytic leukemia, *Arch Pathol Lab Med* 127 (2003) 1506–1508, [https://doi.org/10.1043/1543-2165\(2003\)127<1506:SPOMMA>2.0.CO;2](https://doi.org/10.1043/1543-2165(2003)127<1506:SPOMMA>2.0.CO;2).
- [10] W Lu-Qun, L Hao, L Xiang-Xin, et al., A case of simultaneous occurrence of acute myeloid leukemia and multiple myeloma, *BMC Cancer* 15 (2015) 724, <https://doi.org/10.1186/s12885-015-1743-6>.
- [11] H Yashige, T Maekawa, H Fujii, K Nishida, [Acute myelogenous leukemia (M2) simultaneously associated with multiple myeloma with special reference to chromosome abnormality of t(6; 14) (p21.1; q32.3)], *Rinsho Ketsueki* 31 (1990) 359–364.
- [12] P Choudhry, MC Mariano, AP Wiita, DNA Methyltransferase Inhibitors Increase Expression of CD38 and Enhance Daratumumab Efficacy in Multiple Myeloma, *Blood* 132 (2018) 10 1182/blood-2018-99-114206.
- [13] AK Nooka, JL Kaufman, CC Hofmeister, et al., Daratumumab in multiple myeloma, *Cancer* 125 (2019) 2364–2382, <https://doi.org/10.1002/cncr.32065>.
- [14] J Merlevede, N Droin, T Qin, et al., Mutation allele burden remains unchanged in chronic myelomonocytic leukaemia responding to hypomethylating agents, *Nat Commun* 7 (2016) 10767, <https://doi.org/10.1038/ncomms10767>.