

# Renal cell carcinoma diagnosed during pregnancy: a case report and literature review

Journal of International Medical Research

2018, Vol. 46(8) 3422–3426

© The Author(s) 2018

Article reuse guidelines:

[sagepub.com/journals-permissions](http://sagepub.com/journals-permissions)

DOI: 10.1177/0300060518776744

[journals.sagepub.com/home/imr](http://journals.sagepub.com/home/imr)



Ercan Yilmaz<sup>1</sup>, Fatih Oguz<sup>2</sup>, Gorkem Tuncay<sup>1</sup>,  
Rauf Melekoglu<sup>1</sup>, Ali Beytur<sup>2</sup>,  
Ebru Inci Coskun<sup>1</sup> and Ali Gunes<sup>2</sup>

## Abstract

Diagnosing cancer during pregnancy is uncommon. Although pregnancies with concomitant malignancies have been reported, urological tumours are possibly the most rarely identified tumours during pregnancy. Renal cell carcinoma appears to be the most common urological malignancy during pregnancy. In this case report, we discuss successful management of a patient who was diagnosed with renal cell carcinoma during the antenatal period.

## Keywords

Renal cell carcinoma, pregnancy, urological tumour, haematuria, malignancy, ultrasonography

Date received: 12 January 2018; accepted: 23 April 2018

## Introduction

Although receiving a diagnosis of cancer during pregnancy is rare, approximately one in every 1000 pregnancies is diagnosed with cancer during the antenatal period. While cervical cancer and breast cancer are among the most commonly identified cancers during pregnancy, gastrointestinal, urological, and lung cancers have a lower rate of incidence.<sup>1</sup> Among urological tumours, which are rarely identified tumours during pregnancy, renal cell

carcinoma (RCC) appears to be the most common urological malignancy during pregnancy.<sup>2</sup> In this case report, we describe

<sup>1</sup>Department of Obstetrics and Gynecology, Faculty of Medicine, Inonu University, Malatya, Turkey

<sup>2</sup>Department of Urology, Faculty of Medicine, Inonu University, Malatya, Turkey

### Corresponding author:

Ercan Yilmaz, Department of Obstetrics and Gynecology, Faculty of Medicine, Inonu University, Malatya, Turkey.  
Email: [ercanyilmazgyn@yahoo.com](mailto:ercanyilmazgyn@yahoo.com)



successful management of a patient who was diagnosed with RCC during the antenatal period and discuss our case in the context of the relevant literature.

## Case report

A 36-year-old patient at 16 weeks of pregnancy presented with the complaint of haematuria. Urinary ultrasonography showed a heterogeneous, well-demarcated mass with an approximate diameter of 12×9 cm on the upper pole of the right kidney. Magnetic resonance imaging was then performed (Figure 1), and the lesion that was identified by ultrasonography was observed to extend exophytically up to the inferior vena cava. Fine needle biopsy was performed for the patient, who was strongly suspected of having a renal tumour. A pathological examination confirmed a renal tumour. At 21 gestational weeks, right radical nephrectomy was performed in the patient by carrying out preterm prophylaxis (a Ca<sup>2+</sup> channel blocker was applied for tocolysis). The surgical team were cautioned about hypotension.

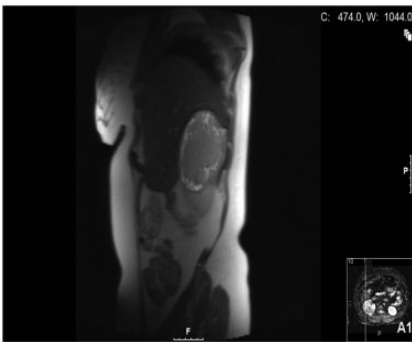
A pathological examination after surgery showed chromophobe RCC without

capsular invasion. No pathology was detected during routine antenatal follow-ups of the patient. The patient did not require any adjuvant treatment during the postoperative period. She was delivered by caesarean section at the 38th week of pregnancy because of a previous caesarean section. She was discharged on the second postoperative day because of her good general condition, as well as that of her newborn. The patient provided verbal consent for publication.

## Discussion

Although renal tumours are approximately 10 times more common in developed countries than in non-developed, they rarely appear during pregnancy. Although environmental factors are influential in the aetiology of renal tumours, chronic diseases (e.g., obesity, hypertension, and diabetes) may also play a role. This situation is slightly different for RCC. Elevated levels of oestrogen and progesterone increase the risk of RCC in multiparous women compared with nulliparous women.<sup>3</sup> The presence of hypertension is the most important risk factor for RCC, and approximately 18% of these patients have hypertension.<sup>2</sup> Genetic abnormalities have also been detected in development of RCC, especially Xp 11.2 translocation, which is the most common mutation.<sup>4</sup>

Although pathological examination of tissue and/or samples is necessary for diagnosing RCC, radiological imaging methods are also important. While ultrasonography is the easiest antenatal imaging technique, computerized tomography is not suitable for pregnant women. Magnetic resonance imaging is an option for identifying RCC.<sup>3</sup> RCC may be asymptomatic and appear as a completely incidentally detected renal mass during the antenatal period. However, RCC may also lead to complaints of abdominal pain, distention, urinary tract infection,



**Figure 1.** Magnetic resonance image of the upper abdomen obtained during the antenatal period. Contrast involvement and pelvicaliectasis were observed in the right kidney.

**Table 1.** Information of previously reported patients who were diagnosed with RCC during the antenatal period

Reference	Number of patients	Age of patient during diagnosis (years)	Gestational week during diagnosis	Gestational week during treatment	Treatment	Mode of delivery
Simon et al. <sup>7</sup>	1	N/A	First trimester	First trimester	RN	Aborted
Bovio et al. <sup>4</sup>	1	20	N/A	N/A	N/A	N/A
Van der Veldt et al. <sup>8</sup>	1	20	18th week	N/A	N/A	N/A
Yin et al. <sup>9</sup>	1	32	N/A	N/A	Lap. nephrectomy	N/A
O'Connor et al. <sup>10</sup>	1	34	11th week	19th week	Lap. nephrectomy	Spontaneous delivery
Lee et al. <sup>11</sup>	1	39	First trimester	19th week	Lap. nephrectomy	Spontaneous delivery
Fyn et al. <sup>12</sup>	1	N/A	12th week	24th week	RN	CS at the 24th week
Pearson et al. <sup>13</sup>	1	N/A	28th week	32th week	RN	CS at the 34th week
Stojnic et al. <sup>14</sup>	1	22	First trimester	Second trimester	RN	CS at the second trimester
Buda et al. <sup>6</sup>	1	N/A	Second trimester	17th week	RN	CS at the second trimester
Stroup et al. <sup>15</sup>	1	52	N/A	N/A	RN	N/A
Van Basten et al. <sup>16</sup>	1	30	N/A	16th week	RN	N/A
Casella et al. <sup>17</sup>	1	N/A	N/A	22nd week	RN	N/A
Sainsbury et al. <sup>18</sup>	1	30	N/A	11th week	Lap. nephrectomy	Spontaneous delivery
Ceglowska et al. <sup>19</sup>	1	N/A	32nd week	N/A	RN	CS at the 38th week
Armah et al. <sup>20</sup>	1	26	14th week	15th week	RN	Spontaneous delivery
Bettez et al. <sup>21</sup>	1	28	21st week	36th week	RN	CS at the 36th week

RN radical nephrectomy, CS caesarean section, Lap. laparoscopic, N/A not available.

hypertension, and haematuria. The only complaint of our patient was haematuria. However, cases of RCC that resulted in inferior vena cava thrombosis, haemolytic anaemia, and hypercalcemia have also been reported.<sup>5</sup>

Even though treatment for RCC is surgery, it should be individualized and a multidisciplinary approach should be established because it is rare. Surgery for RCC can be safely performed at every trimester for a patient who is diagnosed during the antenatal period. Precautions should also be taken to prevent uterine contractions in the second and third trimesters, and uterine manipulations should be avoided. Additionally, hypotension should be avoided because it negatively affects uteroplacental perfusion during this period. A case of RCC, in which surgery was postponed until the 28th week (threshold period for lung maturation), has also been reported.<sup>6</sup> Surgical laparotomic and laparoscopic approaches should be carried out by individualization. The characteristics of patients who were diagnosed with RCC during the antenatal period, and the surgical and pregnancy outcomes from 2004 to the present day are shown in Table 1.<sup>4,6-21</sup>

Postoperative adjuvant therapy is used in patients with metastatic RCC. In recent years, classical chemotherapy and hormone-therapy have been replaced by multikinase inhibitors (sunitinib, sorafenib), mammalian target of rapamycin inhibitors (everolimus, temsirolimus), and anti-angiogenic agents (bevacizumab).<sup>3</sup> In our case, adjuvant therapy was not administered because no metastasis was detected.

#### Declaration of conflicting interest

The authors declare that there is no conflict of interest.

#### Funding

This research received no specific grant from any funding agency in the public, commercial, or not-for-profit sectors.

#### References

1. Pavlidis N. Cancer and pregnancy: what should we know about the management with systemic treatment of pregnant women with cancer? *Eur J Cancer* 2011; 47: 348–352.
2. Scavuzzo A, Santana Rios Z, Diaz-Gomez C, et al. Renal Cell Carcinoma in a Pregnant Woman With Horseshoe Kidney. *Urol Case Rep* 2017; 11: 58–60.
3. Khaled H, Lahloubi NA and Rashad N. Review on renal cell carcinoma and pregnancy: A challenging situation. *J Adv Res* 2016; 7: 575–580.
4. Bovio IM, Allan RW, Oliai BR, et al. Xp11.2 translocation renal carcinoma with placental metastasis: a case report. *Int J Surg Pathol* 2011; 19: 80–83.
5. Ghanney EC, Cavallo JA, Levin MA, et al. Renal cell carcinoma with inferior vena cava thrombus extending to the right atrium diagnosed during pregnancy. *Ther Adv Urol* 2017; 16: 155–159.
6. Buda A, Pizzocaro G, Ceruti P, et al. Case report: renal cell carcinoma presenting as hypertension in pregnancy. *Arch Gynecol Obstet* 2008; 277: 263–265.
7. Simon I, Rorive S, Kirkpatrick C, et al. Clear cell renal carcinoma presenting as a bleeding cyst in pregnancy: inaugural manifestation of a von Hippel-Lindau disease. *Clin Nephrol* 2008; 69: 224–228.
8. van der Veldt AA, van Wouwe M, van den Eertwegh AJ, et al. Metastatic renal cell cancer in a 20-year-old pregnant woman. *Urology* 2008; 72: 776–777.
9. Yin L, Zhang D, Teng J, et al. Retroperitoneal laparoscopic radical nephrectomy for renal cell carcinoma during pregnancy. *Urol Int* 2013; 90: 487–489.
10. O'Connor JP, Biyani CS, Taylor J, et al. Laparoscopic nephrectomy for renal-cell carcinoma during pregnancy. *J Endourol* 2004; 18: 871–874.

11. Lee D and Abraham N. Laparoscopic radical nephrectomy during pregnancy: case report and review of the literature. *J Endourol* 2008; 22: 517–518.
12. Fynn J and Venyo AK. Renal cell carcinoma presenting as hypertension in pregnancy. *J Obstet Gynaecol* 2004; 24: 821–822.
13. Pearson GA and Eckford SD. Renal cell carcinoma in pregnancy. *J Obstet Gynaecol* 2009; 29: 53–54.
14. Stojnic J, Jeremic K, Petkovic S, et al. Renal cell carcinoma in pregnancy: a case report. *Eur J Gynaecol Oncol* 2009; 30: 347–349.
15. Stroup SP, Altamar HO, L'Esperance JO, et al. Retroperitoneoscopic radical nephrectomy for renal cell carcinoma during twin pregnancy. *J Endourol* 2007; 21: 735–737.
16. van Basten JP, Knipscheer B and de Kruif J. Case report: retroperitoneoscopic tumor nephrectomy during pregnancy. *J Endourol* 2006; 20: 186–187.
17. Casella R, Ferrier C, Giudici G, et al. Surgical management of renal cell carcinoma during the second trimester of pregnancy. *Urol Int* 2006; 76: 180–181.
18. Sainsbury DC, Dorkin TJ, MacPhail S, et al. Laparoscopic radical nephrectomy in the first trimester of pregnancy. *Urology* 2004; 64: 1231.e7–e8.
19. Ceglowska A and Michalski A. Renal cell carcinoma during pregnancy. *Ginekol Pol* 2004; 75: 145–149.
20. Armah HB and Parwani AC. Xp11.2 translocation renal cell carcinoma. *Arch Pathol Lab Med*, 2010; 134: 124–129.
21. Bettez M, Carmel M, Temmar R, et al. Fatal fast-growing renal cell carcinoma during pregnancy. *J Obstet Gynaecol Can* 2011; 33: 258–261.