



Case Report

Right-sided paraduodenal hernia with malrotation - A case report

Navin Poudel^a, Aramva Bikram Adhikari^{a,*}, Kshitiz Acharya^a, Devansh Upadhyay^a,
Deepak Sharma^b, Sumita Pradhan^b, Ramesh Singh Bhandari^b

^a Maharajgunj Medical Campus, Tribhuvan University Institute of Medicine, Maharajgunj, Nepal

^b Department of GI and Hepato-biliary Surgery, Tribhuvan University Teaching Hospital, Kathmandu, Nepal

ARTICLE INFO

Keywords:

Paraduodenal hernia

Malrotation

Laparotomy

Case report

ABSTRACT

Introduction: Paraduodenal hernia is a rare cause of internal hernia. It is the herniation of small bowel through a peritoneal sac in the duodenum. It occurs due to incomplete rotation and fixation abnormalities of the primitive midgut during fetal development. We report a case of right sided paraduodenal hernia in an adult male.

Case presentation: This is a case of 36-year-old gentleman who presented with complaints of abdominal fullness and upper abdominal pain for 1.5 months and 7 to 8 episodes of vomiting. CT scan of abdomen gave an impression of right-sided paraduodenal hernia. Exploratory laparotomy with hernia repair was performed and patient was discharged without complications.

Discussion: Right sided paraduodenal hernia is the protrusion of viscera through the fossa of Waldeyer. It is frequently associated with malrotation and strangulation. Its diagnosis is frequently delayed. Symptoms are non-specific and may need laparotomy for diagnosis. Technique of choice for surgical management remains inconclusive.

Conclusion: Paraduodenal hernias are frequently diagnosed late or incidentally because of vague symptoms. They are rarer and carry higher lifetime risk of strangulation and bowel obstruction. Surgical management is necessary after diagnosis.

1. Introduction

Internal hernias only accounts for 0.2%–0.9% of all intestinal obstructions(1). They constitute protrusions of abdominal viscera or part of them through congenital or acquired orifices of the peritoneum or mesentery within the peritoneal cavity [2]. Paraduodenal hernia (PDH) or mesocolic hernia is the herniation of small bowel through a peritoneal sac in the 4th part of the duodenum or the duodenal caudal segment(3). PDH occurs due to incomplete rotation and fixation abnormalities of the primitive midgut during fetal development [1,3]. It accounts for 53% of internal hernias, but only 0.2%–5.8% of intestinal obstructions, and occurs in both adults and children(1,4,5) (see Figs. 3 and 4).

This report describes exploratory laparotomy and repair of right sided PDH in an adult male. The case has been reported in line with SCARE 2020 criteria [13].

2. Case report

A 36-years-old gentleman from the western part of Nepal, presented to the out-patient department with complaints of abdominal fullness and upper abdominal pain for 1.5 months. He gave a history of 7–8 episodes of vomiting which was non-bilious and non-blood stained. There was no history of hematemesis, melena, diarrhea or constipation. There was a past history of bilateral nephrolithiasis for which he still is under medical management. There is no history of past surgical interventions and he does not have diabetes mellitus, hypertension, thyroid disorders, COPD or asthma.

On examination, he looked dehydrated but there were no other features like pallor, icterus, lymphadenopathy and edema. Per-abdominal examination revealed soft and tender abdomen, with tenderness present over epigastrium, umbilical and right paraumbilical region. Laboratory results were unremarkable.

Upper gastrointestinal endoscopy showed erosive antral gastritis but colonoscopy was normal.

* Corresponding author. harajgunj Medical Campus, Tribhuvan University Institute of Medicine, Maharajgunj, Nepal.

E-mail address: aramva.a10@iom.edu.np (A.B. Adhikari).

<https://doi.org/10.1016/j.amsu.2021.103135>

Received 2 November 2021; Received in revised form 24 November 2021; Accepted 30 November 2021

Available online 4 December 2021

2049-0801/© 2021 The Author(s). Published by Elsevier Ltd on behalf of IJS Publishing Group Ltd. This is an open access article under the CC BY-NC-ND license

(<http://creativecommons.org/licenses/by-nc-nd/4.0/>).

CT of abdomen and pelvis revealed unusual cluster of sac-like pseudo-capsulated small bowel loops (duodenum and jejunum) on the right side of abdomen (right pre-renal region) with non-crossing of duodenum towards the left side, absent retro-mesenteric third part of duodenum and duodenojejunal junction lying posterolateral to the superior mesenteric vein on right side (Fig. 1). Right colic artery and vein was found displaced and lying anterior to the cluster of small bowel loops. There was evidence of overriding of superior mesenteric vein over superior mesenteric artery. Ileocecal junction was in its normal position on the right side and features of small bowel obstruction were not seen. These findings gave an impression that there was intestinal malrotation with right paraduodenal hernia without obstructive features (see Fig. 2).

He was planned for exploratory laparotomy with hernia repair. Perioperatively, malrotation of duodenum and proximal jejunum was found. Duodenum and jejunum were found to be confined to a sac with thick band distally causing partial obstruction of the small bowel. The hernia sac was the wall of the peritoneum and the third part of duodenum was found in the right side, not crossing the midline. Hepatic flexure was dissected and colon was pulled down. Hernia sac was dissected and band adhesions were freed. Sac was incised and duodenum and jejunum were released from the sac. The sac was then resected. Appendectomy was performed. Small bowel was placed on the right and large bowel was placed on left side. Abdomen was closed in layers and dressing was applied.

The post-operative period was uneventful and our patient was discharged on 6th post-operative day with no issues. The patient's party is satisfied with the treatment they received.

3. Discussion

PDHs are congenital mesocolic hernias caused by an abnormal rotation of the primitive midgut in embryonic life(4). First described by Treitz in 1857 [14], paraduodenal hernias were categorized by Jönnesco in 1889 as either left- or right-sided based on its location in relation to

the ligament of Treitz [15]. RPH is three times less common than left paraduodenal hernias and has male preponderance of 3:1 [4,11,16]. In Right PDH, the viscus herniates into the fossa of Waldeyer, a defect formed by the failure of fusion of the mesentery behind the superior mesenteric artery and inferior to the third segment of the duodenum [17,18]. As a result, the small bowel becomes trapped in a hernial sac formed by the peritoneum. Found in 1% of the population on autopsy, right sided PDH is frequently associated with malrotation of the midgut and bowel strangulation due to the size of the hernia neck [2,19]. The risk of obstruction rises over time due to growth and extension of the sac and hence presentation is more commonly seen between 4th and 6th decades [3].

This report describes an adult male with right-sided PDH, which was successfully managed by exploratory laparotomy and repair. Since right-sided PDH is rare and is frequently accompanied by nonspecific clinical signs, it is reported that laparotomy may be necessary to confirm the precise diagnosis [6,8–10]. However, in this case, we confirmed the diagnosis preoperatively with the use of abdominal CT findings.

The symptoms and physical findings are vague and nonspecific. Patients present with a history of recurrent pain in the abdomen and ill-defined complaints, which often leads to misdiagnosis [8,9]; history of partial or complete intestinal obstruction might also be present [5–7, 11]. Plain abdominal radiographs and ultrasonography are also frequently nondiagnostic. However, Kummer in 1921 provided a unique characteristic under radiography, which can help in formulating a definitive diagnosis which remains true to this day(11,20). It is the “total absence of small intestine in the true pelvis in the upright position; the small bowel is confined in a smooth, sharply circumscribed mass”—the ‘classical empty abdominal sign’ [20]. With the advent and widespread availability of advanced technologies, abdominal CT can be very helpful for the diagnosis of PDH [2,6].

The treatment approach for PDH is based on the principle of hernia reduction plus either repair of the defect or widening of the hernial orifice [11,12]. Since its nonspecific symptoms delay diagnosis, there is

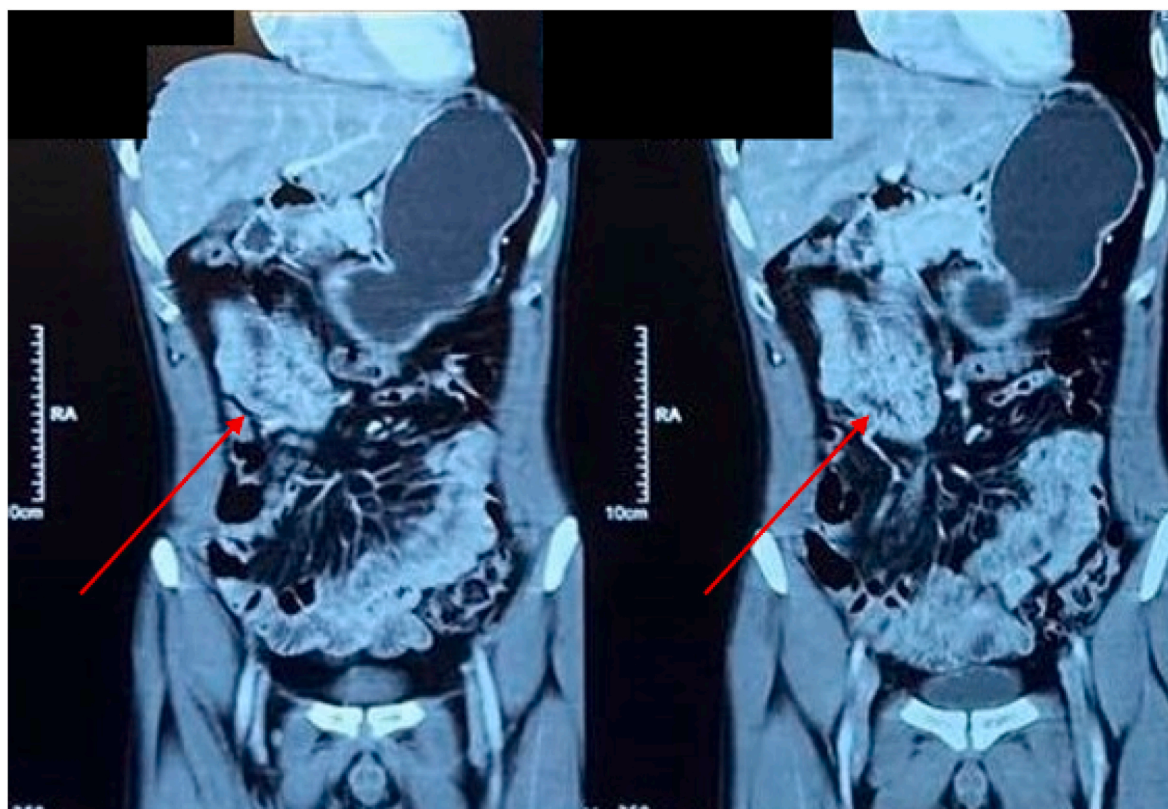


Fig. 1. Coronal view of CECT Abdomen showing cluster of small bowel loops in the right side of abdomen.

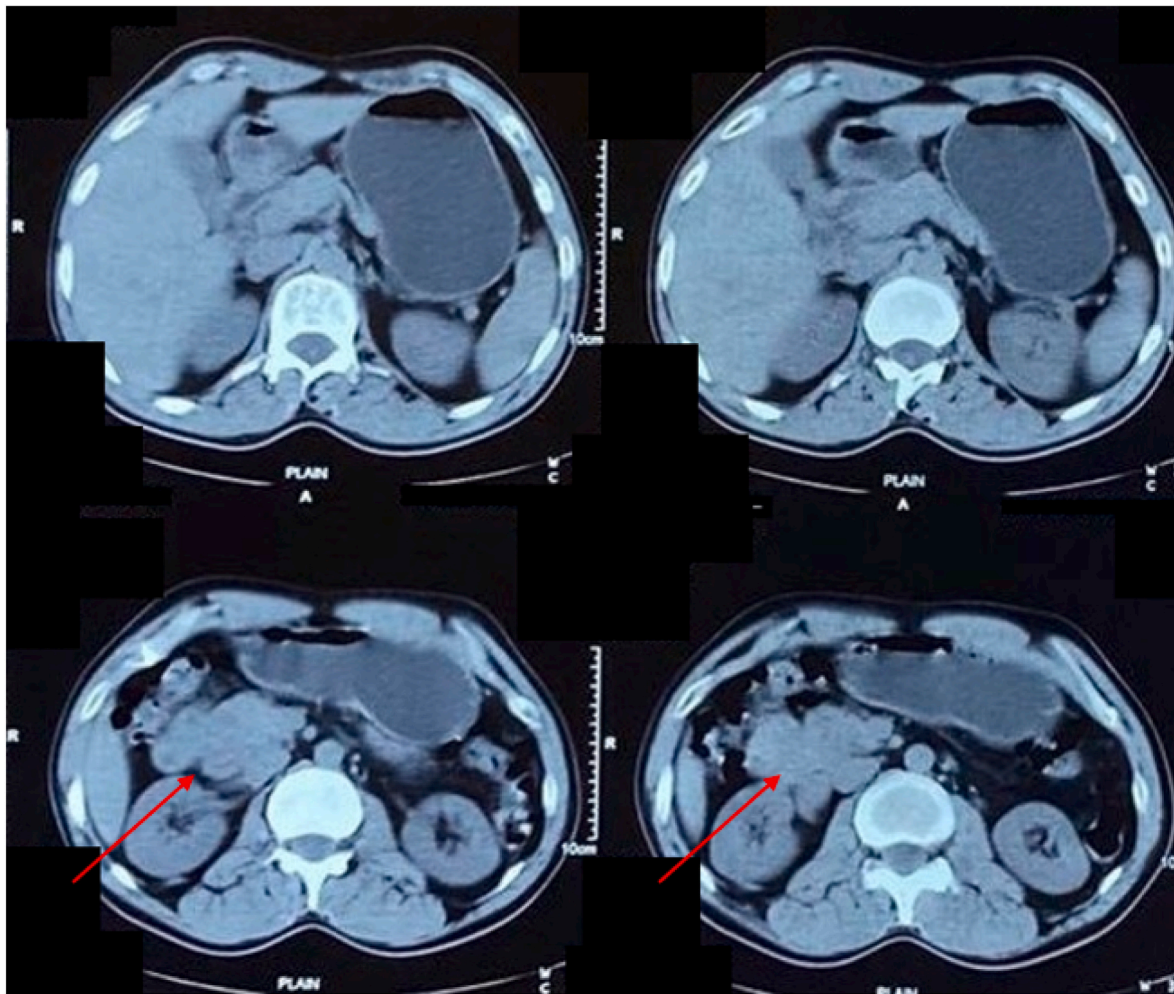


Fig. 2. Axial view of CECT abdomen showing cluster of small bowel loops in the right side of abdomen.

the risk of strangulation and bowel necrosis [4]. Although both open and laparoscopic approaches for surgical management of PDH are popular, the most efficient choice of technique still remains inconclusive due to sparsity of available literature [2,11].

4. Conclusion

Paraduodenal hernias are rare causes of intestinal obstruction. Because of vague symptoms, they are frequently diagnosed late or incidentally. Since right sided paraduodenal hernias are rarer and carry higher lifetime risk of strangulation and bowel obstruction, surgical management is necessary once diagnosis is made.

Patient consent

Written informed consent was obtained from the patient for publication of this case report and accompanying images. A copy of the written consent is available for review by the Editor-in-Chief of this journal on request.

Provenance and peer review

Not commissioned, externally peer-reviewed.

Please state any conflicts of interest

There are no conflicts of interest.

Please state any sources of funding for your research

There are no sources of funding.

Ethical approval

Case reports are exempt from ethical approval in our institution, Tribhuvan University Institute of Medicine, Maharajgunj.

Consent

Written informed consent was obtained from the patient for publication of this case report and accompanying images. A copy of the written consent is available for review by the Editor-in-Chief of this journal on request.

Author contributions

All the authors contributed equally for the preparation of this case report.

Ramesh Singh Bhandari (RSB), Sumita Pradhan (SP), Deepak Sharma (DS) = study concept and surgical therapy for the patient.

Navin Poudel (NP), Aramva Bikram Adhikari (ABA), Kshitiz Acharya (KA), Devansh Upadhyaya (DU) = Data collection, obtaining consent from patient's party, review of previous literatures, editing and writing of the manuscript.

RSB and SP = Senior author and manuscript reviewer.

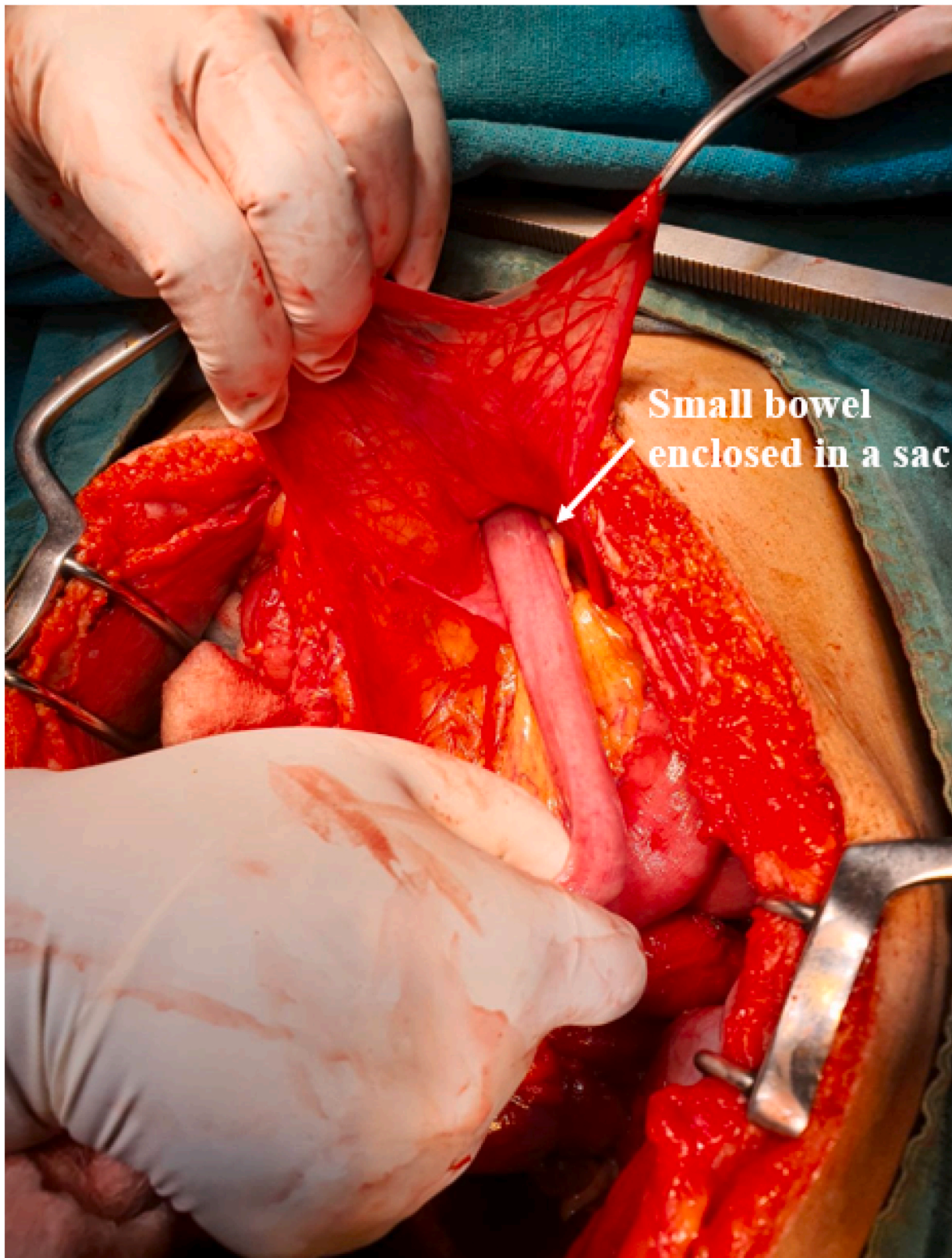


Fig. 3. Per-operative view showing herniation of small bowel into the Waldeyer's fossa.

All the authors individually did the final proof-reading of the manuscript before submission.

7. Registration of research studies

1. Name of the registry:
2. Unique Identifying number or registration ID:

3. Hyperlink to your specific registration (must be publicly accessible and will be checked):

Guarantor

Navin Poudel, Maharagunj Medical Campus, Tribhuvan University Institute of Medicine, Maharajgunj, Kathmandu, Nepal, Email: navin

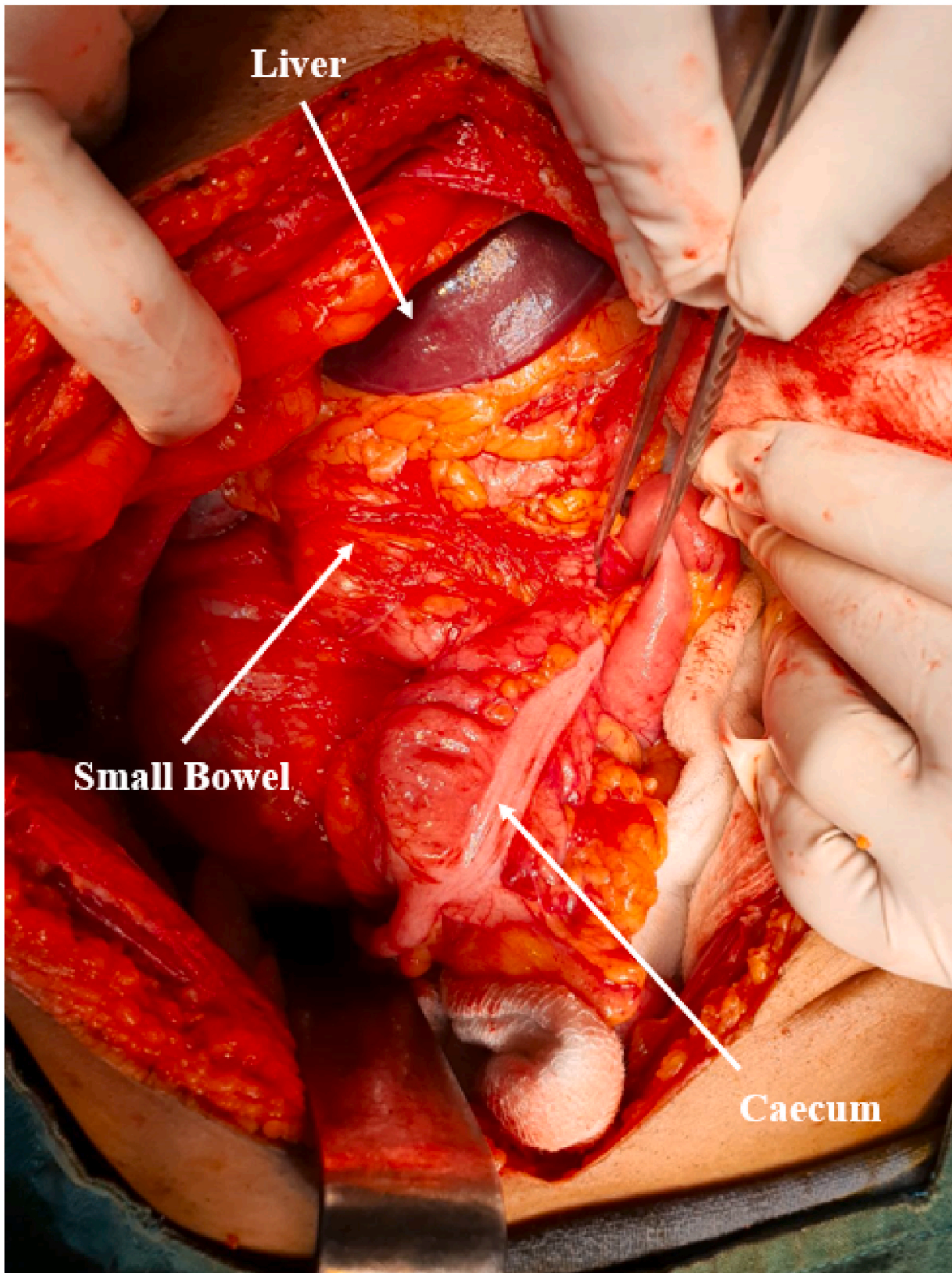


Fig. 4. Per-operative view of small bowel enclosed in a sac.

poudel77@iom.edu.np Phone number: +977-9847411763.

Acknowledgements

Declaration of competing interest

None.

None.

References

- [1] M.A. Khan, A.Y. Lo, D.M. Vande Maele, Paraduodenal hernia, *Am. Surg.* 64 (12) (1998 Dec) 1218–1222. PMID: 9843350.
- [2] D. Schizas, K. Apostolou, S. Krivan, P. Kanavidis, I. Katsaros, M. Vailas, et al., Paraduodenal hernias: a systematic review of the literature, *Hernia* 23 (6) (2019 Dec 1) 1187–1197.
- [3] S. Manfredelli, Z. Andrea, P. Stefano, L. Giovanni, M. Maria, F. Angelo, et al., Rare small bowel obstruction: right paraduodenal hernia. Case report, *Int. J. Surg. Case Rep.* 4 (4) (2013 Jan 1) 412–415.
- [4] T. Tomino, S. Itoh, D. Yoshida, T. Nishida, H. Kawanaka, T. Ikeda, et al., Right paraduodenal hernia successfully treated with laparoscopic surgery [cited 2021 Aug 30], *Asian J. Endosc. Surg.* [Internet] 8 (1) (2015 Feb 1) 87–90. Available from: <https://onlinelibrary.wiley.com/doi/full/10.1111/ases.12139>.
- [5] H.Y. Yoo, J. Mergelas, D.G. Seibert, Paraduodenal hernia: a treatable cause of upper gastrointestinal tract symptoms, *J. Clin. Gastroenterol.* 31 (3) (2000 Oct) 226–229, <https://doi.org/10.1097/00004836-200010000-00008>. PMID: 11034002.
- [6] T. Takagishi, Y. Niimi, G. Matsuki, S. Nagano, J. Hinami, M. Kajiwara, et al., Laparoscopic repair of right paraduodenal hernia in adult patients: case report and literature review, *Case Rep. Surg.* (2018) 1–5, 2018 Oct 15.
- [7] D.W. Dietz, R.M. Walsh, S. Grundfest-Broniatowski, I.C. Lavery, V.W. Fazio, D. P. Vogt, Intestinal malrotation: a rare but important cause of bowel obstruction in adults [cited 2021 Aug 30], *Dis. Colon. Rectum.* [Internet] 45 (10) (2002 Oct 1) 1381–1386. Available from: https://journals.lww.com/dcrjournal/Fulltext/2002/45100/Intestinal_Malrotation_A_Rare_but_Important_Cause.15.aspx.
- [8] T. Shinohara, K. Okugawa, C. Furuta, Volvulus of the small intestine caused by right paraduodenal hernia: a case report, *J. Pediatr. Surg.* 39 (2) (2004 Feb) e8–9, <https://doi.org/10.1016/j.jpedsurg.2003.10.029>. PMID: 14966765.
- [9] J.M. Moran, J. Salas, S. Sanjuán, J.L. Amaya, P. Rincón, A. Serrano, E.M. Tallo, Paramesocolic hernias: consequences of delayed diagnosis. Report of three new cases, *J. Pediatr. Surg.* 39 (1) (2004 Jan) 112–116, <https://doi.org/10.1016/j.jpedsurg.2003.09.027>. PMID: 14694386.
- [10] E. Erdas, A. Pitzalis, D. Scano, S. Licheri, M. Pomata, G. Farina, Diagnosis and treatment of symptomatic right paraduodenal hernia: report of a case, 441 [Internet]. 2013 Jan 18 [cited 2021 Aug 30], *Surg. Today* 44 (1) (2013) 192–196. Available from, <https://link.springer.com/article/10.1007/s00595-012-0483-3>.
- [11] Gastroenterol Rep [Internet] R. Mehra, A.K. Pujahari [cited 2021 Aug 30], Right paraduodenal hernia: report of two cases and review of literature 4 (2) (2016 May 1) 168–171. Available from: <https://academic.oup.com/gastro/article/4/2/168/1749388>.
- [12] R.A. Brigham, d'Avis J.C. Paraduodenal hernia, in: L.M. Nyhus, R.E. Condon (Eds.), *Hernia*, third ed., Lippincott, Philadelphia, 1989, pp. 481–486.
- [13] R.A. Agha, T. Franchi, C. Sohrabi, G. Mathew, A. Kerwan, A. Thoma, et al., The SCARE 2020 guideline: updating consensus surgical CAse REport (SCARE) guidelines, *Int. J. Surg.* 84 (2020 Dec 1) 226–230.
- [14] W. Treitz, *Hernia retroperitonealis: ein Beitrag zur Geschichte innerer Hernien, Mit Abbildungen* [Internet]. 1857 [cited 2021 Aug 30], <https://books.google.com/books?hl=en&lr=&id=jCBpAAAACAAJ&oi=fnd&pg=PA1&ots=jqdh4Gjs31&sig=8mmaA4gd41AVIgdunnpdAGgGjk>. Available from.
- [15] T. Jonnesco, *Anatomie topographique du duodenum et hernies duodenaes* [Internet]. 1889 [cited 2021 Aug 30], <https://books.google.com/books?hl=en&lr=&id=oMM0AQAAAMAAJ&oi=fnd&pg=PA1&ots=SIVwKMGi8o&sig=xJFZ45RW1u0L3P0I8uE2xtC6JK0>. Available from.
- [16] A.U. Desjardins, Left paraduodenal hernia, *Ann. Surg.* 67 (2) (1918 Feb) 195–201, <https://doi.org/10.1097/00000658-191802000-00011>. PMID: 17863859; PMCID: PMC1426661.
- [17] S. Singh, A. Das, A.S. Chawla, S.V. Arya, J. Chaggar, A rare presentation of midgut malrotation as an acute intestinal obstruction in an adult: two case reports and literature review [cited 2021 Aug 30], *Int. J. Surg. Case Rep.* [Internet] 4 (1) (2013) 72. Available from /pmc/articles/PMC3537961/.
- [18] Case Reports [Internet] M. Ong, M. Roberts, M. Perera, C. Pretorius, Case of a Strangulated Right Paraduodenal Fossa Hernia in a Malrotated Gut [cited 2021 Aug 30]; 2017:bcr-2017-220645, 2017 Jul 24. Available from: <https://casereports.bmj.com/content/2017/bcr-2017-220645>.
- [19] Pan Afr Med J [Internet] K.I.M. Hassani, Y. Aggouri, S.A. laalim, I. Toughrai, K. Mazaz, Left Paraduodenal Hernia: A Rare Cause of Acute Abdomen, 2014 [cited 2021 Aug 31]; 17:1937–8688 Available from: /pmc/articles/PMC4145264/.
- [20] E. Kummer, Signes radiologiques de la hernie duodenojejunale, *J. Radiol. Electro.* 5 (1921) 362–367.