

# Purple Urine Bag Syndrome in an 80-year-old Female Cameroonian

Valirie Ndip Agbor<sup>1</sup>, Tsi Njim<sup>2</sup>, Helen Bessem Oben<sup>3</sup>, Leopold Ndemnge Aminde<sup>4,5</sup>

<sup>1</sup>Ibal Health Centre, Oku, North west region, Cameroon, <sup>2</sup>Centre for Global Health and Tropical Medicine, Nuffield Department of Medicine, University of Oxford, Oxfordshire, United Kingdom, <sup>3</sup>Faculty of Medicine and Biomedical Sciences, University of Yaounde I, Yaounde, <sup>4</sup>Clinical Research Education, Networking and Consultancy, Douala, Littoral, Cameroon, <sup>5</sup>School of Public Health, Faculty of Medicine and Biomedical Sciences, University of Queensland, Brisbane, Australia

## Abstract

Purple urine bag syndrome is a rare clinical entity commonly seen in elderly females with a long-term urinary catheterization. It presents as purple discoloration of the patient's plastic urine bag and tubing. We report the first case of this rare entity from Central Africa. We present the case of an 80-year-old female with purple urine associated with signs of urinary tract infection. Her symptoms resolved after 3 days of intravenous antibiotic treatment and diet modification. Purple urine bag syndrome remains rare, especially in African literature. Awareness of this benign syndrome is necessary for clinicians so as to adequately manage up to and including the associated anxiety.

**Keywords:** Cameroon, chronic indwelling catheter, purple urine bag syndrome

## INTRODUCTION

Purple urine bag syndrome (PUBS) is a rare clinical entity secondary to a urinary tract infection (UTI), marked by a purple discoloration of the plastic urine bag and tubing when in contact with the patient's urine.<sup>1</sup> This can be disturbing for the patient, caregiver, and even the inexperienced primary health-care provider. It is frequently associated with recurrent UTI on long-term indwelling urinary catheters and has a benign prognosis if adequately managed. PUBS remains rare in the African literature. A MEDLINE and Google Scholar search revealed just a single-case report of PUBS by Adam from South Africa, Africa.<sup>2</sup>

We report, to the best of our knowledge, the first case of this phenomenon from Central Africa.

## CASE REPORT

An 80-year-old female Cameroonian, known hypertensive on aspirin, amlodipine, and lisinopril hospitalized 3 months previously for an ischemic stroke, was brought to our unit 10 weeks after her prior discharge with a history of a purple discoloration of her urine bag, abdominal pain, and fever for 24 h. She had missed her followed up visit for the replacement of her urinary catheter 9 weeks earlier due to financial constraints.

She was also bedridden, developed urinary incontinence, and chronic constipation as sequelae of the stroke. On examination, she had a blood pressure of 143/86 mmHg, a pulse rate of 90 beats/min, a maximum temperature of 38.6°C, and suprapubic tenderness. The plastic urine bag and tube were seen with a purple discoloration [Figure 1] even though her urine had an amber yellow. The rest of the examination was unremarkable.

A full blood count done revealed a leukocytosis at 16,000 cells/mm<sup>3</sup> with a neutrophilic predominance at 10,500 cells/mm<sup>3</sup>. Her urinalysis was positive for leukocyte esterase and nitrites, with a pH of 8.2, and a specific gravity of 1.010. Urine culture was positive for *Escherichia coli*. Her serum electrolytes (Na<sup>+</sup>/K<sup>+</sup>/Cl<sup>-</sup>), urea, and creatinine were all within normal ranges.

The indwelling catheter was changed and she was placed on laxatives, diet and hygiene modification (washing of hands before and after touching the catheter; washing the skin around catheter with soap and water daily, and after each bowel

**Address for correspondence:** Dr. Valirie Ndip Agbor,  
Ibal Health Centre, Oku, Northwest Region, Cameroon.  
E-mail: nvagbor@gmail.com

### Access this article online

Quick Response Code:



Website:  
www.nigeriamedj.com

DOI:  
10.4103/nmj.NMJ\_173\_16

This is an open access journal, and articles are distributed under the terms of the Creative Commons Attribution-NonCommercial-ShareAlike 4.0 License, which allows others to remix, tweak, and build upon the work non-commercially, as long as appropriate credit is given and the new creations are licensed under the identical terms.

**For reprints contact:** reprints@medknow.com

**How to cite this article:** Agbor VN, Njim T, Oben HB, Aminde LN. Purple urine bag syndrome in an 80-year-old female Cameroonian. Niger Med J 2017;58:119-21.

movement), and intravenous amoxicillin-clavulanate 1 g every 8 h. On the third day of admission, symptoms resolved and she was discharged 2 days later on the same antibiotics (per os) to complete a 10-day course of treatment. She returned for a follow-up visit a week later, then every 2 weeks for 6 weeks with no resurgence of symptoms.

## DISCUSSION

PUBS is a rare phenomenon first described in 1978 by Barlow.<sup>3</sup> Even though it can be alarming for the patients, caregiver, and inexperienced primary health-care provider, it is mostly a benign condition. Even though PUBS is a rare pathology, recent studies have shown a higher prevalence of 8.3%–16.7% in chronically catheterized patients and 27% in elderly patients with dementia in a geriatric home requiring catheterization.<sup>4</sup>

PUBS has been associated with the following risk factors; being elderly, female gender, bedridden states, constipation, chronic urinary catheterization, alkaline urine, UTI, and kidney failure.<sup>5,6</sup> The following bacteria have commonly been isolated in the urine of patients with PUBS; *Pseudomonas aeruginosa*, *Proteus mirabilis*, *Providencia* species, *E. coli*, *Klebsiella pneumoniae*, *Morganella morganii*, *Citrobacter* species, Methicillin-resistant *Staphylococcus aureus*, Group B streptococci, and *Enterococcus* species.<sup>4,6,7</sup>

Our patient had risk factors consistent with the aforementioned predisposing her to this rare syndrome such as her age (80 years), sex (female gender), bedridden state, alkaline urine, chronic catheterization, constipation, and a UTI (due to *E. coli* infection). Furthermore, the poor hygienic care afforded to our patient coupled with her poor economic status which allowed her to carry the same catheter for 10 weeks greatly contributed to the development of this rare entity.

The pathogenesis of PUBS involves deamination of dietary tryptophan to indole by bacteria in the gut, which is usually favored by constipation. Indole is then conjugated in the liver to indoxyl sulfate (indican), which is then excreted in urine. An underlying renal failure will impair the clearance of indican, hence favoring the development of PUBS.<sup>2,5</sup> Indican is then oxidized by sulfatase/phosphatase-containing

bacteria colonizing the urinary catheter system to the pigment indigo (blue) and indirubin (red) [Figure 2].<sup>8</sup> Oxidation of indican is facilitated by an alkaline urine. When these pigments get in contact with a plastic urine bag or tubing, it produces a purple discoloration of the urine bag.<sup>2,5</sup>

Even though alkaline urine has been reported by a majority of authors to be a risk factor for the development of PUBS,<sup>1,2,6-8</sup> it has also been described in patients with acidic urine.<sup>9,10</sup>

Although most of the reported cases of PUBS are benign,<sup>5,6,11</sup> some reports have associated PUBS to severe complications such as severe sepsis requiring aggressive treatment in the intensive care unit<sup>8</sup> and Fournier’s gangrene in an immunocompromised patient.<sup>12</sup> Since urine discoloration is not a sign of UTI, PUBS is therefore classified as asymptomatic bacteriuria.<sup>13</sup>

The treatment generally involves controlling underlying risk factors, avoiding chronic catheterization, and proper urologic sanitation in patients with PUBS. Antibiotic treatment is only recommended for patients with symptomatic UTI.<sup>11</sup>

Her urine culture revealed the presence of *E. coli* which responded well to antibiotics. Diet modification (limiting consumption of foods rich in tryptophan), proper hygiene, and psychological support were instrumental in the management.

## CONCLUSION

PUBS is a rare condition, especially to the African literature associated with significant anxiety for both patients and caregivers. It is benign and resolves with appropriate management. Awareness of this syndrome among health-care providers in Africa is important so as to adequately manage the condition, while providing psychosocial support.

## Declaration of patient consent

The authors certify that they have obtained all appropriate patient consent forms. In the form the patient has/have given his/her/their consent for his/her/their images and other clinical information to be reported in the journal. The patient understand that their names and initials will not be published and due efforts will be made to conceal their identity, but anonymity cannot be guaranteed.



Figure 1: Purple discoloration of plastic urine bag and tube

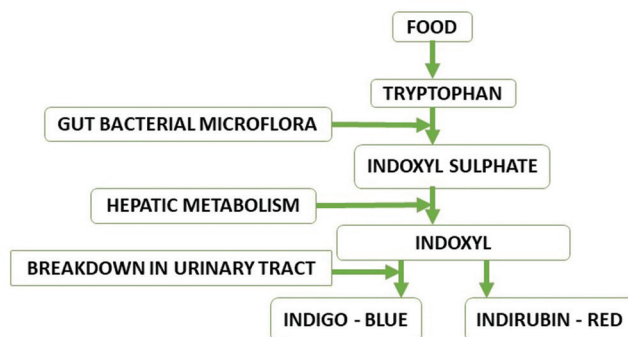


Figure 2: Pathogenesis of purple urine bag syndrome

## Financial support and sponsorship

Nil.

## Conflicts of interest

There are no conflicts of interest.

## REFERENCES

1. Al Montasir A, Al Mustaque A. Purple urine bag syndrome. *J Family Med Prim Care* 2013;2:104-5.
2. Adam A. The “purple urine bag syndrome”: Where indigo and indirubin meet! *Afr J Urol* 2015;21:155-6.
3. Barlow GB, Dickson JA. Purple urine bags. *Lancet* 1978;311:220-1.
4. Su FH, Chung SY, Chen MH, Sheng ML, Chen CH, Chen YJ, *et al.* Case analysis of purple urine-bag syndrome at a long-term care service in a community hospital. *Chang Gung Med J* 2005;28:636-42.
5. Khan F, Chaudhry MA, Qureshi N, Cowley B. Purple urine bag syndrome: An alarming hue? A brief review of the literature. *Int J Nephrol* 2011;2011:419213.
6. Agapakis D, Massa E, Hantzis I, Paschoni E, Satsoglou E. Purple urine bag syndrome: A case report of an alarming phenomenon. *Hippokratia* 2014;18:92-4.
7. Tul Llah S, Khan S, Dave A, Morrison AJ, Jain S, Hermanns D. A case of purple urine bag syndrome in a spastic partial quadriplegic male. *Cureus* 2016;8:e552.
8. Lin J, Hlafka M, Vargas O, Bhattarai M. Recurrent purple urine bag syndrome presenting with full spectrum of disease severity: Case report and review of literature. *CEN Case Rep* 2016;5:144-7.
9. Chung SD, Liao CH, Sun HD. Purple urine bag syndrome with acidic urine. *Int J Infect Dis* 2008;12:526-7.
10. Mantani N, Ochiai H, Imanishi N, Kogure T, Terasawa K, Tamura J. A case-control study of purple urine bag syndrome in geriatric wards. *J Infect Chemother* 2003;9:53-7.
11. Van Keer J, Detroyer D, Bammens B. Purple urine bag syndrome in two elderly men with urinary tract infection. *Case Rep Nephrol* 2015;2015:746981.
12. Lin CH, Huang HT, Chien CC, Tzeng DS, Lung FW. Purple urine bag syndrome in nursing homes: Ten elderly case reports and a literature review. *Clin Interv Aging* 2008;3:729-34.
13. Ga H, Kojima T. Purple urine bag syndrome. *JAMA* 2012;307:1912-3.