

Echocardiographic assessment of right ventricular functions in healthy subjects who migrated from the sea level to a moderate altitude

Arif Arısoy, Selim Topçu¹, Selami Demirelli², Fatih Altunkaş, Metin Karayakalı, Ataç Çelik, İbrahim Halil Tanboğa¹, Enbiya Aksakal¹, Serdar Sevimli¹, Hanefi Yekta Gürlertop³

Department of Cardiology, Faculty of Medicine, Gaziosmanpaşa University; Tokat-Turkey

¹Department of Cardiology, Faculty of Medicine, Atatürk University; Erzurum-Turkey

²Department of Cardiology, Erzurum Regional Training and Research Hospital; Erzurum-Turkey

³Department of Cardiology, Faculty of Medicine, Trakya University; Edirne-Turkey

ABSTRACT

Objective: The aim of this study was to evaluate right ventricle (RV) functions using echocardiography in healthy subjects who migrated from the sea level to moderate altitude (1890 m).

Methods: The prospective observational in this study population consisted of 33 healthy subjects (23 men; mean age 20.4±3.2 years) who migrated from the sea level to a moderate altitude (Erzurum city centre, 1890 m above sea level) for long-term stay. Subjects underwent echocardiographic evaluation within the first 48 h of exposure to the moderate altitude and at the sixth month of arrival. Conventional echocardiographic parameters such as RV sizes and areas, systolic, and diastolic functional indices [fractional area change (FAC), tricuspid flow velocities, myocardial performance index (MPI), and tricuspid annular plane systolic excursion (TAPSE)] were obtained. Systolic (S) and diastolic (E', A') velocities were acquired from the apical four-chamber view using tissue Doppler imaging. Kolmogorov–Smirnov test, student's t-test, Wilcoxon test, and chi-square test were used in this study.

Results: There were no significant changes in RV size, FAC, MPI, TAPSE, inferior inspiratory vena cava collapse, tricuspid E velocity, and tricuspid annulus E' velocity. Compared with the baseline, there was a significant increase in mean pulmonary artery pressure (p=0.001); RV end systolic area (p=0.014); right atrial end diastolic area (p=0.021); tricuspid A velocity (p=0.013); tricuspid annulus S and A' velocity (p=0.031 and p=0.006, respectively); and RV free wall S, E', and A' velocity (p=0.007, p<0.001, and p=0.007 respectively) at the sixth month. Also, there was a significant decrease in tricuspid E/A ratio (1.61±0.3 vs. 1.45±0.2, p=0.038) and tricuspid annulus E'/A' ratio (1.52±0.5 vs. 1.23±0.4, p=0.002) at the sixth month.

Conclusion: Our study revealed that right ventricular diastolic function was altered while the systolic function was preserved in healthy subjects who migrated from the sea level to a moderate altitude. (*Anatol J Cardiol* 2016; 16: 779-83)

Keywords: tissue Doppler, right ventricle, high altitude

Introduction

Altitude exposure is associated with major changes in cardiovascular function. Cardiopulmonary effects become more pronounced with increasing altitude. Oxygen content and partial oxygen pressure drops at high-altitude environments. Hypoxemia leads to an increase in myocardial workload and pulmonary vascular resistance (1). Increased pulmonary vascular resistance results in structural and functional changes in the pulmonary arterial system and right ventricle (RV) (2, 3). Massive hypertrophy and dilatation in RV, dilation in pulmonary vessels, medial hypertrophy in pulmonary arteries, and development of new muscles in pulmonary arterioles have been observed in these individuals (4-6). Although there is no certain level of altitude to initiate the effects on the cardiovascular

system, significant changes occur above 2500 m (7). To date, related studies have generally involved altitudes above 2500 m (high altitude), and there is an insufficient number of studies on the effects of moderate altitude (1500–2500 m) on the cardiovascular system.

In this study, we evaluated RV functions with conventional and tissue Doppler echocardiography in healthy individuals who migrated to a moderate altitude settlement from the sea level.

Methods

Study design and study power

This study was designed as a prospective observational study. Power analysis values for our study variables were calculated between 81% and 99%.

Address for correspondence: Dr. Arif Arısoy, Gaziosmanpaşa Üniversitesi Tıp Fakültesi, Kardiyoloji ABD, Tokat-Türkiye

Phone: +90 356 252 16 16 / 1025 Fax: +90 356 252 16 25 E-mail: arfarsy@hotmail.com

Accepted Date: 14.09.2015 **Available Online Date:** 25.11.2015

©Copyright 2016 by Turkish Society of Cardiology - Available online at www.anatoljcardiol.com
DOI:10.5152/AnatolJCardiol.2015.6622



Study population and study protocol

The study population consisted of 33 healthy subjects (10 women and 23 men; mean age 20.4 ± 3.2 years) who migrated from the sea level to a moderate altitude (Erzurum city centre, 1890 m above sea level) for long-term stay. Subjects underwent echocardiographic evaluation within the first 48 h of exposure to the moderate altitude and at the sixth month of arrival. Smokers and individuals with any kind of systemic disease were excluded from the study. The study was approved by the local Ethics Board. Informed consent was obtained from all participants.

Echocardiography

All patients were examined in a semisupine, left lateral position by the same observer. Echocardiographic imaging was performed using Vivid-S5 devices (General Electric, Vingmed, Norway) equipped with 3-MHz transducers, with continuous electrocardiographic monitoring. M-mode and two-dimensional images, color, pulsed, and continuous wave Doppler measurements were acquired from all subjects compatible with standard echocardiographic application methods. Pulsed wave tissue Doppler image (TDI) was obtained by activating the device's tissue Doppler imaging function with gains adjusted to eliminate transvalvular flow velocities and minimize noise. In the apical 4-chamber view, a 5–10 mm sample volume was placed at the lateral side of the tricuspid annulus and RV free wall. Measurements were recorded during the end-expiratory apnea to minimize the respiratory effect.

Inferior vena cava (IVC) diameter and collapse and E/E' ratio were measured to evaluate preload; the mean pulmonary arterial pressure was measured to evaluate afterload; FAC, S' velocity, TAPSE, and TDI-derived myocardial performance index (MPI) were measured to evaluate systolic functions; and tricuspid E and A wave velocity, E/A ratio, E' velocity, and E'/A' ratio were measured to evaluate the diastolic function of RV.

TAPSE was calculated by placing an M-mode cursor through the tricuspid annulus and measuring the amount of longitudinal motion of the annulus at peak systole. Because of inadequate tricuspid regurgitation (TR) or absence of Doppler-detected TR, the mean pulmonary artery pressure (mPAP) was calculated using pulmonary acceleration time (AT) measured by pulsed Doppler of the pulmonary artery in systole, whereby $mPAP = 79 - (0.45 \times AT)$. The formula $90 - (0.62 \times AT)$ was used in patients with ATs <120 ms (8, 9).

On the TDI images, the annular peak systolic velocity (S), early (E') and late (A') peak annular diastolic velocities, ejection time (ET), isovolumetric relaxation time (IVRT, time between the end of ET and the beginning of E'), and isovolumetric contraction time (IVCT, time between the end of A' and the beginning of ET) were measured. The final values of all parameters were recorded as the average of measurements of three cardiac cycles. The TDI-derived MPI, as a global estimate of both systolic and diastolic functions of the RV, was calculated as the sum of IVCT and IVRT divided by the ET ($TDI-MPI = (IVRT + IVCT) / ET$) (10).

Intra-observer variability was assessed in 20 patients by repeating the measurements on two occasions under the same basal conditions.

Statistical analyses

Continuous variables were tested for normal distribution by the Kolmogorov–Smirnov test. We reported continuous data as mean and standard deviation and compared by t-test if compatible with normal distribution and compared by Wilcoxon test if not compatible with normal distribution. Categorical variables were summarized as percentages and compared using the chi-square test. A two-sided p value <0.05 was considered as statistically significant.

Results

A total of 33 individuals consisting of 10 women and 23 men were enrolled in the study. The mean age of the subjects was 20.4 ± 3.2 years, mean height of subjects was 173.2 ± 8.5 cm, mean body weight was 68.3 ± 13.0 kg, and mean body mass index (BMI) was 22.7 ± 3.1 kg/m². There was no statistically significant difference between the initial and sixth month measurements for systolic blood pressure (SBP), diastolic blood pressure (DBP), pulse rate, and arterial oxygen saturation ($p=0.160$, $p=0.705$, $p=0.868$, and $p=0.240$, respectively). Demographical and clinical properties of the individuals enrolled in the study are shown in Table 1.

In the echocardiographic evaluation of the left ventricle (LV), there were no changes in diastolic and systolic diameters, interventricular septum and posterior wall thicknesses, ejection fraction, fractional shortening, and LV MPI measurements ($p=0.123$, $p=0.565$, $p=0.844$, $p=0.145$, $p=0.658$, $p=0.758$, and $p=0.604$, respectively). Additionally, although there were no changes in mitral inflow E wave velocity, deceleration time, and IVRT and IVCT values, there was a significant increase in mitral inflow A wave velocity (53.9 ± 12.6 cm/s vs. 61.0 ± 12.6 cm/s, $p=0.006$), and there was a significant decrease in the E/A ratio (1.64 ± 0.3 vs. 1.51 ± 0.2 ,

Table 1. Baseline characteristics of the participants

Variable	Initial (n=33)	6 th month (n=33)	P
Age, years	20.4 ± 3.2	–	
Sex, F/M	10/23	–	
Height, cm	173.2 ± 8.5	–	
Weight, kg	68.3 ± 13.0	–	
Body mass index, kg/m ²	22.7 ± 3.1	–	
Systolic blood pressure, mm Hg	111 ± 15.9	113.2 ± 14.4	0.160
Diastolic blood pressure, mm Hg	69.0 ± 8.7	72.5 ± 9.2	0.705
Heart rate, bpm	77.2 ± 12.7	74.7 ± 11.6	0.868
Oxygen saturation, %	95.5 ± 1.5	95.8 ± 1.8	0.240
Student's t-test was used			

p=0.018). The echocardiographic measurements of LV are presented in Table 2.

With respect to the RV diameter and area measurements, although there were no changes in RV end-diastolic diameter and RV end-diastolic area, there were statistically significant increases in RV end-systolic area and right atrium (RA) end-diastolic area (9.7±2.9 cm² vs. 10.5±2.9 cm², p=0.014; 11.5±2.3 cm² vs. 12.9±3.2 cm², p=0.02, respectively). There were no changes in inspiratory inferior vena cava collapse and tricuspid E/E' ratio, whereas there was an increase in mPaP (13.9±5.7 mm Hg vs. 17.6±4.4 mm Hg, p=0.001) (Fig. 1). For RV systolic functions, there were no changes in TAPSE (23.5±2.95 mm vs. 23.5±3.6 mm, p=0.664), RV MPI (0.34±0.18 vs. 0.28±0.07, p=0.135), and RV FAC (36.6±10.6 % vs. 35.4±9.3%, p=0.519). However, there were significant increases in tissue Doppler S wave velocity measured from the tricuspid annulus and RV free wall (14.1±2.9 cm/s vs. 15.4±2.3 cm/s, p=0.031 and 10.5±3.2 cm/s vs. 12.7±2.2 cm/s, p=0.007, respectively). With respect to RV diastolic functions, there were no changes in tricuspid inflow E wave velocity and deceleration time, whereas there was an increase in A wave velocity (42.3±11.2 cm/s vs. 48.8±12.5 cm/s, p=0.013) and a decrease in E/A ratio (1.61±0.3 vs. 1.45±0.2, p=0.038). Similarly, in tissue Doppler measurements, although there were no changes in tricuspid annular E' wave velocity, there was an increase in A' wave velocity (10.0±3.8 cm/s vs. 12.1±3.0 cm/s, p=0.006) and a decrease in E'/A' ratio (1.52±0.5 vs. 1.23±0.34, p=0.002) (Fig. 1). For measurements on

Table 2. Echocardiographic variables for left ventricular morphology and function of the study group

Variable	Initial (n=33)	6 th month (n=33)	P
Left ventricular diastolic dimension, mm	44.6±4.0	45.2±4.3	0.123
Left ventricular systolic dimension, mm	28.6±3.5	29.1±3.6	0.565
Interventricular septum thickness, mm	9.3±1.5	9.3±1.4	0.844
Posterior wall thickness, mm	8.8±1.8	8.3±1.4	0.145
Left ventricular ejection fraction, %	63.6±11.5	65.2±5.3	0.658
Left ventricular fractional shortening, %	36.1±4.4	35.7±4.0	0.758
Left ventricular myocardial performance index	0.48±0.17	0.51±0.1	0.604
Isovolumetric relaxation time, ms	70.9±14.9	71.9±12.5	0.520
Isovolumetric contraction time, ms	78.8±17.0	74.3±14.0	0.290
Mitral E wave, cm/s	86.7±19.2	92.5±20.9	0.224
Mitral A wave, cm/s	53.9±12.6	61.0±12.6	0.006
Mitral E/A	1.64±0.3	1.51±0.2	0.018
Mitral deceleration time, ms	221±49	215±43	0.624

Student's t-test was used

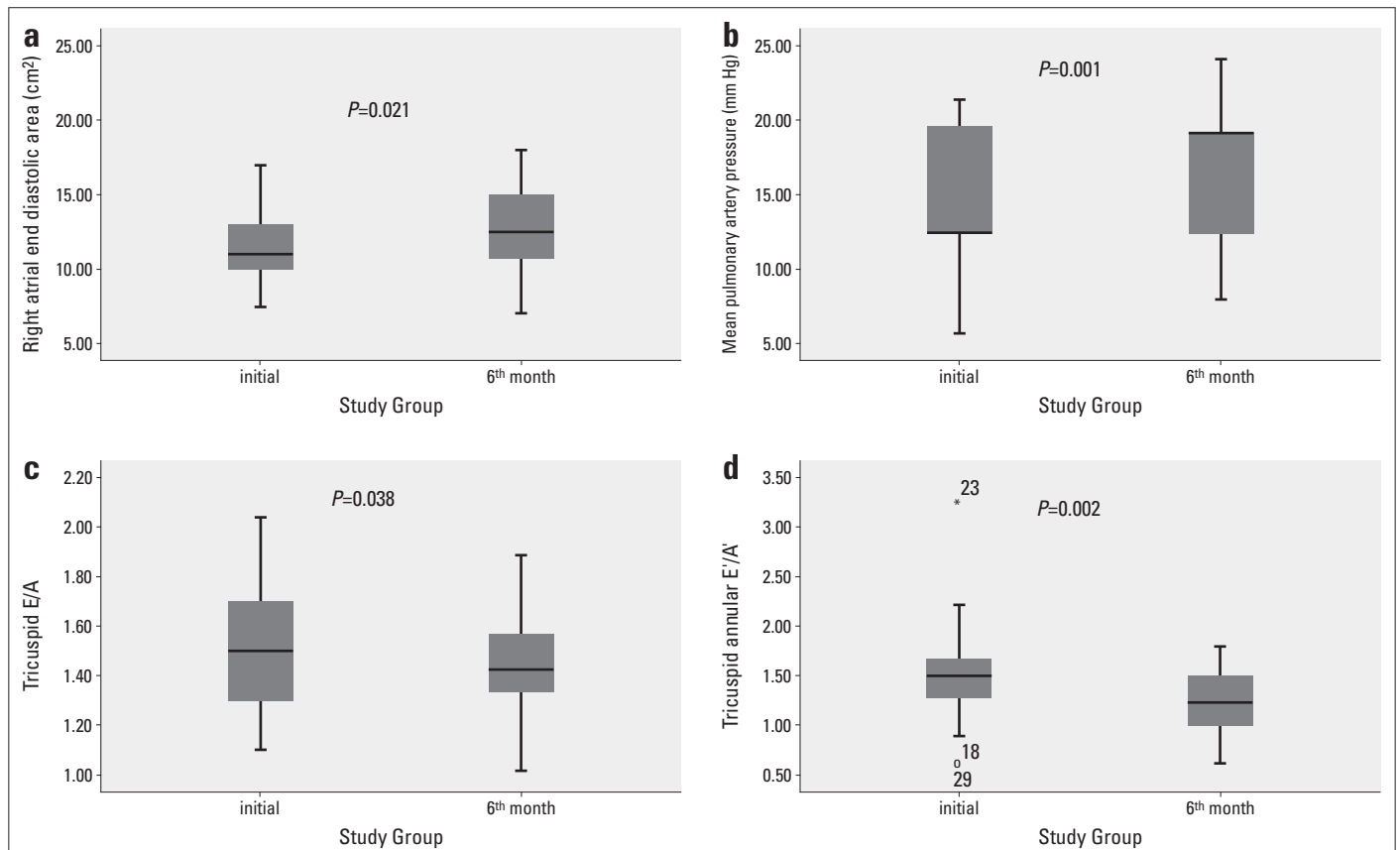


Figure 1. Boxplot graphics for echocardiographic indices of right ventricular diastolic function and pulmonary artery pressure. (a) Right atrial end diastolic area, (b) Mean pulmonary artery pressure, (c) Tricuspid flow E/A ratio, and (d) Tricuspid annular E'/A' ratio

Table 3. Echocardiographic variables for right ventricular morphology and function of the study group

Variable	Initial (n=33)	6 th month (n=33)	P
RV end-diastolic diameter, mm	36.8±4.3	37.1±4.7	0.728
RV end-diastolic area, cm ²	15.3±3.8	16.4±3.9	0.123
RV end-systolic area, cm ²	9.7±2.9	10.5±2.9	0.014
RV fractional area change, %	36.6±10.6	35.4±9.3	0.519
Right atrial end diastolic area, cm ²	11.5±2.3	12.9±3.2	0.021
Tricuspid annular plane systolic excursion, mm	23.5±2.9	23.5±3.6	0.664
RV myocardial performance index	0.34±0.1	0.28±0.07	0.135
Tricuspid E wave, cm/s	65.4±12.4	69.5±16.0	0.101
Tricuspid A wave, cm/s	42.3±11.2	48.8±12.5	0.013
Tricuspid E/A	1.61±0.3	1.45±0.2	0.038
Tricuspid deceleration time, ms	204±52	206±55	0.860
Mean pulmonary artery pressure, mm Hg	13.8±5.7	17.4±4.6	<0.001
Inspiratory inferior vena cava collapse, %	0.55±0.08	0.51±0.08	0.123
Tricuspid annular S, cm/s	14.1±2.9	15.4±2.3	0.031
Tricuspid annular E', cm/s	14.0±3.5	14.2±2.2	0.379
Tricuspid annular A', cm/s	10.0±3.8	12.1±3.0	0.006
RV free wall S, cm/s	10.5±3.2	12.7±2.2	0.007
RV free wall E', cm/s	11.9±3.8	14.5±3.2	<0.001
RV free wall A', cm/s	6.7±1.9	10.3±3.3	0.007
Tricuspid E wave/ Tricuspid annular E'	4.8±1.2	5.0±1.3	0.600
Tricuspid annular E'/A'	1.52±0.5	1.23±0.3	0.002
Student's t-test was used RV - right ventricle			

RV free wall, there were increases in the entire S, E', and A' wave velocities (10.5±3.2 cm/s vs. 12.7±2.2 cm/s, p=0.007; 11.9±3.8 cm/s vs. 14.5±3.2 cm/s, p<0.001; and 6.7±1.9 cm/s vs. 10.3±3.3 cm/s, p=0.007, respectively). The echocardiographic measurements of RV are presented in Table 3.

Discussion

In this study, we determined that RV systolic functions were preserved because of the absence of changes in the TAPSE, MPI, and FAC measurements and increased tricuspid annular S wave velocity. RV diastolic functions were altered because of the increased tricuspid inflow A and, annular A' wave velocity and decreased E/A and E'/A' ratio. In addition, altered LV diastolic function, because of increased mitral A wave velocity and decreased E/A ratio, was observed in healthy individuals who migrated to moderate altitude settlements from the sea level.

Transthoracic echocardiography is the most commonly used diagnostic tool for the evaluation of right ventricular functions in clinical practice. However, there are some difficulties in the evaluation of right ventricular functions. These difficulties are the complex geometry of the RV, trabeculated myocardium, retrosternal position of the RV, limited echocardiographic imaging windows, and the marked load dependence of indices of RV function (11). Previous studies have shown that tissue Doppler echocardiography is an efficient method for the evaluation of RV functions (12, 13). In our study, we used tissue Doppler echocardiography, which is a less load-dependent method, together with conventional echocardiographic methods.

RV changes observed in people after altitude exposure may be explained by afterload changes due to hypoxic pulmonary vasoconstriction. RV can adapt to afterload changes, but this contractile reserve is limited. Although RV can adapt to slow increases in afterload, as in chronic hypoxia, it cannot adapt to acute increases in afterload, as in acute pulmonary embolism. Similarly, there have been reported cases that developed acute right ventricular failure and acute pulmonary edema as a result of an acute increase in afterload developing after a rapid elevation to high altitudes (14-16). Also, CMS can develop following exposures that overwhelm the adaptive capacity to chronic hypoxia (17,18). In our study, there was not a huge change in RV functions because our study subjects were slowly exposed to only to moderate and not high altitude.

High-altitude environments and hypoxia decrease the exercise capacity (19, 20). Increased pulmonary vascular resistance may impair right ventricular function and reduce stroke volume and venous return to the left atrium. The interaction between the right and left ventricles may impair diastolic left ventricular filling as a consequence of right ventricular pressure overload and reduce the stroke volume. Additionally, the negative inotropic effect of hypobaric hypoxia is among the possible causes (21). Although these functional changes in LV and RV contribute to the reduced exercise capacity, the etiology is still not clear. In our study, we found altered RV and LV functions. As a result of our findings, the exercise capacity may also be affected in the moderate altitude.

Huez et al. (22) determined that following respiration in a hypoxic environment equivalent to 4500 m of altitude, RV systolic functions were preserved, whereas diastolic functions of both ventricles were impaired in 25 healthy individuals. In another study reported by Huez et al. (23), they found altered RV and LV diastolic functions in healthy persons at a high altitude (3750 m). Also, Huez et al. (24) reported that systolic and diastolic functions of RV were impaired in pulmonary hypertension patients. Maignan et al. (18) reported that a high altitude (4300 m) caused impairment both in RV systolic and diastolic functions. Similarly, Zeybek et al. (25) determined that RV diastolic functions were impaired in children living in moderate-altitude settlements (1890 m). In the studies mentioned above, it was stated that the observed results could have been caused by an increased RV afterload because of hypoxic pulmonary vasoconstriction. In our study, we also observed that mPaP was increased and altered RV diastolic func-

tion. The cause of altered RV diastolic functions could be the increased RV afterload, as reported in previous studies (22-25). Our results were observed to be within the physiological limits. This condition may be explained by an exposure to a relatively lower altitude and a short follow-up duration. Also, our study group consisted of healthy and young individuals.

Study limitations

The major limitations of our study are the limited number of cases, short follow-up duration, and the lack of basal measurements at the sea level before progressing to a moderate altitude. Another noteworthy limitation of our study is that the RV examinations were not compared with other gold standard methods. Difficulties in the echocardiographic evaluations of RV, which have been reported in many studies, were also a problem in our study.

Conclusion

Our study revealed that right ventricular diastolic function was altered while the systolic function was preserved in healthy subjects who migrated from the sea level to a moderate altitude. These changes could be explained by the adaptation mechanisms that develop in response to hypoxia. However, these results may be seen more dramatically in patients with chronic obstructive pulmonary disease, pulmonary hypertension, and heart failure. In this regard, prospective long-term follow-up studies are necessary in this population.

Conflict of interest: None declared.

Peer-review: Externally peer-reviewed.

Authorship contributions: Concept – A.A., E.A., H.Y.G., S.S.; Design – İ.H.T., H.Y.G., S.S., E.A.; Supervision – E.A., S.S., H.Y.G., A.A.; Materials- A.A., S.D., S.T., İ.H.T.; Data collection &/or processing – A.A., S.T., S.D., F.A.; Analysis and/or interpretation – S.D., F.A., M.K., A.Ç.; Literature review – F.A., M.K., A.Ç.; Writing – A.A., S.T., S.D., M.K.; Critical review – İ.H.T., A.Ç., F.A.

References

- Gibbs JS. Biventricular function at high altitude: implications for regulation of stroke volume in chronic hypoxia. *Adv Exp Med Biol* 2007; 618: 13-24.
- Güvenç TS, Erer HB, Kul S, Perinçek G, İlhan S, Sayar N, et al. Right ventricular morphology and function in chronic obstructive pulmonary disease patients living at high altitude. *Heart Lung Circ* 2013; 22: 31-7.
- Bärtsch P, Gibbs JS. Effect of altitude on the heart and the lungs. *Circulation* 2007; 116: 2191-202.
- Sui GJ, Liu YH, Cheng XS, Anand IS, Harris E, Harris P, et al. Subacute infantile mountain sickness. *J Pathol* 1988; 155: 161-70.
- Rich S, McLaughlin VV. Pulmonary hypertension, Braunwald's Heart Disease 8th edition, (Libby P, Bonow R., Mann D. Eds) Saunders, Elsevier, Philadelphia, 2008. p. 1886.
- Aparicio Otero O, Romero Gutierrez F, Haris P, Anand I. Echocardiography shown persistent thickness of the wall of the right ventricle in infants at high altitude. *Cardioscience* 1991; 2: 63-9.
- Morgan BJ, Alexander JK, Nicoli SA, Brammell HL. The patient with coronary heart disease at altitude: observations during acute exposure to 3100 meters. *J Wilderness Med* 1990; 1: 147-53.
- Mahan G, Dabestani A, Gardin J, Burn C, Henry W. Estimation of pulmonary artery pressure by pulsed Doppler echocardiography. *Circulation* 1983; 68: 367.
- Dabestani A, Mahan G, Gardin JM, Takenaka K, Burn C, Allfie A, et al. Evaluation of pulmonary artery pressure and resistance by pulsed Doppler echocardiography. *Am J Cardiol* 1987; 59: 662-8.
- Rudski LG, Lai WW, Afilalo J, Hua L, Handschumacher MD, Chandrasekaran K, et al. Guidelines for the echocardiographic assessment of the right heart in adults: a report from the American Society of Echocardiography endorsed by the European Association of Echocardiography, a registered branch of the European Society of Cardiology, and the Canadian Society of Echocardiography. *J Am Soc Echocardiogr* 2010; 23: 685-713.
- Jiang L. Right ventricle. In: Weyman AE, ed. *Principle and Practice of Echocardiography*. Baltimore, Md: Lippincott Williams & Wilkins; 1994. p. 901-21.
- Kjaergaard J, Snyder EM, Hassager C, Oh JK, Johnson BD. Impact of preload and after-load on global and regional right ventricular function and pressure: a quantitative echocardiography study. *J Am Soc Echocardiogr* 2006; 19: 515-21.
- Meluzin J, Spinarova L, Bakala J, Toman J, Krejci J, Hude P, et al. Pulsed Doppler tissue imaging of the velocity of tricuspid annular systolic motion; a new, rapid, and noninvasive method of evaluating right ventricular systolic function. *Eur Heart J* 2001; 22: 340-8.
- Huez S, Faoro V, Vachiere JL, Unger P, Martinot JB, Naeije R. Images in cardiovascular medicine. High altitude induced right heart failure. *Circulation* 2007; 115: 308-9.
- Maggiorini M, Léon-Velarde F. High-altitude pulmonary hypertension: a pathophysiological entity to different diseases. *Eur Respir J* 2003; 22: 1019-25.
- Gabry AL, Ledoux X, Mozziconacci M, Martin C. High-altitude pulmonary edema at moderate altitude (<2,400 m; 7,870 feet): a series of 52 patients. *Chest* 2003; 123: 49-53.
- Penaloza D, Arias-Stella J. The heart and pulmonary circulation at high altitudes: healthy highlanders and chronic mountain sickness. *Circulation* 2007; 115: 1132-46.
- Maignan M, Rivera-Ch M, Privat C, Leon-Velarde F, Richalet JP, Pham I. Pulmonary pressure and cardiac function in chronic mountain sickness patients. *Chest* 2009; 135: 499-504.
- Kjaergaard J, Snyder EM, Hassager C, Olson TP, Oh JK, Johnson BD, et al. Right ventricular function with hypoxic exercise: effects of sildenafil. *Eur J Appl Physiol* 2007; 102: 87-95.
- Aldashev AA, Kojonorazov BK, Amatov TA, Sooronbaev TM, Mirrakhimov MM, Morrell NW, et al. Phosphodiesterase type 5 and high altitude pulmonary hypertension. *Thorax* 2005; 60: 683-7.
- Naeije R. Physiological adaptation of the cardiovascular system to high altitude. *Prog Cardiovasc Dis* 2010; 52: 456-66.
- Huez S, Retailleau K, Unger P, Pavelescu A, Vachiere JL, Derumeaux G, et al. Right and left ventricular adaptation to hypoxia: a tissue Doppler imaging study. *Am J Physiol Heart Circ Physiol* 2005; 289: 1391-8.
- Huez S, Faoro V, Guénard H, Martinot JB, Naeije R. Echocardiographic and tissue Doppler imaging of cardiac adaptation to high altitude in native highlanders versus acclimatized lowlanders. *Am J Cardiol* 2009; 103: 1605-9.
- Huez S, Vachiéry JL, Unger P, Brimiouille S, Naeije R. Tissue Doppler imaging evaluation of cardiac adaptation to severe pulmonary hypertension. *Am J Cardiol* 2007; 100: 1473-8.
- Zeybek C, Taşyenen V, Kazancı E, Boğa A. Evaluation of cardiac function in healthy children native to 1890 metres. *Cardiol Young* 2010; 20: 201-5.