

Case Report

Successful treatment of inoperable recurrent secondary hyperparathyroidism with cinacalcet HCl

Rieko Eriguchi¹, Junko Umakoshi¹, Yoshihiro Tominaga² and Yuzuru Sato¹

¹Sato Junkanki Hospital, Matsuyama and ²Department of Transplant and Endocrine Surgery, Nagoya Daini Red Cross Hospital, Nagoya, Japan

Keywords: bone mineral density; cinacalcet; parathyromatosis; secondary hyperparathyroidism

Introduction

Secondary hyperparathyroidism is a common complication for patients with end-stage renal disease (ESRD). When it progresses, it is associated with morbidity and mortality [1]. Phosphate binders and vitamin D can be used to prevent the progression of secondary hyperparathyroidism. However, these conservative treatments often fail to control severe hyperparathyroidism. In such cases, parathyroidectomy is required. Despite medical management after parathyroidectomy, persistent or recurrent hyperparathyroidism can occur. One of the causes of recurrent hyperparathyroidism is parathyromatosis, which has been described as multiple nodules or rests of hyperfunctioning parathyroid tissue that become evident following parathyroidectomy. We describe a female haemodialysis patient diagnosed with secondary hyperparathyroidism, which was probably caused by parathyromatosis. Treatment with cinacalcet, a calcimimetic agent, in combination with vitamin D was extremely effective.

Case report

A 66-year-old woman with ESRD due to chronic glomerulonephritis was started on haemodialysis therapy in April 1992 at the age of 50. In October 1997, she was diagnosed with secondary hyperparathyroidism after her serum parathyroid hormone (PTH) level reached 940 pg/ml. The serum calcium level was 10.5 mg/dl, the serum phosphorus level was 4.8 mg/dl and the alkaline phosphatase level was 502 IU/l. Conservative oral vitamin D therapy was started. In April 2000, three enlarged parathyroid glands were found. Specifically, the right inferior gland was 18 mm

in diameter, the left superior gland was 17 mm and the left inferior gland was 19 mm by ultrasonography (US). Parathyroidectomy with autotransplantation of tissue into the left forearm was performed. The right and left inferior glands were easily removed, but the left superior gland was in the thyroid lobe. The right superior gland could not be detected. The pathological diagnosis of all the enlarged glands was nodular parathyroid hyperplasia.

Unfortunately, the int-PTH level continued to increase and reached 2160 pg/ml in April 2001. Considering the results of CT and technetium Tc 99m-sestamibi scans, removal of the remaining gland was performed. The gland was located in the right fossa supraclavicularis with attachment to the back of the trachea. Although we removed as much of the gland as possible, the patient had persistent paresis of the right recurrent laryngeal nerve postoperatively. In June 2003, she fell down and fractured her femoral neck.

In August 2003, enlargement of the autografted parathyroid tissues in her left forearm was detected, and the int-PTH level was 1800 pg/ml. Since the autografted parathyroid tissues were considered to be one of the main sources of PTH, they were removed. After the operation, the int-PTH level decreased to 290 pg/ml, but gradually increased thereafter. In August 2004 and November 2005, operations to remove the autografted parathyroid tissues were performed again. However, these operations were unsuccessful and the int-PTH levels were around 700 pg/ml.

In November 2006, the origins of her PTH oversecretion were re-evaluated. Autografted parathyroid nodules in the left forearm were detected by MRI, while nodules located around the bilateral lower poles of the thyroid lobes were detected by technetium Tc 99m-sestamibi, CT and US scans. Considering the risk of bilateral paresis of the recurrent laryngeal nerve, we were hesitant to re-operate. The possibility of parathyromatosis due to dissemination of the parathyroid tissue during the previous parathyroidectomy was considered. Histological examinations until this time showed no evidence of malignancy.

The dosage of calcitriol was limited to 3 µg/week due to hypercalcemia, and failed to stop the int-PTH level from reaching 1880 pg/ml. The patient was troubled by pruritus and bone pain in various parts of her body.

Correspondence and offprint requests to: Rieko Eriguchi, Asouda-cho 4-10-25, Matsuyama City, Ehime Prefecture 790-0952, Japan. Tel: +81-89-931-3355; Fax: +81-89-931-3431; E-mail: rieko-eriguchi@satohp.co.jp

© The Author [2008].

The online version of this article has been published under an open access model. Users are entitled to use, reproduce, disseminate, or display the open access version of this article for non-commercial purposes provided that: the original authorship is properly and fully attributed; the Journal and Oxford University Press are attributed as the original place of publication with the correct citation details given; if an article is subsequently reproduced or disseminated not in its entirety but only in part or as a derivative work this must be clearly indicated. For commercial re-use, please contact journals.permissions@oxfordjournals.org

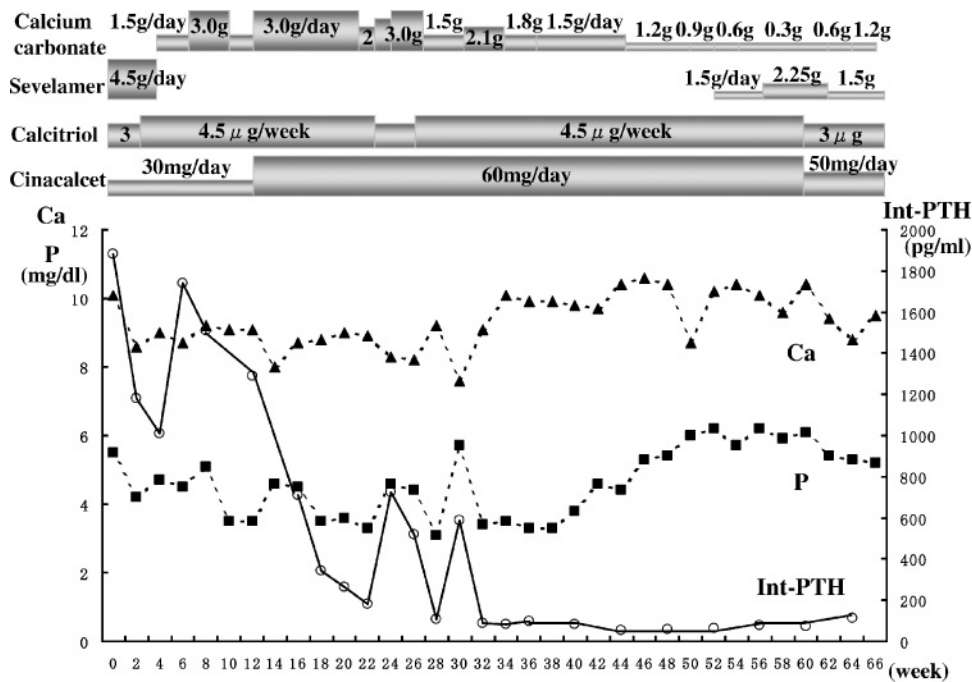


Fig. 1. Calcium, phosphorus and int-PTH levels during treatment with cinacalcet.

In December 2006, we started to administer cinacalcet using a dosage of 30 mg/day, in addition to a phosphate binder (sevelamer 4.5 g/day) and vitamin D (calcitriol 3 μ g/week intravenously). At 3 months after initiation of the therapy, we increased the cinacalcet dose to 60 mg/day, and its effects were more remarkable. The int-PTH level gradually decreased to 100–200 pg/ml, and the levels of serum calcium and phosphorus normalized (Figure 1). After the treatment, her severe bone pain disappeared, and the pruritus was relieved.

Her bone mineral density (BMD) was improved by administration of cinacalcet. Before the treatment, the BMD of the distal one-third of the radial bone by dual-energy X-ray absorptiometry (DEXA) was 0.248 g/cm² (*T* score, -7.62 SD), but after 1.4 years of administration of cinacalcet, it became 0.286 g/cm² (*T* score, -6.92 SD). The change in the BMD was 11.1% per year. The alkaline phosphatase level decreased from 1459 to 443 IU/l, while bone-type alkaline phosphatase (BAP) changed from 239 to 39 U/l and type 1 collagen *N*-telopeptide (NTX) changed from 800 to 62.5 nmol/BCE/l (Figure 2). It has currently been 16 years since she started haemodialysis, but she can now visit our hospital unaccompanied without using a wheelchair and without any pain or any additional bone fractures.

Discussion

Parathyromatosis is an uncommon but important cause of recurrent hyperparathyroidism. Two forms of parathyromatosis have been reported. Primary or type 1 parathyromatosis is thought to be due to hyperplasia of parathyroid rests from embryologic development [2]. The more common type 2 parathyromatosis occurs after spillage and

seeding of parathyroid tissue during parathyroid resection [2,3]. The present case is considered to be due to the latter situation. Parathyromatosis is difficult both to diagnose postoperatively, and to completely control by re-operations [4].

There are two previous reports regarding the successful use of cinacalcet for treating parathyromatosis [5,6]. In our case, the calcium, phosphorus and int-PTH levels could be controlled within the NKF-K/DOQI recommended targets for long periods, and her BMD was remarkably improved. Cinacalcet reduces PTH production and secretion by increasing the sensitivity of calcium-sensing receptors (CaSRs) to extracellular calcium. Activation of CaSRs not only reduces hormone secretion but also decreases parathyroid cell proliferation [7]. In our case, the severe hyperparathyroidism may not be due to parathyromatosis alone, and other possible causes were inoperable residual parathyroid glands or relapse of autografted parathyroid glands. Regardless of the cause, our patient clearly had nodular parathyroid hyperplasia considering the sizes of the parathyroid glands and the histological results. Cells in nodular hyperplasia have reduced numbers of vitamin D receptors and CaSRs, and are thus usually refractory to medical therapies [8]. Our present findings suggest that administration of cinacalcet with vitamin D may be effective against nodular hyperplasia.

Moreover, even though our patient had low BMD due to severe secondary hyperparathyroidism, her BMD improved after treatment with cinacalcet and vitamin D. This effect can lead to elimination of bone pain and prevention of additional bone fractures. Lien reported that cinacalcet reversed bone loss in the proximal femur, but did not affect the BMD of the lumbar spine [9]. Although our patient had extremely low BMD of the radial bone compared to this

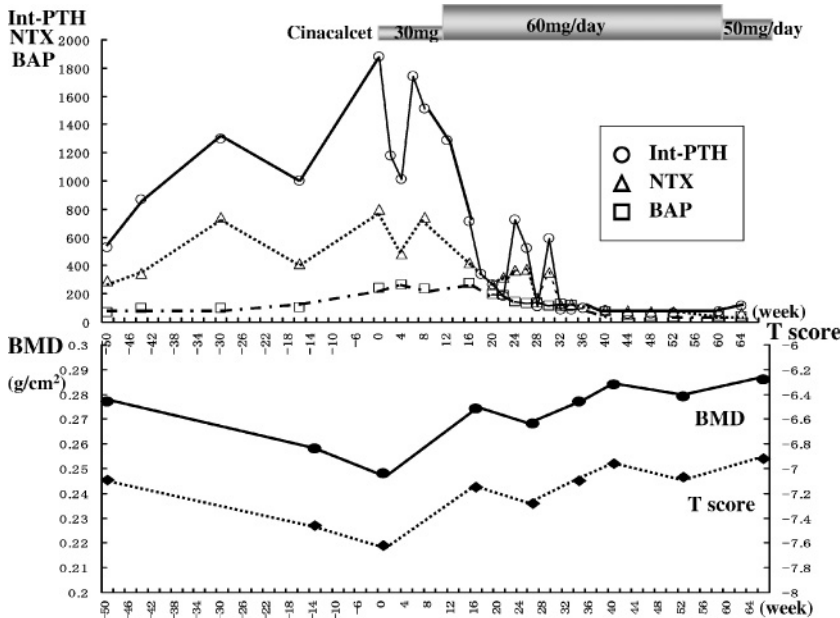


Fig. 2. Top: levels of int-PTH (pg/ml), type 1 collagen *N*-telopeptide (NTX; nmol/BCE/l) and bone-type alkaline phosphatase (BAP; U/l) before and during treatment with cinacalcet. Bottom: bone mineral density (BMD) before and during treatment with cinacalcet.

previous study based on *T* scores, her BMD nevertheless improved.

Rothe reported on a CaSR gene polymorphism, Arg990Gly, and its possible effects on the response to cinacalcet [10]. Homogeneous patients for the Arg990Gly polymorphism showed significantly higher sensitivities to cinacalcet with reduced int-PTH levels from the baseline. Our patient was examined for this gene polymorphism after providing an informed consent. She was found to be heterozygous for the Arg990Gly polymorphism, but the effect of cinacalcet was very evident.

In conclusion, cinacalcet is effective for refractory and inoperable secondary hyperparathyroidism patients. In addition, it improves their BMD and relieves bone pain.

Conflict of interest statement. None declared.

References

- Block GA, Klassen PS, Lazarus JM *et al.* Mineral metabolism, mortality and morbidity in maintenance hemodialysis. *J Am Soc Nephrol* 2004; 15: 2208–2218
- Reddick RL, Costa JC, Marx SJ. Parathyroid hyperplasia and parathyromatosis. *Lancet* 1977; 1: 549
- Kollmorgen CF, Aust MR, Ferreiro JA *et al.* Parathyromatosis: a rare yet important cause of persistent or recurrent hyperparathyroidism. *Surgery* 1994; 116: 111–115
- Matsuoka S, Tominaga Y, Sato T *et al.* Recurrent renal hyperparathyroidism caused by parathyromatosis. *World J Surg* 2007; 31: 299–305
- Daphnis E, Stylianou K, Katsipi I *et al.* Parathyromatosis and the challenge of treatment. *Am J Kidney Dis* 2006; 48: 502–505
- Unbehau R, Lauerwald W. Successful use of cinacalcet HCl in a patient with end-stage renal failure and refractory secondary hyperparathyroidism due to parathyromatosis. *Clin Nephrol* 2007; 67: 188–192
- Wada M, Nagano N. Control of parathyroid cell growth by calcimimetics. *Nephrol Dial Transplant* 2003; 18: III13–III17
- Fukagawa M, Nakanishi S, Kazama JJ. Basic and clinical aspects of parathyroid hyperplasia in chronic kidney disease. *Kidney Int* 2006; 70(Suppl 102): S3–S7
- Lien YH, Silva AL, Whittman D. Effects of cinacalcet on bone mineral density in patients with secondary hyperparathyroidism. *Nephrol Dial Transplant* 2005; 20: 1232–1237
- Rothe HM, Shapiro WB, Sun WY *et al.* Calcium-sensing receptor gene polymorphism Arg990Gly and its possible effect on response to cinacalcet HCl. *Pharmacogenet Genomics* 2005; 15: 29–34

Received for publication: 25.4.08

Accepted in revised form: 28.4.08