

Characteristics and proposed classification system of posterior pilon fractures

Jianzheng Zhang, MD, PhD^a, Hao Wang, MD^a, Cheng Pen, MD^a, Wen-chun Qu, MD, PhD^b, Lida Duan, MS^c, Jixin Ren, MD^a, Lianhua Li, MD^a, Zhi Liu, MD^a, Tiansheng Sun, MD, PhD^{a,*}

Abstract

Posterior pilon fractures involve the medial malleolus (MM). Our purpose was to define the characteristics of posterior pilon fractures, and propose a classification system based on fracture morphology and type of management.

The records of patients with posterior pilon fractures treated from 2011 to 2015 were retrospectively reviewed. The injury mechanism, fracture morphology, surgical approach, and follow-up results were reviewed and analyzed. This study was approved by the Institutional Review Board of PLA Army General Hospital.

Thirty-six patients, 18 males and 18 females (mean age: 48.9 years) were included in the study. Four characteristics were used to define posterior pilon fractures. A simple posterolateral approach or a combined posterolateral and posteromedial approach was used for reduction and fixation in all patients. The mean follow-up time was 28.2 months, and at the end of follow-up, the mean American Orthopedic Foot and Ankle Society Score (AOFAS) was 82.5 points (range: 35–100 points). Based on injury mechanism and fracture morphology, we classified posterior pilon fractures into 3 types that suggest the optimal surgical approach: type I, a single complete fracture fragment; type II, a posterior malleolus fracture with 2 subtypes; type III, a posterior malleolus fracture associated with complete MM fracture with 2 subtypes.

The proposed classification system based on injury mechanism and fracture morphology can guide the surgical approach to maximize outcomes.

Abbreviations: AC = anterior colliculus, AOFAS = American Orthopedic Foot and Ankle Society Score, MM = medial malleolus, PC = posterior colliculus, PL = posterolateral fragment, PM = posteromedial fragment, VAS = visual analogue scale.

Keywords: ankle, fracture, medial malleolus, Posterior pilon

1. Introduction

A posterior pilon fracture is a unique type of ankle fracture, and its mechanism of injury and treatment principles are different from those of the trimalleolar fracture in the Lauge–Hansen classification, and also different from those described for the classic pilon fracture. Posterior pilon fractures have a low incidence and generally poor treatment outcomes.^[1] Chen et al^[1] reported that posterior pilon fractures occur in 6.4% of

trimalleolar fractures, and Topliss et al^[2] reported that posterior pilon fractures occur in 5.6% of all pilon fractures, based on computed tomography (CT) images. Huber et al^[3] initially applied the concept of “trimalleolar pilon fracture” to describe posterior malleolus fractures in the coronal plane. Hansen et al^[4] summarized the characteristics of posterior pilon fractures, and considered it a special type of trimalleolar fracture, that is, a posterior pilon fracture. The authors commented that the pathological features of posterior pilon fractures are different from those of the traditional ankle fracture and the classic pilon fracture, and it is very important to differentiate a posterior pilon fracture from an ankle fracture and classic pilon fracture in clinical practice.

Because of the low incidence and variation in fracture morphology, there is controversy over the practicable classification of posterior pilon fractures based on clinical features.^[1,5,6] An ideal fracture classification system can suggest the injury mechanism and severity, guide treatment, and predict prognosis.^[7] At present, the various classification methods agree that posterior pilon fractures involve the entire coronal plane of the posterior malleolus.^[8,9] However, no current classification method is based on the injury mechanism, and none can summarize fracture morphology or guide treatment.

The most commonly used classification methods include the system developed by Yu et al^[8] that is based on CT cross-sectional images, and the system developed by Klammer et al^[9] that is based on the location and degree of comminution of the medial malleolus (MM) fracture. However, neither method takes into account the mechanism of injury or the degree of comminution of the (MM) fracture, nor do they provide guidance for treatment or prognosis.

Editor: Johannes Mayr.

The study was funded by the General Project of 12th 5-Year plan (PLA), CBJ14ZJ008. The research is rated as a special capital project by the Beijing Municipal Committee of Science and Technology, Z111107058811032.

The authors have no conflicts of interest to disclose.

^a Department of Orthopedic Surgery, PLA Army General Hospital, No. 5 Nanmencang, Dongcheng District, Beijing, China. ^b Department of Physical Medicine and Rehabilitation, Division of Pain Medicine, Mayo Clinic, Rochester, MN, USA. ^c Department of Orthopedic Surgery, PLA No. 66029 Army Hospital, Sonid Right Banner, Neimenggu, China.

* Correspondence: Tiansheng Sun, Department of Orthopedic Surgery, PLA Army General Hospital, No. 5 Nanmencang, Dongcheng District, Beijing, 100700, China (e-mail: suntiansheng@163.com).

Copyright © 2019 the Author(s). Published by Wolters Kluwer Health, Inc. This is an open access article distributed under the terms of the Creative Commons Attribution-Non Commercial-No Derivatives License 4.0 (CCBY-NC-ND), where it is permissible to download and share the work provided it is properly cited. The work cannot be changed in any way or used commercially without permission from the journal.

Medicine (2019) 98:3(e141133)

Received: 3 November 2017 / Received in final form: 20 December 2018 /

Accepted: 21 December 2018

<http://dx.doi.org/10.1097/MD.00000000000014133>

The purpose of this study was to review the clinical characteristics, treatments, and outcomes of posterior pilon fractures treated at our institution and to propose a new classification that takes into account the injury mechanism and fracture morphology. We also aimed to investigate the effectiveness of this method for guiding the selection of the surgical approach that would provide the best outcomes.

2. Patients and methods

2.1. Patients

The medical records of patients with ankle fractures treated at our institution from January 2011 to March 2015 were retrospectively reviewed. Inclusion criteria for this study were:

1. age ≥ 18 and ≤ 75 years;
2. ankle fracture involving the posterior malleolus;
3. complete preoperative and postoperative CT imaging data; and
4. follow-up data for at least 24 months.

Exclusion criteria were:

1. the fracture was pathological or old;
2. Gustilo type II or III open fractures or fractures treated conservatively;
3. local soft tissue infection or systemic inflammatory response syndrome;
4. fractures involving multiple segments or multiple bones in the same limb, or associated injuries of vital organs;
5. history of ipsilateral ankle joint trauma or disease;
6. neurologic or psychiatric disorder.

This study was approved by the Institutional Review Board of our hospital (2017-GK-006; approved date: 2017/03/16), and because of the retrospective nature of the study, informed consent was waived. All patients provided consent for all surgical procedures performed.

2.2. Posterior pilon fracture diagnosis

Two orthopedic surgeons reviewed patient data and analyzed imaging studies independently after receiving training on posterior pilon fracture characteristics based on the classification methods described by Yu et al.^[8] and Klammer et al.^[9] and the novel classification method described in this report. Diagnosis of a posterior pilon fracture was made when the primary indicator and one of the secondary indicators (described later in the article) were identified. If the diagnosis of the 2 surgeons differed, the final diagnosis was determined by the research team (all authors of the study) after discussion. The primary indicator was defined as the posterior malleolus fracture line extending along the coronal plane into the posterior colliculus (PC) of the (MM) or the intercollicular groove, and when one or more fracture fragments were present. Secondary indicators were:

1. the posterior malleolus fracture fragment was displaced proximally, and there was associated posterior dislocation of the ankle joint;
2. a die-punch fragment or depressed articular surface of the distal tibia was present;
3. an anteroposterior radiograph showed a double-cortical sign;
4. a lateral malleolus fracture was present.

2.3. Surgical techniques

Epidural or general anesthesia was used. A pneumatic tourniquet was applied around the upper thigh of the affected limb, and the

patient was placed in the prone position on an orthopedic operating table. In all patients with a single fracture fragment or some patients with 2 fragments in the posterior malleolus, a posterolateral approach was used to expose the fracture sites at the posterior malleolus and lateral malleolus. A longitudinal incision was made between the lateral margin of the Achilles tendon and the posterior margin of the fibula. The length of incision was based on the lateral malleolus and posterior malleolus fractures. The soft tissues were incised, and the sural nerve and small saphenous vein were protected. Reduction and fixation of the lateral malleolus fracture was performed via an approach between the peroneus longus and brevis and the extensor digitorum longus. The posterior tibial lip and the posterior joint capsule were then exposed between the flexor hallucis longus and the peroneus longus and brevis. Although fixation of the lateral malleolus may affect the results on intraoperative fluoroscopy, reduction of the posterior malleolus can be achieved due to the traction of the posterior inferior tibiofibular ligament. In some patients, the posterior malleolus fragment was turned backward under direct vision, and reduction of the depressed die-punch fragment or the depressed articular surface was carried out using a bone hook. After bone grafting, temporary fixation was performed using a fine Kirschner (K)-wire on the anterior tibial lip. Free bone fragments were removed when they were ≤ 2 mm. After reduction of the posterior malleolus, temporary fixation was performed. Plate and screw fixation was then performed after fluoroscopic results confirmed that the articular surface was congruent.

For patients with multiple fracture fragments or comminuted fractures, a combined posterolateral approach was used. Reduction and fixation of the lateral malleolus fracture was performed via the posterolateral approach, and temporary fixation of the posterolateral fragment (PL) was carried out. Next, a longitudinal incision was made between the medial margin of the Achilles tendon and posterior margin of the tibia to expose the medial fracture site between the flexor digitorum longus and posterior tibial neurovascular bundle. The posterior tibial nerve and blood vessels were protected carefully. The posteromedial fragment (PM) was then turned over. In 15 patients, the die-punch fragment was located in the posteromedial side of the tibia. Reduction and temporary K-wire fixation was performed when fracture fragments were large enough, and fragments were removed when they were ≤ 2 mm. For comminuted fractures, a combined approach was used for reduction of the comminuted bone fragments and temporary fixation was performed under fluoroscopy. A one-third tubular plate or a posterior malleolus sliding plate was used for final fixation.

In patients with complete MM fractures, the medial fracture line extended to the anterior colliculus (AC) of the MM, and a combined posterolateral and posteromedial approach was used. That is, the posterolateral incision was extended along the posterior margin of the MM in an arc shape. After reduction, fixation was carried out using 4.0 mm cannulated screws. In 4 patients where the posterior malleolus fracture line involved the intercollicular groove, avulsion fracture of the AC and separation of the AC and PC were observed. For these patients, the posteromedial incision was extended to the front of the prominence of the lateral malleolus to expose the fractured AC. After temporary reduction of the AC using K-wire, a 3.0 mm cannulated screw was used for fixation.

After the surgical procedures were completed, a drainage tube was placed and the wound closed in layers. No external fixation was used.

Table 1
Comparison of 3 classification methods for posterior pilon fractures.

Case	Fracture characteristics	Injury mechanism	Fracture pattern on CT	Surgical management	Prognosis (AOFAS score)	Proposed classification of the present study	Yu classification ^[8]	Klammer classification ^[9]
1	Single posterior malleolus fracture	Fall from height	PM and die-punch	Posterolateral approach and ORIF PM	86	I	Ila	I
2		Fall from height	PM and die-punch	Posterolateral approach and ORIF PM	87	I	Ila	I
3		Traffic injury	PM and die-punch	Posterolateral approach and ORIF PM	92	I	Ila	I
4		Traffic injury	PM and die-punch	Posterolateral approach and ORIF PM	100	I	Ila	I
5		Fall from height	PM	Posterolateral approach and ORIF PM	91	I	Ila	I
6		Traffic injury	PM and die-punch	Posterolateral approach and ORIF PM	72	I	Ila	I
7		Fall during bicycle riding	PM and die-punch	Posterolateral approach and ORIF PM	80	I	Ila	I
8		Fall from height	PM	Posterolateral approach and ORIF PM	91	I	Ila	I
9		Traffic injury	PM and die-punch	Posterolateral approach and ORIF PM	91	I	Ilb	I
10		Sport injury	PM and die-punch	Posterolateral approach and ORIF PM	88	I	Ilb	I
11		Fall from height	PM	Posterolateral approach and ORIF PM	68	I	Ilb	I
12		Fall from height	PM	Posterolateral approach and ORIF PM	91	I	Not classified	I
13	Two-part fracture	Fall during bicycle riding	PM and PL	Posterolateral approach and ORIF PM and PL	94	Ila	Ila	II
14		Sport injury	PM and PL	Posterolateral approach and ORIF PM and PL	68	Ila	Ilb	II
15		Traffic injury	PM and PL,die-punch	Posterolateral approach and ORIF PM and PL	83	Ila	Ilb	II
16		Fall from height	PM and PL	Posterolateral approach and ORIF PM and PL	81	Ila	Ilb	II
17		Fall during bicycle riding	PM and PL	Posterolateral approach and ORIF PM and PL	74	Ila	III	II
18		Sport injury	PM and PL,die-punch	Posterolateral approach and ORIF PM and PL	83	Ila	III	II
19		Fall from height	PM and PL,die-punch	Posterolateral approach and ORIF PM and PL	58	Ila	III	II
20		Sport injury	PM and PL	Posterolateral approach and ORIF PM and PL	93	Ila	III	II
21		Fall from height	PM and PL	Posterolateral approach and ORIF PM and PL	90	Ila	III	II
22		Traffic injury	PM and PL, die-punch	Posterolateral approach and ORIF PM and PL	84	Ila	III	II
23	Comminuted fracture	Fall from height	Three comminuted posterior malleolus fragments, die-punch	Posterolateral approach and additional posteromedial approach	93	Ilb	III	II
24		Sport injury	Three comminuted posterior malleolus fragments	Posterolateral approach and additional posteromedial approach	92	Ilb	Not classified	II
25		Traffic injury	Three comminuted posterior malleolus fragments, die-punch	Posterolateral approach and additional posteromedial approach	89	Ilb	Not classified	II
26		Fall from height	Three comminuted posterior malleolus fragments	Posterolateral approach and additional posteromedial approach	68	Ilb	Not classified	II
27	Posterior malleolus fracture line extending to the AC of the MM, and the anterior and PC is a complete bone fragment.	Sport injury	Posterior malleolus fracture involves AC of MM, die-punch	Posterolateral and posteromedial approach	82	IIla	III	III
28		Traffic injury	Posterior malleolus fracture involves AC of MM	Posterolateral and posteromedial approach	86	IIla	III	III
29		Fall from height	Posterior malleolus fracture involves AC of MM, die-punch	Posterolateral and posteromedial approach	91	IIla	Not classified	III
30		Fall from height	Posterior malleolus fracture involves AC of MM	Posterolateral and posteromedial approach	84	IIla	Not classified	III
31		Sport injury	Posterior malleolus fracture involves AC of MM	Posterolateral and posteromedial approach	49	IIla	Not classified	III
32		Fall from height	Posterior malleolus fracture involves AC of MM, die-punch	Posterolateral and posteromedial approach	93	IIla	Not classified	III
33	Separated fractures in the AC and PC	Sport injury	Posterior malleolus fracture involves PC, and AC avulsion	Posterolateral and extended posteromedial approach, 3.0-mm screw for AC	86	IIlb	II	III
34		Traffic injury	Posterior malleolus fracture involves PC, and AC avulsion	Posterolateral and extended posteromedial approach, K-wire for AC	35	IIlb	Not classified	III
35		Fall from height	Posterior malleolus fracture involves PC, and AC avulsion, die-punch	Posterolateral and extended Posterolateral approach, K-wire for AC	86	IIlb	Not classified	III
36		Traffic injury	Posterior malleolus fracture involves PC, and AC avulsion, die-punch	Posterolateral and extended posteromedial approach, 3.0-mm cannulated screw for AC	91	IIlb	Not classified	III

Note: A type I fracture in the Yu et al classification is a large-block avulsion fracture of the posterolateral Volkmann's tubercle. Because the fracture line does not involve the MM, it should not be classified as a posterior pilon fracture.

AC=anterior colliculus; MM=medial malleolus; PC=posterior colliculus; PL=posterolateral fragment; PM=posteromedial fragment.

2.4. Postoperative management and evaluation

The drainage tube was removed on the second day after surgery, and isometric contraction exercises of the quadriceps femoris, calf muscles, and lower limb were begun. Continuous passive motion training was also carried out. Partial weight-bearing was started 6 weeks after surgery, and normal activity was restored gradually, beginning 12 weeks after surgery. Patients were followed-up at 1, 2, 3, 4, 6, 12, and 24 months after surgery, and then annually to observe ankle joint function and fracture healing.

Burwell-Charnley radiographic criteria^[10] were used to evaluate postoperative fracture reduction. At the last follow-up (24 months postoperatively), ankle joint and foot function were evaluated using the American Orthopedic Foot and Ankle Society (AOFAS) score.^[11,12] A visual analogue scale (VAS) was used to evaluate knee joint pain during walking and resting.

3. Results

3.1. Patients and operative results

A total of 406 patients of posterior malleolus fracture were identified in the medical records search. Forty met the diagnostic criteria for a posterior pilon fracture. Of these, 2 patients were excluded because of incomplete preoperative data, 1 because the patient had Alzheimer disease, and 1 because of an ipsilateral Lisfranc injury. Thus, 36 patients were included in the analysis. Injury mechanism, fracture characteristics, fracture pattern on CT, surgical management, and prognosis are summarized in Table 1.

Of the 36 patients, 18 were males and 18 were females, and the mean patient age as 48.9 years (range: 20–73 years). Fractures were on the left side in 19 patients, and the right side in 17. Causes of the injury included falls from heights in 15 patients, traffic injuries in 10, sports injuries in 8, and falls during cycling in 3. All patients had closed fractures. In 2 patients there was local swelling, ecchymosis, and blisters in the soft tissue anterior to the ankle joint caused by suppression of the fracture end (Tscherne grade II). All patients were associated with lateral malleolus fractures. The average injury-to-surgery interval was 6.1 days (range: 1–13 days).

According to the Danis–Weber classification, 21 patients had type B and 15 had type C lateral malleolus fractures, of which 26 (72.2%) had oblique fractures and 10 (27.8%) had transverse or comminuted fractures. Thirty patients (83.3%) had associated posterior dislocation of the ankle. Twenty patients (55.5%) had associated die-punch injuries with the bone fragments measuring 2 to 8 mm in diameter; in these patients, the posteromedial articular surface of the tibia was involved in 15 patients and the posterolateral articular surface was involved in 5. Of 20 patients with associated die-punch injuries, small fragments (≤ 2 mm) were removed in 8 patients because they were too small to repair, and the larger fragments in the other 12 patients were reduced and fixed (autologous cortical bone grafts were used in 8 of these patients).

Anteroposterior radiographs showed a double-cortical sign of the MM in 10 patients. The intraoperative Cotton test was positive in 10 patients; 4 patients were Weber type B and 6 were type C. The mean percentage of posterior malleolus fracture fragments in the distal articular surface of the tibia was 31.4% (range: 12%–46%). Plaster fixation was used in 28 patients, and calcaneal traction was performed for 8 others.

According to the classification of Yu et al,^[8] 7 patients were type IIa, 5 were type IIb, and 10 were type III. Four patients involving comminuted fractures of the posterior malleolus and 10 patients with associated medial malleolus fractures could not be classified (Table 1). According to the Klammer classification,^[9] 12 patients were type I, 14 were type II, and 10 were type III. However, 4 patients could not be classified due to comminuted fractures of the posterior malleolus. Four patients could not be classified because the posterior malleolus fracture line extended to the AC of the MM, and the anterior and PC was a complete bone fragment (Table 1). According to Burwell–Charnley radiographic criteria, 18 patients were rated as excellent, 14 were fair, and 2 were poor.

The mean follow-up time for all 36 patients was 28.2 months (range: 24–51 months). Bone union was achieved in all patients at a mean of 14.6 weeks (range: 12–20 weeks). No neurovascular injury, wound infection, reduction loss, or internal fixation failure occurred in any patient. Screws were removed from

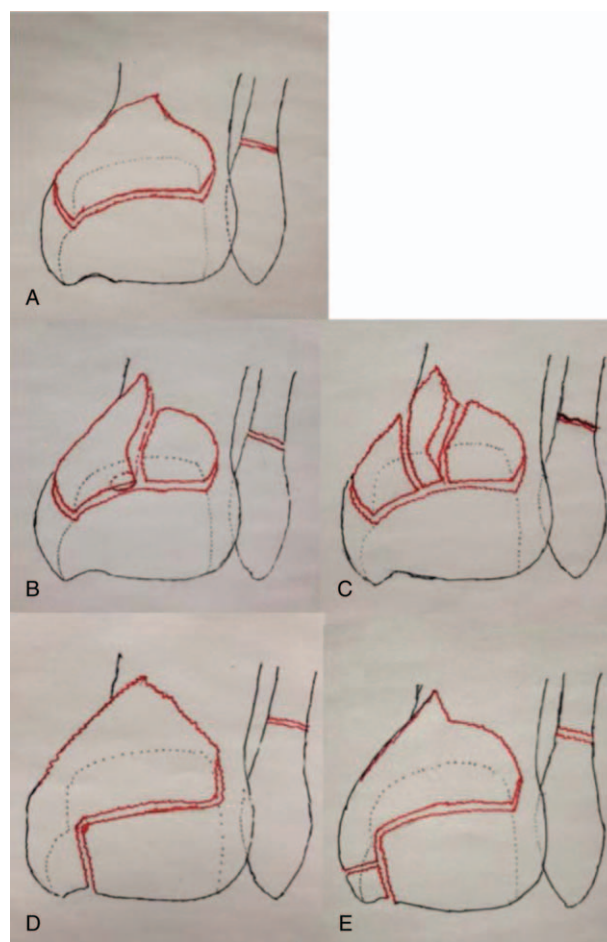


Figure 1. Schematic illustration of the Army General Hospital classification. (A) Type I fracture: the posterior malleolus is a single complete bone fragment. (B) Type IIa fracture: the posterior malleolus fracture is divided into 2 parts, posteromedial and PL. (C) Type IIb fracture: the posterior malleolus fracture is a comminuted fracture. (D) Type IIIa fracture: the fracture line of the posterior malleolus fracture involves the AC of the MM, the MM fracture is a complete fracture, but the AC and PC are not separated. (E) Type IIIb fracture: the posterior malleolus fracture line involves the intercollicular groove, the AC fracture is an avulsion fracture associated with separation of the AC and PC. AC = anterior colliculus, MM = medial malleolus, PC = posterior colliculus.

10 patients with tibiofibular joint fixation 6 to 9 weeks after surgery (mean: 7.3 weeks). During the follow-up period, internal fixation devices were removed in 16 patients. The posterior tibial tendon was irritated by the posterior malleolus plate in 6 patients, and the pain was relieved after removing the plate. One patient had traumatic arthritis of the ankle joint, and the pain improved after arthroscopic debridement. One patient complained of continuous pain, stiffness, and swelling of the ankle joint, and the pain was relieved with nonsteroidal anti-inflammatory drugs.

At the 24-month follow-up, the mean AOFAS score was 82.5 points (range: 35–100 points); 14 patients were rated as excellent, 14 were good, 6 were fair, and 2 were poor. The mean VAS pain score was 1.6 points (range: 0–5 points) during walking and 0.5 points (range: 0–3 points) during rest.

3.2. Proposed classification system

Based on the patients in this study, we identified 4 features that differentiate posterior pilon fractures from the traditional trimalleolar fracture and the classic pilon fracture (Fig. 1).

1. The posterior malleolus fracture line extends along the coronal plane to the PC of the MM or the intercollicular groove, and the fracture is usually associated with an oblique lateral malleolus fracture.
2. The posterior malleolus fracture is often larger than 25% of the entire articular surface, and displaced posteriorly with the talus.
3. There is an associated die-punch injury in the posterior articular surface of the tibia, which is mostly located in the posteromedial side of the tibia.
4. Because the MM fracture is displaced proximomedially, there is a distinctive double-cortical sign of the MM on radiographs.

Based on the classification systems developed by Yu et al^[8] and Klammer et al,^[9] we propose a novel classification system of posterior pilon fractures according to injury mechanism and fracture morphology identified on CT cross-sectional

images (Table 1). In our proposed system, type I fractures are defined when the posterior malleolus fracture fragment is a complete block, and a transverse, oblique, or curved fracture line involves the PC of the MM. The possible mechanism of this type of fracture is that the foot is in a mild varus or neutral position at the time of injury, and the force of impact is vertical to the posterior malleolus, resulting in a fracture of the posterior malleolus. Because the posterior malleolus fracture fragment is a complete block and mainly located in the posterolateral side, a simple posterolateral approach can expose it and achieve reduction (Fig. 2).

A type II fracture is defined when the posterior malleolus is separated into 2 or more fragments. Based on the severity of fracture comminution, type II is divided into 2 subtypes, type IIa and type IIb. Type IIa has 2 fracture fragments, posteromedial and PL, while type IIb is a comminuted fracture of the posterior malleolus (Fig. 3). The possible injury mechanism of a type IIa fracture is that a vertical force results in a posterior malleolus fracture, and internal rotation of the tibia results in infra-tibiofibular syndesmosis tension that separates the fracture fragments. The possible mechanism of the type IIb fracture is that the vertical force is more severe, or the ankle joint is in extreme plantar flexion at the time of injury (Fig. 4).

A type III fracture is defined as a posterior malleolus fracture associated with a complete MM fracture. Based on the morphology of the medial fracture, it is further divided into type IIIa and type IIIb fractures. In type IIIa, the posterior malleolus fracture line involves the whole MM; however, the AC and the PC are not separated, and the fracture line forms an "L" shape (Fig. 5). In type IIIb fractures, the posterior malleolus fracture line involves the PC or the intercollicular groove, and the AC is fractured and separated from the PC (Fig. 6). The possible injury mechanism of a type IIIa fracture is that the foot is in extreme varus, and the mediosuperior margin of the talus impacts the MM to result in a vertical fracture of the MM. The possible mechanism of the type IIIb fracture is that a vertical force results in a posterior malleolus fracture, and a torsional

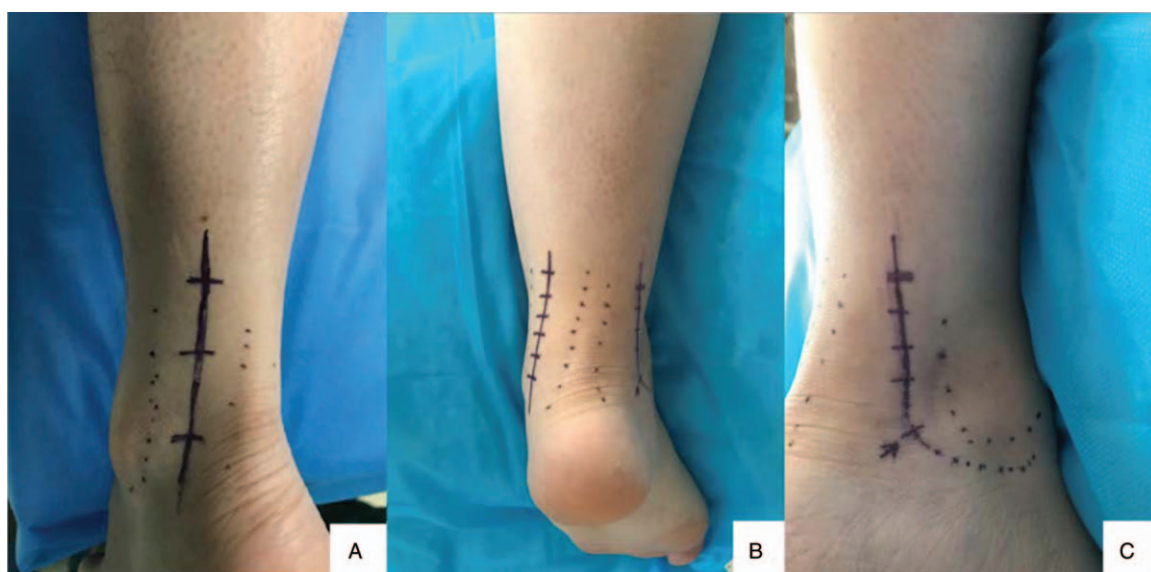


Figure 2. Surgical approaches for posterior pilon fractures. (A) Posterolateral incision. (B) Combined posterolateral and posteromedial incision. (C) Extended posteromedial incision.

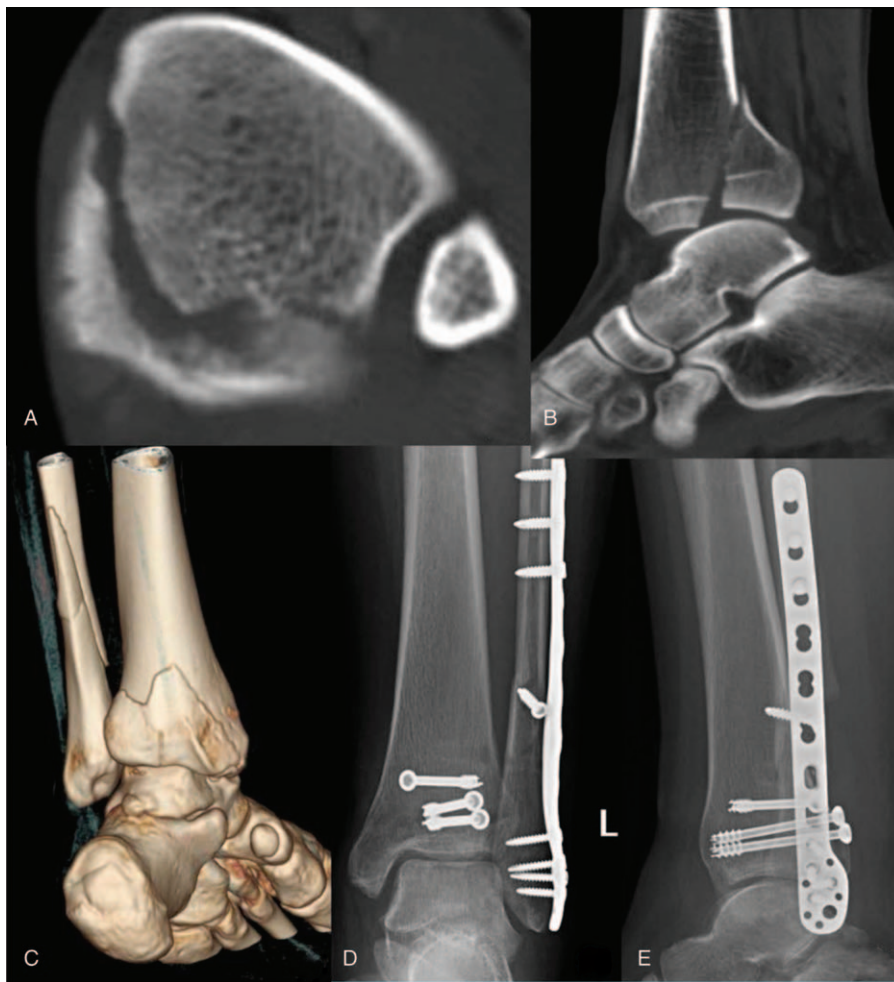


Figure 3. A 45-year-old male had a posterior pilon fracture due to a fall. It was a type I fracture, and the posterior malleolus was a single complete bone fragment. (A) CT axial scan showed that the curved fracture line of the posterior malleolus involves the MM. (B) The CT reconstruction showed that the posterior malleolus fracture was associated with posterior dislocation of the ankle joint. (C) Three-dimensional (3D) CT reconstruction showed that the posterior malleolus is a single complete bone fracture, and the fracture line involves the MM. (D) Reduction and fixation of the lateral malleolus and MM were carried out via the posterolateral approach. This postoperative x-ray image shows reduction of the posterior malleolus fracture with a smooth articular surface. (E) This postoperative lateral x-ray image shows anterior-to-posterior screw fixation following reduction of the posterior malleolus fracture. CT = computed tomography, MM = medial malleolus.

force results in an avulsion fracture of the AC and separation of the AC and PC. Due to the extent of the MM fracture, the posteromedial incision should be extended distally, or an auxiliary medial incision should be used for reduction and fixation of the MM fracture. In type IIIb fractures, because the AC fragment is small, it should be fixed with a tension band or a fine screw.

4. Discussion

In this report, we identified characteristics of posterior pilon fractures, and proposed a classification system based on the injury mechanism and fracture morphology on coronal CT scans. The system allows classification of all posterior pilon fractures, and can assist in choosing the appropriate surgical approach to optimize outcome. While Leonetti and Tigani recently proposed a new classification system that can be helpful for defining the surgical approach,^[13] we focused on the posterior pilon, not just the pilon. In addition, our classification is based on CT results of the fracture pattern and not joint involvement, the number of

articular fragments, the plane along which the major fracture line lies at the joint level, or areas of comminution.

Posterior pilon fractures are unique, independent ankle joint fractures involving the coronal plane of the posterior malleolus and the MM that have a distinct anatomical basis and injury mechanism.^[12,14] The articular surface of the distal end of the tibia is concave, with the prominent MM and lateral malleolus together with a convex posterior lip (Fig. 7). The top of the posterior lip is the attachment of the posterior tibiofibular ligament.^[15] This anatomical arrangement limits posterior dislocation of the talus, and becomes the anatomical basis of posterior pilon fractures.^[16,17] During high-energy injuries from traffic accidents or falls, the ankle joint is in a plantar flexion position, while the foot is inverted. When the lateral edge of the foot touches the ground, the body's inertia imparts forward, downward, and outward forces to the lateral malleolus and posterior malleolus. This results in an oblique posterosuperior-to-anteroinferior fracture of the lateral malleolus, and fracture of the coronal plane of the posterior malleolus, due to the impact of the posterior malleolus on the talus. These fractures are mostly

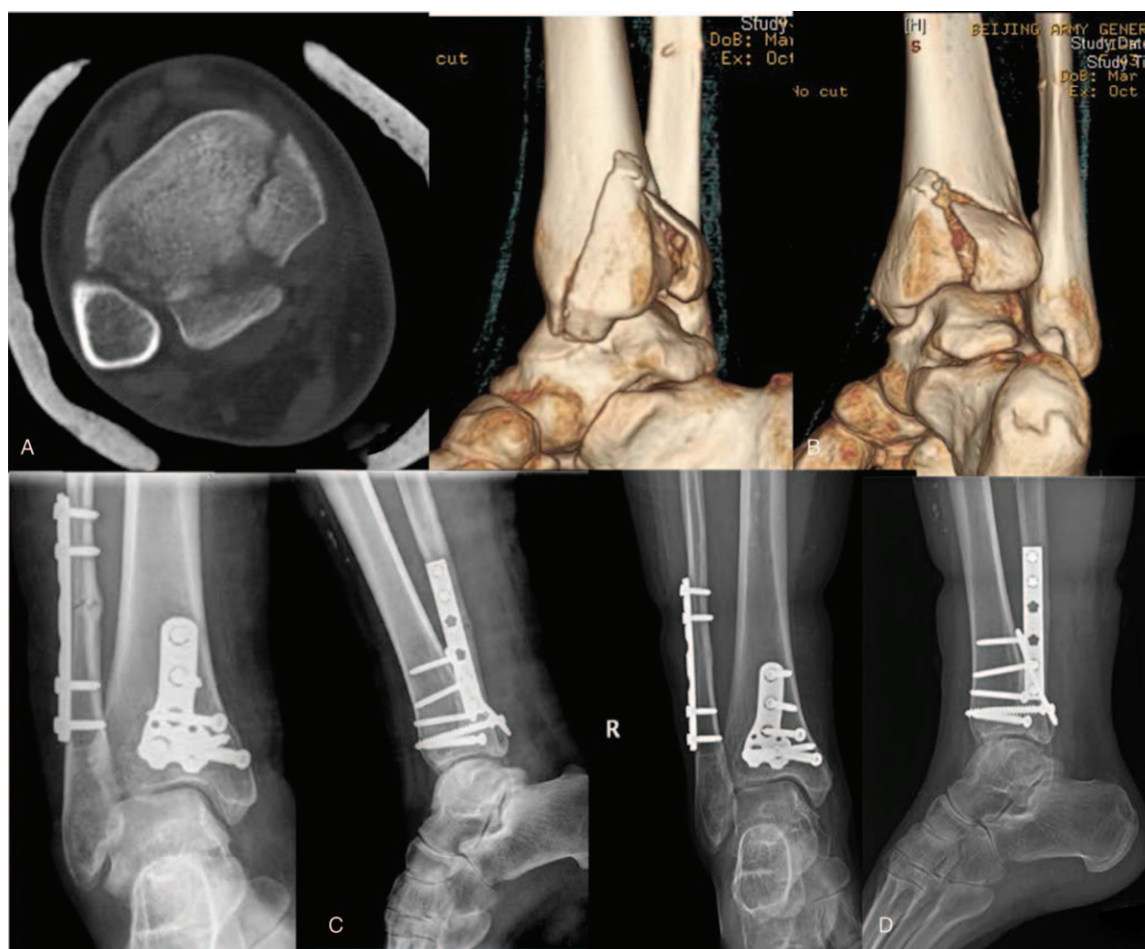


Figure 4. A 43-year-old female had a posterior pilon fracture due to a car accident. It was a type IIa fracture; the posterior malleolus was split into 2 parts, PM and PL. (A) Axial CT showed the posterior malleolus was divided into 2 parts. (B) 3D CT reconstruction showed the posterior malleolus was divided into 2 parts, and the posteromedial fracture involved the MM. (C) Reduction and buttress plate fixation were carried out via a combined posteromedial and posterolateral approach. Postoperative anteroposterior x-ray images showed reduction of the posterior malleolus fracture, with a smooth articular surface. (D) Anteroposterior x-ray images taken 12 months after surgery showed bony healing of the posterior malleolus and lateral malleolus fractures with a smooth articular surface. MM = medial malleolus, PL = posterolateral fragment.

intra-articular fractures with relatively large bone fragments, and the fracture line extends along the coronal plane of the posterior margin of the tibia to the PC of the MM. This type of fracture is often associated with varying degrees of depression, comminution, and instability of the posterior portion of the tibia.^[18] Jiang et al^[19] believe that an anterior pilon fracture caused by dorsiflexion of the ankle is often not associated with lateral malleolus fractures. Therefore, posterior pilon fractures caused by plantar flexion of the ankle are usually associated with lateral malleolus fractures.

If the angle of plantar flexion of the ankle is small, the size of the posterior malleolus fracture fragment is large. Conversely, if the angle is large, the fragment is small and the degree of comminution and depression is greater. In the present study, 25 injuries were due to falls and traffic accidents, and the area of the fracture fragment was more than 25% of the entire articular surface. However, 8 patients were sports-related injuries, and the average area of the posterior malleolus fractures was 15.3% of the articular surface. When the MM is completely fractured, the fracture line of the lateral malleolus is relatively high, and the possible injury mechanism is that the foot was in a varus position

at the time of fracture. The force results in a transverse fracture or comminuted fracture of the lateral malleolus, while the backward impact of the talus on the MM results in a longitudinal fracture of the MM.^[20] The anterior inferior tibiofibular ligament is relatively thin, and torsional stress may result in an associated ligament tear or avulsion fracture.^[21] Posterior malleolus fractures caused by torsion at the time of a traditional trimalleolus fracture often represent small extra-articular Volkmann fractures.^[22] Zhang et al^[23] studied 18 patients of posterior pilon fractures, and found that the pathological feature was vertical and torsional forces focused on the posterior malleolus, and that this was different from trimalleolar fractures and pilon fractures.

An ideal fracture classification should suggest the injury mechanism, reflect the injury severity, guide treatment, and predict the prognosis. An ideal classification of posterior pilon fractures has yet to be developed. Wang et al^[18] classified posterior pilon fractures into types I and II according to the relationship between the fibular fracture line and the inferior tibiofibular ligament. In type I fractures, the fracture line is located superior to the infra-tibiofibular syndesmosis, and there

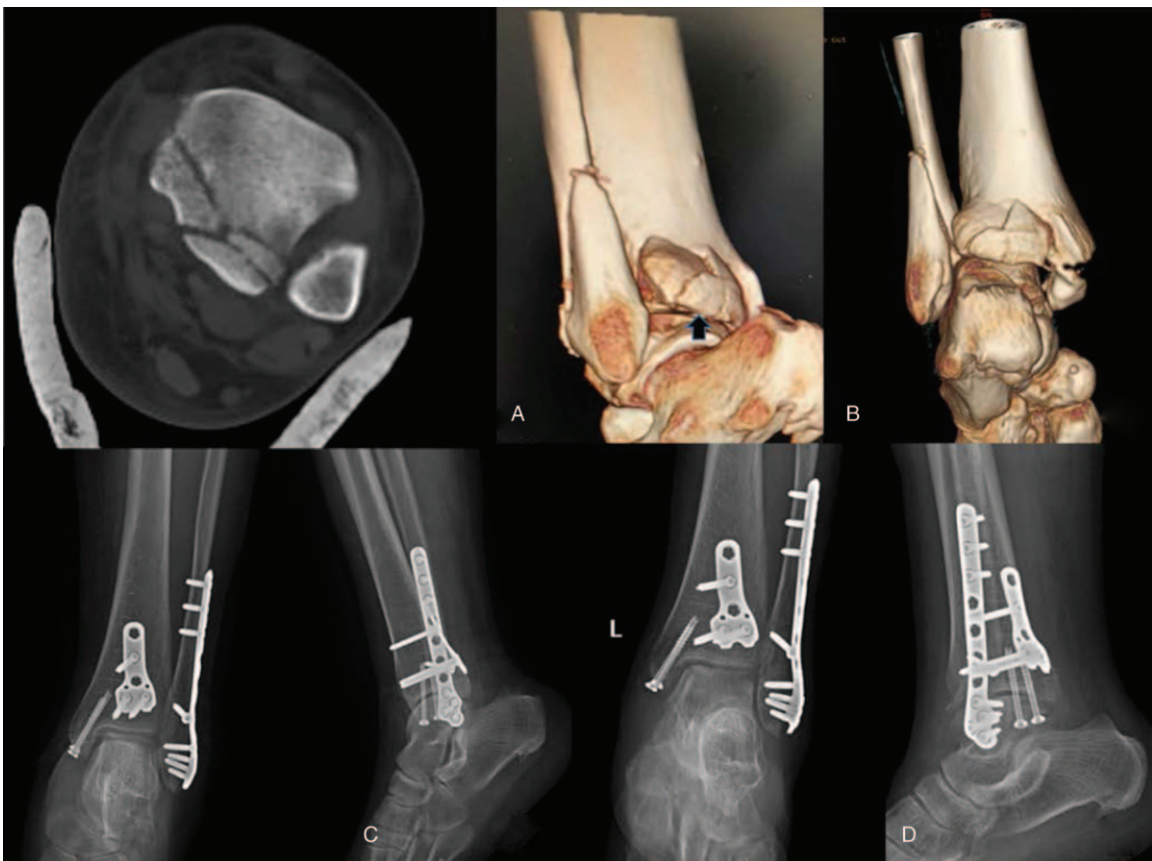


Figure 5. A 62-year-old female had a posterior pilon fracture due to a car accident. It was a type IIb fracture (a comminuted fracture). (A) Axial CT showed the comminuted posterior malleolus fracture. The posteromedial fracture line involved the MM. (B) CT 3D reconstruction showed the comminuted posterior malleolus fracture. The arrow indicates several fracture fragments of the posterior malleolus. (C) Reduction and buttress plate fixation were carried out via a combined posteromedial and posterolateral approach. The postoperative anteroposterior x-ray image showed reduction of the posterior malleolus fracture with a smooth articular surface. (D) Anteroposterior x-ray images taken 12 months after surgery showed bony healing of the posterior malleolus and lateral malleolus fractures, with a smooth articular surface. MM = medial malleolus.

is no connection between the medial fracture fragment of the posterior malleolus and the AC fracture fragment of the MM. In type II fractures, the fracture line is located on the same level of the infra-tibiofibular syndesmosis, and there is a connection between the medial fracture fragment of the posterior malleolus and the fracture fragment of the MM. This classification is suitable for evaluating the stability of the infra-tibiofibular syndesmosis, but it does not reflect the mechanism of injury or fracture morphology, or guide treatment or predict prognosis.

Yu et al^[8,24] developed their fracture classification system based on cross-sectional CT images. A type I fracture is defined as an avulsion fracture with a large fragment from the posterolateral Volkmann tubercle, which may be easily confused with the traditional trimalleolar fracture. A type II fracture is defined as a single posterior bone fragment with a transverse or arc-shaped fracture line extending to the posterior aspect of the MM. A type III fracture is defined as a fracture dividing the posterior malleolus into 2 parts (posteromedial part and posterolateral part). Yu et al suggested that torsional forces commonly result in type I fractures, and vertical force usually results in type II or type III fractures. This classification is not consistent with the agreement that posterior pilon fractures involve the entire coronal plane of the posterior malleolus, and type I fractures can be easily

confused with traditional trimalleolar fractures. Moreover, the classification does not take into account the MM fracture, and the severity of the posterior malleolus fracture.

Klammer et al^[9] proposed a classification system according to fracture morphology. These authors defined type I fracture as a long oblique fracture involving the entire posterior malleolus, with the base toward the posterolateral side. Type II is defined as a fracture dividing the posterior malleolus into a posteromedial part and a posterolateral part. Type III is defined as the posterior fragment involving the PC, or associated with a complete MM fracture. Although this classification system can assist in planning the surgical approach, it does not reflect the mechanism of injury and also does not include all fracture types. As an example, this method would not have classified the 4 patients in our study who had comminuted fractures of the posterior malleolus and the 4 patients with the posterior malleolus fracture line extending to the AC of the MM, and the anterior and PC as a complete bone fragment.

Using the classification systems developed by Yu et al^[8] and Klammer et al,^[9] as a basis, we developed a novel classification system of posterior pilon fractures according to injury mechanism and fracture morphology identified on CT cross-sectional images. Based on our proposed classification system, in our study 12 patients had type I fractures, and the posterolateral approach

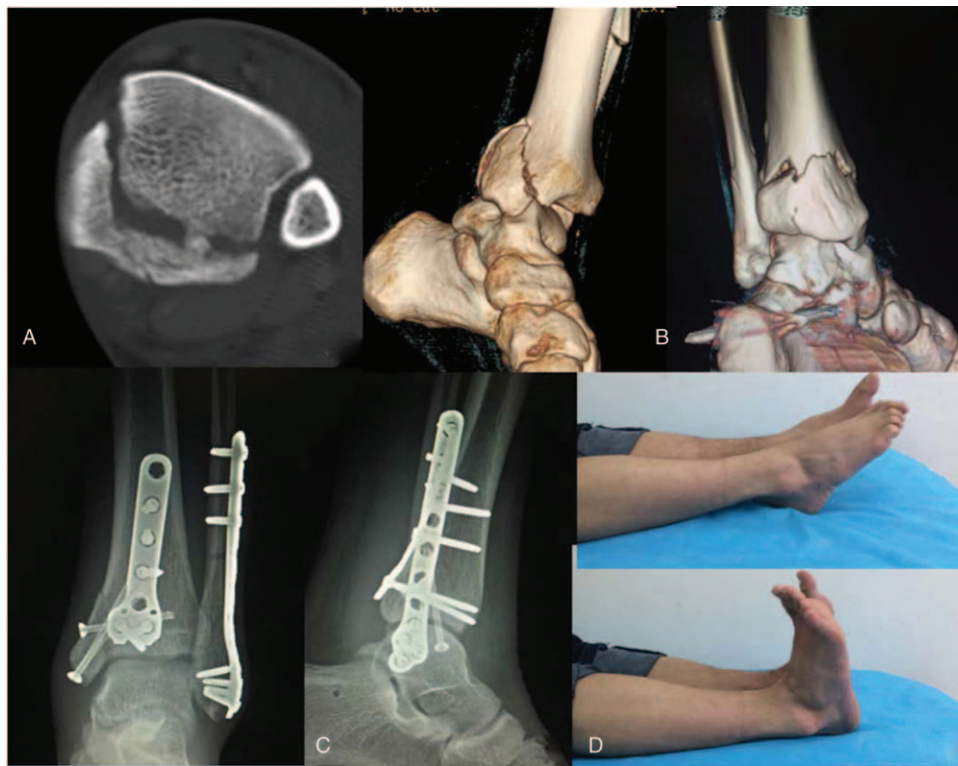

Figure 6. A 22-year-old male had a posterior pilon fracture due to a fall. It was a type IIIa fracture; the posterior malleolus fracture involved the AC of the MM, the MM fracture was a complete fracture, but the AC and PC were not separated. (A) Axial CT showed that the posterior malleolus fracture involved the AC of the MM, the fracture line was L-shaped, and there was a depressed die-punch fragment between the 2 fracture ends. (B). CT 3D reconstruction showed that the posterior malleolus fracture involved the AC of the MM. (C) Reduction and buttress plate fixation were carried out via a combined posterolateral and extended posteromedial approach. Postoperative anteroposterior x-ray images showed reduction of the posterior malleolus fracture with a smooth articular surface. (D) Twelve months after surgery, the affected ankle showed satisfactory functional recovery. AC = anterior colliculus, MM = medial malleolus, PC = posterior colliculus.

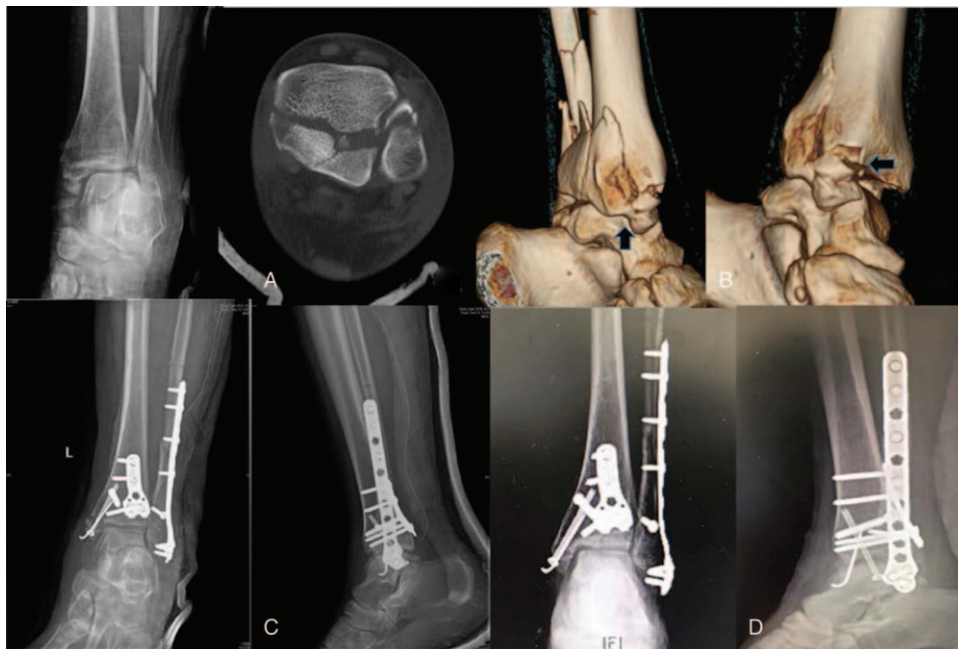


Figure 7. A 32-year-old female had a posterior pilon fracture due to falling. It was a type IIIb fracture; the posterior malleolus fracture line involved the intercollicular groove, there was an avulsion fracture of the AC, and the AC was separated from the PC. (A) The preoperative anteroposterior X-ray image and CT axial image showed fracture dislocation of the ankle joint and transverse fracture of the posterior malleolus, the posteromedial fracture involved the PC of the MM, and there was an MM fracture. (B) CT 3D reconstruction showed that the posterior malleolus fracture involved the PC (the black arrow indicates the avulsion fracture of the AC). (C) Reduction and buttress plate fixation were carried out via a combined posterolateral and extended posteromedial approach. The MM was fixed with a K-wire. Postoperative anteroposterior X-ray image showed reduction of the posterior malleolus fracture with a smooth articular surface. (D) Anteroposterior X-ray image taken 12 months after surgery showed bony healing of the posterior malleolus and lateral malleolus fractures with a smooth articular surface. AC = anterior colliculus, MM = medial malleolus, PC = posterior colliculus.

was applied and sufficient exposure of the fracture site was obtained. Ten patients had type IIa fractures and 4 had type IIb fractures. The combined posterolateral and posteromedial approach provided sufficient exposure, and reduction and fixation were performed under direct vision. Finally, 6 patients had type IIIa fractures and 4 had type IIIb fractures.

There are a number of limitations of the current study. It is a retrospective study, and patient selection bias is inevitable. Although we chose the time interval to be as long as possible, the incidence of the posterior pilon fractures is low, and there have been no large studies to provide a parallel control group.^[25,26] The small number of patients also limits the reliability of our classification method. Even though we described 4 features of the posterior pilon fractures, we did not take into account the impact of the ligament injury on the stability of the ankle joint. The classification method was based on clinical findings, and further biomechanical studies should be performed to examine these methods.

5. Conclusion

Posterior pilon fractures have unique pathological features and clinical findings. The posterior malleolus fracture fragment is related to the degree of plantar flexion of the ankle joint at the time of injury, the posteromedial fracture morphology is related to the degree of inversion of the foot, and the degree of fracture displacement is related to the degree of internal rotation of the foot. The proposed classification method based on injury mechanism and fracture morphology can help guide the surgical approach to maximize treatment outcomes.

Author contributions

Conceptualization: Jianzheng Zhang, Jixin Ren, Zhi Liu, and Tian-sheng Sun.

Data curation: Jianzheng Zhang, Hao Wang, Cheng Pen, Wen-chun Qu, Lianhua Li, Zhi Liu, and Tian-sheng Sun.

Formal analysis: Hao Wang and Cheng Pen.

Investigation: Jixin Ren.

Methodology: Jianzheng Zhang and Lida Duan.

Resources: Wen-chun Qu.

Writing – original draft: Jianzheng Zhang and Tian-sheng Sun.

Writing – review & editing: Jianzheng Zhang, Lida Duan, Lianhua Li, Zhi Liu, and Tian-sheng Sun.

References

- [1] Chen DW, Li B, Yang YF, et al. Posterior pilon fractures. *Foot Ankle Int* 2013;34:766–7.
- [2] Topliss CJ, Jackson M, Atkins RM. Anatomy of pilon fractures of the distal tibia. *J Bone Joint Surg Br* 2005;87:692–7.
- [3] Huber M, Stutz PM, Gerber C. Open reduction and internal fixation of the posterior malleolus with a posterior antiglide plate using a posterolateral approach— a preliminary report. *Foot Ankle Surg* 1996;2:95–103.
- [4] Hansen S. *Functional Reconstruction of the Foot and Ankle*. 2000; Lippincott Williams & Wilkins, Philadelphia PA:37–46.
- [5] Amorosa LF, Brown GD, Greisberg JA. Surgical approach to posterior pilon fractures. *J Orthop Trauma* 2010;24:188–93.
- [6] Liu J, Smith CD, White E, et al. A systematic review of the role of surgical approaches on the outcomes of the tibia pilon fracture. *Foot Ankle Spec* 2016;9:163–8.
- [7] Tang X, Tang PF, Wang MY, et al. Pilon fractures: a new classification and therapeutic strategies. *Chin Med J (Engl)* 2012;125:2487–92.
- [8] Yu GF, Ma JT, Yu M, et al. Clinical observation of characteristic and treatment of posterior pilon fractures. *Zhongguo Gu Shang* 2015;28:527–30. [Article in Chinese].
- [9] Klammer G, Kadakia AR, Joos DA, et al. Posterior pilon fractures: a retrospective case series and proposed classification system. *Foot Ankle Int* 2013;34:189–99.
- [10] Burwell HN, Charnley AD. The treatment of displaced fractures at the ankle by rigid internal fixation and early joint movement. *J Bone Joint Surg Br* 1965;47:634–60.
- [11] Beaman DN, Gellman R. Fracture reduction and primary ankle arthrodesis: a reliable approach for severely comminuted tibial pilon fracture. *Clin Orthop Relat Res* 2014;472:3823–34.
- [12] Gardner MJ, Streubel PN, McCormick JJ, et al. Surgeon practices regarding operative treatment of posterior malleolus fractures. *Foot Ankle Int* 2011;32:385–93.
- [13] Leonetti D, Tigani D. Pilon fractures: a new classification system based on CT-scan. *Injury* 2017;48:2311–7.
- [14] Huber M, Stutz PM, Gerber C. Open reduction and internal fixation of the posterior malleolus with a posterior antiglide plate using a posterolateral approach: a preliminary report. *Foot Ankle Surg* 2014;2:95–103.
- [15] Hong J, Dai F, Qiu C, et al. The relationship between morphological changes of ankle mortise and ankle function after pilon fracture surgery. *Chin J Orthop* 2012;32:471–6.
- [16] Haraguchi N, Haruyama H, Toga H, et al. Pathoanatomy of posterior malleolar fractures of the ankle. *J Bone Joint Surg Am* 2006;88:1085–92.
- [17] Lacasse JS, Laflamme M, Penner MJ. Irreducible fracture-dislocation of the ankle associated with interposition of the tibialis posterior tendon in the syndesmosis: a case report. *J Foot Ankle Surg* 2015;54:962–6.
- [18] Wang L, Shi ZM, Zhang CQ, et al. Trimalleolar fracture with involvement of the entire posterior plafond. *Foot Ankle Int* 2011; 32:774–81.
- [19] Jiang L, Zheng Q, Pan Z, et al. The summary of characteristics and treatment of Pilon fracture with intact fibula. *Chin J Orthop* 2015;36:96–102.
- [20] Wei SJ, Han F, Lan SH, et al. Surgical treatment of pilon fracture based on ankle position at the time of injury/initial direction of fracture displacement: a prospective cohort study. *Int J Surg* 2014;12:418–25.
- [21] McGoldrick NP, Murphy EP, Kearns SR. Single oblique incision for simultaneous open reduction and internal fixation of the posterior malleolus and anterior syndesmosis. *J Foot Ankle Surg* 2016;55:664–7.
- [22] Mingo-Robinet J, López-Durán L, Galeote JE, et al. Ankle fractures with posterior malleolar fragment: management and results. *J Foot Ankle Surg* 2011;50:141–5.
- [23] Zhang H, Chen J, Guan P, et al. Surgical treatment of posterior pilon fracture through the posteromedial approach. *Chin J Orthop Trauma* 2016;18:214–9.
- [24] Yu G, Chen D, Zhao H, et al. The effect of buttress plate fixation in the treatment of posterior pilon fractures. *Chin J Trauma* 2013;29: 243–8.
- [25] Macko VW, Matthews LS, Zwirkoski P, et al. The joint-contact area of the ankle. The contribution of the posterior malleolus. *J Bone Joint Surg Am* 1991;73:347–51.
- [26] Odak S, Ahluwalia R, Unnikrishnan P, et al. Management of posterior malleolar fractures: a systematic review. *J Bone Joint Surg Am* 2016; 55:140–5.