

In-One-Continuity Rectal Excision and Anal Mucosectomy of a Giant Villous Adenoma: An Alternative Surgical Approach

G.G. Koning^a P.L. Rensma^b A.W.M. van Milligen de Wit^c
C.J.H.M. van Laarhoven^a

Departments of ^aSurgery and ^bInternal Medicine, Saint Elisabeth Hospital, Tilburg, and ^cDepartment of Gastroenterology, Amphia Hospital, Breda, The Netherlands

Key Words

Rectal villous adenoma · Rectal surgery · Renal failure · Dehydration · Electrolyte disorders · McKittrick-Wheelock syndrome

Abstract

Background: The authors present a woman suffering from McKittrick-Wheelock syndrome (MKWS) with a giant rectal villous adenoma. MKWS is a rare disorder caused by fluid and electrolyte hypersecretion from a rectal tumor. The most frequently reported tumors are villous adenomas. Symptoms of dehydration with severe hyponatremia, hypokalemia, metabolic acidosis and acute renal failure are typical in MKWS. Several options for operation have been reported, such as a transsacral approach (according to Kraske), transanal endoscopic microsurgery (TEM) or total mesorectal excision (TME). In this case we report an alternative surgical approach: in-one-continuity transanal mucosectomy and transabdominal TME with a handsewn colonic-anal anastomosis.

Case: A 54-year-old woman had a history of hospital admissions because of repeated bouts of dehydration with electrolyte disorders since 2004. At admission she presented with prerenal azotemia, hyponatremia and severe hypokalemia in combination with watery stools. At colonoscopy an 8-cm villous adenoma was seen in the rectum. Dehydration and electrolyte disturbances were treated by appropriate intravenous fluid administration. An in-one-continuity anal mucosectomy and complete rectal excision were performed and restored by a handmade colonic-anal anastomosis. Postoperative recovery was uneventful.

Conclusion: MKWS can be a difficult problem to assess in both gastroenterological and nephrological ways. Patients may develop severe complications which require surgical intervention in some cases. In-one-continuity transanal mucosectomy and rectum excision with a handmade colonic-anal anastomosis seemed to be a new and solid surgical therapeutic option in this case.

Introduction

Patients with colonic adenomatous polyps show unspecific symptoms in most cases or may even be asymptomatic. The most cardinal symptom which can be attributed to colonic polyps or tumors and which requires colonoscopic survey is rectal bleeding. Patients with villous adenomas rarely exhibit secretory diarrhea accompanied by considerable loss of fluids and electrolytes resulting in renal failure, which may prove fatal in some cases of McKittrick-Wheelock syndrome (MKWS). Tumors causing MKWS are localized at the rectum or sigmoid and are large in diameter (>3 cm).

Case Report

We present the case of a 54-year-old woman. Her symptoms were rectal bleeding, frequent defecations (>4 stools/24 h) accompanied by low abdominal pains, nausea and vomiting. She had a medical history of repeated hospital admissions because of collapse inclinations, dehydration and disorders in electrolyte levels since 2004. So far, renal disorders and cardiovascular pathology had been excluded by thorough analysis.

At physical examination there was no fever, she was hemodynamically stable but dehydrated and had a distended abdomen. On manual rectal investigation there was a large soft tumor palpable starting 1 cm from the anal ring. Laboratory investigations showed prerenal uremia, hyponatremia and severe hypokalemia ([table 1](#)). Colonoscopy revealed a villous adenoma in the rectum with a diameter of 8 × 15 cm ([fig. 1](#)). Apart from this finding, the rest of the colon had a normal endoscopic aspect. Multiple biopsies were taken from the rectal tumor and areas of low-grade dysplasia were assessed during histopathological analysis ([fig. 2](#)). The final diagnosis was secretory villous adenoma of the rectum with low-grade dysplasia causing MKWS, frequent defecation, dehydration, renal disorders, electrolyte inconvenience and collapse. The patient recovered temporarily on substitution therapy of electrolytes and fluids and required surgical intervention.

Options for treatment were endoscopic resection of the tumor or open surgery such as a transsacral approach (according to Kraske), transanal endoscopic microsurgery (TEM) or total mesorectal excision (TME). Based on the explicit findings of merely low-grade dysplasia of the tumor, sphincter-preserving surgery was chosen as a safe option to treat this patient. Because of the location up to the dentate line, a TEM procedure was considered impossible. Therefore a transanal mucosectomy and TME with a handmade colonic-anal anastomosis was performed ([fig. 3](#)), completed with a temporary loop ileostomy implementation on the abdomen.

Postsurgical recovery was uneventful. However the hypokalemia, which had been diagnosed on the first day of admission, did not respond to the treatment immediately after surgery. A feasible explanation could be exhaustion of intracellular potassium levels. It improved after administration of spironolactone. The patient recovered very well from surgery, the stoma was productive and she was discharged in good physical condition. After three months the ileostomy was closed in one successful surgical session. A complete recovery was achieved.

Discussion

Our patient was finally diagnosed with MKWS after repeated hospital admissions for analysis of collapse and renal dysfunction of unknown origin since 2004. This case is interesting from both medical as well as surgical points of view. This patient's symptoms gratify the diagnostic findings of MKWS. As described, low abdominal pains, nausea and vomiting in combination with severe electrolyte and fluid depletion and the presence of a large (>3 cm) rectal villous adenoma confirmed our hypothesis. Laboratory findings ([table 1](#)) revealed hyponatremia, hypokalemia, hypochloremia, metabolic acidosis and dehydration leading to acute prerenal failure. The large villous adenoma was in accordance with intestinal secretion of water, sodium and potassium, induced by prostaglandin E₂. The distal localisation of the tumor precluded corrective reabsorption

of fluid and electrolytes by the colonic mucosa. Clinical studies showed a decrease in prostaglandin E2 levels after indomethacin and somatostatin were subscribed, resulting in amelioration of MKWS [1, 2]. Villous adenomas left untreated may show a mortality of 100% [3]. Therapy includes electrolyte rebalancing, endocavitary irradiation (in malignant tumors), endoscopic resection or surgical removal of the tumor. Electrolyte rebalancing is a cardinal step before curative therapy [4, 5]. In our case this rebalancing process of electrolytes was watched closely and even after surgery sodium and potassium had to be administered for several days until normal ranges were achieved.

Our surgical decision-making included several thoughts: firstly the low distal localisation up to the dentate line of the tumor in the rectum and its size of 8 × 15 cm, secondly the benign aspect of the villous adenoma, and thirdly the histopathological findings of low-grade dysplasia. Our surgical options were TEM, transsacral resection according to Kraske's approach [6], and further there was the option for a transabdominal rectal amputation or a suprasphincteric resection of the tumor. In our patient we chose to perform an alternative surgical option: in-one-continuity transanal mucosectomy and rectum excision with a handsewn colonic-anal anastomosis (fig. 3). The anal sphincter was spared and the other benefit of this therapy is the complete removal of the tumor. This was followed by normalisation of sodium and potassium levels due to the elimination of abnormal prostaglandin E2 secretion. The patient recovered very well from surgery, the stoma was productive and she was discharged in a good physical condition. After three months the ileostomy was abrogated in one successful surgical procedure and complete recovery was achieved.

In conclusion, MKWS can be a difficult problem to assess in both gastroenterological and nephrological ways. Patients may develop severe complications which require surgical intervention in some cases. In-one-continuity transanal mucosectomy and rectum excision in combination with a handmade colonic-anal anastomosis can be regarded as a new and safe surgical option for this problem.

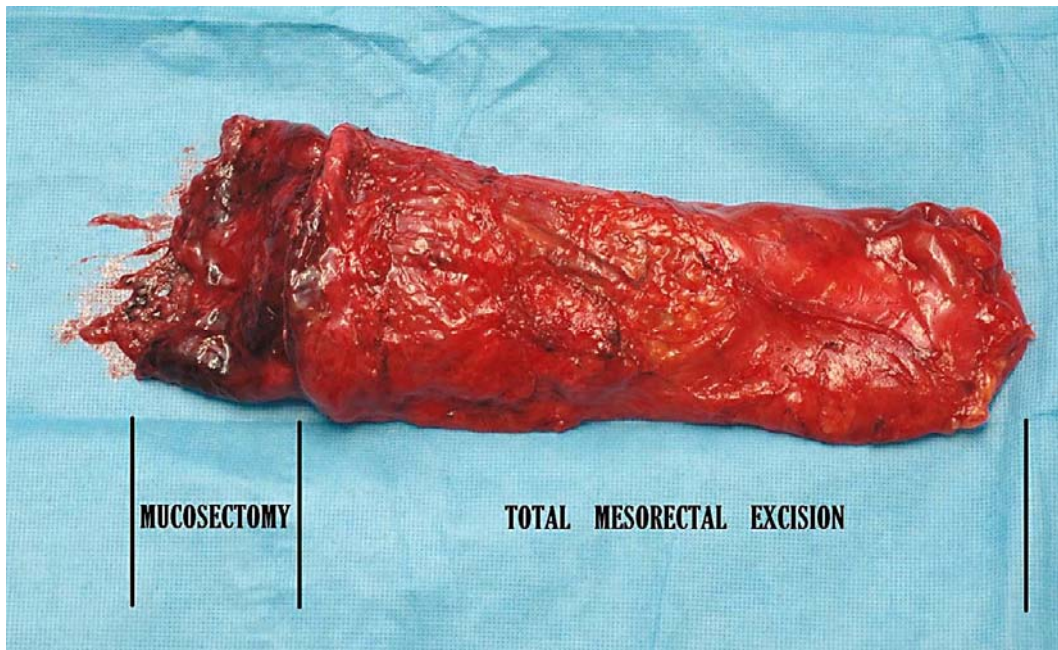
Acknowledgement

The authors would like to thank the Department of Pathology at the St. Elisabeth Hospital for providing the histopathological findings on film.

Table 1. Laboratory findings

Electrolyte	Laboratory result	Normal value
Ureum, mmol/l	50.9	3.0–7.0
Potassium, mmol/l	2.8	3.5–5.1
Sodium, mmol/l	117	136–145
Creatinine, μmol/l	694	45–80

Fig. 3. Surgical specimen of combined transanal mucosectomy and rectum excision of the giant villous adenoma.



References

- 1 Steven K, Lange P, Bukhave K, Rask-Madsen J: Prostaglandin E2-mediated secretory diarrhea in villous adenoma of rectum: effect of treatment with indomethacin. *Gastroenterology* 1981;80:1562–1566.
- 2 Smelt AH, Meinders AE, Hoekman K, Noort WA, Keirse MJ: Secretory diarrhea in villous adenoma of the rectum: effect of treatment with somatostatin and indomethacin. *Prostaglandins* 1992;43:567–572.
- 3 Emrich J, Niemeyer C: The secreting villous adenoma as a rare cause of renal failure (in German). *Med Klin (Munich)* 2002;97:619–623.
- 4 Popescu A, Orban-Schiopu AM, Becheanu G, Diculescu M: McKittrick-Wheelock syndrome – a rare cause of acute renal failure. *Rom J Gastroenterol* 2005;14:63–66.
- 5 Acute G, Gričiute L, Tamosaitis A, Grazulis S: Renal failure due to a villous adenoma. *Medicina (Kaunas)* 2003;39(suppl 1):48–50.
- 6 Christiansen J: Excision of mid-rectal lesions by the Kraske sacral approach. *Br J Surg* 1980;67:651–652.