

Outcome of Adenotonsillar Specimen Histology in a Private Hospital Setting

Waheed Atilade Adegbiyi, Shuaib Kayode Aremu¹, Akindele Abdurrazaq Oladipo²

Department of ENT, Ekiti State University Teaching Hospital, ¹Department of ENT, Federal Teaching Hospital Ido-Ekiti/Afe Babalola University, Ado-Ekiti, Ekiti State, ²Department of Anaesthesia, Lagos School of Anaesthetic Studies, General Hospital, Lagos, Nigeria

Abstract

Background: All adenoid and tonsils tissue specimens are routinely histologically examined in pediatric otorhinolaryngology practice worldwide. This study aimed at determining the sociodemographic features, clinical presentation, indications, postoperative management, and histological diagnosis of the adenoid and tonsils tissues. **Materials and Methods:** This is a retrospective hospital-based study of patients who had adenotonsillectomy done between August 2008 and July 2018 at Golden Cross Infirmary Hospital, Festac Town, Lagos, Nigeria. All data were obtained from the patients' record, case note, and theater operation register. All the data obtained were collated and analyzed using SPSS version 18.0. **Results:** There were 59.2% of males with a male-to-female ratio of 1.5:1. Clinical presentation among the pediatric patients was 71.8% difficulty breathing, 64.8% snoring, 63.4% sleep apnea, 60.6% catarrh, and 54.9% noisy breathing. The most common indications for adenoid and tonsils surgery were obstructive sleep apnea in 64.8%. Adenoidectomy in 42.3% was the most common form of pediatric adenoid and tonsils surgery. The most common complication of adenoid and tonsils surgery was pain at surgical site/odynophagia in all the patients. Postoperative histological reports were reactive lymphoid hyperplasia in all the patients. **Conclusion:** Adenoid and tonsils surgeries are common pediatric otorhinolaryngology, head-and-neck surgical procedures. The most common indication found for adenoid and tonsils surgery was obstructive sleep. Adenoidectomy was the most common form of pediatric adenoid and tonsils surgery. All the adenoid and tonsils tissue specimens revealed histological benign diseases.

Keywords: Adenoid, adenoidectomy, histology, tonsillectomy, tonsils

INTRODUCTION

Adenotonsillectomy is the surgical removal of both adenoid and tonsils.^{1,2} Adenoidectomy is defined when only nasopharyngeal tonsils (adenoid) are excised. Tonsillectomy is also defined when only palatine tonsils (tonsils) are excised.

This is one of the most common pediatric otorhinolaryngology, head-and-neck surgical procedures in the ear, nose, throat, and head and neck practice worldwide.³

Major indications for adenotonsillectomy in children include recurrent or chronic infections and obstructive adenoid with obstructive sleep apnea syndrome.⁴ Other indications include peritonsillar abscess and impacted the tonsillar foreign body. Uncommon reasons for adenotonsillectomy in children are unilateral tonsillar enlargement and ulcerative tonsillar lesion for biopsy.⁵⁻⁸ The obtained specimen is sent for histological diagnosis to exclude the malignancy. In all surgical practices,

every biopsy tissue specimen is evaluated by the pathologist to determine the histologic diagnosis, and adenotonsillar tissue specimens are not excluded.^{9,10} These tissue specimens are examined histologically to rule out a deadly disease like malignancy and tuberculosis which are usually missed during the clinical assessment. This is for the early diagnosis with appropriate treatment and to avoid litigation.

There is controversy on the mandatory adenotonsillar tissue specimen histologic evaluation in children. Adenoidectomy and tonsillectomy are performed secondary to inflammation/

Address for correspondence: Dr. Shuaib Kayode Aremu,
Department of ENT, Federal Teaching Hospital, Afe Babalola University,
Ido-Ekiti, Nigeria.
E-mail: shuaib.arem@gmail.com

Submission: 26-May-2019 **Revision:** 14-Jul-2019
Acceptance: 04-Sep-2019 **Publication:** 26-Nov-2019

This is an open access journal, and articles are distributed under the terms of the Creative Commons Attribution-NonCommercial-ShareAlike 4.0 License, which allows others to remix, tweak, and build upon the work non-commercially, as long as appropriate credit is given and the new creations are licensed under the identical terms.

For reprints contact: reprints@medknow.com

How to cite this article: Adegbiyi WA, Aremu SK, Oladipo AA. Outcome of adenotonsillar specimen histology in a private hospital setting. Niger Med J 2019;60:234-7.

Access this article online

Quick Response Code:



Website:
www.nigeriamedj.com

DOI:
10.4103/nmj.NMJ_71_19

infection in children, not malignancy as in some adult cases.^{11,12} This is assumed to be a waste of money in low-income resource countries like ours. It is also waste to funding the surgical management of adenoid and tonsils disorders in children.¹³

There is a paucity of literature on adenoid and tonsils specimens' tissue histological diagnosis in developing countries and private hospital practice in particular. This study aimed at determining the sociodemographic features, clinical presentation, indications for adenoid and tonsil surgeries, postoperative management, and histological diagnosis of the adenoid and tonsils tissues in Golden Cross Infirmiry Hospital, Festac Town, Lagos, Nigeria.

MATERIALS AND METHODS

This was a retrospective hospital-based study which was carried out on the hospital records of patients who had adenotonsillectomy over a period of 10 years (between August 2008 and July 2018) at Golden Cross Infirmiry Hospital, Festac Town, Lagos, Nigeria.

All the hospital patients' record, case note, and patients' register including theater operation register were used.

Data obtained included patients' biodata: age, sex, and other sociodemographic features, indications for adenotonsillectomy, and histologic diagnosis of the tissue specimen.

Adenoidectomy or tonsillectomy was done for all patients using "cold steel" dissection in our operating theater, under general anesthesia through endotracheal intubation, under the aseptic situation, with hemostasis sustained. The obtained surgical adenoid and tonsils tissue specimens were immediately fixed in 10% formaldehyde. The tissue specimens were sent to the pathologist within 24 h for histological processing and analysis. The specimens were then embedded in paraffin and cut into thin sections of about 2–3 µm with a microtome and stained routinely with hematoxylin and eosin using standard operating procedures that apply to the Nigerian laboratories that are ISO compliant. All the slides were carefully viewed under light microscopy by the same pathologists. The hospital laboratory expertise was maintained, and the WHO classification of tumors was used for malignant cases.

All the data obtained were collated and analyzed using the SPSS Version 18.0 (IBM Corp. Released 2018. IBM SPSS Statistics for Windows, Version 25.0. Armonk, NY: IBM Corp.). All the data results were presented and expressed in percentage, frequency tables, bar chart, and pie chart.

RESULTS

A total of 71 patients had adenoid and tonsils surgery done over the studied period.

The most common prevalence value was 47 (67.6%) at the age group of 1–5 years and this is followed by 12 (16.9%) at the age group of 6–10 years. Figure 1 demonstrates the age distribution of the patients.

There were 42 (59.2%) males and 29 (40.8%) females with a male-to-female ratio of 1.5:1. Majority (61; 85.9%) of the

patients resided in the city, whereas the remaining 8 (11.3%) and 2 (2.8%) resided in town and village, respectively. Table 1 illustrates the sociodemographic features of the patients.

Clinical presentation among the pediatric patients was 51 (71.8%) difficulty breathing, 48 (64.8%) snoring, 45 (63.4%) sleep apnea, 43 (60.6%) catarrh, and 39 (54.9%) noisy breathing. Table 2 shows the clinical presentation among the patients.

The most common indication for adenoid and tonsils surgery was obstructive sleep apnea in 46 (64.8%). This was followed by 14 (19.7%) recurrent tonsillitis and 6 (8.5%) otitis media. Table 3 shows the indications for adenotonsillectomy among the patients.

In this study, adenoidectomy in 30 (42.3%) was the most common form of pediatric adenotonsillar surgery. Others included tonsillectomy in 24 (33.8%) and adenotonsillectomy in 17 (23.9%). Figure 2 illustrates the types of adenotonsillectomy among the patients.

The most common complication of adenoid and tonsils surgery in this study was pain at surgical site/odynophagia in all the patients. Other encountered complications were 13 (18.3%) vomiting and 14 (19.7%) otalgia. Table 4 demonstrates the complications associated with adenotonsillectomy among the patients.

Postoperative management of adenoid and tonsils were conservative management, analgesic and histological reports of reactive lymphoid hyperplasia in all the patients. Antibiotics were administered on all our patients except one.

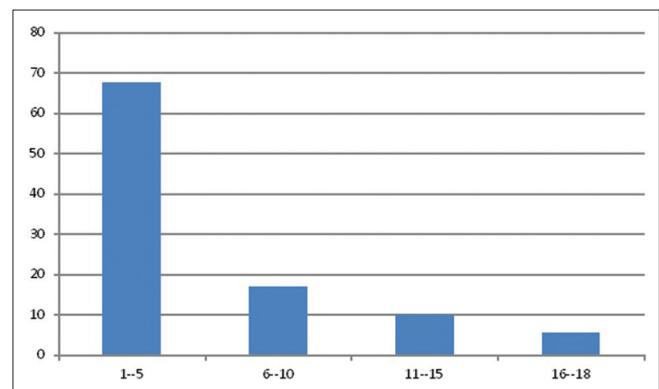


Figure 1: Age group distribution of the patients

Table 1: Sociodemographic features of the patients

Sociodemographic features	Number	Percentage
Sex		
Male	42	59.2
Female	29	40.8
Residential		
City	61	85.9
Town	8	11.3
Village	2	2.8

Table 2: Clinical presentation among the patients

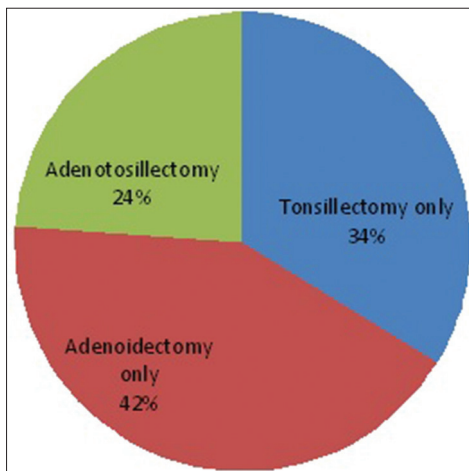
Clinical presentation	Number	Percentage
Difficulty breathing	51	71.8
Catarrh	43	60.6
Noisy breathing	39	54.9
Mouth breathing	26	36.6
Snoring	48	64.8
Sleep apnoea	45	63.4
Recurrent sore throat	16	22.5
Odynophagia	19	26.8
Fever	9	12.7

Table 3: Indication for adenotonsillectomy among the patients

Indication	Number	Percentage
Obstructive Sleep apnoea	46	64.8
Recurrent tonsillitis	14	19.7
Under weight	2	2.8
Otitis media	6	8.5
Quinsy	1	1.4
Persistent fever	2	2.8

Table 4: Complications associated with adenotonsillectomy among the patients

Complications	Number	Percentage
Pain at surgical site/odynophagia	71	100
Vomiting	13	18.3
Nasal regurgitation	3	4.2
Soft tissue injury	2	2.8
Otalgia	14	19.7
Haemorrhage	6	8.5

**Figure 2:** Types of adenotonsillectomy among the patients

DISCUSSION

Pediatric adenoid and tonsils surgery is a very common procedure in all pediatric age group as demonstrated in this study. The prevalence of this surgery is higher in the preschool

age group in our center. Similar prevalence in the children age group was reported in other studies in Nigeria.¹⁴

In this study, adenoidectomy, tonsillectomy, or both were performed in both males and females. The procedures are common in males than in females. Similar findings were reported in other studies.¹⁵

Injuries and infections rate is more common in males than in females. This may be due to male is more active and prone to injuries and infections as reported in other studies.^{1,2} As illustrated in this study, adenotonsillar surgeries are performed in all sociodemographic strata. Majority of the patients were city dwellers. This may be because the facility is located in the city. Accessibility and affordability are of greater advantage reported in the author's previous study.^{16,17}

In this study, all the clinical presentations of the studied patients were those of inflammatory and infective pathology. They were difficult breathing, snoring, obstructive sleep apnea, catarrh, and noisy breathing. These were not suspicious of neoplastic diseases in the children age group. This is similar to the report from a study in South-Southern Nigeria.¹¹

Detailed clinical evaluation of all the studied children does not give a pointer to childhood malignancy. The diagnoses revealed underground diseases from the various forms of pediatric inflammatory/infection diseases. Major diagnoses in this study were obstructive sleep apnea, recurrent tonsillitis, and otitis media. Other studies also reported similar findings in their studies.^{1,2}

All the children had different forms of adenoid and tonsils surgeries. The most common of which is adenoidectomy followed by tonsillectomy and adenotonsillectomy. These findings are similar to a report from another study in Nigeria.¹ Our findings during examination under anesthesia revealed no contact bleeding, well-encapsulated tonsils, some were fibrosed, and good hemostasis was achieved. These findings are not surprising as adenoid and tonsils malignancy are rare in children in the first decades in both sexes as documented in other studies.¹⁸⁻²¹

During intraoperative and postoperative care, our common encountered complications were pain at surgical site/odynophagia, referred otalgia, and vomiting. This was also reported in other studies.^{1,11} In this study, no mortality was recorded.

All the children had uneventful adequate postoperative care. They were managed on intravenous fluids and intravenous drug (antibiotic and analgesic). All patients were commenced on ice cream and cold fluid diet when fully awake. All the patients were discharged to ear, nose, and throat outpatient clinic between the 1st and 3rd postoperative days depending on the patients response to postoperative care. All the adenoid and tonsils specimens' tissue histological examination reported reactive lymphoid hyperplasia in this study as observed in previous studies.^{11-15,21}

CONCLUSION

Adenoid and tonsils surgeries are common pediatric otorhinolaryngology, head-and-neck surgical procedures. The most common indication found for adenoid and tonsils surgery was obstructive sleep. Adenoidectomy was the most common form of pediatric adenoid and tonsils surgery. The entire adenoid and tonsils tissue specimen revealed histologic benign diseases. It is a necessity that all adenoid and tonsils tissue specimens in children should only be subjected to routine histologic analysis in the presence of suspected malignancy.

Acknowledgment

We wish to thank all the staff of Golden Cross Infirmary hospital, Festac town, Lagos, Nigeria, that contribute to the development of this research.

Financial support and sponsorship

Nil.

Conflicts of interest

There are no conflicts of interest.

REFERENCES

1. Adegbiyi WA, Aremu SK, Aluko AA, Olubi O. Pattern of paediatric Adenoid and tonsillar surgery in Ekiti. *Int J Clin Med* 2018;9:841-53.
2. Adegbiyi WA, Aremu SK, Nwawolo CC, Asoegwu CN. Current trends of adenotonsillar hypertrophy presentation in a developing country, Nigeria. *Int J Otorhinolaryngol Head Neck Surg* 2017;3:501-5.
3. Guerra MM, Garcia E, Pilan RR, Rapoport PB, Campanholo CB, Martinelli EO, *et al.* Antibiotic use in post-adenotonsillectomy morbidity: A randomized prospective study. *Braz J Otorhinolaryngol* 2008;74:337-41.
4. Olusesi AD, Undie NB, Amodu JE. Allergy history as a predictor of early onset adenoids/adenotonsillar hypertrophy among Nigerian children. *Int J Pediatr Otorhinolaryngol* 2013;77:1032-5.
5. Ibekwe TS, Obasikene G, Offiong E. Tonsillectomy: Vasoconstrictive hydrolytic cold dissection method. *Afr J Paediatr Surg* 2013;10:150-3.
6. Gaultier C, Guilleminault C. Genetics, control of breathing, and sleep-disordered breathing: A review. *Sleep Med* 2001;2:281-95.
7. Alho OP, Koivunen P, Penna T, Teppo H, Koskela M, Luotonen J, *et al.* Tonsillectomy versus watchful waiting in recurrent streptococcal pharyngitis in adults: Randomised controlled trial. *BMJ* 2007;334:939.
8. Karaman M, Tek A, Tuncel A, Oysu C, Sheidaei S. Adult tonsillectomy: Relationship between indications and postoperative hemorrhage. *Kulak Burun Bogaz Ihtis Derg* 2012;22:21-5.
9. Dell'Aringa AR, Juarez AJ, Melo Cd, Nardi JC, Kobari K, Perches Filho RM. Histological analysis of tonsillectomy and adenoidectomy specimens – January 2001 to May 2003. *Braz J Otorhinolaryngol* 2005;71:18-22.
10. Felipe F, Gomes GA, de Souza BP, Cardoso GA, Tomita S. Evaluation of the utility of histopathologic exam as a routine in tonsillectomies. *Braz J Otorhinolaryngol* 2006;72:252-5.
11. Ibekwe MU, Onotai LO. Routine histopathologic evaluation of adenoidectomy/or tonsillectomy specimens in Nigerian children: How relevant? *J Med Med Sci* 2012;3:179-83.
12. Rebechi G, Pontes TE, Braga EL, Matos WM, Rebechi F, Matsuyama C, *et al.* Are histologic studies of adenotonsillectomy really necessary? *Int Arch Otorhinolaryngol* 2013;17:387-9.
13. Adoga AS, Ma An DN, Nuhu SI. Is routine histopathology of tonsil specimen necessary? *Afr J Paediatr Surg* 2011;8:283-5.
14. Adeyemo A, Okolo C, Ogunkeyede S. Evaluation of histopathology examination of routine tonsillectomy and adenoidectomy specimens in developing countries. *J Pediatr Sci* 2011;3:e96.
15. Sushna M, Puja N, Ramesh P. Histopathological examination of routine tonsil or adenoid specimens in a tertiary care centre of Nepal: Evaluation of its necessity and cost-benefit rate analysis. *Glob J Oto* 2017;8:555733.
16. Adegbiyi WA, Olajide GT, Aremu SK, Alabi SB. Barriers to adenoid and tonsil Surgeries in Ekiti, Nigeria. *Am J Med Med Sci* 2017;7:385-92.
17. Adegbiyi WA, Aremu SK, Lasisi AO. Patients barrier to ear, nose, and throat surgical care in Nigeria. *Am Sci Res J Eng Technol Sci* 2017;32:96-104.
18. Parker NP, Walner DL. Trends in the indications for pediatric tonsillectomy or adenotonsillectomy. *Int J Pediatr Otorhinolaryngol* 2011;75:282-5.
19. Thorp MA, Isaacs S, Sellars SL. Tonsillectomy and tonsillitis in cape town – Age and sex of patients. *S Afr J Surg* 2000;38:62-4.
20. Sadeghi-Shabestari M, Jabbari Moghaddam Y, Ghaharri H. Is there any correlation between allergy and adenotonsillar tissue hypertrophy? *Int J Pediatr Otorhinolaryngol* 2011;75:589-91.
21. Mohamad I, Hassan S, Salim R. The routine histopathological examination of tonsillectomy specimens at hospital Universiti Sains Malaysia – A retrospective study and its implication. *Malays J Med Sci* 2007;14:53-5.