

# Delayed manifestation of extensive COVID-19-associated coagulopathy in high-risk patient

Purva Sharma,<sup>1</sup> Kanishka Chakraborty<sup>2</sup>

<sup>1</sup>Medical Oncology, East Tennessee State University, Johnson City, Tennessee, USA  
<sup>2</sup>Internal Medicine, East Tennessee State University, Johnson City, Tennessee, USA

**Correspondence to**  
 Dr Kanishka Chakraborty;  
 chakrabk@etsu.edu

Accepted 7 May 2021

## SUMMARY

COVID-19 is an infectious disease caused by the novel coronavirus. It presents as an acute respiratory illness, however, it also affects multiple other organ systems. One such unique manifestation is systemic coagulopathy involving arterial and venous systems. We present a 29-year-old woman with Hodgkin's lymphoma, who was diagnosed with COVID-19 infection prior to initiating chemotherapy. Two months after resolution of symptoms and testing negative for COVID-19, she presented with multiple acute thromboembolic complications of the infection, including bilateral jugular venous thrombosis, right atrial clot and arterial emboli in the brain resulting in cerebrovascular injury. These were thought to be delayed manifestations of the systemic coagulopathy secondary to infection. Also, some of these thromboembolic phenomena occurred while the patient was on anticoagulation, which emphasises the extensive hyperinflammatory state caused by the virus. This case highlights the importance of thromboprophylaxis especially in high-risk patients with this infection.

## BACKGROUND

COVID-19 manifests as an acute respiratory distress syndrome due to acute systemic inflammatory response. Apart from the lung injury, severe systemic coagulopathy and acquired thrombophilia with arterial, venous and microvascular thrombosis have been reported in a majority of cases.

We present to you an intriguing case of a young woman with recent diagnosis of Hodgkin's lymphoma on chemotherapy, who was infected with COVID-19 prior to starting treatment and showed delayed manifestation of the infection with extensive coagulopathy weeks after resolution of infection.

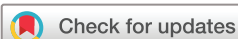## CASE PRESENTATION

A 29-year-old woman with recent diagnosis of classical Hodgkin's lymphoma, nodular sclerosis type on active treatment with chemotherapy presented to the hospital with syncopal episode and headaches. Patient was receiving standard of care treatment for stage II unfavourable disease with ABVD (adriamycin/bleomycin/vinblastine/dacarbazine) chemotherapy regimen. She was on Cycle 2 day 12 at the time of presentation. She did not receive any radiation treatment. Physical examination on presentation was significant for increased neck circumference due to body habitus, along with truncal obesity. Patient also had right-sided port in place for chemotherapy access. Pulmonary embolism was ruled out. Initial central nervous system

imaging including CT head without contrast due to renal injury as well as MRI brain was unremarkable. Ultrasound of neck was performed due to increasing neck swelling, which showed no carotid stenosis, however, incidental finding of thrombosis of bilateral internal jugular veins was noted. Patient was immediately started on anticoagulation with heparin per venous thromboembolism (VTE) protocol at 18 U/kg/hour with close monitoring of Factor Xa level. Due to persistent headaches, MRI brain was repeated with contrast the next day and showed acute infarction in the left frontal cortex as well as small punctate infarcts in the right caudate nucleus, left lentiform nucleus and left posterior parietal lobe suggesting an embolic phenomenon (figure 1). This was while patient was on anticoagulation. CT angiography of the head also confirmed the findings of the MRI. Of note, CT angiography of neck was a suboptimal study due to artefact related to patient's body habitus. 2D transthoracic echocardiogram with bubble study was attempted, which was a poor study. MR venography was performed after 2 days, which was unremarkable. This was followed by a transoesophageal echocardiogram, which showed a large right atrial clot (figure 2). It did not demonstrate a patent foramen ovale, thus ruling out paradoxical embolus. Inflammatory markers were also tested during this period and were found to be elevated—d-dimer 947 ng/mL, C reactive protein 161 mg/L. Fibrinogen was 463 mg/dL. Of note, patient tested positive for COVID-19 2 months prior to this presentation with PCR testing of nasal swab specimen. Patient had reports of fatigue, loss of appetite, arthralgia and myalgia during COVID-19 infection, however, had no acute respiratory distress. She did not require hospitalisation or supplemental oxygen. Patient did not undergo any other workup or testing. Repeated COVID-19 testing 3 weeks after initial test was negative.

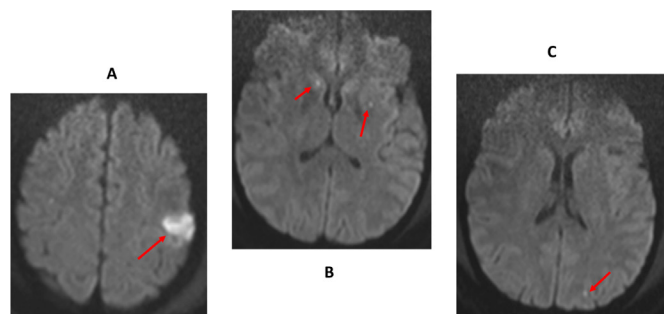
## DIFFERENTIAL DIAGNOSIS

Patient likely had extensive coagulopathy secondary to previous COVID-19 infection. Patient had delayed manifestation of this complication as the first evidence of coagulopathy was after almost 10 weeks of testing positive for the infection. It is also fascinating to see that the patient developed new arterial thrombi while she was on anticoagulation. Of note, patient had completed two cycles of chemotherapy at the time of this presentation for Hodgkin's lymphoma, and her follow-up positron emission tomography/CT scan during this hospital stay showed complete response to chemotherapy



© BMJ Publishing Group Limited 2021. No commercial re-use. See rights and permissions. Published by BMJ.

**To cite:** Sharma P, Chakraborty K. *BMJ Case Rep* 2021;**14**:e242921. doi:10.1136/bcr-2021-242921



**Figure 1** MRI brain with contrast showing right mid posterior frontal lobe infarct (A), punctate infarcts in right caudate and left lentiform nucleus (B), small punctate infarct in left posterior parietal lobe (C).

with no hypermetabolic activity in the lymph nodes, making malignancy less likely a culprit in this setting.

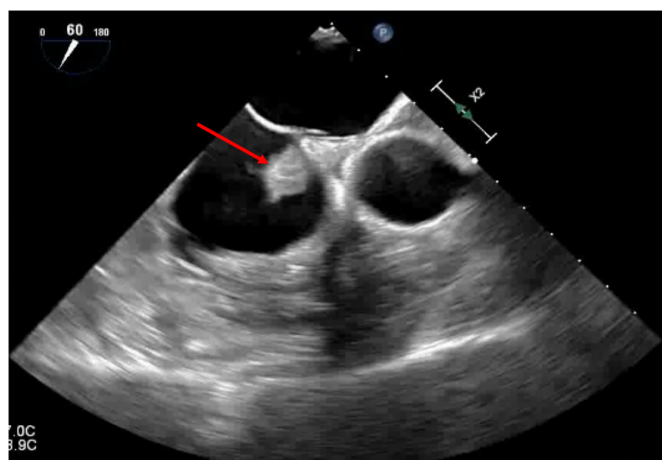
### OUTCOME AND FOLLOW-UP

Patient was discharged after a prolonged hospital course. She had no neurological deficits at the time of discharge. She was continued on enoxaparin 1 mg/kg two times per day for anticoagulation.

### DISCUSSION

COVID-19 was first emerged in the Wuhan province of China in December 2019. The virus has since affected more than 100 million people around the world and has spread to more than 200 countries in 6 months causing a global pandemic. The first case of COVID-19 in the USA was reported on 20 January 2020 in the state of Washington, and the first known death due to the virus was reported on 6 February 2020. COVID-19 infection was declared a pandemic by the WHO on 11 March 2020.

COVID-19 disease presents as an upper respiratory infection with fever followed by an interstitial pneumonia. It can evolve into a SARS, leading to critical illness requiring intensive care unit (ICU) admission and multiorgan failure. COVID-19 infection has also brought to light several other systemic manifestations that are rather unique to this viral infection. One among these manifestations is the development of a systemic coagulopathy that is seen in patients with formation of arterial, venous and microvascular thrombosis. Several mechanisms have been implicated in the development of coagulopathy in COVID-19,



**Figure 2** Trans-oesophageal echocardiogram showing large right atrial thrombus (arrow).

including endothelial dysfunction, cytokine-induced hyperinflammatory state, stasis and hypoxia.<sup>1</sup>

Hyperinflammatory state has been well reported in COVID-19 infection. Our patient presented with elevated inflammatory markers including d-dimer levels (947 ng/dL), C reactive protein (161 mg/L) and sedimentation rate 82 mm/hour. Fibrinogen was 463 mg/dL. Studies have shown correlation between inflammatory markers and hypercoagulable state that support this. Al-Samkari *et al* reported results of a retrospective multicenter study of 400 patients who were hospitalised with COVID-19 infection between 1 March and 5 April 2020. The study showed that an inflammatory state—depicted by elevated levels of inflammatory markers C reactive protein, erythrocyte sedimentation rate, ferritin and procalcitonin, was associated with high incidence of coagulopathy. Among these, D-dimer level was the most predictive.<sup>2</sup> Guan *et al* shed light on the association of the severity of COVID-19 infection with a high D-dimer level with a large retrospective study of 1099 patients with COVID-19 infection. The study suggested that a cut-off point of 0.5 mg/L is more frequent in patients with severe disease than in those without (60% vs 43%,  $p = 0.002$ ).<sup>3</sup>

The thrombotic manifestations of COVID-19 infection are varied and include venous thromboembolic disease including pulmonary emboli and deep vein thrombosis as well as arterial thrombosis. One of the distinct presentations of COVID-19-associated coagulopathy is acute large vessel occlusion resulting in ischaemic stroke. This has been reported as a presenting feature in five patients all younger than age 50, over a period of 2 weeks who all tested positive for COVID-19.<sup>4</sup> Multiple case reports have also highlighted the possibility of cardiovascular arterial thrombosis presenting as acute coronary syndrome/ST elevation myocardial infarction.<sup>5 6</sup> Our case was fascinating as our patient presented with all the thrombotic complications including deep vein thromboses of bilateral internal jugular veins and right atrial thrombus. The ischaemic insult seen on MRI brain was thought to be more of an embolic phenomena, which also supports COVID-19-related widespread microthrombi due to possible vascular inflammation. The fact that patient has recovered near fully from neurological standpoint also supports vascular inflammation-related event rather than underlying cardiac issues.<sup>7-9</sup> Of note, patient did have a venous catheter in place in the right cavoatrial junction at the time of developing the jugular vein thrombi; however, it does not explain why she would develop bilateral thrombosis. Of note, CT angiography of the neck was attempted but was a poor study, hence, could not determine if there was clot propagation from one side of the neck to the other. Studies have proposed other mechanisms at the molecular level that could explain the hypercoagulability associated with COVID-19.<sup>10</sup>

Studies have shown that despite anticoagulant thromboprophylaxis, the reported rates of VTE and arterial thrombosis range from 15% to 30% in critically ill patients with COVID-19 and ~7% in those admitted to medical wards.<sup>11 12</sup> In patients dying from COVID-19, autopsy studies reveal unsuspected deep vein thrombosis and multiple thrombi in the vessels of the lungs, kidneys and other organs.<sup>13</sup> These findings have prompted some clinicians to use treatment doses of heparin or low-molecular-weight heparin instead of prophylactic doses in critically ill patients with COVID-19.

The International Society on Thrombosis and Hemostasis guidelines recommend use of prophylactic dose low-molecular-weight heparin unless there is active bleeding or a platelet count of  $<25 \times 10^9/L$  to protect against venous thromboembolism.<sup>14</sup> The American College of Cardiology<sup>15</sup> recommends

pharmacological VTE prophylaxis in patients with COVID-19 requiring ICU-level care as well as those with comorbidities including pneumonia, respiratory failure, heart failure, cancer and possibly pregnant women who are hospitalised. A retrospective study looked at 449 patients with severe COVID-19, of whom 99 patients received heparin (mainly low-molecular weight heparin). Results show that the heparinised group had lower mortality among patients who had an elevated sepsis-induced coagulopathy score and D-dimer.<sup>16</sup>

Our patient did have relative risk factor for coagulopathy including active malignancy on treatment and obesity. But at the same note, she did not have any family or personal history before this event. Although there is some data regarding increased risk of thrombotic events in patient with Hodgkin's lymphoma,<sup>17</sup> but it is important to note that was mostly seen in patients with advanced disease. Furthermore, all the patients in this analysis received BEACOPP (bleomycin, etoposide, adriamycin, cyclophosphamide, vincristine, procarbazine, prednisone) and none of them received ABVD as part of treatment regimen. However, it is to be noted that she developed acute ischaemic embolic stroke while on anticoagulation with heparin. Development of coagulopathy while on anticoagulation secondary to COVID-19 has been previously described as well.<sup>18</sup> Most importantly in respect to her malignancy, PET/CT scan showed complete response with no active hypermetabolic disease. These factors suggest that there was a secondary mechanism at play with hyperinflammatory state leading to extensive coagulopathy due to COVID-19 infection itself. Both cancer and COVID-19 are associated with coagulopathy in a complex manner. Thrombotic and bleeding complications are leading causes of death in patients with cancer and are often associated with the morbidities in patients with COVID-19. Increased levels of D-dimer and prothrombin and decrease in fibrinogen were reported in these patients at days 10–14.<sup>19 20</sup> This emphasises the importance of frequent and regular monitoring and maintaining of these factors in COVID-19 and patients with cancer. However, it is too early to infer if the COVID-19-related coagulopathy is more or less common in patients with cancer and further studies are required.

### Learning points

- ▶ COVID-19-associated coagulopathy is a complication of this novel coronavirus infection and can lead to serious adverse effects with arterial and venous thrombosis.
- ▶ Special attention is required while treating high-risk patients with COVID-19 including patients with respiratory failure, active cancer and other comorbidities requiring intensive care treatment.
- ▶ Precise knowledge of the incidence of thrombotic complications in patients with COVID-19 is important for decision-making with regards to intensity of thromboprophylaxis, especially in patients admitted to the intensive care unit who are at highest thrombotic risk.

**Contributors** PS: conception of design, writing, editing, acquisition of data, interpretation of data. KC: conception of design, acquisition of data, interpretation and analysis of data.

**Funding** The authors have not declared a specific grant for this research from any funding agency in the public, commercial or not-for-profit sectors.

**Competing interests** None declared.

**Patient consent for publication** Obtained.

**Provenance and peer review** Not commissioned; externally peer reviewed.

This article is made freely available for use in accordance with BMJ's website terms and conditions for the duration of the covid-19 pandemic or until otherwise determined by BMJ. You may use, download and print the article for any lawful, non-commercial purpose (including text and data mining) provided that all copyright notices and trade marks are retained.

### REFERENCES

- 1 Chan NC, Weitz JI. COVID-19 coagulopathy, thrombosis, and bleeding. *Blood* 2020;136:381–3.
- 2 Al-Samkari H, Karp Leaf RS, Dzik WH, *et al*. COVID-19 and coagulation: bleeding and thrombotic manifestations of SARS-CoV-2 infection. *Blood* 2020;136:489–500.
- 3 Guan W-J, Ni Z-Y, Hu Y, *et al*. Clinical characteristics of coronavirus disease 2019 in China. *N Engl J Med* 2020;382:1708–20.
- 4 Oxley TJ, Mocco J, Majidi S, *et al*. Large-vessel stroke as a presenting feature of Covid-19 in the young. *N Engl J Med* 2020;382:e60.
- 5 Dominguez-Erquicia P, Dobarro D, Roposeiras-Roubin S, *et al*. Multivessel coronary thrombosis in a patient with COVID-19 pneumonia. *Eur Heart J* 2020;41:2132.
- 6 Lodigiani C, Lapichino G, Carenzo L, *et al*. Venous and arterial thromboembolic complications in COVID-19 patients admitted to an academic hospital in Milan, Italy. *Thromb Res* 2020;191:9–14.
- 7 Prasad A, Kataria S, Srivastava S, *et al*. Multiple embolic stroke on magnetic resonance imaging of the brain in a COVID-19 case with persistent encephalopathy. *Clin Imaging* 2021;69:285–8.
- 8 Dhamoon MS, Thaler A, Gururangan K, *et al*. Mount Sinai stroke Investigators\*. acute cerebrovascular events with COVID-19 infection. *Stroke* 2021;52:48–56.
- 9 Lu Y, Li X, Geng D, *et al*. Cerebral Micro-Structural Changes in COVID-19 Patients - An MRI-based 3-month Follow-up Study. *EClinicalMedicine* 2020;25:100484.
- 10 Berthelot J-M, Drouet L, Lioté F. Kawasaki-like diseases and thrombotic coagulopathy in COVID-19: delayed over-activation of the sting pathway? *Emerg Microbes Infect* 2020;9:1514–22.
- 11 Incidence of venous thromboembolism in hospitalized patients with COVID-19. *J Thromb Haemost* 2020.
- 12 Nahum J, Morichau-Beauchant T, Daviaud F, *et al*. Venous thrombosis among critically ill patients with coronavirus disease 2019 (COVID-19). *JAMA Netw Open* 2020;3:e2010478.
- 13 Deshpande C. Thromboembolic findings in COVID-19 autopsies: pulmonary thrombosis or embolism? *Ann Intern Med* 2020.
- 14 Thachil J. ISTH interim guidance on recognition and management of coagulopathy in COVID-19. *J Thromb Haemost* 2020.
- 15 Bikdeli B, Madhavan MV, Jimenez D, *et al*. COVID-19 and thrombotic or thromboembolic disease: implications for prevention, antithrombotic therapy, and follow-up. *J Am Coll Cardiol* 2020.
- 16 Tang N, Bai H, Chen X, *et al*. Anticoagulant treatment is associated with decreased mortality in severe coronavirus disease 2019 patients with coagulopathy. *J Thromb Haemost* 2020.
- 17 Borchmann S, Hude I, Müller H, *et al*. Thrombosis in Hodgkin lymphoma patients: incidence, time points, risk factors and impact of stage and treatment. *Blood* 2016;128:4151.
- 18 Garg A, Goyal S, Patel P. A case of COVID-19 infection with delayed thromboembolic complication on warfarin. *Cureus* 2020;12:e8847.
- 19 Levi M, Thachil J, Iba T, *et al*. Coagulation abnormalities and thrombosis in patients with COVID-19. *Lancet Haematol* 2020;7:e438–40.
- 20 Tang N, Li D, Wang X, *et al*. Abnormal coagulation parameters are associated with poor prognosis in patients with novel coronavirus pneumonia. *J Thromb Haemost* 2020;18:844–7.

Copyright 2021 BMJ Publishing Group. All rights reserved. For permission to reuse any of this content visit <https://www.bmj.com/company/products-services/rights-and-licensing/permissions/>  
BMJ Case Report Fellows may re-use this article for personal use and teaching without any further permission.

Become a Fellow of BMJ Case Reports today and you can:

- ▶ Submit as many cases as you like
- ▶ Enjoy fast sympathetic peer review and rapid publication of accepted articles
- ▶ Access all the published articles
- ▶ Re-use any of the published material for personal use and teaching without further permission

### **Customer Service**

If you have any further queries about your subscription, please contact our customer services team on +44 (0) 207111 1105 or via email at [support@bmj.com](mailto:support@bmj.com).

Visit [casereports.bmj.com](http://casereports.bmj.com) for more articles like this and to become a Fellow