

Acromegaly associated with a symptomatic Rathke's cyst

Vishal Gupta, Ashley Grossman¹, Aneesa Kapadia², Kiran Thorat³

Department of Endocrinology, Jaslok Hospital and Research Centre, Mumbai, ¹Department of Medicine and Endocrinology, Bart and The London NHS Trust, London, ²Department of Medicine and Endocrinology, Jaslok Hospital and Research Centre, Mumbai, ³Department of Histopathology, Saifee Hospital, Mumbai, India

ABSTRACT

Our aim is to describe a case of acromegaly that was associated with symptomatic Rathke's cyst. We describe a young male student without any significant family history who presented with clinical and biochemical features consistent with growth hormone excess, which was confirmed with dynamic testing. He also described a persistent headache predating symptoms of growth hormone excess by 4 years. Magnetic resonance imaging (MRI) of the pituitary showed a large sellar mass which was thought to be a somatotroph adenoma. Trans-sphenoidal surgery was performed; however, a colloid lesion was identified by the neurosurgeon that proved to be a Rathke's cyst. The association of acromegaly with Rathke's cyst is very rare, with less than 10 cases found to be reported on review of literature. This is the first report from India.

Key words: Acromegaly, colloid cyst, growth hormone excess, pituitary adenoma, pituitary tumor, Rathke's cyst

INTRODUCTION

In more than 99% of cases acromegaly is due to a benign pituitary growth hormone secreting adenoma; less than 1% is due to a peripheral neuroendocrine tumour secreting growth hormone releasing hormone.^[1] Acromegaly has an average incidence of 3.3 per million people with a mean age of 46.3 years at diagnosis.^[2]

Rathke's cleft cysts are remnants of the embryonic pharyngeal stomodeum. During the third or fourth week of development Rathke's pouch is formed by the in folding of simple ciliated columnar epithelium lining the roof of the stomodeum. The anterior and posterior walls give rise to the anterior and intermediate lobes of the pituitary

gland, respectively. The residual caudal lumen between the lobes is designated Rathke's cleft. It has been proposed that epithelial cells lining the intermediate lobe secrete products that accumulate and dilate Rathke's cleft to form a cyst (Rathke's cyst). They are generally asymptomatic. While most Rathke's cleft cysts are intrasellar, one third of Rathke's cleft cysts exhibit suprasellar extension, which can lead to compression of the optic nerve, chiasm, pituitary stalk, or hypothalamus.^[3-5] When symptomatic, these cysts often present in the form of headaches, visual loss, or hypothalamic pituitary dysfunction.^[4-6] The maximum diameter of the Rathke's cyst varies from 0.7 to 4 cm, with an average size of 1.7+/-0.7 cm.^[3]

CASE REPORT

A 20 year old male student coming from the interiors of Maharashtra (Jalgaon), India, a non-smoker, without any significant family or past medical history, presented with headache for 5-6 years, a sudden increase in height (approximately 5-6 cms/yr) and weight of 10kgs over 2 years, a change in facial features for 2 years. A working diagnosis of growth hormone excess was made

Access this article online

Quick Response Code:



Website:
www.ijem.in

DOI:
10.4103/2230-8210.81950

Corresponding Author: Dr. Vishal Gupta, Jaslok Hospital and Research Centre, 15 – Dr. Deshmukh Marg, Pedder Road, Mumbai – 400 026, India.
E-mail: enquiry@drvishalgupta.com

On examination his observations read as follows: blood pressure 150/90mm of Hg in right arm, without postural fall in blood pressure, pulse 80 bpm and normal jugular venous pressure. He had coarse facial features, prognathism, skin tags, increased soft tissue mass in his palms and soles, and on comparison of previous photographs there was an obvious change in facial characters. Confrontation to red-pin was normal and there was no evidence of any cranial nerve palsies or signs of intracranial hypertension. General systemic examination was otherwise normal

Biochemical tests

Normal hemoglobin, white count, liver, renal function tests, electrolytes and serum calcium with a serum osmolality 299 mmol/l and urine osmolality 634 mmol/l, excluding significant diabetes insipidus Serum angiotensin converting enzyme (ACE), Immune screen, tumour markers normal.

Baseline pituitary function tests

Suggested growth hormone excess with secondary hypogonadism and hypocortisolism. FSH 1.36 IU/ml (normal range 1.7 – 12) LH 2.14 IU/ml (normal range 1.1 – 7.0), total testosterone 130 ng/dl (282 - 800), Prolactin 12.42 ng/ml (upto 30ng/ml), T3 1.62 mcg/ml (normal range 0.6 – 2.0), T4 8.99 mcg/ml (5 – 13), TSH 0.76 mIU/ml (0.4 to 5), Adrenocorticotrophic hormone 31.3 pg/ml (10-100), Cortisol 5.4 mcg/dl (normal range 5-25), Human growth hormone 4.2 ng/ml (0-8), IGF-1 757 ng/ml (127- 324).

Glucose tolerance test (75g of carbohydrate) failed to suppress growth hormone with 1 hr and 2 hr values of 3.7 ng/ml and 3.9 ng/ml respectively, confirming growth hormone excess. The Glucose tolerance test also confirmed the presence of impaired glucose tolerance secondary to growth hormone excess.

- Glucagon stimulation test confirmed secondary cortisol insufficiency
- 24hr urine 5-HIAA - normal
- Visual perimetry and 2D Echo were normal

Imaging

Dual energy X-ray absorptiometry (DEXA) suggested osteopenia at the level of both hip and spine (Z-score spine minus 1.7, hip; minus 1.1)

X-Ray chest and CT-chest, abdomen, pelvis were normal

MRI Pituitary with gadolinium contrast [Figure 1] showed a sellar mass, (18.7 x 15.7 x13.9) mm in size, which failed to enhance following contrast

We thus confirmed acromegaly with secondary testosterone and cortisol insufficiency, and impaired glucose tolerance

He underwent a trans-sphenoidal excision of pituitary lesion with the aim to remove the sellar mass that was thought to be a somatotroph adenoma. The neurosurgeon encountered colloid-like material in the sellar region, that was removed under hydrocortisone cover. This was complicated by diabetes insipidus and CSF rhinorrhea. The diabetes insipidus was managed by oral desmopressin and CSF rhinorrhea by a lumbar drain with appropriate antibiotic cover

Histopathology of sellar mass proved to be colloid tissue suggestive of Congenital Rathke's cyst [Figure 2].

On the 7th day post-trans-sphenoidal surgery, 75gms-glucose tolerance test suggested persistent, excess growth hormone secretion that failed to suppress (1 hr venous

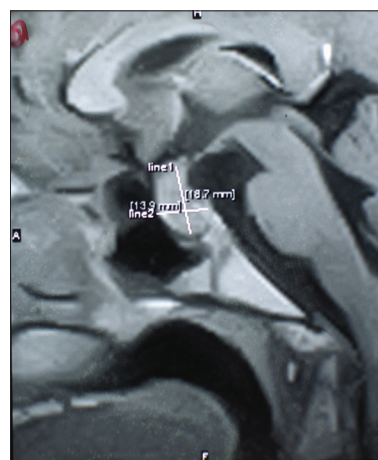


Figure 1: Magnetic Resonance Imaging pituitary – A sellar mass (18.7 × 15.7 × 13.9) mm in size

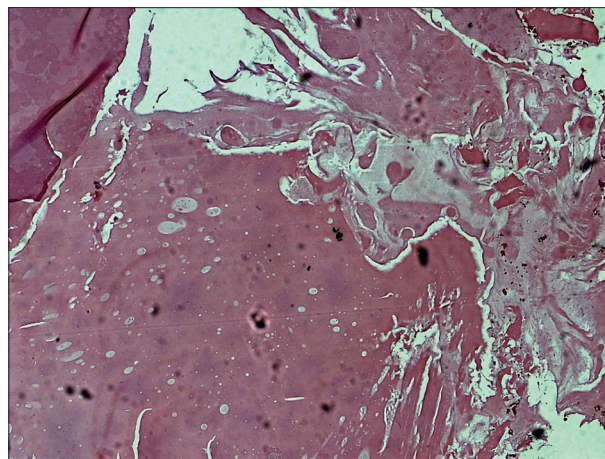


Figure 2: Histology image showing Rathke's cyst (H and E, 10x)

blood sugar 247mg%, 2hrs venous blood sugar 171mg%, with corresponding growth hormone levels of 5.3ng/ml and 5.7ng/ml respectively)

A repeat MRI scan performed 3 months later showed no obvious evidence of pituitary adenoma. The patient was initiated on Octreotide LAR and continues to do well with symptomatic improvement and suppression of his growth hormone to safe levels.

DISCUSSION

The concomitant presentation of acromegaly and Rathke's cleft cyst is very rare.^[7-12] The most logical assumption for the source for growth hormone in the case described would be secondary to a pituitary adenoma, but we were misled by the concomitant presence of Rathke's cyst. The lack of signal intensity differentiation on MRI of the pituitary suggested that the sellar mass was the probable source of growth hormone excess. Furthermore literature suggests that in only about 50% of patients there may be two different signal intensities on MRI.^[13] Trans-sphenoidal surgery is recommended and is the treatment of choice for both symptomatic intra- and suprasellar colloid cysts and acromegaly secondary to somatotropinoma.^[14]

Despite the development of new drugs in the last few years and the use of trans-sphenoidal surgery, gamma-knife surgery remains the primary treatment of choice for most patients. Medical and radiotherapy still have an important role in the treatment of acromegaly especially in patients who are resistant to, refuse, or have recurrence after surgery. The main drawbacks of radiotherapy are the long interval between treatment and cure and the high incidence of hypopituitarism.^[15] The long-acting somatostatin analogues octreotide LAR and lanreotide SR have become the mainstay of medical treatment for acromegaly, having largely supplanted dopamine agonist agents since the introduction of bromocriptine and more recently cabergoline for the suppression of growth hormone secretion in the 1970s.^[16]

The association of two symptomatic pathologies, acromegaly with a Rathke's cyst is very rare with less than 10 cases reported on review of the literature.^[8,13,17] This is the first report of such a case from India. When a non-enhancing cyst-like structure may be demonstrated in a patient with pituitary adenoma, the possibility of a coexisting Rathke's cleft cyst should be considered.^[7] We suspect that there is a small somatotroph tumor still within the pituitary region, but its presence was masked by the

Rathke's cyst. At present, the excellent response to the somatostatin analogue has led us to avoid further surgery.

REFERENCES

1. Thorner MO, Frohman LA, Leong DA, Thominet J, Downs T, Hellmann P, *et al.* Extrahypothalamic growth-hormone-releasing factor (GRF) secretion is a rare cause of acromegaly: Plasma GRF levels in 177 acromegalic patients. *J Clin Endocrinol Metab* 1984;59:846-9.
2. Bengtsson BA, Eden S, Ernest I, Oden A, Sjogren B. Epidemiology and long-term survival in acromegaly. A study of 166 cases diagnosed between 1955 and 1984. *Acta Med Scand* 1988;223:327-35.
3. Wen L, Hu LB, Feng XY, Gaurav D, Zou LG, Wang WX, *et al.* Rathke's cleft cyst: Clinicopathological and MRI findings in 22 patients. *Clin Radiol* 2010;65:47-55.
4. Waggle VG, Nelson D, Rossi A, Uphoff D. Magnetic resonance imaging of symptomatic Rathke's cleft cyst: Report of a case. *Neurosurgery* 1989;24:276-8.
5. Kasperbauer JL, Orivdas LJ, Atkinson JL, Abboud CF. Rathke cleft cyst: Diagnostic and therapeutic considerations. *Laryngoscope* 2002;122:1836-9.
6. Oka H, Kawano N, Suwa T, Yada K, Kan S, Kameya T. Radiological study of symptomatic Rathke's cleft cyst. *Neurosurgery* 1994;335:632-7.
7. Sumida M, Migita K, Tominaga A, Iida K, Kurisu K. Concomitant pituitary adenoma and Rathke's cleft cyst. *Neuroradiology* 2001;43:755-9.
8. Bader LJ, Carter KD, Latchaw RE, Ellis WG, Wexler JA, Watson JC. Simultaneous symptomatic Rathke's cleft cyst and GH secreting pituitary adenoma: A case report. *Pituitary* 2004;7:39-44.
9. Swanson SE, Chandler WF, Latack J, Zis K. Symptomatic Rathke's cleft cyst with pituitary adenoma: Case report. *Neurosurgery* 1985;17:657-9.
10. Nishio S, Mizuno J, Barrow DL, Takei Y, Tindall GT. Pituitary tumors composed of adenohypophysial adenoma and Rathke's cleft cyst elements: A clinicopathology study. *Neurosurgery* 1987;21:371-7.
11. Trokoudes KM, Walfish PG, Holgate RC, Pritzker KP, Schwartz ML, Kovacs K. Sellar enlargement with hyperprolactinemia and a Rathke's pouch cyst. *JAMA* 1978;240:471-3.
12. Koutourousiou M, Kontogeorgos G, Wesseling P, Grotenhuis AJ, Seretis A. Collision sellar lesions: Experience with eight cases and review of the literature. *Pituitary* 2010;13:8-17.
13. Noh SJ, Ahn JY, Lee KS, Kim SH. Pituitary adenoma and concomitant Rathke's cleft cyst. *Acta Neurochir (Wien)* 2007;149:1223-8.
14. Nomikos P, Buchfelder M, Fahlbusch R. Intra- and suprasellar colloid cysts. *Pituitary* 1999;2:123-6.
15. Merza Z. Modern treatment of acromegaly. *Postgrad Med J* 2003;79:189-94.
16. Racine MS, Barkan AL. Somatostatin analogs in medical treatment of acromegaly. *Endocrine* 2003;20:271-8.
17. Isono M, Kamida T, Kobayashi H, Shimomura T, Matsuyama J. Clinical features of symptomatic Rathke's cleft cyst. *Clin Neurol Neurosurg* 2001;103:96-100.

Cite this article as: Gupta V, Grossman A, Kapadia A, Thorat K. Acromegaly associated with a symptomatic Rathke's cyst. *Indian J Endocr Metab* 2011;15:140-2.

Source of Support: Nil, **Conflict of Interest:** None declared.