

Case report

Open Access

## Effect of pioglitazone treatment in a patient with secondary multiple sclerosis

Harrihar A Pershadsingh\*<sup>1,2</sup>, Michael T Heneka<sup>2</sup>, Rashmi Saini<sup>1</sup>,  
Navin M Amin<sup>1</sup>, Daniel J Broeske<sup>3</sup> and Douglas L Feinstein<sup>4</sup>

Address: <sup>1</sup>Departments of Family Medicine, Kern Medical Center, Bakersfield, and University of California, Irvine, California, USA, <sup>2</sup>Department of Neurology, University of Bonn, Bonn, Germany, <sup>3</sup>Department of Internal Medicine, Kern Medical Center, Bakersfield, California, USA and <sup>4</sup>Department of Anesthesiology, University of Illinois, Chicago, Illinois, USA

Email: Harrihar A Pershadsingh\* - pershadh@kernmedctr.com; Michael T Heneka - Michael.Heneka@ukb.uni-bonn.de; Rashmi Saini - pershadh@kernmedctr.com; Navin M Amin - aminn@kernmedctr.com; Daniel J Broeske - broeske1@juno.com; Douglas L Feinstein - dlfeins@Uic.edu

\* Corresponding author

Published: 20 April 2004

Received: 24 March 2004

*Journal of Neuroinflammation* 2004, 1:3

Accepted: 20 April 2004

This article is available from: <http://www.jneuroinflammation.com/content/1/1/3>

© 2004 Pershadsingh et al; licensee BioMed Central Ltd. This is an Open Access article: verbatim copying and redistribution of this article are permitted in all media for any purpose, provided this notice is preserved along with the article's original URL.

### Abstract

**Background:** Ligands of the peroxisome proliferator-activated receptor-gamma (PPAR $\gamma$ ) induce apoptosis in activated T-lymphocytes and exert anti-inflammatory effects in glial cells. Preclinical studies have shown that the thiazolidinedione pioglitazone, an FDA-approved PPAR $\gamma$  agonist used to treat type 2 diabetes, delays the onset and reduces the severity of clinical symptoms in experimental autoimmune encephalomyelitis, an animal model of multiple sclerosis (MS). We therefore tested the safety and therapeutic potential of oral pioglitazone in a patient with secondary MS.

**Case presentation:** The rationale and risks of taking pioglitazone were carefully explained to the patient, consent was obtained, and treatment was initiated at 15 mg per day p.o. and then increased by 15 mg biweekly to 45 mg per day p.o. for the duration of the treatment. Safety was assessed by measurements of metabolic profiles, blood pressure, and edema; effects on clinical symptoms were assessed by measurement of cognition, motor function and strength, and MRI. Within 4 weeks the patient exhibited increased appetite, cognition and attention span. After 12 months treatment, body weight increased from 27.3 to 35.9 kg (32%) and maintained throughout the duration of the study. Upper extremity strength and coordination improved, and increased fine coordination was noted unilaterally after 8 months and bilaterally after 15 months. After 8 months therapy, the patient demonstrated improvement in orientation, short-term memory, and attention span. MRIs carried out after 10 and 18 months of treatment showed no perceptible change in overall brain atrophy, extent of demyelination, or in Gd-enhancement. After 3.0 years on pioglitazone, the patient continues to be clinically stable, with no adverse events.

**Conclusions:** In a patient with secondary progressive MS, daily treatment with 45 mg p.o. pioglitazone for 3 years induced apparent clinical improvement without adverse events. Pioglitazone should therefore be considered for further testing of therapeutic potential in MS patients.

**Background**

Current therapies for MS are limited in efficacy and can have adverse effects. Although immuno-modulating type-1β interferons and glatiramer acetate reduce active CNS inflammatory lesions, clinical severity and attack frequency in relapsing remitting MS, they are less efficacious in progressive disease [1]. The immunosuppressive agent, mitoxantrone is presently approved for treating progressive MS but is limited because of severe adverse side-effects especially cardiotoxicity [1]. The insulin-sensitizing anti-diabetic thiazolidinediones (TZDs) are high affinity activators of the nuclear transcription factor peroxisome proliferator-activated receptor-gamma (PPARγ). TZDs inhibit T lymphocyte proliferation and activation, reduce expression and production of inflammatory molecules including interleukin-1β, tumor necrosis factor-α and inducible nitric oxide synthase, increase astrocyte metabolism and resistance to cytotoxicity [11], and reduce clinical symptoms in experimental autoimmune encephalomyelitis (EAE), an autoimmune-mediated, demyelinating disease which provides a model for MS [2,3]. In view of these effects and the established safety profile of TZDs, we investigated the therapeutic potential of the FDA-approved anti-diabetic TZD pioglitazone in a patient with secondary progressive MS.

**Case presentation**

A 44-year-old woman with secondary progressive MS was diagnosed at age 20 yr, per Lublin and Reingold [4]. During the next 15 years she had 8 documented relapses which resolved with intravenous glucocorticoid therapy. The relapses decreased in frequency during this time, after which her clinical status deteriorated, with progressive development of quadriparesis, ataxia, fatigue and cognitive decline. In 1994, a trial of interferon β-1b was discontinued because of increased spasticity, and she was not a

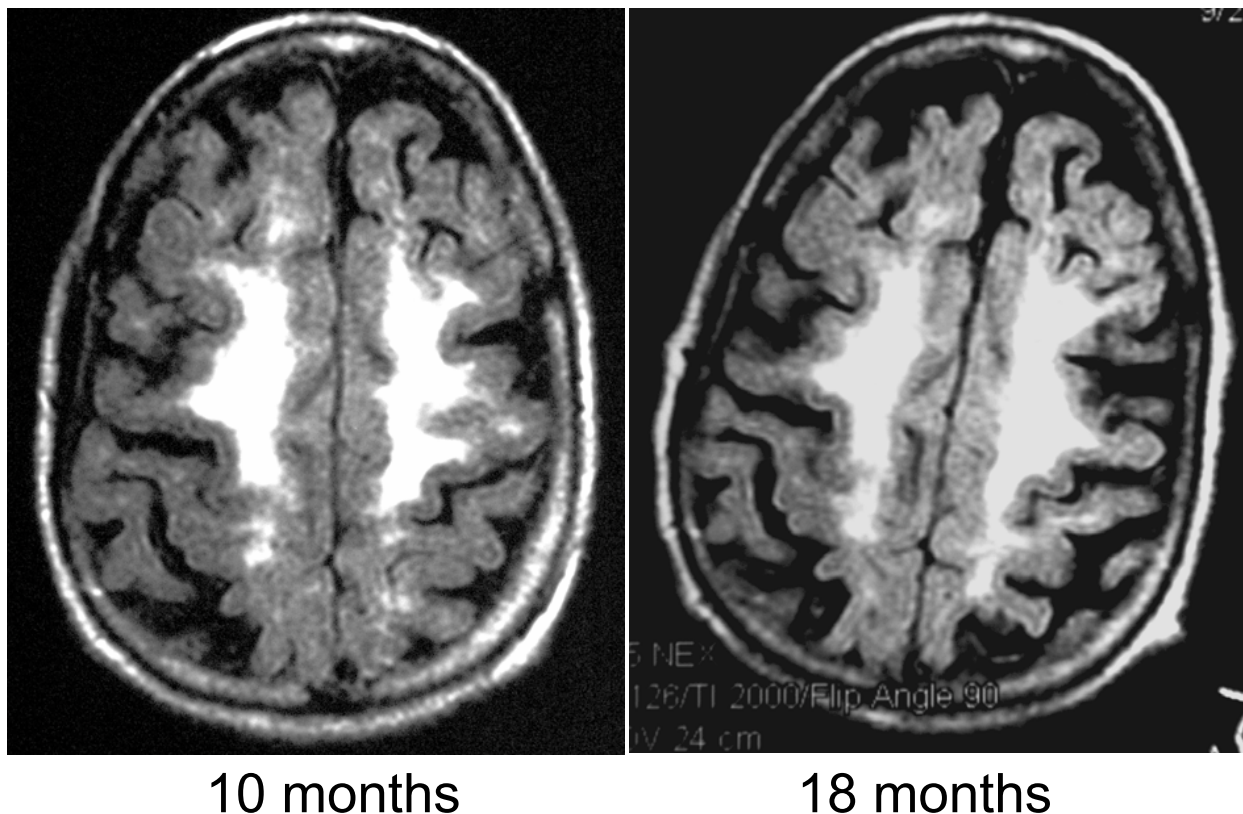
candidate for glatiramer. She had no history of diabetes, cardiovascular, liver or kidney disease.

When seen in 1999 her weight was 29.5 kg, down from 54.5 kg in 1976. She was paraplegic, wheelchair-bound, and exhibited paresis of the upper extremities with OMS (Oxford Muscle Strength) score of 2–3 out of 5 (Table 1) and an EDSS score of 8.0. Neurological presentation included paraplegia, bilateral central scotomata with visual-field loss, dysphagia, chronic fatigue, cognitive impairment similar to mild dementia, and depressed mood. In June 2000, having explained the rationale and risks, she consented to a trial of pioglitazone, which was initiated at 15 mg daily and increased by 15 mg biweekly to 45 mg. Improvement was evident within 4 weeks as increased appetite, cognition and attention span. Her weight increased from 27.3 to 35.9 kg (32%) after 12 months treatment, which was maintained between 34.6 to 36.2 kg throughout an additional 18 months. Weight gain was evident as increased muscle mass and peripheral fat, mainly in the hips, gluteal area, and limbs. Upper extremity strength and coordination progressively improved (Table 1). Improved fine coordination was noted unilaterally after 8 months (left finger-to-nose execution), and bilaterally after 15 months. Before pioglitazone, repetitive statements and forgetfulness, reminiscent of dementia, were problematic. After 8 months therapy, cognitive assessment demonstrated improvement in orientation, short-term memory (recall increased from 0/3 to 2/3 objects), attention span, registration and insight, and is consistent with clinical improvement [5]. According to DSM IV criteria, her depression also improved significantly, along with the progressive gain in weight and improvement in neurological function as a whole. She was progressively able to tolerate outdoor social activities for several hours at a time, with improved stamina and well-being.

**Table 1: Upper Extremity Muscle Strength Before and After 52 Weeks on Pioglitazone**

Muscle Group/Function	Muscle Strength Grade					
	Before PIO (Baseline)		15 months After PIO		30 months After PIO	
	<u>Right</u>	<u>Left</u>	<u>Right</u>	<u>Left</u>	<u>Right</u>	<u>Left</u>
Hand Flexor Group/Grip	2	3	4	5	4	5
Bicep/Arm Flexion	2	3	4	5	4	5
Tricep/Arm Extension	1	2	4	5	4	5
Shoulder Flexion	1	2	4	5	4	5
Shoulder Abduction	2	3	4	5	4	5

Muscle strength determined using the Oxford Muscle Strength Grading Scale (Grade 0 = No movement; Grade 3 = Completely moves body part against gravity; Grade 5 = Normal)

**Figure 1**

Axial T1-weighted fluid-attenuated inversion recovery (FLAIR) MRI images showing confluent demyelination. MRIs were taken at 10 months (left) and at 18 months (right) after initiation of treatment with pioglitazone. Similar axial sections are shown for the two time points.

During the study, two MRI studies with gadolinium (Gd) were performed, one 18 months after initiation of pioglitazone and the second 10 months later (Figure 1). There was no perceptible change in overall brain atrophy, extent of demyelination, or in Gd-enhancement indicating that at least over the 10 months between the MRI studies, the disease was quiescent. This also suggests that the beneficial effects of pioglitazone treatment were not associated with any overt improvement in pathology. After 3 years on pioglitazone, she continues to be clinically stable. There have been no adverse events, and her metabolic profile has remained normal throughout the study.

**Conclusions**

The limited efficacy and safety of immuno-modulatory and immuno-suppressive agents available for treating

progressive MS warrants development of improved and safer therapies [1]. MS is an autoimmune disease associated with inappropriate T lymphocyte activation, CNS inflammation and demyelination, resulting in axonal and neuronal damage [1]. The thiazolidinedione class of drugs were developed for the treatment of type 2 diabetes and act by improving insulin resistance without causing hypoglycemia, even in euglycemic individuals. They were later found to activate PPAR $\gamma$  and shown to promote anti-inflammatory and immunosuppressive effects by suppressing T lymphocyte activation, proliferation, and inhibiting cellular production of inflammatory molecules associated with MS [3,6,7].

The beneficial effects of pioglitazone observed in this patient are somewhat unexpected as inflammation is less

prominent in secondary progressive MS compared to relapsing remitting disease. However, improvements in upper body strength, coordination, dysphagia, and cognitive function, suggest neurological benefit associated with pioglitazone treatment. In addition to their anti-inflammatory actions, TZDs can also influence cell physiology in a receptor-independent manner, and we recently demonstrated that TZDs increase astrocyte glucose metabolism and lactate production [11]. It is therefore feasible that effects on brain metabolism, for example increased capacity of astrocytes to provide lactate to surrounding neurons, accounts in part for improved cognitive and motor function. However, the persistence of lower extremity paralysis appears a likely consequence of irreversible spinal cord atrophy. The 30% gain in weight markedly exceeds the approximately 2–4% weight gain seen with diabetics [see prescribing information: ACTOS® (pioglitazone hydrochloride), Takeda Chemical Co.]. While this may reflect decreased depression, there are as yet no reports that pioglitazone or any other thiazolidinedione, influence mood disorders.

In EAE mice pioglitazone decreased disease incidence, reduced maximum disease severity, and induced remission in already-ill animals [3]. Similar results were obtained with other TZDs including rosiglitazone, another approved antidiabetic drug [3]. These drugs have also been shown to clinically ameliorate other inflammatory diseases [8] including psoriasis [9] and ulcerative colitis [10]. Described adverse effects for pioglitazone are confined to the diabetic population, and include mild edema, and limited weight gain, and pioglitazone has not been causally linked to hepatic failure, as has troglitazone. These findings imply that pioglitazone, and perhaps other insulin-sensitizing TZDs may provide therapeutic benefit in MS.

### Abbreviations

DSM, diagnostic and statistical manual of mental disorders; FLAIR, fluid attenuation inversion recovery; Gd, gadolinium; MRI, magnetic resonance imaging; MS, multiple sclerosis; PIO, pioglitazone; PPAR $\gamma$ , peroxisome proliferator-activated receptor gamma; TZD, thiazolidinedione.

### Competing interests

None declared.

### Authors' contributions

HAP was the primary physician, conceived of the original study, and prepared first draft of the manuscript. MTH was a consulting neurologist, evaluated MRI data, assisted with manuscript editing, and contributed to the original idea of treating MS patients with TZDs. RS performed clinical assessments. NM and DJB consulted on clinical eval-

uations and response to therapy. DLF organized and analyzed data, contributed to the original idea to treat MS patients with TZDs, helped write and edit, and wrote the final draft of the manuscript.

### Acknowledgements

We thank Monica Menendez for secretarial assistance. Supported by grants from the National Multiple Sclerosis Society (DLF), Takeda Pharmaceuticals (DLF) and Bethesda Pharmaceuticals, Inc (HAP). Written consent was obtained from the patient for publication of study.

### References

- Keegan BM, Noseworthy JH: **Multiple sclerosis**. *Annu Rev Med* 2002, **53**:285-302.
- Niino M, Iwabuchi K, Kikuchi S, et al.: **Amelioration of experimental autoimmune encephalomyelitis in C57BL/6 mice by an agonist of peroxisome proliferator-activated receptor-gamma**. *J Neuroimmunol* 2001, **116**:40-48.
- Feinstein DL, Galea E, Gavriluk V, et al.: **Prevention and treatment of experimental autoimmune encephalomyelitis by pioglitazone, a PPAR- $\gamma$  agonist**. *Ann Neurol* 2002, **51**:694-702.
- Lublin FD, Reingold SC: **Defining the clinical course of multiple sclerosis: results of an international survey**. **National Multiple Sclerosis Society (USA) Advisory Committee on Clinical Trials of New Agents in Multiple Sclerosis**. *Neurology* 1996, **46**:907-911.
- DeSousa EA, Albert RH, Kalman B: **Cognitive impairments in multiple sclerosis: a review**. *Am J Alzheimers Dis Other Demen* 2002, **17**:23-9.
- Debril MB, Renaud JP, Fajas L, Auwerx J: **The pleiotropic functions of peroxisome proliferator-activated receptor- $\gamma$** . *J Mol Med* 2001, **79**:30-47.
- Clark RB: **The role of PPARs in inflammation and immunity**. *J Leukoc Biol* 2002, **71**:388-400.
- Pershad Singh HA: **PPAR-gamma-Therapeutic target for diseases beyond diabetes: Zuo vadis? Expert Opin Investig Drugs** 2004, **13**:212-215.
- Ellis CN, Varani J, Fisher GJ, et al.: **Troglitazone improves psoriasis and normalizes models of proliferative skin disease: ligands for peroxisome proliferator-activated receptor-gamma inhibit keratinocyte proliferation**. *Arch Dermatol* 2000, **136**:609-16.
- Lewis JD, Lichtenstein GR, Stein RB, et al.: **An open-label trial of the PPAR-gamma ligand rosiglitazone for active ulcerative colitis**. *Am J Gastroenterol* 2001, **96**:3323-8.
- Dello Russo C, Galea E, Gavriluk V, Weinberg G, Palmer J, Almeida A, Bolanos JP, Pelligrino D, Feinstein DL: **PPAR $\gamma$  agonists increase glucose metabolism in astrocytes**. *J Biol Chem* 2003, **278**:5828-36.

Publish with **BioMed Central** and every scientist can read your work free of charge

"BioMed Central will be the most significant development for disseminating the results of biomedical research in our lifetime."

Sir Paul Nurse, Cancer Research UK

Your research papers will be:

- available free of charge to the entire biomedical community
- peer reviewed and published immediately upon acceptance
- cited in PubMed and archived on PubMed Central
- yours — you keep the copyright

Submit your manuscript here:  
[http://www.biomedcentral.com/info/publishing\\_adv.asp](http://www.biomedcentral.com/info/publishing_adv.asp)

