

# Polymorphous adenocarcinoma of the oral cavity: A skeptical case mimicking lobular carcinoma of breast and gastric carcinoma

Purnima Vadla, Sankeerthana Pathipaka, Jayakiran Madala, Venkateswara Rao Guttikonda

Department of Oral Pathology and Microbiology, Mamata Dental College, Khammam, Telangana, India

## Abstract

Polymorphous adenocarcinoma (PAC) is a distinctive salivary gland neoplasm that predominantly occurs in the minor salivary glands. The tumor is characterized by cytological uniformity, morphological diversity, an infiltrative growth pattern and low metastatic potential. It presents as an asymptomatic, slow-growing mass within the oral cavity. This salivary gland tumor is difficult to diagnose both clinically and histopathologically due to its indolent presentation and diverse architectural pattern which includes various microscopic patterns namely- solid, ductal-tubular, cribriform, trabecular and single-file growth. Hence, Immunohistochemistry plays a very important role in diagnosing this tumor. We hereby report a rare case of PAC occurring in a 50yr old female patient presenting with a lesion in right upper posterior part of alveolus extending to the hard palate.

**Keywords:** Immunohistochemical analysis, Indian file pattern, polymorphous low-grade adenocarcinoma

**Address for correspondence:** Dr. Purnima Vadla, Department of Oral Pathology and Microbiology, Mamata Dental College, Khammam - 507 002, Telangana, India.

E-mail: purnimaswamy.vadla@gmail.com

**Received:** 27.12.2017, **Accepted:** 28.12.2017

## INTRODUCTION

Salivary gland tumors are morphologically diverse group of lesions. Polymorphous adenocarcinoma (PAC) is one such tumor which is misunderstood and controversial in nomenclature. In 1984, Evans and Batsakis coined the term polymorphous low-grade adenocarcinoma (PLGA) due its vivid morphological appearances and less aggressive behavior.<sup>[1]</sup> Batsakis *et al.* first named PLGA as terminal duct carcinoma based on its origin from the terminal intercalated ducts. Soon after, Freedman and Lumerman in 1983 named PLGA as lobular carcinoma due to its similitude to lobular carcinoma of the breast.<sup>[2,3]</sup> Recent update from the 4<sup>th</sup> edition of the world health organization classification of tumors of the salivary gland shortened the term PLGA to PAC.<sup>[4]</sup>

Waldron *et al.* have reported that it is the third most common intraoral malignancy occurring in minor salivary glands with an incidence rate of 26.4% among intraoral malignancies.<sup>[5]</sup> These lesions most commonly involve minor salivary glands of the palate accounting for 49%–77.8%, followed by buccal mucosa and upper lip 7.4%–13.4% and rarely involves floor of the mouth, lower lip and tongue. PAC occurs commonly in females with a female to male ratio of 2:1. PAC occurred over a wide age range of 23–94 years but did not involve the first two decades of life.<sup>[6]</sup> We thereby present a rare case report of PAC which was first thought of as a secondary in the oral cavity with primaries in breast and stomach.

This is an open access article distributed under the terms of the Creative Commons Attribution-NonCommercial-ShareAlike 3.0 License, which allows others to remix, tweak, and build upon the work non-commercially, as long as the author is credited and the new creations are licensed under the identical terms.

**For reprints contact:** reprints@medknow.com

**How to cite this article:** Vadla P, Pathipaka S, Madala J, Guttikonda VR. Polymorphous adenocarcinoma of the oral cavity: A skeptical case mimicking lobular carcinoma of breast and gastric carcinoma. *J Oral Maxillofac Pathol* 2018;22:S60-4.

### Access this article online

#### Quick Response Code:



#### Website:

www.jomfp.in

#### DOI:

10.4103/jomfp.JOMFP\_203\_17

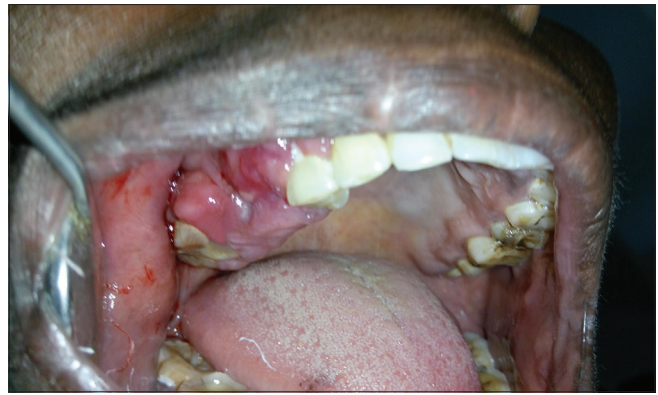## CASE REPORT

A 50-year-old female patient came to the outpatient department of our institution with a chief complaint of rapidly progressing swelling in the upper right back tooth region of jaw since 2 months. Patient medical history revealed gastritis for which she has been taking medication. Dental history was noncontributory. Extraoral examination revealed palpable right submandibular group of lymph nodes which were tender, fixed and hard in consistency. Intraorally, an erythematous swelling measuring 8 cm × 4 cm approximately was seen extending from 13 to 17 regions of the jaw. Lesion showed both buccal and palatal extensions involving the buccal sulcus and 1/3<sup>rd</sup> of the palate, respectively. On palpation, the lesion was tender and firm in consistency [Figure 1]. Orthopantomogram revealed missing 15 and 16.

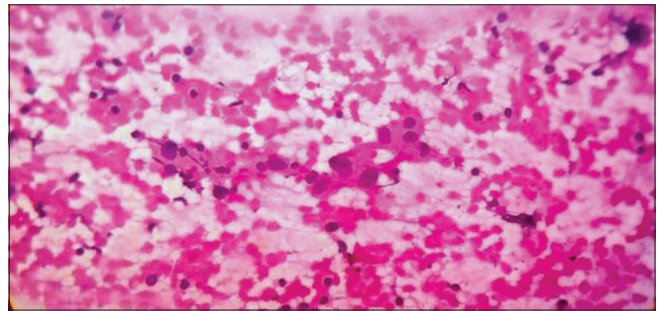
Fine needle aspiration cytology (FNAC) smear from the right submandibular group of lymph nodes shows blood mixed lymphoid tissue and few scattered, single suspicious epithelial cells with hyperchromatic nuclei and abundant eosinophilic cytoplasm suggestive of malignant neoplastic cells in the lymph node [Figure 2].

Histopathological examination revealed a well-circumscribed, unencapsulated lesion with an intact surface epithelium which is of stratified squamous variety. The underlying tumor stroma showed individual tumor cells arranged in a linear, “single file pattern” or “beads on string pattern.” Tumor cells were round to oval in shape with enlarged and hyperchromatic nuclei. Few areas of signet ring-like cancer cells were also noted. In addition, stroma showed thick bundles of haphazardly arranged collagen fibers along with areas of hyalinization. Tumour cells were seen whorling around the nerve bundle showing neurotropism and thus demonstrating perineural invasion [Figures 3-7].

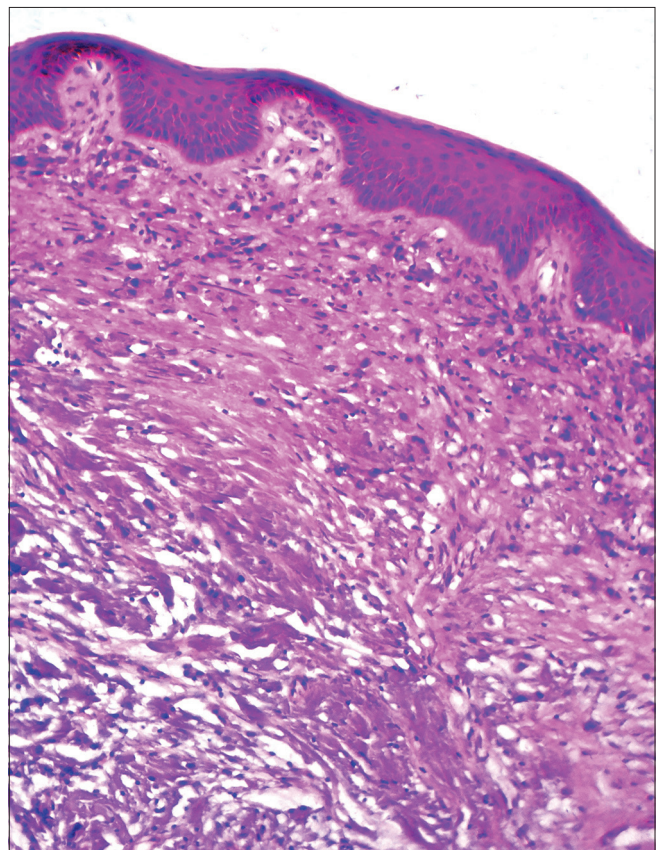
Current scenario suspected the presence of malignant tumor to the oral cavity with the primaries located in either breast or stomach. Certain bewildering histological features such as Indian file pattern and signet ring-like cells got us to suspect metastatic tumors to the oral cavity. They suggested of two possibilities lobular carcinoma of breast and diffuse type of gastric carcinoma. The patient was subjected to ultrasonography of abdomen and breast which both showed a normal study. The patient was also subjected to mammography which also showed a normal study. Finally, the patient was subjected to a panel of immunohistochemical markers to derive a final diagnosis irrespective of radiological investigations showing normal study.



**Figure 1:** Intraoral photograph showing an erythematous swelling



**Figure 2:** Fine needle aspiration cytology showing epithelial cells with hyperchromatic nuclei and abundant eosinophilic cytoplasm suggestive of malignant neoplastic cells (×10)



**Figure 3:** Section showing intact surface epithelium of stratified squamous variety (H&E, ×10)

### Immunohistochemistry being the benchmark

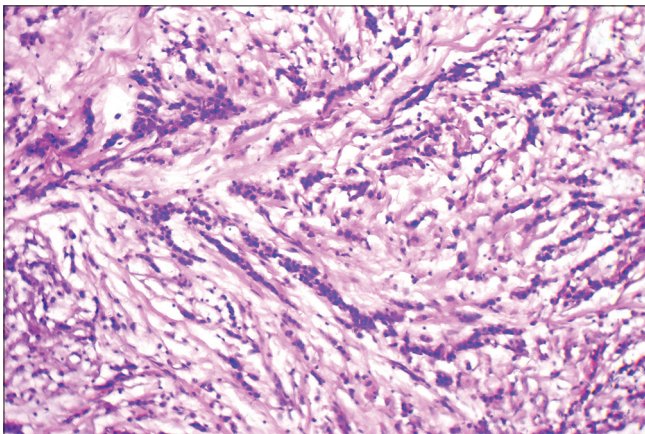
The tumor cells showed strong positivity for cytokeratin 7 (CK7), carcinoembryonic antigen, E-cadherin and vimentin which are all positive for a salivary gland lesions. Since E-cadherin is positive, gastric carcinoma was ruled out [Figures 8-11]. Likewise, to rule out lobular carcinoma of breast, markers such as CK20, estrogen receptor, progesterone receptor, androgen receptor, gross cystic disease fluid protein-15, GATA 3 and mammaglobin were used which all showed immunonegativity. A group of markers such as thyroid transcription factor-1 (TTF1) which is a marker for lung carcinoma and napsin A which is a marker for gallbladder carcinoma were both negative. Similarly, Ki 67 was immunonegative.

Based on the clinical, radiographic, histopathological and immunohistochemical evaluation, a diagnosis of PAC was made and the patient was referred to higher centers. On follow-up, it was noted that the patient underwent excision but turned up with recurrence of the lesion on the same site after 3 months for which she was further evaluated and monitored [Figures 12 and 13].

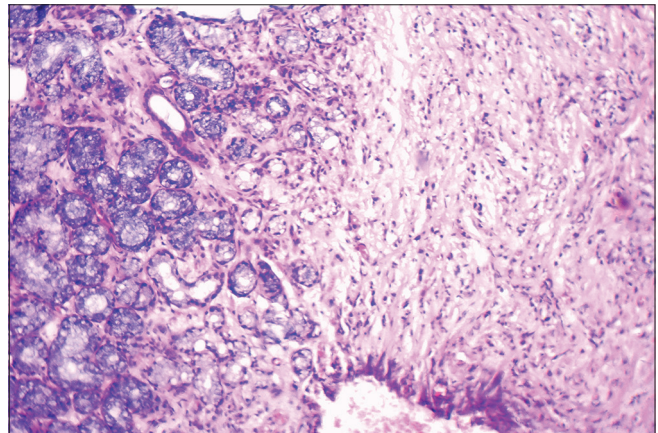
### DISCUSSION

Clinically, PAC presents as slow growing, asymptomatic with an indolent biology. Sometimes patients might have pain, bleeding and surface ulceration. The present case reported had surface bleeding and mild ulceration.<sup>[7]</sup>

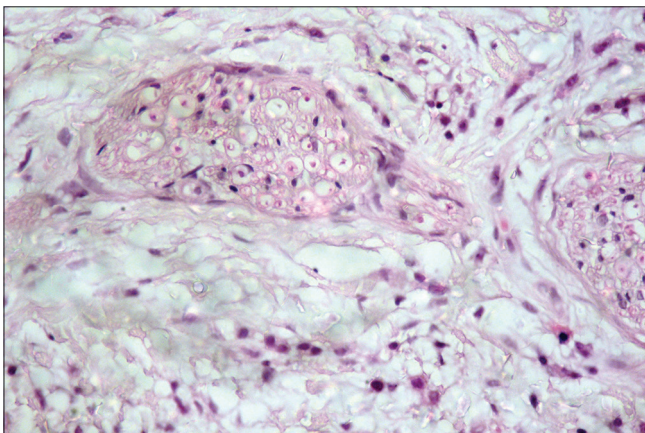
Histologically, PACs are noncapsulated, well circumscribed and show local aggressiveness and infiltration. Surface epithelium is usually intact. Tumor shows numerous growth patterns which includes solid, glandular, trabecular, cribriform and single file pattern. Tumor cells show neurotropism and perineural invasion. Tumor cells are round with indistinct cell borders and have eosinophilic cytoplasm and the nuclei are uniform round to ovoid in shape with inconspicuous nucleoli. Tumor cells are surrounded by a hyalinized stroma and a characteristic slate gray-blue stroma is noted. The present case showed predominant single file pattern of tumor cells arranged in hyalinized stroma along with perineural invasion.<sup>[6]</sup>



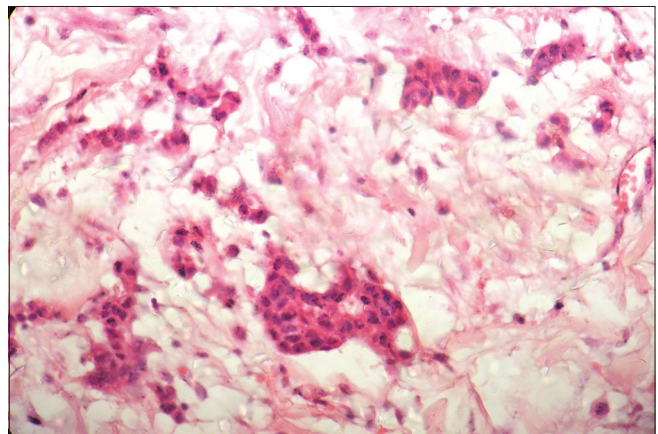
**Figure 4:** Section showing individual tumor cells in single file pattern (H&E, ×10)



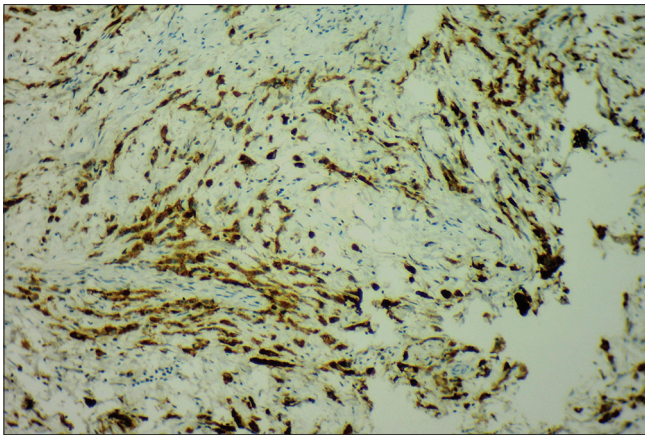
**Figure 5:** Section showing minor salivary glands (H&E, ×10)



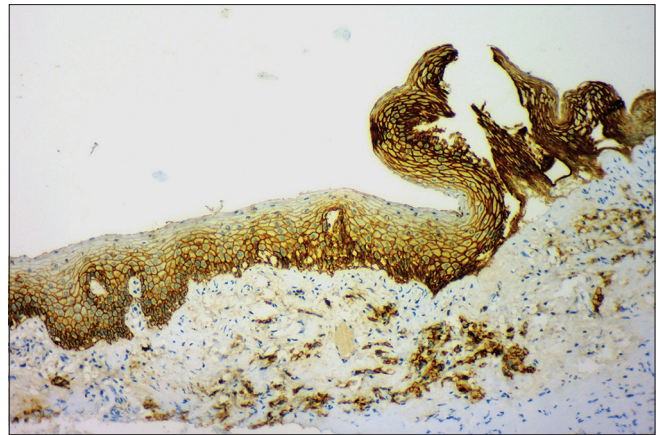
**Figure 6:** Section showing perineural invasion (H&E, ×40)



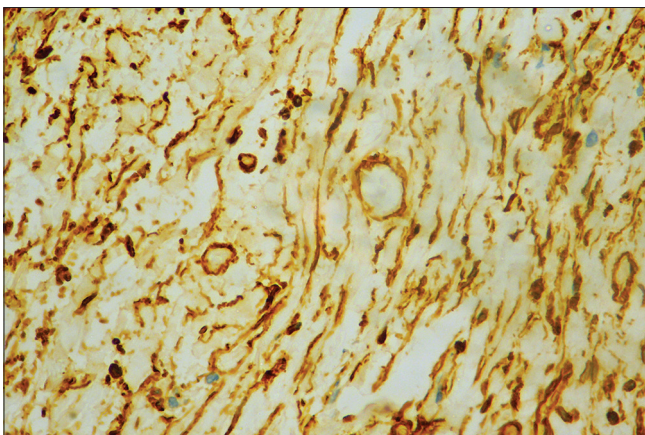
**Figure 7:** Picture on the lesional tissue (isomorphic small tumor islands) that helped us to identify it as polymorphous low-grade adenocarcinoma other than the single file pattern (×40)



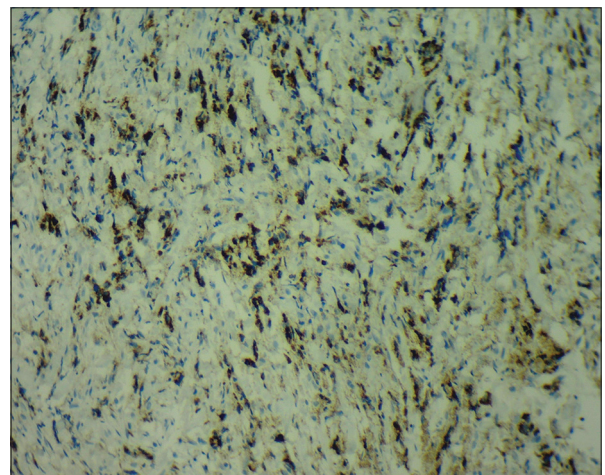
**Figure 8:** Section of the lesion stained with carcinoembryonic antigen showing strong positivity for tumor cells (x10)



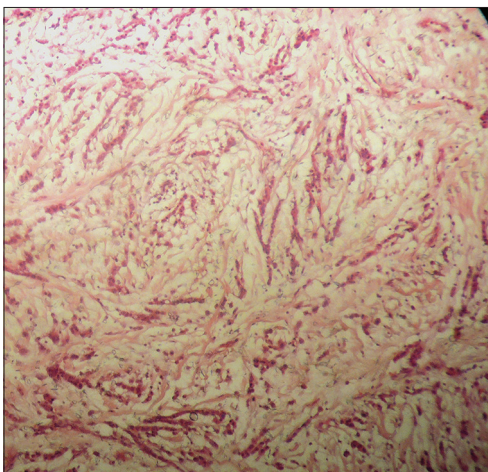
**Figure 9:** Immunohistochemical stain showed E-cadherin positivity (x10)



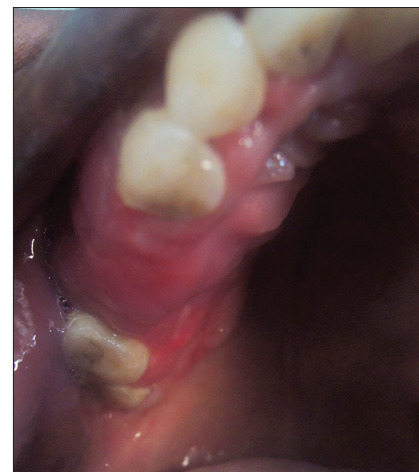**Figure 10:** Section of the lesion stained with vimentin showing strong positivity for tumor cells (x10)



**Figure 11:** Section of the lesion stained with cytokeratin 7 showing strong positivity for tumor cells (x10)



**Figure 12:** Histopathological picture of the recurrent lesion in the same site after surgery (x10)



**Figure 13:** Clinical picture of recurrent lesion

Since single file pattern predominated the histopathological picture; the present case was first thought of as a metastatic tumor to the oral cavity. It was important to rule out lobular carcinoma of the breast because it shows predominant

single file pattern as well which was given by Foote and Stewart.<sup>[8]</sup> Since both PAC and lobular carcinoma of the breast occurs predominantly in females, perplexity of the situation increased. It is suggested that estrogen receptor, progesterone receptor and GATA 3 expression

help in diagnosis of lobular breast carcinoma which are immunonegative in the present case.<sup>[9]</sup> Likewise, some evident signet ring-like cells were noted which obligated the case further to rule out diffuse carcinoma of stomach. E-cadherin positivity facilitated ruling out gastric carcinoma of stomach.<sup>[10]</sup>

Most common salivary gland tumor which could be confused with PAC in the oral cavity is adenoid cystic carcinoma (ACC). Both have infiltrative borders, variable growth patterns, perineural invasion and slow growth rate in common. Both tumors may recur but ACC is more aggressive with proliferative index. Histologically in ACC, cells are smaller, with hyperchromatic nuclei, less cytoplasm and high nuclear to cytoplasmic ratio.<sup>[11]</sup> The present case showed hyperchromatic nuclei and other features similar to ACC which imposed the requirement of immunohistochemistry for prompt diagnosis. Darling *et al.* in a study concluded that the only marker which differentiates PAC from ACC is vimentin which is positive in PAC and negative in ACC. Vimentin stains the luminal terminal duct cells from which PAC originates.<sup>[12]</sup> de Araujo *et al.* stated that uniform staining of CK7 and vimentin is enough for prompt diagnosis of PAC which are both positive in the present case.<sup>[7]</sup>

Concerning the prognosis of the lesion, metastasis is mostly curbed to the regional lymphnodes and the distant metastasis is very rare. Likewise, the rate of conversion of PAC to high grade or less differentiated variant is very rare. The present case explicated neoplastic cells in the FNAC picture and lead to suspicion for its aggressive behavior.<sup>[13]</sup> This notion was seized when Ki 67 which is a proliferative marker was used and showed immunonegativity. Distance metastasis to lung in the present case was ruled out; TTF1 marker was used which also showed immunonegativity. Metastasis to breast and abdomen was ruled out by performing mammography and ultrasound of abdomen, both of which showed a normal study in the present case.

Recommended treatment for PAC is surgery with generous margins. In case of recurrence or lymph node metastasis, radiotherapy is suggested. Although known to have good prognosis, local recurrence could be as high as 33%. The present case showed recurrence for which she was monitored at higher centers.<sup>[3,14]</sup>

## CONCLUSION

PAC could be mystifying because of analogous histological features with certain lesions of salivary gland origin and

certain other metastatic tumors to the oral cavity. Hence, to avoid diagnostic pitfalls, immunohistochemistry must be made mandatory for definitive diagnosis.

## Declaration of patient consent

The authors certify that they have obtained all appropriate patient consent forms. In the form the patient(s) has/have given his/her/their consent for his/her/their images and other clinical information to be reported in the journal. The patients understand that their names and initials will not be published and due efforts will be made to conceal their identity, but anonymity cannot be guaranteed.

## Financial support and sponsorship

Nil.

## Conflicts of interest

There are no conflicts of interest.

## REFERENCES

1. Evans HL, Batsakis JG. Polymorphous low-grade adenocarcinoma of minor salivary glands. A study of 14 cases of a distinctive neoplasm. *Cancer* 1984;53:935-42.
2. Batsakis JG, Pinkston GR, Luna MA, Byers RM, Sciubba JJ, Tillery GW, *et al.* Adenocarcinomas of the oral cavity: A clinicopathologic study of terminal duct carcinomas. *J Laryngol Otol* 1983;97:825-35.
3. Freedman PD, Lumerman H. Lobular carcinoma of intraoral minor salivary gland origin. Report of twelve cases. *Oral Surg Oral Med Oral Pathol* 1983;56:157-66.
4. Seethala RR, Stenman G. Update from the 4<sup>th</sup> edition of the World Health Organization classification of head and neck tumours: Tumors of the salivary gland. *Head Neck Pathol* 2017;11:55-67.
5. Waldron CA, el-Mofty SK, Gnepp DR. Tumors of the intraoral minor salivary glands: A demographic and histologic study of 426 cases. *Oral Surg Oral Med Oral Pathol* 1988;66:323-33.
6. Chatura KR. Polymorphous low grade adenocarcinoma. *J Oral Maxillofac Pathol* 2015;19:77-82.
7. de Araujo VC, Passador-Santos F, Turssi C, Soares AB, de Araujo NS. Polymorphous low-grade adenocarcinoma: An analysis of epidemiological studies and hints for pathologists. *Diagn Pathol* 2013;8:6.
8. Foote FW, Stewart FW. Lobular carcinoma *in situ*: A rare form of mammary cancer. *Am J Pathol* 1941;17:491-6.3.
9. Liu H, Shi J, Wilkerson ML, Lin F. Immunohistochemical evaluation of GATA3 expression in tumors and normal tissues: A useful immunomarker for breast and urothelial carcinomas. *Am J Clin Pathol* 2012;138:57-64.
10. Schrader KA, Masciari S, Boyd N, Wyrick S, Kaurah P, Senz J, *et al.* Hereditary diffuse gastric cancer: Association with lobular breast cancer. *Fam Cancer* 2008;7:73-82.
11. Fatahzadeh M. Palatal polymorphous low grade adenocarcinoma: Case report and review of diagnostic challenges. *Arch Orolfac Sci* 2012;7:92-100.
12. Darling MR, Schneider JW, Phillips VM. Polymorphous low-grade adenocarcinoma and adenoid cystic carcinoma: A review and comparison of immunohistochemical markers. *Oral Oncol* 2002;38:641-5.
13. Simpson RH, Pereira EM, Ribeiro AC, Abdulkadir A, Reis-Filho JS. Polymorphous low-grade adenocarcinoma of the salivary glands with transformation to high-grade carcinoma. *Histopathology* 2002;41:250-9.
14. Surya V, Tupkari JV, Joy T, Verma P. Histopathological spectrum of polymorphous low-grade adenocarcinoma. *J Oral Maxillofac Pathol* 2015;19:266.