

HOSTED BY



ELSEVIER

Contents lists available at ScienceDirect

Chinese Journal of Traumatology

journal homepage: <http://www.elsevier.com/locate/CJTEE>

Original article

Pattern of rubber bullet injuries in the lower limbs: A report from Kashmir

Shabir Ahmed Dhar^{a,*}, Tahir Ahmed Dar^a, Sharief Ahmed Wani^b, Saheel Maajid^a, Jawed Ahmed Bhat^a, Naseer Ahmed Mir^a, Imtiyaz Hussain Dar^c, Shahid Hussain^a^a Department of Orthopaedics, SKIMS Medical College/Hospital Bemina, Srinagar 190001, Kashmir, India^b Directorate of Health Services, Srinagar 190001, Kashmir, India^c Government Hospital for Bone and Joint Surgery Barzulla, Srinagar 190001, Kashmir, India

ARTICLE INFO

Article history:

Received 14 December 2014

Received in revised form

7 May 2015

Accepted 15 May 2015

Available online 23 December 2015

Keywords:

Rubber bullet

Non-lethal

Crowd control

ABSTRACT

Purpose: Rubber bullets are considered a non-lethal method of crowd control and are being used over the world. However the literature regarding the pattern and management of these injuries is scarce for the forensic pathologist as well as for the traumatologist. The objective of this report was to add our experience to the existing literature.

Methods: From June 2008 to August 2010 the Government Hospital for Bone and Joint Surgery Barzulla and the Department of Orthopaedics, SKIMS Medical College/Hospital Bemina Srinagar received 28 patients for management of their orthopaedic injuries caused by rubber bullets. We documented all injuries and also recorded the management issues and complications that we encountered.

Results: All patients were males with an age range of 11–32 years and were civilians who had been hit by rubber bullets fired by the police and the paramilitary forces. Among them, 19 patients had injuries of the lower limbs and 9 patients had injuries of the upper limbs. All patients were received within 6 h of being shot.

Conclusion: Our findings suggest that these weapons are capable of causing significant injuries including fractures and it is important for the surgeon to be well versed with the management of such injuries especially in areas of unrest. The report is also supportive of the opinion that these weapons are lethal and should hence be reclassified.

© 2016 Production and hosting by Elsevier B.V. on behalf of Daping Hospital and the Research Institute of Surgery of the Third Military Medical University. This is an open access article under the CC BY-NC-ND license (<http://creativecommons.org/licenses/by-nc-nd/4.0/>).

Introduction

Rubber bullets are rubber or rubber-coated projectiles that are fired from riot guns. They are intended to be a non-lethal alternative to metal projectiles. Rubber bullets were used for the first time in Northern Ireland in 1970.^{1,2} These bullets were introduced with an idea to reduce injuries and casualties caused by conventional firearms. It is with this in mind that these bullets are considered as a “non-lethal” method of crowd control.

Rubber bullets are blunt-nosed with a muzzle velocity of around 70 m/s and a kinetic energy of nearly 400 J. The transferred kinetic energy depends on the angle and the distance at which the bullet

strikes. A few reports of the serious injuries caused by these bullets have been published.^{3–6}

Most of the reports focus on injuries of relatively vulnerable tissues like the eyes, brain and the lungs while reporting the mortality and morbidity caused by rubber bullets.^{3–7} It is often recommended that the police should aim at the limbs while using rubber bullets.^{6,8,9} However proper rules of engagement are not followed during riot control, converting these non-lethal weapons into lethal weapons.

This report which focuses exclusively on injuries of the extremities highlights the fact that even in the limbs the rubber bullets can cause significant morbidity and therefore they should not be considered a safe method for controlling crowds.

Materials and methods

From June 2008 to August 2010, the Government Hospital for Bone and Joint Surgery Barzulla and the Department of

* Corresponding author.

E-mail address: shabirdhar@yahoo.co.in (S.A. Dhar).

Peer review under responsibility of Daping Hospital and the Research Institute of Surgery of the Third Military Medical University.

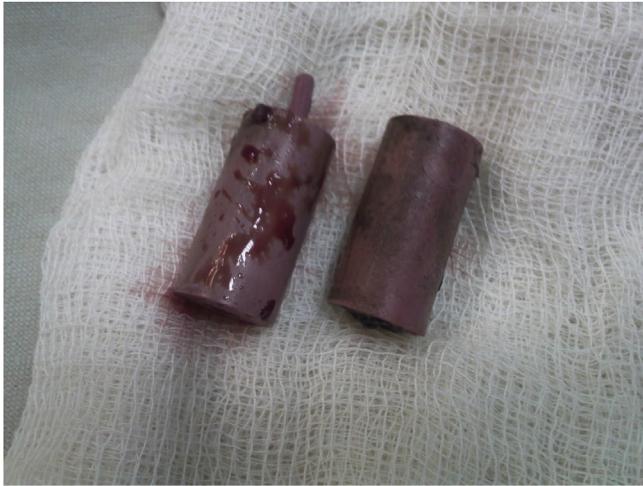

Fig. 1. Photograph of the rubber bullets.



Fig. 2. The rubber bullet in comparison to conventional munitions.

examination of the patients was recorded and relevant investigations ordered. Radiographs of all the patients were taken and studied. Relevant findings were noted down.

We noted the injured area, the neurological and vascular status of the limb and the radiographic findings. The surgical procedures carried out on these patients were also recorded.

It is difficult to obtain figures of the rubber bullet use from the authorities in Kashmir due to difficult conditions. However in the summer of 2010, the pellet gun which fires multiple rubber projectiles was used for the first time. This paper mainly reported injuries caused by the rubber bullet which is fired as a single projectile (weighs 48 g and has a diameter of 1.8 cm). Although the rubber bullets are felt hard to the touch, they are easily bent, flattened and distorted on impact.

It must be recalled that there is no expectation of pinpoint accuracy with these bullets. It is expected that 80% of shots fired form a 30 cm circle (or better) at 20 m. According to the manufacturers, less lethal ammunition is light and small and needs to travel fast to be effective and to be accurate outdoors if there is a breeze. Incorrect use of less lethal ammunition can cause serious injury, even death. Some penetration is accepted as “less lethal”. The clay test at 20 m should have average penetration of less than 44 mm. The effective range at which the bullet will cause severe pain extends beyond the 20 m minimum range. At a range of less than 20 m there is almost certainly going to be penetration although this is dependent, as at all ranges, on how many layers of clothing the target is wearing, and velocity which depends on the type of rifle used. The accuracy level is best at 20 m and the dispersion increases from there on out.

Results

Totally, 28 patients with penetrating injuries of the upper and lower extremities were treated. All patients were males with an age range of 11–32 years. All the patients were civilians who had been hit by rubber bullets fired by the police and the paramilitary forces (Figs. 1 and 2).

Among them, 19 patients had injuries of the lower limbs (Figs. 3 and 4) and 9 patients had injuries of the upper limbs (Figs. 5 and 6). All patients were received within 6 h of being shot.

There were 8 fractures, 4 nerve injuries, 3 tendon injuries and 10 isolated lacerations. In 3 cases the bullet was lodged in the soft tissues and in another 2 cases the rubber bullet was lodged in an intraarticular location in the knee (Table 1).

All the patients were admitted on an indoor basis. A thorough history was taken and physical examination was conducted. The procedures were conducted under general or local anaesthesia as required.

Orthopaedics, SKIMS Medical College/Hospital Bemina Srinagar received 28 patients for management of their orthopaedic injuries. All these patients had been injured by rubber bullets. As it was difficult to ascertain the nature of the wounding missile from the history, only those patients who had a retained rubber bullet in the wound or got the rubber bullet to the hospital were included in the study. As such cases were relatively uncommon, the study proceeded slowly over three years. The history and physical

Table 1
Injury types and treatment.

Injury type	Area involved	Immediate procedure
Fractures (<i>n</i> = 8)	1 patellar fracture	Cerclage wiring
	1 fibular fracture	Conservative
	2 metacarpal fractures	K wiring
	4 phalangeal fractures	K wiring
Nerve injuries (<i>n</i> = 4)	2 common peroneal nerve injuries	Conservative
	1 posterior interosseous nerve injury	Conservative
	1 sural nerve injury	Conservative
Tendon injuries (<i>n</i> = 3)	3 extensor tendon injuries of the digits	Debridement and reconstruction
Isolated lacerations (<i>n</i> = 10)	6 thigh lacerations	Debridement
	4 calf lacerations	Debridement
Retained bullets (late presentation, <i>n</i> = 3)	2 in the thigh	Debridement and removal
	1 around soft tissue of the knee	Debridement and removal
Intraarticular bullets (<i>n</i> = 2)	2 in the knee	Debridement and removal

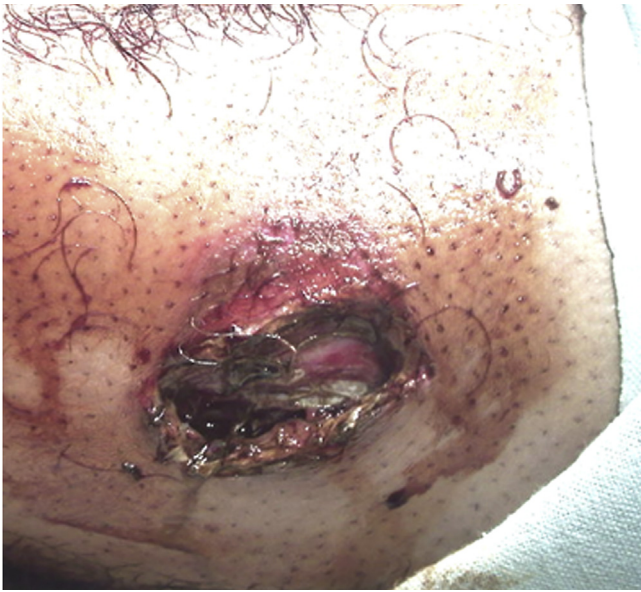

Fig. 3. Entry wound at the thigh.

The patellar fracture occurred in a patient who reported that the muzzle of the gun was kept on his knee before he was shot. Almost all other patients reported that they were shot from close range. A majority of the patients had been shot through the clothing that they were wearing.

Four patients reported with nerve injuries. After wound debridement, conservative management was done. The sural nerve injury did not recover. There was partial recovery of the common peroneal nerve injury in the 2 patients who had complete involvement of that nerve at presentation. The patient with the posterior interosseus nerve injury refused a tendon transfer surgery which was offered 1 year after the injury.

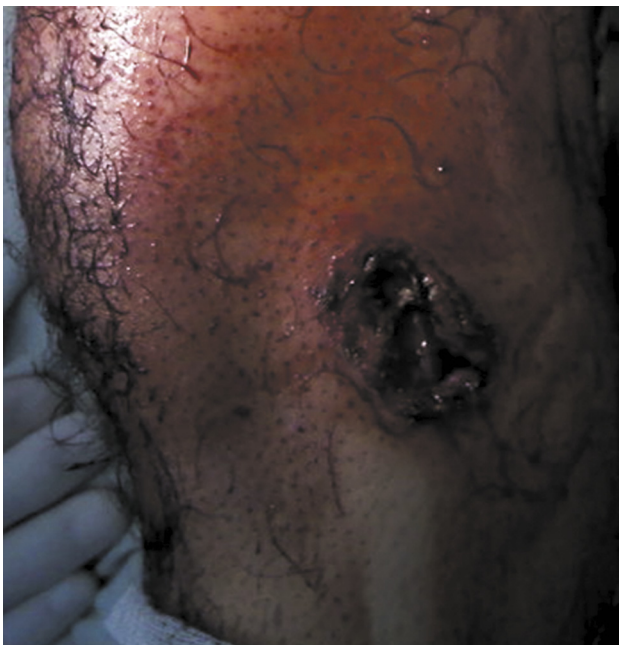

Fig. 4. Entry wound of the bullet entering the knee. The bullet was in an intraarticular location.

The skin was debrided to the area where it started bleeding. Tendon injuries were debrided and reconstructed, but significant stiffness ensued due to underlying comminuted phalangeal fractures in two patients.

Three cases presented late with primary wound management done at a local level. Infection of the wound was the cause for referral. All cases were treated with removal of the bullet, wound debridement and washes.

In two cases the bullet was present within the knee joint. Both bullets were retrieved and repeated joint washes were given.

A significant number of wounds were larger than the size of the rubber bullet. This had probably occurred due to the bullet hitting nose first and then destabilising into a sideways presentation. The wound was surrounded by skin splits which were debrided. Smaller wounds were managed by dressings and larger ones were managed in the operating theatre by longitudinal incisions in the fascia and skin to relieve the haematoma and remove the debris and the bullet.

The muscle was debrided along the time-honoured concept of colour, consistency, contractility and circulation. The area was allowed to drain in cases with extensive damage. The primary wound tract, otherwise known as the permanent cavity was cleaned and washed. This cavity is the result of the actual crushing of tissue directly in the bullet's path. The contusion zone of muscle adjacent to the bullet track was washed. The concussion zone formed by the shock waves produced during cavitation which causes damage distant from the immediate bullet contact area was not explored according to the principles of debridement.

We used second generation antibiotics and aminoglycosides in all cases at the outset before obtaining culture sensitivity reports. Even though rubber bullets are sometimes shot in a rebound pattern which may increase the chances of infection, we encountered only two cases which developed infection. Both wounds needed several debridements and culture sensitivity-based antibiotics.

Discussion

Rubber bullets are regarded as a non-lethal method of crowd control. They are expected to produce contusions, abrasions, and hematomas. Reports of their propensity to cause severe injuries have been few and far between with most of the literature constituting case reports.^{3–6} Some reports concern sporting accidents and suicide.^{7,10}

The blunt tip of the bullet causes compression or crushing injury to the area of impact. This makes the bullet unstable in flight and it may tumble end over end and impact the patient sideways. It is also known to generate shock waves which cause fractures and lacerations around the area of the impact. Force of impact is controlled by several factors, including magnitude (proportional to mass of the missile, acceleration-deceleration, and area of application), duration of application, and rate of onset.¹¹ The hardness of the bullet also has an effect on the injury pattern.

When strains applied by the blunt rubber bullet deform tissue beyond its limits of elasticity (tendency to regain its original state) or viscosity (resistance to change in shape during motion), cohesion of tissue surface is lost, and disruption with penetration of the missile into the body takes place.⁶

Wang and colleagues¹² described three zones of injury secondary to the missile's projector. The first zone of injury is the primary wound tract, otherwise known as the permanent cavity. This cavity results from the actual crushing of tissue directly in the bullet's path. The second zone of injury is a contusion zone of muscle adjacent to the bullet track. Finally, the concussion zone is

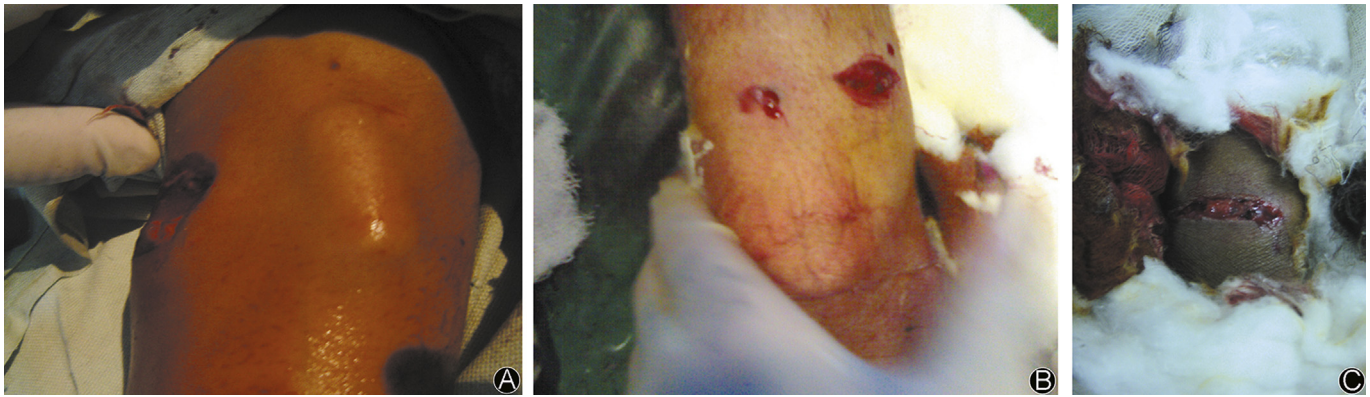


Fig. 5. A: Bullet lodged subcutaneously in the elbow after damaging the supinator and the posterior interosseus nerve; B: Entry and exit wounds; C: A laceration created by the rubber bullet.

the area where the shock waves produced during cavitation have caused damage distant from the immediate bullet contact area.

When a missile enters tissue, a temporary cavity is created along the primary wound tract through the process of cavitation.¹³ Cavitation occurs when energy distribution from one point spreads into adjacent tissue; the energy of the moving bullet pushes tissue particles away from the impact point, producing a cavity. The resultant stretching, compressing, and shearing of tissue may produce damage extending several centimetres lateral to the bullet track.

Most low-velocity gunshot injuries may be safely treated non-operatively on an outpatient basis, as these wounds usually involve only the skin, subcutaneous and/or muscle tissue, and minor cortical bone fragments. Local wound care consists of superficial irrigation and careful cleansing followed by a dressing. Rubber bullet injuries with deeper penetration and associated fractures require immediate and aggressive irrigation and debridement. The margins of the entrance and exit wounds should be excised and the missile tract thoroughly irrigated. A wide debridement of devitalized tissue must be performed and foreign bodies removed. The patient should then be returned to the operating room every 48–72 h for serial debridement. All contaminated subcutaneous fat and devitalized muscle must be removed. Bone without soft tissue attachment should be excised. Elimination of dead space is vital. Primary closure of bullet wounds must be avoided because of the

possibility of contamination. The fracture should be stabilized by external or internal fixation. Secondary wound closure can usually be performed within 5–7 days after injury.

Almost all the literature about rubber bullet injuries pertains to injuries of the eyes, chest, brain and the abdomen. Injuries in these areas are thought to be more severe due to the fact that the elasticity and the viscosity is lower.¹⁴

The extremities are thought to have a higher elasticity and are hence supposed to be more resistant to injury. However in a study by Mahajna et al⁶ after analysis of medical records for 151 casualties with injuries proved to be caused by rubber bullets showed that 61% had blunt injuries and 39% had penetrating injuries. Two people died of penetrating ocular injuries into the brain and one died of postoperative aspiration after a knee injury. Some recommendations were made to the Israeli police force and are mentioned by Mahajna et al.⁶ These included (1) the minimum firing range was changed to 50 m; (2) police are told to aim exclusively at the lower limbs.

However in spite of being a signatory to the Geneva Convention, the paramilitary personnel sometimes indulge in point-blank firing because in the heat of the battle with crowds, the rules of engagement become a casualty.

Our data show that injuries of the extremities also involve a variety of structures which sometimes leave behind significant morbidity. Besides soft tissue injuries, the bullets caused tendon injuries, nerve injuries and fractures. Interestingly enough all three bullets that were retained caused infection which required removal of the bullets and antibiotic washes and dressings. This probably points to the fact that the bullets need to be removed in view of their propensity to cause infection. This is a question that has been discussed elsewhere in literature in a case with a retained bullet in the ethmoid sinus.¹⁵

Rubber bullets should not be considered as a safe method of crowd control. Israeli doctors have argued after a review of the use of rubber bullets by Israeli police against Palestinians showed a high number of injuries and some deaths.¹⁶ However on the other end of the scale MacDonald et al¹⁷ argued that injuries sustained during police use-of-force events affect thousands of police officers and civilians in the United States each year. Incidence of these injuries can be reduced dramatically when law enforcement agencies responsibly employ less-lethal weapons in lieu of physical force. Kobayashi et al^{18–20} reported that it is becoming increasingly important for the forensic pathologist to become familiar with these injuries as the use of non-lethal weapons is increasing. Wani et al²¹ also reported on a number of vascular injuries caused by the non-lethal weapons and found them to be no different as a management challenge from any other vascular

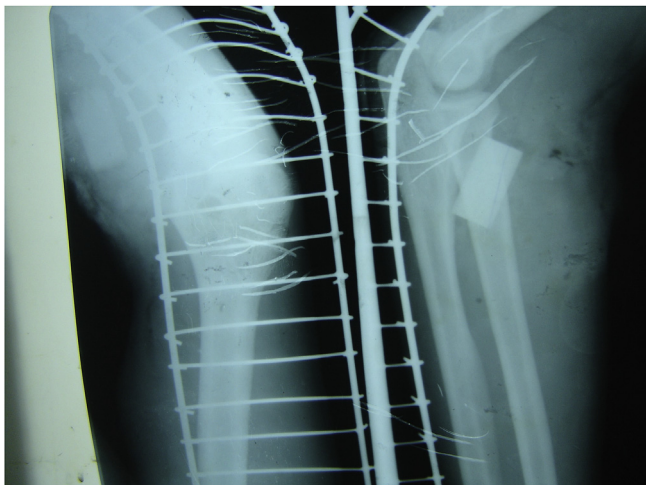


Fig. 6. Radiograph of the above patient.

injury. Amelot et al²² presented a penetrating craniocerebral injury due to a rubber bullet and questioned the non-lethality of these weapons. Contargyris et al²³ mentioned that it is important for the medical staff not to underestimate the severity of these injuries. Many recent reports have highlighted the morbidity and mortality caused by these weapons.^{3,4,24}

Conclusion

Rubber bullets often cause significant damage to all tissues of the limb including the bone. The treating surgeon should be aware of the potential seriousness of these injuries and manage them on the pattern of other ballistic injury. Attempt should be made to retrieve the rubber bullet as it is likely to cause infection and a consequent draining sinus.

The conditions under which the rubber bullets are fired also have an effect on the wounding capacity. Shorter firing distances may increase both the mortality and morbidity. It is also important to understand that these weapons are capable of causing significant morbidity and hence there is a need to reclassify them as less lethal or lethal weapons.

References

1. Millar R, Rutherford WH, Johnston S, et al. Injuries caused by rubber bullets: a report on 90 patients. *Br J Surg*. 1975;62:480–486.
2. Roche L. Injuries caused by plastic bullets compared with those caused by rubber bullets. *Lancet*. 1983;1:919–920.
3. Rezende-Neto J, Silva FD, Porto LB, et al. Penetrating injury to the chest by an attenuated energy projectile: a case report and literature review of thoracic injuries caused by “less-lethal” munitions. *World J Emerg Surg*. 2009;4:26.
4. Khonsari RH, Fleuridas G, Arzul L, et al. Severe facial rubber bullet injuries: less lethal but extremely harmful weapons. *Injury*. 2010;41:73–76.
5. Lavy T, Asleh SA. Ocular rubber bullet injuries. *Eye (Lond)*. 2003;17:821–824.
6. Mahajna A, Aboud N, Harbaji I, et al. Blunt and penetrating injuries caused by rubber bullets during the Israeli-Arab conflict in October, 2000: a retrospective study. *Lancet*. 2002;359:1795–1800.
7. Welsh NH, Howes F, Lever J. Eye injuries associated with ‘war games’. *S Afr Med J*. 1989;76:270–271.
8. Hiss J, Hellman FN, Kahana T. Rubber and plastic ammunition lethal injuries: the Israeli experience. *Med Sci Law*. 1997;37:139–144.
9. Hiss J, Kahana T. The fatalities of the intifada (uprising): the first five years. *J Forensic Sci Soc*. 1994;34:225–229.
10. Voiglio EJ, Fanton L, Caillot JL, et al. Suicide with “non-lethal” firearm. *Lancet*. 1998;352:882.
11. Barach E, Tomlanovich M, Nowak R. Ballistics: a pathophysiologic examination of the wounding mechanisms of firearms—part I. *J Trauma*. 1986;26:225–235.
12. Wang ZG, Feng JX, Liu YQ. Pathomorphological observations of gunshot wounds. *Acta Chir Scand Suppl*. 1982;508:185–195.
13. Swan KG, Swan RC. Wound ballistics. In: Swan KG, ed. *Gunshot Wounds: Pathophysiology and Management*. Chicago: Year Book Medical Publishers; 1989:7–20.
14. National Research Council Committee on Trauma Research. Injury biomechanics research and the prevention of impact injury. Committee on Trauma Research. In: *Injury in America: A Continuing Public Health Problem*. Washington DC: National Academy Press; 1985:48.
15. Gross M, Regev E, Hamdan K, et al. Penetrating rubber bullet into the ethmoid sinus: should the bullet be removed? *Otolaryngol Head Neck Surg*. 2005;133:814–816.
16. Siegel-Itzkovich J. Israeli doctors warn against rubber bullets. *BMJ*. 2002;324:1296.
17. MacDonald JM, Kaminski RJ, Smith MR. The effect of less-lethal weapons on injuries in police use-of-force events. *Am J Public Health*. 2009;99:2268–2274.
18. Lewer N. Benign intervention and non-lethality: wishful thinking for the 21st century. In: Dando M, ed. *Non-lethal Weapons: Technological and Operational Prospects*. London: Jane’s Publishing; 2000.
19. Wright S. *An Appraisal of the Technologies of Political Control*. European Parliament, Directorate General for Research, Directorate B, The STOA Programme; 1998.
20. Kobayashi M, Mellen PF. Rubber bullet injury: case report with autopsy observation and literature review. *Am J Forensic Med Pathol*. 2009;30:262–267.
21. Wani ML, Ahangar AG, Ganie FA, et al. Pattern, presentation and management of vascular injuries due to pellets and rubber bullets in a conflict zone. *J Emerg Trauma Shock*. 2013;6:155–158.
22. Amelot A, Goutagny S, Ricome S, et al. Penetrating craniocerebral injury caused by a rubber bullet questions the relative harmlessness of these weapons. *Am J Emerg Med*. 2013;31:636. e5–7.
23. Contargyris C, Peytel E. Sudden death caused by a less lethal weapon chest-wall injury (Comotio cordis). *Ann Fr Anesth Reanim*. 2012;31:469–471.
24. Kalebi A, Olumbe AK. Death following rubber bullet wounds to the chest: case report. *East Afr Med J*. 2005;82:382–384.