


# Complex Fractures of the Sacrum with Spinopelvic Dissociation Treated Surgically with Iliolumbar Fixation\*

## *Fraturas complexas do sacro com dissociação espinopélvica tratadas cirurgicamente com fixação iliolumbar*

Alberto Kazuo Miyamoto<sup>1</sup>  Xavier Soler I. Graells<sup>1,2</sup> André Luis Sebben<sup>1</sup> Marcel Luiz Benato<sup>1</sup>  
Pedro Grein Del Santoro<sup>1</sup> Álynson Larocca Kulcheski<sup>1</sup>

<sup>1</sup>Spinal Surgery Group, Hospital do Trabalhador, Curitiba, PR, Brasil

<sup>2</sup>Departament of Orthopedics and Traumatology, Hospital das Clínicas, Universidade Federal do Paraná (UFPR), Curitiba, PR, Brasil

Address for correspondence Alberto Kazuo Miyamoto, Hospital do Trabalhador, Cirurgia da Coluna, Rua Martin Afonso 1.900, apto. 404, Bigorriho, Curitiba, PR, 80730-030, Brasil (e-mail: betokm@hotmail.com).

Rev Bras Ortop 2020;55(3):304–309.

### Abstract

**Objective** To analyze a series of cases of complex fractures of the sacrum with spinopelvic dissociation surgically treated with iliolumbar fixation, and to review the existing medical literature.

**Methods** For the analysis, the medical records of the cases operated using the Schildhauer et al technique for fixation were retrospectively evaluated, and followed up for at least 12 months. The functional results were assessed using the visual analog scale (VAS) for pain and the Oswestry disability index, version 2.0. The data were compared with those of the existing medical literature.

**Results** Six cases were analyzed, four of which evolved with moderate disability, one, with minimal disability, and one, with severe disability. Three cases that presented neurological deficits obtained significant improvement. Only one case evolved with pulmonary thromboembolic complications.

**Conclusion** The Schildhauer et al technique is an efficient technique for the fixation of complex sacral fractures with spinopelvic dissociation. The patients evolved with good functional results. Early weight-bearing has been shown to be safe with the use of this treatment.

### Keywords

- ▶ sacrum
- ▶ wounds and injuries
- ▶ spinal injuries
- ▶ spinal fractures

### Resumo

**Objetivo** Analisar uma série de casos de fraturas complexas do sacro com dissociação espinopélvica tratados cirurgicamente com fixação iliolumbar, e revisar a literatura médica existente.

**Métodos** Para a análise, foram avaliados retrospectivamente os prontuários médicos de casos operados utilizando a técnica de Schildhauer et al para fixação. O período de acompanhamento foi de pelo menos 12 meses. Os resultados funcionais foram

\* Work developed at the Spinal Surgery Group, Hospital do Trabalhador, Curitiba, PR, Brazil.

**Palavras-chave**

- ▶ sacro
- ▶ ferimentos e lesões
- ▶ traumatismos da coluna vertebral
- ▶ fraturas da coluna vertebral

avaliados por meio da escala visual analógica (EVA) de dor e do índice de incapacidade de Oswestry, versão 2.0. Os dados foram comparados com os da literatura médica existente.

**Resultados** Seis casos foram analisados, sendo que quatro evoluíram com incapacidade moderada, um, com incapacidade mínima, e um, com incapacidade grave. Três casos que apresentavam déficit neurológico obtiveram melhora significativa. Apenas um caso evoluiu com complicação tromboembólica pulmonar.

**Conclusão** A técnica de Schildhauer et al é eficiente para a fixação de fraturas complexas de sacro com dissociação espinopélvica. Os pacientes evoluíram com bons resultados funcionais. A liberação precoce de sustentação de carga demonstrou-se segura com o uso deste tratamento.

**Introduction**

Sacrum fractures correspond to 1% of all spinal column fractures, and most of the time they are associated with pelvic injuries. Approximately 60% of sacral fractures go unnoticed in the patient's initial care. They are largely caused by high-energy traumas such as automobile accidents, falls from heights, and suicide attempts,<sup>1,2</sup> which are also known as "suicidal jumper's fracture".

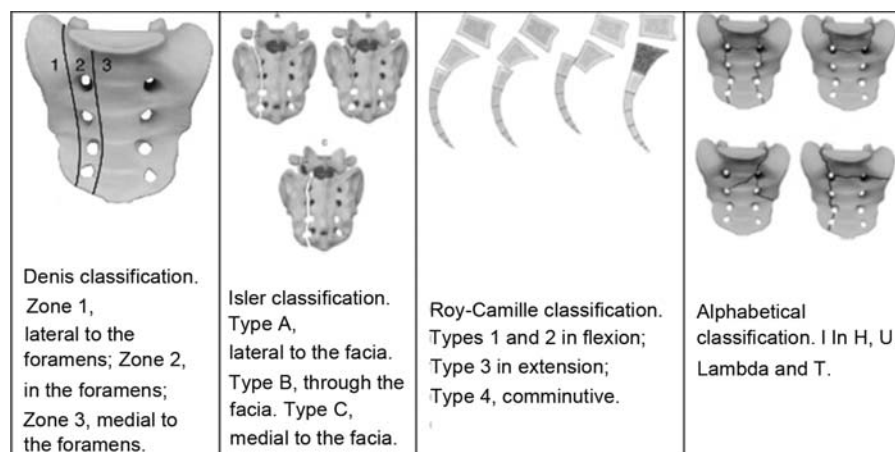
Sacrum fractures were first classified by Denis as types I, II and III lesions. In addition to the Denis classification, Isler divided type-II fractures into subtypes A, B and C, considering the fracture trait through the articular facet of L5-S1. Subsequently, Roy-Camille described type-III fractures with a transverse trait, according to the mechanism of trauma: flexion, extension and comminutive. Finally, fractures involving both sides of the sacrum can be classified as they resemble the letters of the Latin and Greek alphabets (U, T, H, and  $\lambda$  [lambda])<sup>1,3,4</sup> (→ **Figure 1**).<sup>5</sup> Another way to classify sacrum fractures is through the Arbeitsgemeinschaft für Osteosynthesefragen (AO, Association for the Study of Internal Fixation, in German) spine classification.<sup>6</sup>

The treatment varies according to the stability of the fracture. The conservative treatment, with rest and removal

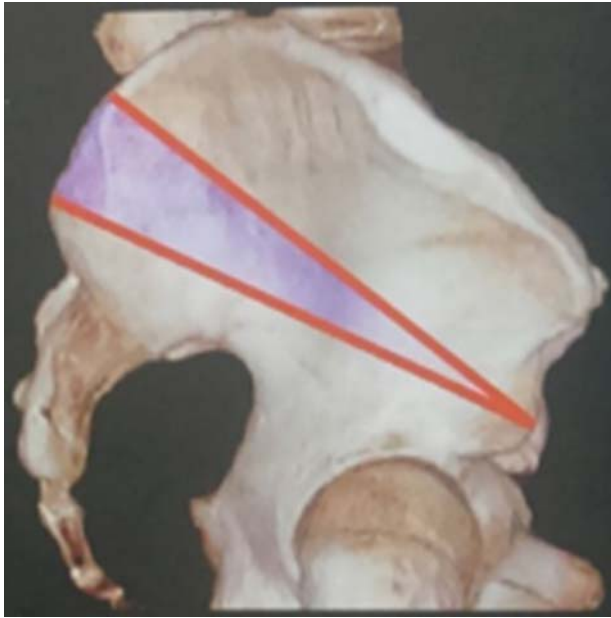of the axial load, may be performed on the sacrum. The surgical treatment can be performed in different ways: sacral screws and plaques, and, in cases of complex fractures of the sacrum with vertical instability, it is necessary to perform surgical stabilization between the lumbar spine and pelvis with systems that offer greater stability.<sup>1,4</sup>

In the Schildhauer et al<sup>7</sup> technique to insert the iliac screw, the iliac wing is partially exposed. After that, the entry point of the screw 1 cm below the posterosuperior iliac spine is identified. At this point, an osteotomy of 1.5 cm is performed to accommodate the head of the screw in the iliac. With a puncher, or a pedicle prosecutor, the tunnel is directed into a trajectory 45° caudal and 35° lateral, pointing the perforator or pedicle prosecutor at the upper gluteal notch. After confirming the trajectory with the aid of a fluoroscope, the screw is inserted and, according to the technique used, it must be at least 70 mm in length<sup>7,8</sup> (→ **Figure 2**).

The present work aims to review the existing medical literature and report the experience of a tertiary trauma service in the treatment of a series of cases of sacral fracture with instability, in which the spinopelvic fixation was performed using the technique of Schildhauer et al<sup>7</sup> for the insertion of the iliac screws.



**Fig. 1** Different classifications of sacral fractures. Reproduced from: Vaccaro et al.<sup>5</sup>



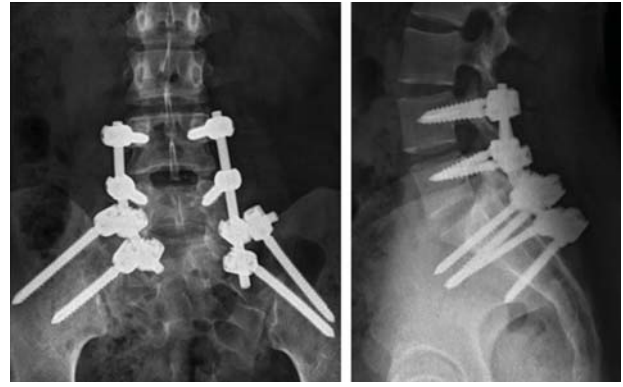
**Fig. 2** Iliac Screw path by the Schildhauer et al<sup>7</sup> technique. Reproduced from: Schildhauer et al.<sup>7</sup>

## Method

This is a retrospective study in which an analysis of the clinical evolution of a series of cases, as well as their complications, was made, and the results were compared to those of the currently available medical literature.

The present study was approved by the Ethics Committee of the university hospital under number 2,661,464.

A total of six cases of complex sacrum fractures with vertical instability were selected, which were surgically treated with spinopelvic fixation through the posterior pathway. For the choice of technique and the surgical planning, anteroposterior (AP) and profile (P) incidence radiographs of the sacrum, inlet and outlet incidence radiographs of the pelvis, and tomography with three-dimensional reconstructions (→ **Figure 3**) were taken. Through a median approach, levels L4 and L5 of the spine, the sacrum and both iliac bones were exposed for instrumentation. In cases with nerve compression, laminectomy and posterior decompression were performed with removal of the canal fragments and foraminal release. In fractures with large deviation (> 1 cm), indirect reduction was performed with the aid of reduction calipers, traction and Schanz pins as joysticks. Pedicular screws were inserted into L4, L5, S1 (when the fracture trait enabled it) and two screws



**Fig. 4** Postoperative radiographs in anteroposterior and profile incidences showing the fixation system.

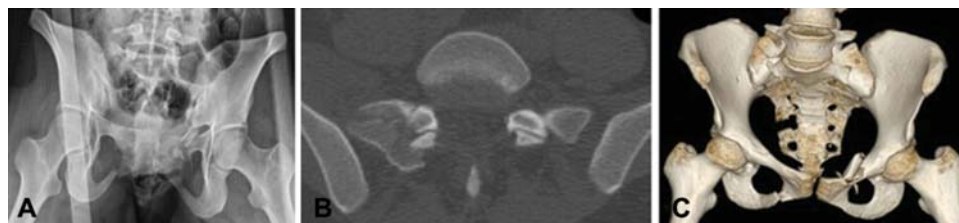were inserted into each iliac bone using the Schildhauer et al<sup>7</sup> technique (→ **Figure 4**).<sup>7,8</sup>

The inclusion criteria were cases of sacrum fractures with vertical and spinopelvic dissociation instability, with indication of surgical treatment in high-energy trauma victims with or without associated injuries, regardless of gender and fracture type, in which the surgical option was spinopelvic fixation by the aforementioned technique. Cases of sacral fractures that did not present lumbopelvic instability, those with no surgical indication, those treated with fixation that was not spinopelvic, as well as pathological fractures caused by low-energy mechanisms were excluded from the study.

After the selection of the patients, the epidemiological factors were analyzed, such as gender and age. Other factors analyzed were: presence or absence of neurological injury; associated injuries; mechanism of trauma; trauma-related clinical complications; complications related to the surgical procedure and treatment; and clinical evolution with a minimum of 12 months of follow-up. The outpatient follow-up was based on regular return visits: after 15 days of surgery, after 45 days, after 90 days, after 180 days of the procedure, and biannual return after this period, if there were no particularities involving the case. The clinical evaluation was based on data recorded on the medical records and on the Oswestry disability index, version 2.0,<sup>9</sup> and on the visual analog scale (VAS) for pain, which are applied in all surgical cases as a part of the service's protocol.

## Case Analysis

Among the 6 cases analyzed in this series, 3 (50%) were due to automobile accidents, and 3 (50%) to attempted suicide. The



**Fig. 3** Complementary imaging exams. A) radiograph in the outlet incidence of the pelvis; B) computerized axial tomography (CAT) cut with spinopelvic instability and fracture of the L5-S1 articular process; C) three-dimensional (3D) reconstruction of the CAT.

mean age was 29 years (range: 20 to 48 years), and the sample was composed of 4 (66.6%) females and 2 (33.4%) males. The most common associated lesion was pelvic fracture in 66.6% of the cases. The other lesions found were: distal radius fracture, fracture of transverse processes of the lumbar spine, abdominal trauma, and femoral fracture. These had a lower incidence (2 cases; 33.4%) (► **Table 1**).

Even though all of the cases admitted to the emergency room were classified as Frankel E,<sup>10</sup> two of these patients had perineal paresthesia and one case had far-out syndrome,<sup>11</sup> the name given to the compression of the L5 root between the transverse process of L5 and the fractured fragment of the sacrum, described initially by Wiltse in 1984 and more commonly observed in Denis type-II fractures.<sup>3</sup>

When classifying sacrum fractures, we found that half of the cases were classified by Denis as type-II, and the other half, as type-III. Among the cases of Denis type-II, two were classified as Isler type-B. Using the descriptive classification, when applicable, two U-shaped fractures and one H-shaped fracture were found. According to the classification, no dominant pattern was identified.

After the fixation procedure was performed, all patients were mobilized early, and allowed to sit on the bed on the first postoperative day associated with active and passive mobilization with physiotherapy exercises. On the second postoperative day, the patient was stimulated to get up with the aid of walkers according to the pain limitation and the limitations of the associated lesions.

The cases were monitored in the outpatient facility, with postsurgical return visits at 15 days, 45 days, 3 months, 6 months, and 12 months after the procedure, and biannual return visits from then on. The follow-up ranged from 12 to 24 months, starting at the date of the surgical procedure.

**Table 1** Patient characteristics

Gender	Age	Mechanism	Associated injuries	Follow-up time
Female	20	Collision between a motorcycle and a car	Bilateral fracture of the ischiopubic branches	15 months
Female	26	Collision between a motorcycle and a car	Fracture of the pelvis	
			Bilateral fracture of the ischiopubic branches	12 months
			Pelvic ring disjunction	
			Traumatic diaphragmatic hernia	
Female	21	Suicide attempt (15 m)	T12 surgical fracture	24 months
			Injury of the lumbar posterior ligamentous complex	
Female	33	Suicide attempt (8 m)	Bilateral fracture of the ischiopubic branches	12 months
			Pubic symphysis opening	
			Right subtrocantalic fracture	
			Fracture of the transverse processes from T11 to L5	
			Left distal radio fracture	
Male	26	Suicide attempt (30 m)	Exposed subtalar dislocation	12 months
			Transverse fracture of L5	
Male	48	Collision between two cars	Fracture of the ischiopubic branches	16 months
			Fracture of the right fist	
			Fracture of the left elbow	

Note: Source: electronic medical records of Hospital do Trabalhador.

**Table 2** Functional outcomes of the cases studied

VAS	Oswestry	Denis	Isler	Descriptive	AO
3	24%	Type 2	Type B	Does not apply	C2
2	30%	Type 2	Type C	Does not apply	C2
3	28%	Type 3	Does not apply	In U	C0
4	50%	Type 3	Does not apply	In H	C3
1	0%	Type 2	Type B	Does not apply	B2
3	36%	Type 3	Does not apply	In U	C0

Abbreviations: AO, Arbeitsgemeinschaft für Osteosynthesefragen; VAS, visual analog scale.

Note: Source: electronic medical records of Hospital do Trabalhador.

## Results

The three patients with neurological alterations requiring decompression presented complete recovery in the follow-up (two cases with perineal paresthesia and one with far-out syndrome).

In the Oswestry disability index, version 2.0, 1 patient was classified as having a minimal disability, 4, with moderate disability, and 1, with severe disability (► **Table 2**). The worst score was 50%; this patient had attempted suicide and presented fibromyalgia and severe depression, and was refractory to the psychiatric treatment.

As for the complications, 1 patient evolved with deep venous thrombosis on the 21st postoperative day, and 1 patient evolved with suture dehiscence, both with improvement after adequate therapy.

During the 24-month follow-up period, it was necessary to withdraw the synthesis material in 2 cases (33.4%) due to complications already described in the literature:<sup>12</sup> the first

due to laxity of the material; the second, due to prominence and pain on the implant material due to low body mass index.

## Discussion

Complex sacrum fractures with lumbopelvic instability are severe, with multiple associated lesions, high morbidity and mortality rates. Even when treated correctly, reestablishing spinopelvic stability and evolving with fracture consolidation, the patients who suffered this type of injury may evolve with sequelae of the lesion itself, or of the instituted treatment. According to the literature, less than 50% of patients who suffered complex sacrum fractures return to their previous working conditions and functionalities.<sup>13</sup>

Although they are considered rare,<sup>14,15</sup> fractures caused by suicide attempts comprised 50% of the cases analyzed in the present study, a significant portion of the complex sacrum fractures.

After analyzing the cases submitted to surgery at our service, up to now we have obtained results superior to those described in the literature with an evolutionary follow-up of the patients. A good clinical evolution was observed, with few patients presenting residual pain, and good surgical results, with good recovery of function in the short- and medium-term. It is worth noting that we analyzed studies using the same surgical technique (iliolumbar fixation with iliac screws using the Schildhauer et al<sup>7</sup> technique), as well as those that differed only regarding the iliac screw technique. As for the surgical complications, we observed a case of laxity of the synthesis material and a case of infection of the surgical site, both resolved with satisfactory outcomes. The literature shows that these complications, both clinical and surgical, are of great incidence in patients undergoing surgical treatment with spinopelvic fixation.<sup>15,16</sup>

Despite the severity, risk of death and morbidity that sacrum fractures represent, a good evolution was observed in the present series of cases with spinopelvic fixation. There were three cases due to automobile accidents, and three due to attempted suicide, which is in line with the data in the literature.<sup>1,2</sup>

Spinopelvic fixation is a good synthesis technique for sacrum fractures with lumbopelvic dissociation, enabling immediate mobilization as well as postoperative weight-bearing.<sup>17</sup> In the present series, all cases evolved with complete consolidation, and we did not observe loss of fracture reduction as a consequence of weight-bearing and immediate mobility.

In view of the different fixation techniques, we chose the spinopelvic fixation technique with pedicular screws associated with two titanium rods, which, compared to the techniques mentioned in the literature, such as rigid osteosynthesis with plates and screws, and osteosynthesis with posterior tension band, enables the patients to perform weight-bearing and early movements, has an advantage over the percutaneous iliosacral screws, providing greater vertical stability to the fixation system,<sup>18</sup> and up to 25% more resistance when compared to the fixation associated with only one rod.<sup>19</sup> Taking into account the different techniques

to insert screws in the iliac bone, the literature describes the Schildhauer et al<sup>7</sup> technique as being superior in relation to the techniques of Berry and Miller, because the convergent triangulation of the screws in the former provides greater tension and rotational resistance.

According to the study by Guimarães et al,<sup>20</sup> a treatment option would be to use external acetabular fixators associated with percutaneous sacroiliac screws; however, the cases of this study were specifically fractures classified as Tile type-C, with no inclusion of other types of complex sacrum fractures in the analysis.

According to the VAS for pain, four was the highest score, and the pain improved with the use of a simple analgesic.

Analyzing the functional evolution through the Oswestry disability index, version 2.0, the worst result was 50%, verified in only 1 (16.6%) of our cases, which denotes a severe functional disability; the other cases were classified as minimal and moderate dysfunctions.

Regarding the case in our series that presented far-out syndrome, posterior route decompression of the L5 root and spinopelvic fixation was accomplished, leading to a good clinical outcome, with relief of the symptoms. This fact corroborates the techniques commonly used in the treatment of this pathology, when found.<sup>17</sup>

Among the common complications associated with fixation, there is pain on the implants due to the protrusion of the screw and laxity of the long-term synthesis material. Three patients presented pain on the synthesis material, one of whom presented consolidation and signs of laxity on the bilateral iliac screws, and, in another case, the screws became protruding after the patient lost weight, and they had to be removed. The other patients have not presented these complications so far.<sup>2,16,20</sup>

It is likely that removing the synthesis material electively after fracture consolidation decreases the residual pain at the site of surgery; however, we should remember that because it is a severe and difficult-to-treat injury, the referred pain may not be derived only from the material; it may be a consequence of the injury itself.

In patients in whom the material was removed, there was a significant improvement in residual pain in the low lumbar region, considering that the superficial location of the synthesis material caused painful sensation in the seated position.

Since the literature describes most of the complications related to the synthesis material occurring two years after the procedure, we can still expect that there will be late laxity of the synthesis material, especially after the consolidation of the sacral fracture and of the spinopelvic arthrodesis.

## Conclusion

More than 80% of the cases followed up showed satisfactory results in the medium-term with the fixation technique. This suggests that the Schildhauer et al<sup>7</sup> technique for spinopelvic fixation is safe and with good resistance for immediate postoperative weight-bearing.

However, because the present is a retrospective study that evaluated a limited number (6) of patients treated at a single service, new prospective studies with larger samples should be conducted to enable better conclusions on the efficacy and safety of the technique employed.

#### Conflict of Interests

The authors have no conflict of interests to declare.

#### References

- 1 Keith DW. Fractures, dislocations, and fracture-dislocations of the spine. In: Canale ST, Beaty JH, editors. *Campbell's operative orthopaedics*. 12th ed. Canada: Elsevier; 2013:1559–1627
- 2 Vilela MD, Jermani C, Braga BP. Lumbopelvic fixation and sacral decompression for a U-shaped sacral fracture: case report. *Arq Neuropsiquiatr* 2007;65(3B):865–868
- 3 Bellabarba C, Schildhauer TA, Chapman JR. Sacral fractures. In: Herkowitz HN, Garfin SR, Eismont FJ, Bell GR, Balderston RA, editors. *Rothman-Simeone The spine*. 6th ed. Philadelphia: Saunders/Elsevier; 2013:1405–1421
- 4 Schroeder GD, Savage JW, Patel AA, Stover MD. Spinopelvic fixation in complex sacral fractures. *JBJS Rev* 2015;3(03):e4
- 5 Vaccaro AR, Kim DH, Brodke DS, et al. Diagnosis and management of sacral spine fractures. *Instr Course Lect* 2004;53(01):375–385
- 6 Sacral Trauma [acesso em 2018 abril 18]. Disponível em: <https://www2.aofoundation.org/wps/portal/surgery/mobile?showPage=diagnosis&bone=Spine&segment=TraumaSacrum>
- 7 Schildhauer TA, Ledoux WR, Chapman JR, Henley MB, Tencer AF, Routt ML Jr. Triangular osteosynthesis and iliosacral screw fixation for unstable sacral fractures: a cadaveric and biomechanical evaluation under cyclic loads. *J Orthop Trauma* 2003;17(01):22–31
- 8 Rhee WT, You SH, Jang YG, Lee SY. Lumbo-sacro-pelvic fixation using iliac screws for the complex lumbo-sacral fractures. *J Korean Neurosurg Soc* 2007;42(06):495–498
- 9 Fairbank JC, Pynsent PB. The Oswestry Disability Index. *Spine* 2000;25(22):2940–2952, discussion 2952
- 10 Maynard FM Jr, Bracken MB, Creasey G, et al; American Spinal Injury Association. International Standards for Neurological and Functional Classification of Spinal Cord Injury. *Spinal Cord* 1997; 35(05):266–274
- 11 Ise S, Abe K, Orita S, et al. Surgical treatment for far-out syndrome associated with abnormal fusion of the L5 vertebral corpus and L4 hemivertebra: a case report. *BMC Res Notes* 2016;9:329
- 12 Rocha VM, Guimarães JA, Olivaes Filho AP, et al. Sacral fracture treatment with a variation of the lumbopelvic fixation technique. *Coluna/Columna* 2018;17(01):69–73
- 13 Buchholz RW, Heckman JD, Court-Brown CM, Torneta P III. *Rockwood and Green's Fractures in adults*. 7th ed. Philadelphia: Lippincott Williams & Wilkins; 2009
- 14 Lee SW, Ko SB, Shin DY. Sacral Fracture Dislocation of Suicidal Jumper (Suicidal Jumper's Fracture) - 4 Cases Report -. *J Korean Soc Spine Surg* 2008;15(04):281–285
- 15 Roy-Camille R, Saillant G, Gagna G, Mazel C. Transverse fracture of the upper sacrum. Suicidal jumper's fracture. *Spine* 1985;10(09): 838–845
- 16 König MA, Jehan S, Boszczyk AA, Boszczyk BM. Surgical management of U-shaped sacral fractures: a systematic review of current treatment strategies. *Eur Spine J* 2012;21(05):829–836
- 17 Schildhauer TA, Bellabarba C, Nork SE, Barei DP, Routt ML Jr, Chapman JR. Decompression and lumbopelvic fixation for sacral fracture-dislocations with spino-pelvic dissociation. *J Orthop Trauma* 2006;20(07):447–457
- 18 Kaye ID, Yoon RS, Stickney W, Snaveley J, Vaccaro AR, Liporace FA. Treatment of Spinopelvic Dissociation: A Critical Analysis Review. *JBJS Rev* 2018;6(01):e7
- 19 Ueno FH, Pisani MJ, Machado AN, Rodrigues FL, Fujiki EN, Rodrigues LMR. Estudo biomecânico da fixação da fratura sacroilíaca com barras de titânio e parafusos pediculares. *Acta Ortop Bras* 2015;23(03):154–157
- 20 Guimarães RP, Ribeiro AG, Ulson O, Ávila RB, Ono NK, Polesello GC. Tratamento das lesões instáveis do anel pélvico com fixador supra-acetabular e parafusos sacroilíacos: Resultados preliminares em 20 pacientes. *Rev Bras Ortop* 2016;51(02): 132–137
- 21 Sagi HC. Technical aspects and recommended treatment algorithms in triangular osteosynthesis and spinopelvic fixation for vertical shear transforaminal sacral fractures. *J Orthop Trauma* 2009;23(05):354–360