

POSTER PRESENTATION

Open Access

Black-blood dynamic contrast-enhanced carotid artery wall MRI with SRDIR preparation

Zhaoyang Fan^{1*}, Jingsi Xie¹, Yi He³, Yutaka Natsuaki⁴, Ning Jin⁴, Daniel S Berman², Debiao Li^{1,5}

From 16th Annual SCMR Scientific Sessions
San Francisco, CA, USA. 31 January - 3 February 2013

Background

Inflammation plays a major role in atherosclerotic plaque progression and disruption [1]. Dynamic gadolinium contrast-enhanced (DCE) vessel wall imaging has been used to compute a set of contrast kinetic parameters that may characterize the extent of inflammation of carotid plaques [2-4]. However, previous DCE techniques are limited to a 2D bright-blood acquisition and thus the accuracy of wall signal assessment could be compromised. This work aimed to develop a 3D black-blood DCE technique.

Methods

Sequence

An SRDIR (saturation recovery and double inversion recovery) preparation is combined with an RF spoiled gradient-echo sequence to achieve two aims: 1) To create T1-weighting for vessel wall; 2) To consistently null the

blood with a fixed inversion time combination (TI1 and TI2) (Fig. 1). Bright-blood acquisition is interleaved with black-blood acquisition to enable arterial blood signal measurement as needed in kinetic modeling.

Protocol

Nine healthy volunteers (7 F, 2 M; age 31-49 years) were scanned at 3T (Siemens Magnetom Verio) using a 4-channel bilateral carotid coil. The 3D DCE imaging using the SRDIR technique was conducted axially at the carotid bifurcations. Imaging parameters included: resolution = $0.6 \times 0.6 \times 2.0 \text{ mm}^3$, 4 partitions, ECG triggering to minimize pulsation motion, 30 lines/RR, TI1/TI2 = 200/40 ms based on computer simulations. One-frame pre-contrast scan was followed by repetitive contrast-enhanced scans (40 s/frame, > 15 min), along with intravenous contrast (0.2 mmol/kg gadopentetate dimeglumine) injection and saline flush (30 ml) both at

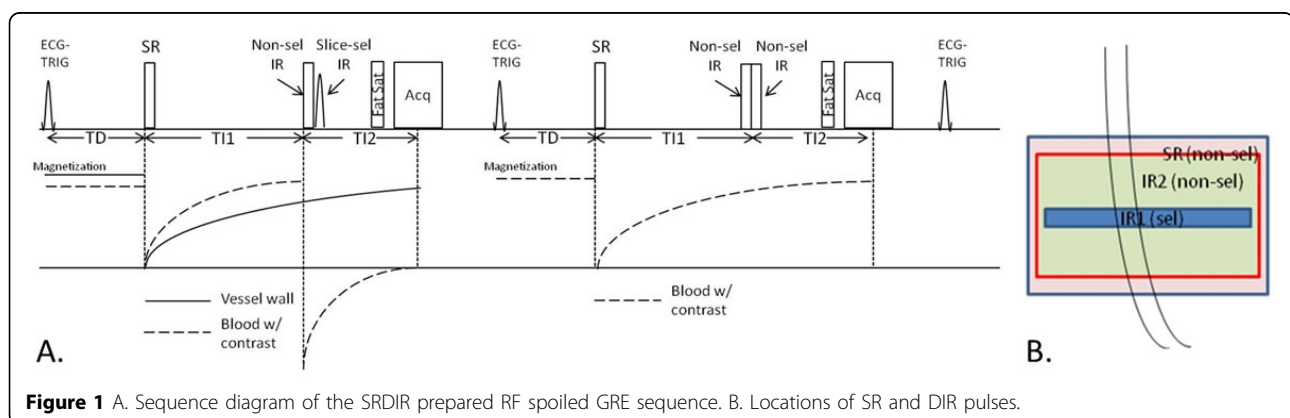
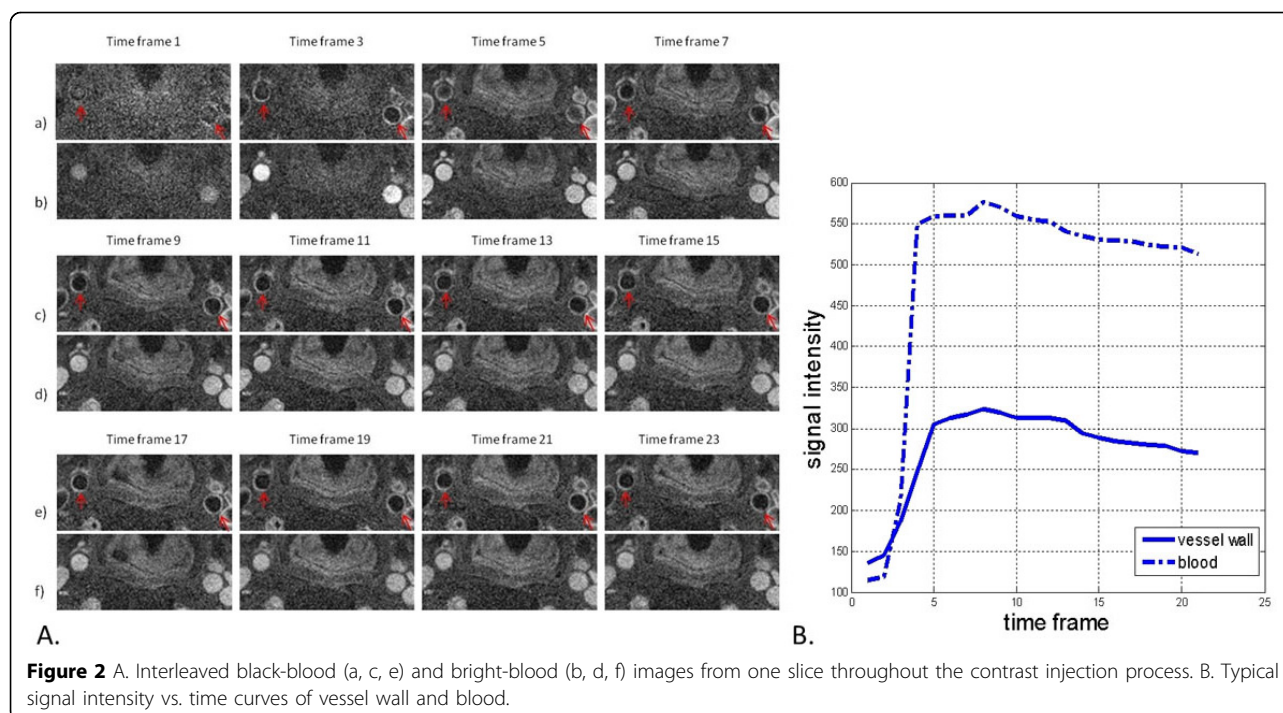


Figure 1 A. Sequence diagram of the SRDIR prepared RF spoiled GRE sequence. B. Locations of SR and DIR pulses.

¹Biomedical Imaging Research Institute, Cedars-Sinai Medical Center, Los Angeles, CA, USA

Full list of author information is available at the end of the article



0.2 ml/s. Through ROI analysis on the black-blood and bright-blood image series, respectively, the changes in signal intensity of carotid artery wall and lumen were obtained and used to compute the kinetic parameters (K^{trans} , K_{ep} , and V_p) based on Toft's two compartmental model.

Results

The luminal signal was consistently nulled regardless of the varying blood T1 values and carotid artery wall were clearly differentiated from the lumen on the DCE images (Fig. 2A). Signal intensity vs. time curves of carotid artery wall and blood were qualitatively similar to previous work (Fig. 2B). From the 9 subjects, $K^{\text{trans}} = 0.062 \pm 0.027 \text{ min}^{-1}$, $K_{\text{ep}} = 0.664 \pm 0.334 \text{ min}^{-1}$, and $V_p = 39.24 \pm 8.34\%$.

Conclusions

K^{trans} and V_p values obtained in this work were in accordance with previous studies. To our knowledge, this is the first work in which K_{ep} is investigated for carotid vessel wall. The healthy volunteer data indicates that SRDIR is a promising dynamic carotid vessel wall imaging technique. Clinical validations are currently underway.

Funding

AHA11POST7650043.

Author details

¹Biomedical Imaging Research Institute, Cedars-Sinai Medical Center, Los Angeles, CA, USA. ²Heart Institute and Imaging Center, Cedars-Sinai Medical Center, Los Angeles, CA, USA. ³Radiology, Anzhen Hospital, Beijing, China. ⁴Siemens Healthcare, Los Angeles, CA, USA. ⁵Department of Bioengineering, University of California, Los Angeles, CA, USA.

Published: 30 January 2013

doi:10.1186/1532-429X-15-S1-P246

Cite this article as: Fan *et al.*: Black-blood dynamic contrast-enhanced carotid artery wall MRI with SRDIR preparation. *Journal of Cardiovascular Magnetic Resonance* 2013 15(Suppl 1):P246.

Submit your next manuscript to BioMed Central and take full advantage of:

- Convenient online submission
- Thorough peer review
- No space constraints or color figure charges
- Immediate publication on acceptance
- Inclusion in PubMed, CAS, Scopus and Google Scholar
- Research which is freely available for redistribution

Submit your manuscript at
www.biomedcentral.com/submit

 BioMed Central