

## Complications of esophageal strictures dilatation in children

## A tertiary-center experience

Osama Bawazir, *FRCS, FRCSI*, Mohammed O. Almaimani, *MD*.

## ABSTRACT

**الأهداف:** الإفصاح عن نتائج التوسيع بالمنظار لضيق المريء عند الأطفال ومضاعفاته وعلاجها. حيث أنه تختلف نتائج توسع المريء وفقاً للمسببات الأساسية.

**المنهجية:** شملت الدراسة 46 مريضاً خضعوا لتوسيع المريء بين عامي 2014م و 2019م. خضع جميع المرضى لدراسة الأشعة بالصبيغ للمريء قبل التوسيع بالمنظار لتحديد مكان التضيق وعدده وطوله. بالإضافة إلى ذلك، تم توثيق نوع الموسعات (البالون مقابل الموسعات شبه الصلبة)، وعدد جلسات التوسيع، والفواصل الزمنية بينهما، ومدة المتابعة. وكانت مقاييس نتائج الدراسة هي الحاجة إلى توسع إضافي وتحسين الأعراض. كان متوسط العمر 2.47 سنة، و 26 مريضاً من الإناث. عسر البلع كان هو العرض الرئيسي، وكان السبب الرئيسي للتضيق هو رتق المريء.

**النتائج:** كانت طريقة العلاج الرئيسية هي توسع البالون بالمنظار (العدد = 29، 63%). ازداد قطر المريء بشكل ملحوظ بعد التوسيع (9 [7-11] مقابل 12 [10-12.8] مم؛ قيمة  $p < 0.001$ ). استخدم ميتوميسين-سي الموضعي كعلاج مساعد في 3 مرضى (6.5%). تم الإبلاغ عن انثقاب المريء في حالتين (4.3%). يحتاج المرضى إلى 3 جلسات توسيع بالمتوسط (النسبة المئوية 25-75: 1-5)، وكانت المدة المتوسطة بين التوسيع الأول والأخير 2.18 سنة (المئين 25-75: 0.5-4.21).

**الخلاصة:** توسع المريء علاج فعال للأطفال الذين يعانون من تضيق المريء. ومع ذلك، فإنهم عادة يحتاجون إلى التوسيع المتكرر، خاصة في المرضى الذين يعانون من التضيق الناتج عن المواد الحارقة. المضاعفات ليست شائعة، ونادر ما تلجأ إلى الجراحة المفتوحة.

**Objectives:** To report the results of endoscopic dilatation of esophageal strictures in children, its complications, and their management. The outcomes of esophageal dilatation differ according to the underlying etiology.

**Methods:** The study included 46 patients who underwent esophageal dilatation between 2014-2019. All patients underwent a contrast study of the esophagus before endoscopic dilatation to determine the location, number, and length of the narrowing. In addition, the type of dilators (balloon versus semi-rigid dilators), the number of dilatation sessions, the interval between them, and the duration of follow-up were also documented. The median age was

2.47 years, and 26 patients were females. Dysphagia was the main presenting symptom, and the leading cause of stricture was esophageal atresia.

**Results:** The main treatment modality was endoscopic balloon dilatation (n=29, 63%). The esophageal diameter was significantly increased after dilation (9 [7-11] versus 12 [10-12.8] mm;  $p < 0.001$ ). Topical mitomycin-C was used as adjuvant therapy in 3 patients (6.5%). Esophageal perforation was reported in 2 cases (4.3%). Patients needed a median of 3 dilatation sessions, 25-75<sup>th</sup> percentiles: 1-5, and the median duration between the first and last dilatation was 2.18 years 25-75<sup>th</sup> percentiles: 0.5-4.21.

**Conclusion:** Esophageal dilatation is effective for the management of children with esophageal stricture; however, repeated dilatation is frequent, especially in patients with corrosive strictures. Complications are not common, and open surgery is not frequently required.

**Keywords:** esophageal strictures, endoscopic dilatation, bougies

*Saudi Med J 2020; Vol. 41 (7): 720-725*  
*doi: 10.15537/smj.2020.7.25166*

From the Department of Surgery (Bawazir), Faculty of Medicine, Umm Al-Qura University and King Faisal Specialist Hospital & Research Centre and from the Department of Surgery (Almaimani), Maternity and Children Hospital, Makkah, Kingdom of Saudi Arabia.

Received 16th May 2020. Accepted 12th June 2020.

Address correspondence and reprint request to: Dr. Osama Bawazir, Department of Surgery, Faculty of Medicine, Umm Al-Qura University, Makkah, Kingdom of Saudi Arabia. E-mail: obawazir@yahoo.com  
ORCID ID: [orcid.org/0000-0002-4213-7377](https://orcid.org/0000-0002-4213-7377)

Pediatric esophageal strictures have different etiology than adults.<sup>1,2</sup> Its most common cause is surgical complications of esophageal atresia or esophageal burns, which mainly occurs in children under the age of 5 years.<sup>3</sup> Esophageal stenosis in children can be caused by gastroesophageal reflux disease (GERD), eosinophilic esophagitis, caustic ingestion, congenital esophageal stenosis (CES), and anastomotic strictures after tracheoesophageal fistula repair.<sup>4</sup> All these diseases have similar clinical presentations, the main being dysphagia, and vomiting. These children often have long-term morbidity and require multiple procedures to improve their symptoms. The inability to thrive is the main consequence of this clinical condition as it decreases oral intake.<sup>5</sup> Patients with esophageal stenosis may need intensive treatment for many years to control their symptoms. Most of these patients undergo dilatation that has been shown to treat symptoms effectively.<sup>6</sup> Previously, constriction was treated with rigid dilation; however, the management has evolved toward balloon dilation because the radial force applied can reduce the risk of esophageal damage and stenosis recurrence.<sup>7</sup>

Various dilators are now available. Fixed-diameter push dilators as semi-rigid dilators (bougienage without guidewire) and radially expanding balloon dilators that run over a guidewire or through the endoscope channel are the most commonly used devices. However, there is a lack of consensus regarding the most preferred device.<sup>2</sup> In recent years, esophageal stents are recommended for some cases. The efficiency of esophageal stenosis dilatation can be checked directly by endoscopy or indirectly by fluoroscopic examination. However, fluoroscopically-guided dilatation carries the risk of radiation exposure, especially in children. Surgery is usually reserved for resistant types of esophageal strictures, such as long strictures and cases of congenital stenosis.<sup>8</sup> Multiple studies have analyzed esophageal dilatation and have obtained variable results.<sup>9,10</sup> Thus, the present study aimed to report the outcomes of endoscopic dilatation of esophageal strictures in children, its complications, and management.

**Methods.** This study is a retrospective analysis of all pediatric patients who underwent esophageal dilatation at our center between April 2014 and December 2019. Data was extracted from the patients' records, including demographics, clinical presentation, endoscopic results, treatment modality, and postoperative outcomes. All

patients underwent a contrast study of the esophagus before endoscopic dilation to determine the location, number, and length of the narrowing. In addition, the type of dilators (balloon versus semi-rigid dilators), the number of dilatation sessions, the interval between them, and the duration of follow-up were also documented.

The study was approved by the Institutional Biomedical Ethical Committee, Faculty of Medicine, Umm Al Qura University (Institutional review number HAP0-02-K-012-2020-04-374), and the consents to participate were waived. All procedures performed in this study involving human participants were in accordance with the ethical standards of the institutional or national research committee and with the 1964 Helsinki Declaration and its later amendments or comparable ethical standards.

**Procedure.** Gradual esophageal dilatations were performed using balloon catheters of an appropriate size for the patient's weight, age, and severity of stenosis. The size of the balloon used depends on the judgment of the attending surgeon. The balloon catheter was inserted through the stenosis after placing a guidewire under endoscopic guidance and inflating it with normal saline; it was then gradually increased by 3 mm by dilatation for a maximum of 2 increments in a single session. The correct positioning of the dilator to the size of the stenosis area was confirmed by endoscopy. The dilator was held in place for one minute before proceeding to the next dilation size. The extinction of the stenosis under a direct endoscopic view was an indication of successful dilation. In patients suspected of esophageal injury (namely, blood in the balloon or the pocket), a careful endoscopic examination was performed after dilatation of the stenosis, and if there was any suspicion of injury, contrast study was conducted to check for esophageal perforation. Most GERD patients continued to receive medical treatment for these conditions with the dilatation. Topical triamcinolone and mitomycin-C injection were used if the child needed more than 2 dilations.

**Outcomes.** Clinical response was assessed according to the degree of improvement in symptoms and the need for additional dilatation. The reaction was considered complete when the symptoms completely disappeared without the need for additional enlargement; satisfactory if there was a partial improvement in symptoms; and insufficient if the symptoms did not improve despite multiple dilation sessions.

**Statistical analysis.** The 25<sup>th</sup>, 50<sup>th</sup> (median), and 75<sup>th</sup> percentiles were calculated for the continuous variables and proportions for categorical variables. The paired t-test was used to compare the first and last esophageal

**Disclosure.** Authors have no conflict of interests, and the work was not supported or funded by any drug company.

diameters. A  $p$ -value $<0.05$  was considered significant. All analyses were performed using Stata 16 (Stata Corp, College Station, Texas, USA).

**Results.** We performed esophageal dilatation in 46 patients during the study period. The median age of the patients was 2.47 years, and 26 patients were females (56.52%). Dysphagia was the main presenting symptom ( $n=27$ , 58.7%), and the main cause of stricture was esophageal atresia ( $n=21$ , 45.65%). Strictures usually involved more than one-third of the segment; however, the upper third was the most commonly involved segment ( $n=20$ , 43.48%). The nasogastric tube was used preoperatively in 14 patients (30.43%). (Table 1) Endoscopic balloon dilatation ( $n=29$ , 63.04%) was the main treatment modality. The esophageal diameter was significantly increased after dilation ( $p<0.001$ ). Topical triamcinolone injection (4mL of 10mg/mL, 1 mL in each quadrant) was used in 5 patients, and topical mitomycin-C (5 mL of 0.4 mg/mL, 2 mg for 5 minutes) was used as adjuvant therapy in 3 patients (6.52%). (Table 2) Esophageal perforation was reported in 2 cases (4.34%). (Figure 1) The patient was managed with an esophageal stent after failing nonoperative measures, and complete healing was achieved. (Figure 2) During endoscopic removal of the stent, complete healing was confirmed by endoscopic visualization of the wall. (Figure 3) The second perforation occurred at the site of anastomotic stricture in the neck post reverse gastric tube pull-up for long-gap pure esophageal atresia. The patient presented with large left neck abscess 10 days after dilatation and was managed with incision and drainage and intravenous antibiotics without stenting of the stricture. Nasogastric tube feeding was used for 6 weeks.

Patients needed a median of 3 dilatation sessions (25-75<sup>th</sup> percentiles: 1-5), and the median duration between the first and last dilatation was 2.18 years (25-75<sup>th</sup> percentiles: 0.5-4.21). In patients with corrosive esophageal stenosis, one patient required 29 dilatations sessions.

**Discussion.** Pediatric esophageal strictures are common clinical entities.<sup>1</sup> Esophageal tumors are the leading cause of stenosis in adults, while the etiological spectrum is prevalent in children.<sup>2</sup> The most common types are anastomotic strictures after surgical repair, inflammatory strictures secondary to GERD, and eosinophilic esophagitis, followed by strictures related to congenital anomalies and caustic lesions. The clinical appearance of strictures is almost identical irrespective of the etiology. In addition to medical treatment, nearly all patients with refractory esophageal stenosis require endoscopic dilation or surgery. Symptom relief after

**Table 1** - Baseline data and patients' characteristics (N=46).

Characteristics	n (%)
Female	26 (56.5)
Age (years)	2.5 (1.2-3.9)
Weight (Kg)	10.165 (6.2-12)
Height	83.5 (70-96)
Body mass index	13.9 (12.2-15.4)
GERD	21 (45.7)
Congenital anomalies	20 (43.5)
Cystic fibrosis	3 (6.52)
Congenital heart disease	20 (43.5)
<b>Symptoms</b>	
Dysphagia	27 (58.7)
Vomiting	12 (26.1)
Drooling	7 (15.2)
<b>Causes of stenosis</b>	
Esophageal atresia	21 (45.7)
Corrosive injury	7 (15.2)
GERD	13 (28.3)
Epidermolysis bullosa	2 (4.4)
Others	3 (6.5)
<b>*Stricture level</b>	
Upper third	20 (43.5)
Middle third	17 (37.0)
Lower third	16 (34.8)
<b>Preoperative diet</b>	
Liquid	10 (21.7)
Soft	11 (23.9)
Solid	12 (26.1)
NPO	13 (28.3)
Preoperative gastrostomy tube	14 (30.4)

GERD: gastro-esophageal reflux disease, NPO: nothing per mouth. Continuous variables were presented as median (25-75th percentiles) and categorical variables as number and percent. \*not mutually exclusive

the first dilation occurred in 15-59% of cases, which is comparable to the rate achieved in our study.<sup>11</sup> We practiced a selective policy to dilate the symptomatic stenosis, as recommended by Parolini et al.<sup>12</sup>

Balloon dilatation can be more effective and less traumatic than traditional bougies because they provide an even radial force.<sup>13</sup> Balloon dilation is carried out under a direct view, and the insertion of multiple devices is not necessary.<sup>14</sup> Endoscopic guidance also enables direct placement of the balloon catheter and the visualization of balloon inflation, reducing the risk of perforation. The major drawback of the balloon approach is its single-use and is, therefore, much more expensive than the bougie.<sup>15</sup> However, semi-rigid dilators

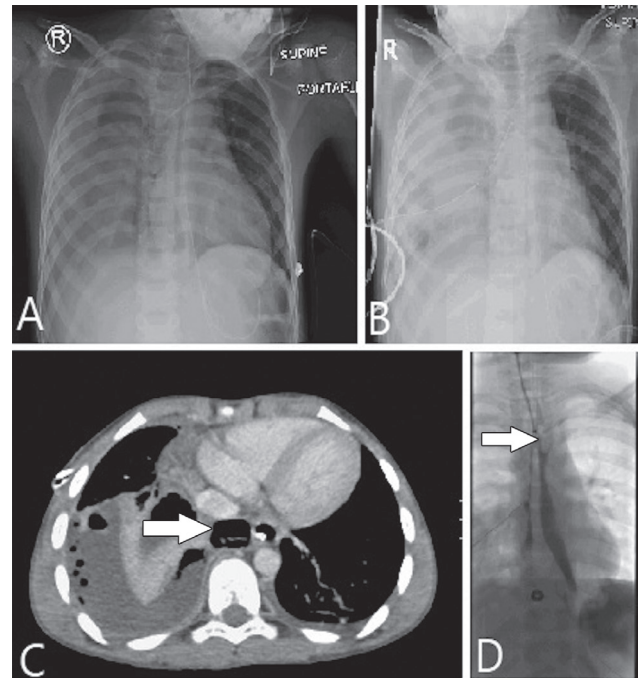
**Table 2** - Operative and postoperative outcomes (N=46).

Variables	n (%)
<i>Treatment</i>	
EBD	29 (63.0)
Both EBD and Savary/bougies dilator	9 (19.6)
Savary/bougies dilator	8 (17.4)
Number of dilatations	3 (1-5)
First diameter	9 (7-11)
Last diameter	12 (10-12.8)
<i>Adjuvants</i>	
Topical steroid	5 (10.9)
Topical mitomycin C	3 (6.5)
<i>*Complications</i>	
Esophageal perforation	2 (4.3)
Respiratory complications	1 (2.2)
Need for surgery for recurrent fistula	2 (4.4)
Need for fundoplication	6 (13)
NG tube use	9 (20.5)
Hematemesis	3 (6.5)
Nausea/refuse feeding	3 (6.5)
NG during follow up	7 (15.2)
<i>Dysphagia</i>	
Substantially reduced	14 (30.4)
Completely reduced	31 (67.4)
Not healed	1 (2.2)
Start oral intake (hours)	8 (8-12)
<i>Diet</i>	
Liquid	1 (2.2)
Soft	3 (6.7)
Solid	42 (91.1)
Hospital stay (days)	1 (1-3)
Second operation	7 (15.2)

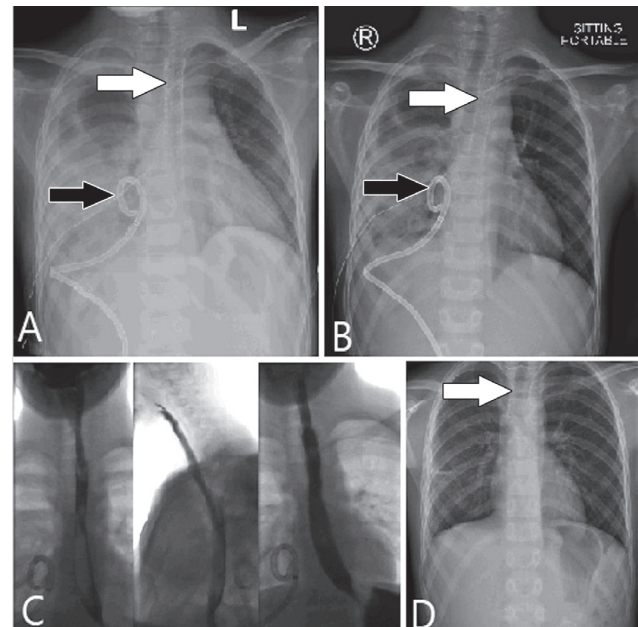
EBD - endoscopic balloon dilatation, NG - nasogastric. Continuous variables were presented as median (25-75th percentiles) and categorical variables as number and percent). \* not mutually exclusive.

are better for long strictures that are readily available and less expensive than balloon dilators. Several studies have shown the superior efficacy and safety of balloon dilators compared to semi-rigid dilators, with efficiency ranging from 76-100% depending on the cause and criteria used to define efficiency.<sup>16,17</sup>

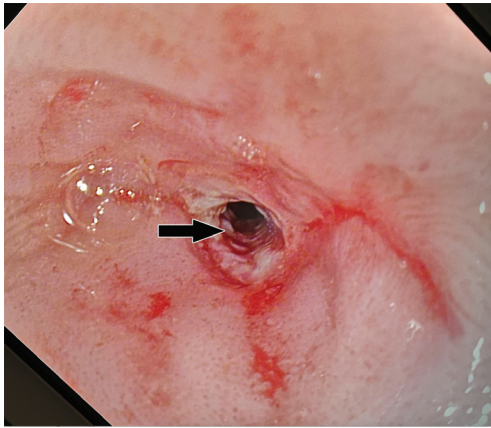
At present, the esophageal dilatation in children is performed almost exclusively under general anesthesia.<sup>3</sup> The most common possible complication is bleeding, and the most severe complication is perforation. A higher perforation rate was estimated for bougienage than for balloon dilation.<sup>18</sup> The risk of esophageal perforation reported in the literature ranged between 0-10%.<sup>19</sup> We had 2 cases of esophageal perforation event that occurred after using semi-rigid dilators. Death after esophageal dilatation was not reported in our cohort.



**Figure 1** - A) X-ray of a patient with esophageal perforation with right pleural effusion, 48-hours post perforation, B) after chest tube insertion. C) CT scan shows right pleural effusion arrow indicate site of perforation and D) esophagogram white arrow shows the site of perforation and leak.



**Figure 2** - A & B) Chest x-ray of a patient with esophageal perforation white arrow showing an esophageal stent and black arrow right CT guided drain. C) Esophagogram shows complete healing of the perforation. D) Chest x-ray 2 weeks after stent insertion (white arrow) with complete resolution of the pleural effusion.



**Figure 3** - Endoscopic view of the esophagus in a patient with very tight esophageal stricture (black arrow).

One death was reported by Contini et al.<sup>13</sup> They used Savary-Gilliard bougies for esophageal dilatation.

In the present study, a median of 3 sessions per patient was required to achieve a complete or satisfactory response. Previous studies have given an average of 2-5 dilation sessions per patient and an average interval of 2-4 weeks between dilation sessions.<sup>20,21</sup> Some variability is expected because the time interval between sessions depends on initial stenosis size, stenosis resistance to dilatation, and clinical response to the previous session.<sup>1</sup> The maximum number of dilatation sessions was 29 in the current study. In the study by Karaman et al,<sup>15</sup> the maximum number of dilatation sessions was 52. In agreement with the results of previous studies, we found that stenosis due to caustic lesions required the most dilatation sessions, although this was observed only in one case.<sup>18</sup> This finding is likely related to extensive fibrosis and scarring that occur after caustic injuries.<sup>2</sup> Narrowing associated with GERD can be severe and difficult to manage, especially in patients with a long history of GERD. Pearson et al,<sup>20</sup> reported GERD-related stenosis in 42% of their cohort of 115 children with esophageal stenosis. Previous studies have reported successful results of almost 80% in patients with GERD-related stenosis.<sup>8</sup> In the present study, a complete response was achieved in 67% of the cases and a satisfactory response in 30%.

Congenital esophageal stenosis has traditionally been treated surgically. Still, increasing evidence suggests that endoscopic dilatation can be a safe and effective intervention, especially for stenoses caused by the membranous web and subtype of fibromuscular thickening of the CES. Surgery is usually required in cases of tracheobronchial debris subtype.<sup>21</sup>

Intralesional corticosteroid injection could prevent recurrent stenosis, through reducing collagen synthesis, fibrosis, and chronic scarring.<sup>22</sup> Although the ESGE-ESPGHAN Guidelines for pediatric gastrointestinal endoscopy do not recommend the routine use of intralesional steroids for refractory esophageal stenosis in children, several studies have demonstrated a significant improvement in the periodic dilation rate and a dysphagia score.<sup>24,25</sup> In this study, we used concomitant steroid injection in 5 cases, and our protocol entails the use of injection if the child needed more than 2 dilatations. Despite conflicting reports, mitomycin-C can be considered a possible adjuvant treatment for relapsing stenosis in patients with esophageal atresia as reported by Espghan-Naspghan Guidelines.<sup>25</sup>

Stents have several benefits over conventional dilatation techniques. Surgeons used stents commonly in refractory caustic lesions or with esophageal stenosis after repair of esophageal atresia.<sup>26</sup> However, several complications of the stent were reported. These complications include but not limited to dysphagia, pain, reflux, perforation, migration, and growth or proliferation of hyperplastic tissue that can occur at the end of the fully covered stent. Surgery may be required, albeit rare option. Therefore, surgery should be reserved for patients who have failed endoscopic dilatation and patients with complications caused by dilatation because they are associated with high mortality and complication rate.<sup>25</sup>

The study showed the effectiveness of esophageal dilatation in the management of strictures. Patients with corrosive strictures could benefit from additional measures to decrease the rate of repeated dilatation. Stents are valid options for the management of specific cases and surgery is rarely required.

**Study limitations.** The study is a retrospective one with selection and referral biases. Additionally, it is a single-center experience. The number of patients is another limitation, especially in subtypes of esophageal strictures.

In conclusion, esophageal dilatation is an effective method for the management of children with esophageal stricture; however, repeated dilatation is frequent, especially in patients with corrosive strictures. Complications are not common, and open surgery is rarely required.

**Acknowledgment.** We would like to express our deep gratitude to Dr. Zergham Zia for his valuable support on the radiology image in this article. We would like also to acknowledge Manuscript Edit ([www.manuscriptedit.com](http://www.manuscriptedit.com)) for English language editing.

## References

1. Dall'Oglio L, Caldaro T, Foschia F, Faraci S, di Abriola GF, Rea F, et al. Endoscopic management of esophageal stenosis in children: New and traditional treatments. *World J Gastrointest Endosc* 2016; 8: 212-219.
2. Ghiselli A, Bizzarri B, Ferrari D, Manzali E, Gaiani F, Fornaroli F, et al. Endoscopic dilation in pediatric esophageal strictures: a literature review. *Acta Biomed* 2018; 89: 27-32.
3. Pieczarkowski S, Woynarowski M, Landowski P, Wilk Robert, Daukszewicz A, Toporowska-Kowalska E, et al. Endoscopic therapy of oesophageal strictures in children - a multicentre study. *Prz Gastroenterol* 2016; 11: 194-199.
4. Arnold M, Numanoglu A. Caustic ingestion in children-A review. *Semin Pediatr Surg* 2017; 26: 95-104.
5. Cakmak M, Boybeyi O, Gollu G, Kucuk G, Bingol-Kologlu M, Yagmurlu A, et al. Endoscopic balloon dilatation of benign esophageal strictures in childhood: a 15-year experience. *Dis Esophagus* 2016; 29: 179-184.
6. Davidson JR, McCluney S, Reddy K, Hadjichristou N, Mutalib M, Monzon L, et al. Pediatric esophageal dilations: A cross-specialty experience. *J Laparoendosc Adv Surg Tech A* 2020; 30: 206-209.
7. Tambucci R, Angelino G, De Angelis P, Torroni F, Caldaro T, Balassone V, et al. Anastomotic strictures after esophageal atresia repair: Incidence, investigations, and management, including treatment of refractory and recurrent strictures. *Front Pediatr* 2017; 5: 120.
8. Al Sarkhy AA, Saeed A, Hamid YH, Al Asmi MM, Altokhais TI, Ullah AA, et al. Efficacy and safety of endoscopic dilatation in the management of esophageal strictures in children. *Saudi Med J* 2018; 39: 787-791.
9. Raitio A, Cresner R, Smith R, Jones MO, Losty PD. Fluoroscopic balloon dilatation for anastomotic strictures in patients with esophageal atresia: A fifteen-year single centre UK experience. *J Pediatr Surg* 2016; 51: 1426-1428.
10. Stenström P, Anderberg M, Börjesson A, Arnbjörnsson E. Dilations of anastomotic strictures over time after repair of esophageal atresia. *Pediatr Surg Int* 2017; 33: 191-195.
11. Antoniou D, Soutis M, Christopoulos-Geroulanos G. Anastomotic strictures following esophageal atresia repair: a 20-year experience with endoscopic balloon dilatation. *J Pediatr Gastroenterol Nutr* 2010; 51: 464-467.
12. Parolini F, Leva E, Morandi A, Gentilino V, Di Cesare A, Torricelli M. Anastomotic strictures and endoscopic dilations following esophageal atresia repair. *Pediatr Surg Int* 2013; 29: 601-605.
13. Contini S, Garatti M, Swarray-Deen A, Depetris N, Cecchini S, Scarpignato C. Corrosive oesophageal strictures in children: outcomes after timely or delayed dilatation. *Dig Liver Dis* 2009; 41: 263-268.
14. Shehata SM, Enaba ME. Endoscopic dilatation for benign oesophageal strictures in infants and toddlers: experience of an expectant protocol from North African tertiary centre. *Afr J Paediatr Surg* 2012; 9: 187-192.
15. Karaman İ, Koç O, Karaman A, Erdoğan D, Çavuşoğlu YH, Afşarlar ÇE, et al. Evaluation of 968 children with corrosive substance ingestion. *Indian J Crit Care Med* 2015; 19: 714-718.
16. Chang CF, Kuo SP, Lin HC, Chuang CC, Tsai TK, Wu SF, et al. Endoscopic balloon dilatation for esophageal strictures in children younger than 6 years: experience in a medical center. *Pediatr Neonatol* 2011; 52: 196-202.
17. Alshammari J, Quesnel S, Pierrot S, Couloigner V. Endoscopic balloon dilatation of esophageal strictures in children. *Int J Pediatr Otorhinolaryngol* 2011; 75: 1376-1379.
18. Uygun I, Arslan MS, Aydogdu B, Okur MH, Otcu S. Fluoroscopic balloon dilatation for caustic esophageal stricture in children: an 8-year experience. *J Pediatr Surg* 2013; 48: 2230-2234.
19. Osuga T, Ikura Y, Hasegawa K, Hirano S. Use of endoscopic balloon dilation for benign esophageal stenosis in children: our 11 year experience. *Esophagus* 2018; 15: 47-51.
20. Pearson EG, Downey EC, Barnhart DC, Scaife ER, Rollins MD, Black RE, et al. Reflux esophageal stricture--a review of 30 years' experience in children. *J Pediatr Surg* 2010; 45: 2356-2360.
21. Hu HT, Shin JH, Kim JH, Jang JK, Park JH, Kim TH, et al. Fluoroscopically guided large balloon dilatation for treating congenital esophageal stenosis in children. *Jpn J Radiol* 2015; 33: 418-423.
22. Nijhawan S, Udawat HP, Nagar P. Aggressive bougie dilatation and intralesional steroids is effective in refractory benign esophageal strictures secondary to corrosive ingestion. *Dis Esophagus* 2016; 29: 1027-1031.
23. Thomson M, Tringali A, Dumonceau JM, Tavares M, Tabbers MM, Furlano R, et al. Paediatric gastrointestinal endoscopy: European society for paediatric gastroenterology hepatology and nutrition and european society of gastrointestinal endoscopy guidelines. *J Pediatr Gastroenterol Nutr* 2017; 64: 133-153.
24. Pereira-Lima JC, Lemos Bonotto M, Hahn GD, Watta G, Lopes CV, dos Santos CEO, et al. A prospective randomized trial of intralesional triamcinolone injections after endoscopic dilation for complex esophagogastric anastomotic strictures: steroid injection after endoscopic dilation. *Surg Endosc* 2015; 29: 1156-1160.
25. Kochhar R, Poornachandra KS. Intralesional steroid injection therapy in the management of resistant gastrointestinal strictures. *World J Gastrointest Endosc* 2010; 2: 61-68.
26. Kramer RE, Quiros JA. Esophageal stents for severe strictures in young children: experience, benefits, and risk. *Curr Gastroenterol Rep* 2010; 12: 203-210.