

Contents lists available at [ScienceDirect](https://www.sciencedirect.com)

## International Journal of Surgery Case Reports

journal homepage: [www.casereports.com](http://www.casereports.com)

# A case report of reconstruction of ocular and complete upper eyelid avulsion with severe facial soft tissue injuries using anterolateral thigh free flap

Yunia Irawati<sup>a,\*</sup>, Marsha Alyssa Razief Fitri<sup>b</sup>, Michelle Eva Rebeca Natalia<sup>b</sup>, Parintosa Atmodiwirjo<sup>c</sup>, Mohamad Rachadian Ramadan<sup>c</sup>, Sara Ester Triatmoko<sup>c</sup>

<sup>a</sup> Plastic Reconstructive Surgery Division, Ophthalmology Department, Faculty of Medicine Universitas Indonesia, Dr. Cipto Mangunkusumo National Hospital, Jakarta, Indonesia

<sup>b</sup> Ophthalmology Department, Faculty of Medicine Universitas Indonesia, Dr. Cipto Mangunkusumo National Hospital, Jakarta, Indonesia

<sup>c</sup> Reconstructive Microsurgery Section, Division of Plastic Surgery, Faculty of Medicine Universitas Indonesia, Dr. Cipto Mangunkusumo National Hospital, Jakarta, Indonesia

## ARTICLE INFO

## Article history:

Received 2 March 2021

Received in revised form 27 March 2021

Accepted 28 March 2021

Available online 1 April 2021

## Keywords:

Anterolateral thigh free flap

Upper eyelid avulsion

Ocular injury

Surgical intervention

Case report

## ABSTRACT

**INTRODUCTION AND IMPORTANCE:** Ocular injury is second mostly caused by motor vehicle accident (MVA) and often leads to severe ocular injury even to visual loss and various aesthetic problems. The outcome is determined by the magnitude of the initial damage and treatment availability. Treating ocular and facial injury due to MVA is challenging given the scope of the damage and may result in various outcomes.

**CASE PRESENTATION:** This case presented a 22-years old woman with a history of car accident assessed with total upper eyelid avulsion with corneal perforation and involvement of multiple facial fractures on the left side. The visual function is irreparable due to the extensive corneal defect from exposure and secondary infection, and possible optic nerve damage.

**CLINICAL DISCUSSION:** This case presented a complete upper eyelid avulsion with severe facial tissue injury. Therefore, the reconstructive procedure main objectives are to maintain appropriate prosthetic position and to improve cosmetic function. This case used anterolateral thigh free flap as the reconstructive surgery method because it is convenient for large defects and the donor scar is not visible. After completing the surgery and several follow-up procedures, the patient recovered without any significant complications.

**CONCLUSION:** Despite visual loss due to the extent damage of the eye, it is important to restore the facial damages. Visual function is as crucial as cosmetic function in determining the patient's quality of life.

© 2021 Published by Elsevier Ltd on behalf of IJS Publishing Group Ltd. This is an open access article under the CC BY-NC-ND license (<http://creativecommons.org/licenses/by-nc-nd/4.0/>).

## 1. Introduction

Motor vehicle accidents (MVA) is one of the most frequent causes of injury leading to morbidity as well as mortality in Indonesia. While there is no clear standard in collecting data on Indonesian traffic accidents, State Police of Indonesia reported 109,215 accidents alone in 2018 causing serious and slight injury of 13,315 and 130,571 people respectively [1,2]. Ophthalmic trauma due to MVA is found to be the second most common cause of ocular injuries [3]. The prognosis of eye injuries is highly determined by the initial damage and by the availability of the treatment. Although previous literature stated that more than 90% ocular injuries were mild and did not threaten the visual acuity, an epidemiological

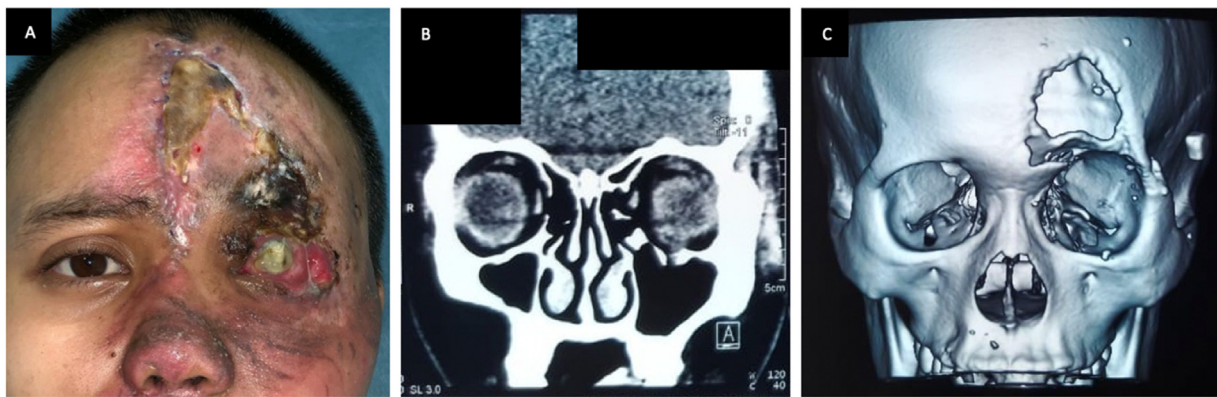
study conducted in 1994 reported that 12% of eyes involved in 150 MVA required removal [4]. A choice for reconstructive surgery for large facial defects, as in this case, should be based on the reconstructive ladder with consideration of each procedure's advantage and disadvantage. Here we present a case with extensive ocular and adnexal injuries with severe facial soft tissue injuries using anterolateral thigh free flap. This study included human subject with ethical principles taken into account, as stated in WMA Declaration of Helsinki in 2013. This case report is compliant with the SCARE Guidelines 2020 [5].

## 2. Case presentation

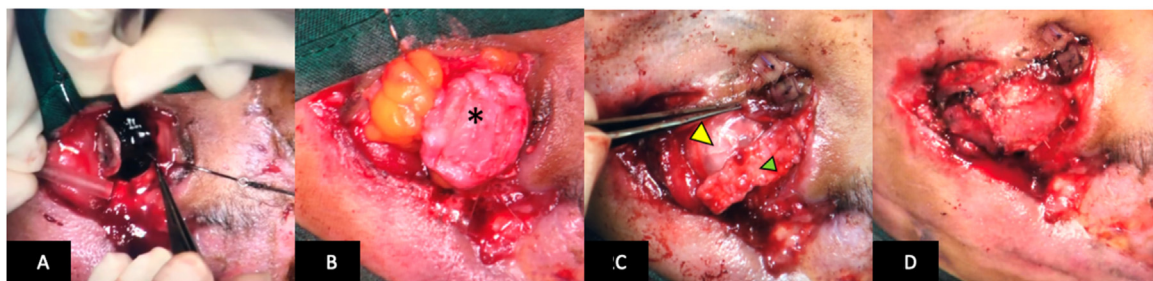
A 22-years-old female patient came by herself to our institution with the appearance of whitish lesion that grew bigger on her left eye in a week. She had a history of being in a high-velocity car accident. She sat using seatbelt in the front left car passenger seat on the highway when another car crashed from the left side

\* Corresponding author at: Jalan Kimia No. 8, Central Jakarta, DKI Jakarta, 10430, Indonesia.

E-mail address: [yunia.irawati@yahoo.com](mailto:yunia.irawati@yahoo.com) (Y. Irawati).



**Fig. 1.** (A) Facial and ocular features on initial examination. (B,C) Orbital CT scan with 3D reconstruction showed left frontal bone defect extending to the anterior left frontal sinus, left superior orbital rim and left zygomatic process of frontal bone, defect of left lamina papyracea with medial rectus muscle and orbital fat herniation to the left ethmoid and maxillary sinus.



**Fig. 2.** Intra operative pictures at the first step of the surgery. (A) the eye was eviscerated; (B) dermis-fat-graft (asterisk) was used to fill the socket; (C) medial and lateral blepharorrhaphy with silicon block and acrylic conformer (yellow arrow heads) was placed above the DFG. Buccal mucosal graft (green arrowheads) was used to aid the shortage of posterior lamella; (D) at the end of the first step, the conformer was completely covered with mucosal graft.

with higher velocity. Then she was caught between the roof and left side of the car. Patient had no underlying health problems, genetic disorders, and no under medications. Ophthalmological examination revealed the visual acuity (VA) of the right eye (RE) 6/6 since correction, while the anterior and posterior segment was within normal limits, and VA of the left eye (LE) had no light perception (NLP). There was complete loss of left superior eyelid (lagophthalmos) with full corneal and scleral exposure and inferior cicatricial ectropion. The bulbar conjunctiva was hyperemic with conjunctival chemosis and ciliary injection. Corneal thinning with infiltrate and crust was found involving almost the entire quadrant of the cornea (corneal abscess). The facial wound was surrounded by pus and necrotic tissue extending to the frontal region (Fig. 1).

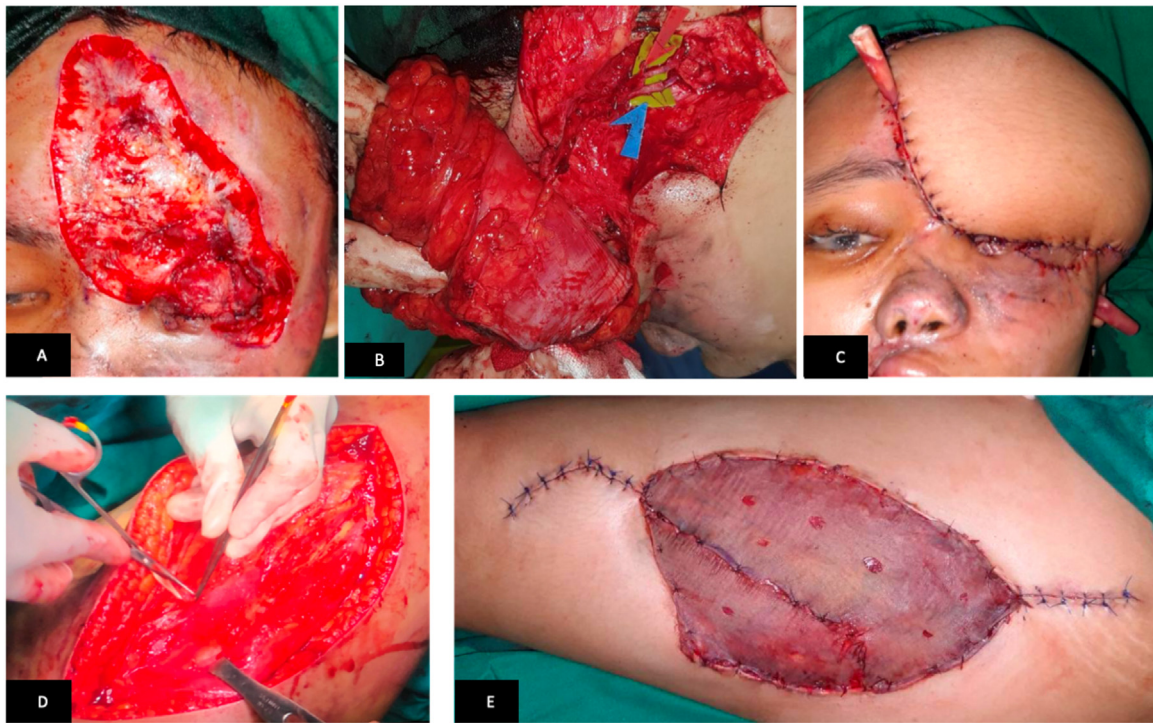
Orbital CT scan with 3D reconstruction was performed to evaluate the extent of the injury (Fig. 1). The patient was assessed with total upper eyelid avulsion with impending perforation of corneal abscess in a nonfunctional eye and involvement of multiple facial fractures on the left side. The patient was consulted to the plastic surgeon for collaborative treatment.

The patient underwent a simultaneous surgery with back up from the neurosurgeon due to the frontal bone defect. Tissue necrotomy in frontal area and upper eyelid was performed. In addition, the left eye was eviscerated, and dermis-fat graft (DFG) harvested from the abdomen was placed to form the socket. Furthermore, extensive release of cicatricial ectropion on lower eyelid and wound adhesion were done. Buccal mucosal graft from the lower lip was also harvested to replace the shortage of posterior lamella of the upper eyelid. At the end of the evisceration, an acrylic conformer was placed, and the inferior eyelid margin to buccal mucous graft to ensure the socket stability was sutured. In the end, the anterolateral thigh free flap was performed (Fig. 2).

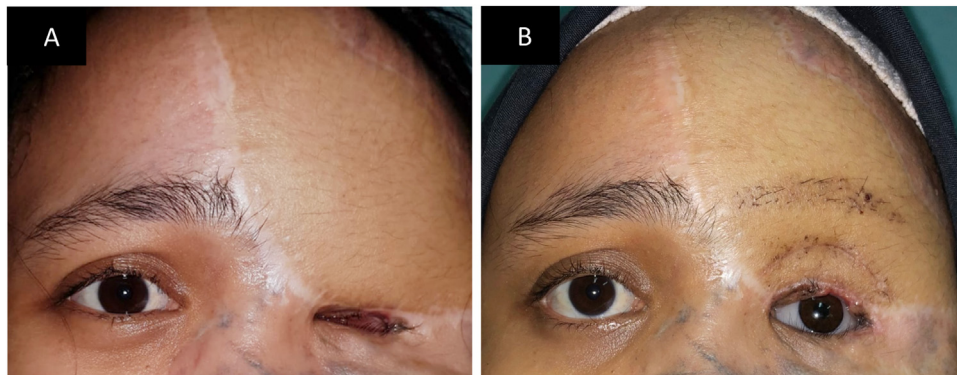
Two weeks after the surgery, stitches on the flap were taken off. Within six months post-operative, there were reduction of the flap size with liposuction, re-insetting of the flap and the socket remains good with the conformer (Fig. 3). The recipient site healed properly with no signs of failure. The donor site showed no signs of infection with minimal scarring. The patient's condition remained stable a year after the surgery. The socket was still in a good condition, but from the aesthetic and anatomical point of view, the horizontal palpebral fissure (HPF) was significantly smaller than the fellow eye. Socket reconstruction with canthopexy was done by the oculoplastic surgeon, and eye prosthesis was used to replace the conformer. The skin palpebra was excised to open the eye. An excision was performed on the palpebra fold and stitched with a quilting suture technique to the periosteum underneath to create the fold. A measurement prior to the procedure should be conducted to get a symmetrical and aesthetic result. The patient also underwent hair transplantation on her left eye brow to reconstruct the anatomical features. The patient recovered without any significant complications after surgery and the intervention was tolerable (Fig. 4). Patient felt satisfied with the result and felt more confident to socialize.

### 3. Discussion

Ocular involvement in MVA may involve the eyelids, lacrimal canaliculi, orbital wall, conjunctiva, cornea, sclera, and extraocular muscles. Serious eye injuries from MVA have a relatively high tendency to cause a permanent visual loss and aesthetic problems, affecting patient's quality of life [4,6]. Kuhn et al. stated that tissue involvement in ocular injury determined the prognosis of anatomical and visual function as well as the initial damage and treatment given. Effective reconstruction of the periorbital area initially aims



**Fig. 3.** Intraoperative pictures flap. The frontal and superior eyelid defect were closed with anterolateral-thigh flap. Vascular anastomosis was successfully achieved. The patient was monitored closely after the surgery to evaluate the flap in the ICU and received heparin.



**Fig. 4.** (A) 14-months after the first surgery, the left HPF was smaller than the fellow eye; (B) One-and-half year after the initial visit, the lid crease and eyebrows were surgically made.

to preserve the vision and associated visual protection mechanism [4,7].

For complex and composite periorbital defects involving multiple tissues, multidisciplinary approach must be taken to achieve optimal functional results. Eyelid is considered a complex structure which protects the globe and contains retractor muscles to elevate the eyelid. Aside from its aesthetic value, upper eyelid is critically important to protect the globe because the eye cannot survive for long without it. Traumatic eyelid injuries could produce a significant loss of tissue causing significant subsequent damage to the globe and could make secondary reconstructive procedures more difficult [7–9].

There are many methods to reconstruct full-thickness eyelid defects. The main principle of eyelid reconstruction is formed of three components: the outer layer of skin, the inner layer of mucosa, and the semi rigid skeleton in the middle. The reconstruction selection is based on the reconstructive ladder, with each of its advantages and disadvantages should be considered before the pro-

cedure. It is impossible for defects with a bone base to use a skin graft, which is the simplest technique. Therefore, a flap is an option. Locoregional flaps (e.g. paramedian forehead or a pedicle superficial temporal artery-based scalp island flap) have the same texture and color advantages but these leave more scarring in the facial area and are only used for the reconstruction of small defects.

The free flap was considered to be superior because the donor defect did not appear in the face area and with the application of anterolateral thigh free flap, the donor defect could be hidden. Debridement was carried out until it left the cranium in the frontal area and the periorbital muscles around the eye, with infection-free and a non-viable tissue with a size of 10 × 12 cm. The defect which was then closed with the anterolateral thigh free flap was extended to obtain a better aesthetic unit and also to hide the lateral scar resulted by the flap on the hairline. This technique is difficult because it requires the transfer of an alive tissue by a blood vessel sized 1–2 mm and requires a thorough evaluation for a successful result within 3 × 24 h postoperatively [10]. One-step reconstruction

with flap would be possible after one step of adequate debridement, because a flap rich in vascularization is a good modality in dealing with infection. In our case, this free flap was not accompanied by an administration of heparin due to a strong recipient arterial flow and smooth recipient venous drainage with a large enough perforator caliber. The goal of the contour can later be obtained by removing a thin flap or by performing re-contouring by means of fat excision or liposuction after the flap is stable [11].

The patient was unfortunate to have a total eyelid avulsion with extensive skin loss for one month before being brought to seek treatment from ophthalmologist. The visual function on the patient could not be restored due to the extent of the damage to the cornea from exposure and secondary infection, and possibly an injury to the optic nerve. Thus, the goal was to maintain appropriate prosthetic position.

During removal of the eyeball, it was important to form a socket. After the eyeball removal, evisceration, and placement of orbital implant, buccal mucosal graft was taken to aid posterior lamella in the upper eyelid, and acrylic conformer was placed. Inferior eyelid margin was stitched to the buccal mucosal graft to ensure that the socket supported the ocular prosthesis. Finally, free flap was harvested to form anterior lamella and cover full thickness skin loss on the frontal region.

#### 4. Conclusion

Eyelid and facial injuries often result in visual loss and various aesthetic problems, raising considerable costs. Even though the visual function of the eye could not be restored in a severe condition, it is principal to improve the cosmetic function. The main objectives of the reconstructive procedure are to make the reconstructed eyelid stable to support the ocular prosthesis and reconstruct the periorbital area with a versatile tissue to improve the patient's quality of life. There are many methods to be applied to reconstruct a complete eyelid avulsion. A surgeon has to choose which method best suits each case.

#### Declaration of Competing Interest

The authors report no declarations of interest.

#### Funding

All funding is from the author. Authors have no sponsor involved.

#### Ethical approval

This study is exempt from ethical approval from the institution.

#### Consent

Written informed consent was obtained from the patient for publication of this case report and accompanying images. A copy of the written consent is available for review by the Editor-in-Chief of this journal on request.

#### Open Access

This article is published Open Access at [sciencedirect.com](https://www.sciencedirect.com). It is distributed under the [IJSCR Supplemental terms and conditions](#), which permits unrestricted non commercial use, distribution, and reproduction in any medium, provided the original authors and source are credited.

#### Author contribution

*Yunia Irawati*: main author, contributing in study concept/design, data collection, analysis, and writing the paper.

*Marsha Alyssa Razief Fitri*: contributing in data collection, analysis and writing the paper.

*Michelle Eva Rebeca Natalia*: contributing in data collection, analysis and writing the paper.

*Parintosa Atmodiwirjo*: contributing in data collection, analysis and writing the paper.

*Mohamad Rachadian Ramadan*: contributing in data collection and writing the paper.

*Sara Ester Triatmoko*: contributing in data collection and writing the paper.

#### Registration of research studies

Not applicable.

#### Guarantor

Yunia Irawati.

#### Provenance and peer review

Not commissioned, externally peer-reviewed.

#### References

- [1] S.P. Santosa, A.I. Mahyuddin, F.G. Sunoto, Anatomy of injury severity and fatality in Indonesian traffic accidents, *J. Eng. Technol. Sci.* 49 (2017) 412–422.
- [2] Central Bureau of Statistics (Indonesia), Traffic Accident, Killed Person, Seriously Injured, Slight Injured and Expected of Material Losses Value 2016–2018, BPS – Statistics Indonesia, 2018 [Internet] [cited 2021 Jan 16]. Available from: <https://www.bps.go.id/indicator/17/513/1/jumlah-kecelakaan-korban-mati-luka-berat-luka-ringan-dan-kerugian-materi.html>.
- [3] D.N. Panagiotidis, P.G. Theodossiadis, C.B. Petsias, T.E. Kyriaki, T.P. Marakis, T.R. Friberg, et al., Ocular injuries secondary to motor vehicle accidents, *Eur. J. Ophthalmol.* 14 (2004) 144–148.
- [4] F. Kuhn, P. Collins, R. Morris, C.D. Witherspoon, Epidemiology of motor vehicle crash-related serious eye injuries, *Accid. Anal. Prev.* 26 (1994) 385–390.
- [5] R.A. Agha, T. Franchi, C. Sohrabi, G. Mathew, for the SCARE Group, The SCARE 2020 guideline: updating consensus surgical CAse REport (SCARE) guidelines, *Int. J. Surg.* 84 (2020) 226–230.
- [6] M.E. Shtewi, M.N. Shishko, G.K. Purohit, J. Sandford-Smith, Road traffic accidents and ocular trauma: experience at Tripoli Eye Hospital, Libya, *Community Eye Health* 12 (1999) 11–12.
- [7] M. Sosin, G.S. Mundinger, A.H. Dorafshar, M. Fisher, B. Bojovic, M.R. Christy, et al., Eyelid transplantation: lessons from a total face transplant and the importance of blink, *Plast. Reconstr. Surg.* 135 (2015) 167e–175e.
- [8] Management of eyelid and periorbital trauma, in: M.A. Codner, C.D. Cord Jr. (Eds.), *Eyelid and Periorbital Surgery*, second edition, Thieme, New York, 2016, pp. 817–839.
- [9] J.L. DeSousa, I. Leibovitch, R. Malhotra, B. O'Donnell, T. Sullivan, D. Selva, Techniques and outcomes of total upper and lower eyelid reconstruction, *Arch. Ophthalmol.* 125 (2007) 1601–1609.
- [10] F. Wei, S. Mardini, *Flaps and Reconstructive Surgery*, 2nd ed., Saunders/Elsevier, Philadelphia, 2016.
- [11] H.H. Jeong, J.P. Hong, H.S. Suh, Thin elevation: a technique for achieving thin perforator flaps, *Arch. Plast. Surg.* 45 (4) (2018) 304–313.