

Single-puncture Method of Laparoscopic Herniorrhaphy in Children

Xue-Qiang Yan¹, Hou-Fang Kuang¹, Nan-Nan Zheng², Jun Yang¹, Xu-Fei Duan¹, Zhen-Chuang Zhu¹, Hong-Qiang Bian¹

¹Department of Pediatric Surgery, Wuhan Medical and Health Center for Women and Children, Wuhan, Hubei 430016, China

²Department of Radiology, Wuhan Medical and Health Center for Women and Children, Wuhan, Hubei 430016, China

Xue-Qiang Yan and Hou-Fang Kuang contributed equally to this work.

To the Editor: Pediatric inguinal hernia repair is a common surgical procedure performed in pediatric patients. Laparoscopic herniorrhaphy has several advantages over conventional open herniotomy; most of them related to the evaluation of possible contralateral patent processus vaginalis (PPV) and avoidance of trauma to the vas deferens and spermatic vessels.

However, percutaneous closure of inguinal hernia cannot prevent simultaneous ligation of subcutaneous tissues (sometimes nerves) of the inguinal canal between the skin and hernia sac; as such, this technique might increase the postoperative morbidity in the long run. The knot is palpable in the subcutaneous space, which might lead to varying degrees of suture reactions.

The procedure for pediatric inguinal hernia was modified to preserve the advantages and overcome the limitations of existing laparoscopic-assisted percutaneous extraperitoneal closure (LPEC). Two 3.5-mm stab incisions were made on both lateral sides of umbilicus, and two trocars of the corresponding size were inserted into the peritoneal cavity. The location of the puncture point through the surface projection of the inner ring was confirmed, and a 1.5-mm stab incision was made. A homemade needle with 2-0 nonabsorbable suture material [Figure 1] was inserted in the loose fat tissues [Figure 2a]. The first half of the circle was begun extraperitoneally from the anterior edge to the posterior edge around the internal inguinal ring. When half of the circle was accomplished, the peritoneal cavity [Figure 2b] was punctured and the end of the 2nd thread into the peritoneal cavity was pulled using a grasper [Figure 2c]. The needle was pulled back slowly to the puncture point where it penetrated. In this point, the direction of the needle was adjusted [Figure 2d] and the opposite half of the internal ring was completed. The spermatic duct and gonadal vessels were crossed over carefully to avoid injury (if the patient was boy). When the previous puncture point was reached, the needle was stabbed into the peritoneal with a double thread (named 3rd thread) [Figure 2e]. The 3rd thread was pulled on one side of the needle to form a new loop, and the end of the 2nd thread was grasped to pass through the new loop [Figure 2f]. The needle was drawn out of the abdominal cavity [Figure 2g]. Extracorporeally, the 3rd thread and 1st thread were pulled simultaneously [Figure 2h] to remove the 2nd thread [Figure 2i]; in this step, the 2nd thread was placed around the inguinal



Figure 1: Homemade needle for pediatric inguinal hernia.

ring under the peritoneum and both ends exit the skin through the same puncture point and tunnel. Gas collected in the distal sac was squeezed out, the thread was tied tightly extracorporeally, and the internal inguinal ring was completely closed. The knot was placed underneath peritoneally, rather than subcutaneously. When asymptomatic contralateral PPV was observed, bilateral closure was performed. During the follow-up period, no recurrence, hydroceles, metachronous hernia, or testicular atrophy were detected.

Laparoscopic inguinal hernia repair for childhood inguinal hernia was first reported in the 1990s.^[1] With the development of medical technology, laparoscopic herniorrhaphy has transitioned from intra-abdominal ligation to total extraperitoneal procedure.^[2]

Address for correspondence: Dr. Nan-Nan Zheng,

Department of Radiology, Wuhan Medical and Health Center for Women and Children, Wuhan, Hubei 430016, China
E-Mail: 251843326@qq.com

Access this article online

Quick Response Code:



Website:
www.cmj.org

DOI:
10.4103/0366-6999.187860

This is an open access article distributed under the terms of the Creative Commons Attribution-NonCommercial-ShareAlike 3.0 License, which allows others to remix, tweak, and build upon the work non-commercially, as long as the author is credited and the new creations are licensed under the identical terms.

© 2016 Chinese Medical Journal | Produced by Wolters Kluwer - Medknow

Received: 01-05-2016 **Edited by:** Peng Lyu

How to cite this article: Yan XQ, Kuang HF, Zheng NN, Yang J, Duan XF, Zhu ZC, Bian HQ. Single-puncture Method of Laparoscopic Herniorrhaphy in Children. Chin Med J 2016;129:2015-6.

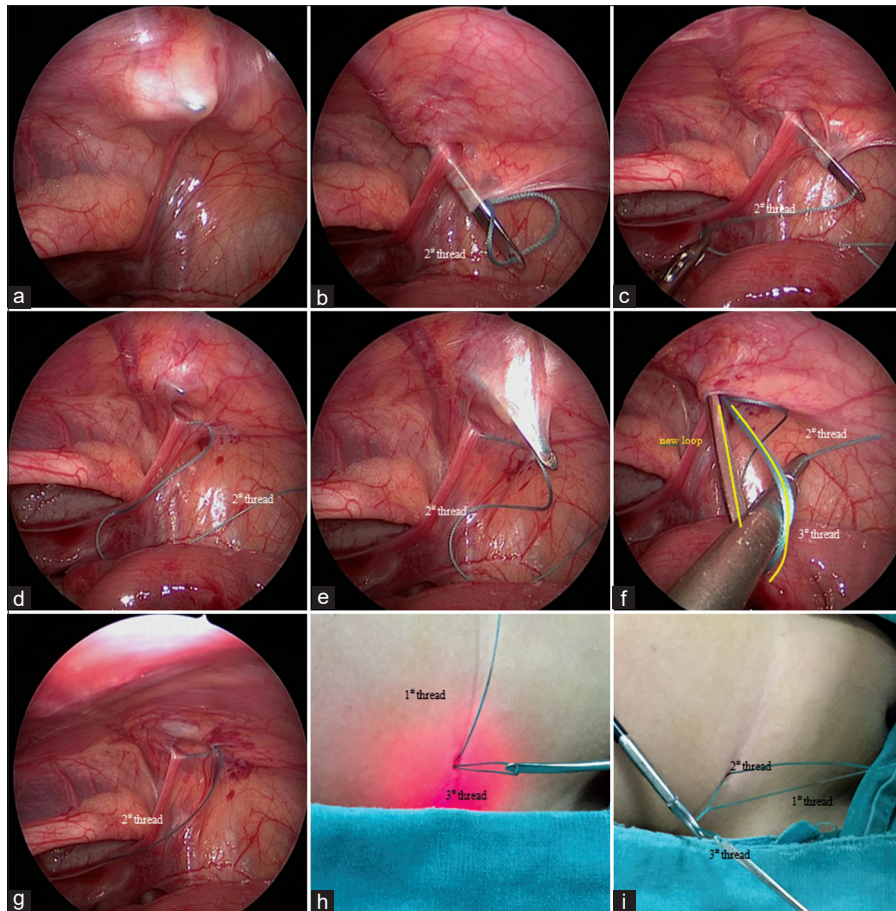


Figure 2: Surgical procedure for pediatric inguinal hernia. (a) A homemade needle with 2-0 nonabsorbable suture material (with a long end and a short end: named 1[#] thread and 2[#] thread) was inserted at the loose fat tissue (5 mm apart from the outside of inferior epigastric artery). (b) When half of the circle accomplished, punctured the peritoneal and (c) pull the end of the 2[#] thread into the peritoneal cavity with the aid of the grasper. (d) The needle was then pulled back slowly to the puncture point where it penetrated in (clung to peritoneal). (e) Finished the opposite half of the internal ring, when the previous puncture point was reached, the needle was stabbed into the peritoneal with a double thread (named 3[#] thread), (f) grasped the end of the 2[#] thread pass through the new loop. (g) Drew the needle (with the 3[#] thread) out of the abdominal cavity. (h) Extracorporeally, pulled the 3[#] thread and (i) the 1[#] thread simultaneously, so the 2[#] thread could be brought out. Then, the thread was tied tightly extracorporeally and the internal inguinal ring was completely closed.

To prevent ligation of celiac wall tissues, both ends of the ligature thread should be in the same channel. In 2014, Liu *et al.*^[3] improved the single-hole sled needle-ring method, in which the needle was punctured twice in the same channel of the abdominal wall fixed through casing. To an extent, this method reduces related complications.

In this proposed procedure, the needle is held underneath the peritoneum during the entire process through a similar method with a homemade hernia needle for LPEC; this procedure ensures that there will be only a single tunnel for two rounds of needle-insertion to prevent the risk of ligating subcutaneous tissues. The proposed method has another advantage over the existing LPEC in terms of reducing suture reactions (ranging from simple granuloma to stitch abscesses), which has been reported in approximately 3% of repairs.^[4] In the current procedure, no suture reactions occurred because the knot had been placed deep underneath the peritoneum rather than in the subcutaneous tissue.

In conclusion, the proposed procedure is safe, feasible, reliable, and presents a low recurrence rate; hence, the modified technique should be considered an alternative treatment for pediatric indirect inguinal hernia. However, the technology described here still does not solve the problem of how to prevent the vas deferens and spermatic cord from twisting. This will be gradually improved in the subsequent studies.

Financial support and sponsorship

Nil.

Conflicts of interest

There are no conflicts of interest.

REFERENCES

- Montupet P, Esposito C. Laparoscopic treatment of congenital inguinal hernia in children. *J Pediatr Surg* 1999;34:420-3. doi: 10.1016/S0022-3468(99)90490-6.
- Lee DY, Baik YH, Kwak BS, Oh MG, Choi WY. A purse-string suture at the level of internal inguinal ring, taking only the peritoneum leaving the distal sac: Is it enough for inguinal hernia in pediatric patients? *Hernia* 2015;19:1-4. doi: 10.1007/s10029-015-1348-7.
- Liu W, Wu R, Du G. Single-port laparoscopic extraperitoneal repair of pediatric inguinal hernias and hydroceles by using modified Kirschner pin: A novel technique. *Hernia* 2014;18:345-9. doi: 10.1007/s10029-013-1181-9.
- Ozgediz D, Roayaie K, Lee H, Nobuhara KK, Farmer DL, Bratton B, *et al.* Subcutaneous endoscopically assisted ligation (SEAL) of the internal ring for repair of inguinal hernias in children: Report of a new technique and early results. *Surg Endosc* 2007;21:1327-31. doi: 10.1007/s00464-007-9202-3.