

Received: 2019.03.25

Accepted: 2019.05.08

Published: 2019.06.06

Perinatal Outcomes After Emergency Cervical Cerclage for Cervical Insufficiency with Prolapsed Membranes

Authors' Contribution:

Study Design A

Data Collection B

Statistical Analysis C

Data Interpretation D

Manuscript Preparation E

Literature Search F

Funds Collection G

ABC **Qi Pang**

CDEF **Xiaoning Jia**

ACF **Lei Chen**

Department of Obstetrics and Gynecology, Sixth Medical Center of the People's Liberation Army (PLA) General Hospital, Beijing, P.R. China

Corresponding Author: Lei Chen, e-mail: leichenplanavy@sina.com

Source of support: Departmental sources

Background: To study the clinical effective of emergency cervical cerclage (ECC) in pregnant women who have cervical insufficiency with prolapsed membranes.

Material/Methods: This study was devised as a retrospective cohort in a single medical center, in which we collected clinical data from patient records. Inclusion criteria were: physical examination indicated ECC was performed at 15 to 25 gestational weeks at the Sixth Medical Center of the PLA General Hospital, and singleton pregnancy. The collected clinical data included: duration of pregnancy at delivery, interval between ECC and delivery, neonatal weight, neonatal mortality, neonatal morbidity, and Neonatal Intensive Care Unit (NICU) admission.

Results: We included 50 women with singleton pregnancies. No surgical complications occurred in any patients. The gestational age at cerclage was 21.3 ± 2.2 weeks. No patients had membrane damage due to surgery. No surgical complications were reported. Five (10%) patients underwent chorioamnionitis. The time interval between ECC and delivery was 11.2 ± 7.1 weeks. The mean gestational age at delivery was 34.1 weeks. The rate of vaginal delivery was 96%. Ten patients had pregnancy lasting longer than 36 weeks. The mean neonate delivery weight was 2510.7 g. Twenty neonates were admitted to the Neonatal Intensive Care Unit (NICU), and the mean NICU stay was 21 days.

Conclusions: ECC has good perinatal results. Our results provide clinical evidence for the efficacy and risks of ECC.

MeSH Keywords: **Cerclage, Cervical • Perinatal Mortality • Uterine Cervical Incompetence**

Full-text PDF: <https://www.medscimonit.com/abstract/index/idArt/916480>

 2046

 3

 2

 17



Background

Many pregnancy complications can occur during the second trimester of pregnancy in women with cervical insufficiency, which can lead to increased perinatal morbidity and mortality. Premature rupture of the membranes, chorioamnionitis, spontaneous abortion, and preterm delivery are common adverse events associated with cervical insufficiency, accounting for 0.2% to 7% of all complicated pregnancies [1]. Preterm birth is the main cause of perinatal mortality [2]. Due to complex maternal factors, the incidence of preterm birth remains high despite improvements in healthcare of pregnant women worldwide. Cervical insufficiency is the leading cause of premature birth. Among all complications of pregnancy, cervical insufficiency accounts for 0.1% to 1.0% [3]. Previous studies found cervical insufficiency accounts for 16% to 20% of all second trimester fetal losses [4] and 10% of preterm deliveries [5].

The classical definition of cervical insufficiency is the cervical absence of clinical contractions, and inability to retain the fetus, or labor in the second trimester [3]. There are many factors associated with cervical insufficiency, including repeated cervical dilation, loop electrosurgical excision, conization, and exposure to diethylstilbestrol [7]. Cervical insufficiency is diagnosed retrospectively, usually after painless cervical dilation. Cervical cerclage is the leading clinical treatment for cervical insufficiency and has good clinical efficacy at 12 to 14 gestational weeks. For some pregnant women with no signs of severe cervical insufficiency, ECC is an optional clinical treatment. However, the clinical efficacy of ECC had not been fully evaluated, especially in severe cervical insufficiency, such as prolapsed membranes. Additionally, ECC performed in the second trimester of pregnancy for cervical insufficiency, such as cervical shortening or dilation, is associated with many complications [8]. Assuming that ECC can significantly extend the gestational period, however, the safety of maternal and fetal from the time interval between cerclage and delivery has been the primary concern of clinicians.

The aim of this study was to evaluate the perinatal outcomes after ECC for women who had cervical insufficiency with prolapsed membranes. The results provide reliable data on the benefits and risks of ECC for clinical practice. This study is the first case series report on women who had severe cervical insufficiency with prolapsed membranes who underwent ECC in china.

Material and Methods

This retrospective study collected clinical data from women with singleton pregnancies who underwent ECC at the Sixth Medical Center of the PLA General Hospital, Beijing, China,

between January 1, 2007, and January 31, 2017. Inclusion criteria were: (I) patients with singleton pregnancies; (II) patients with ≤ 28 weeks of amenorrhea; (III) patients without uterine contractions; (IV) patients without vaginal bleeding; and (V) patients with prolapsed membranes without chorioamnionitis. Exclusion criteria were: (I) patients with multiple pregnancies; (II) patients with > 28 weeks of amenorrhea; (III) patients with uterine contractions; (IV) patients with active vaginal bleeding; (V) patients with chorioamnionitis; and (VI) patients with premature rupture of membranes. This study was approved by the Ethics Committee of the PLA General Hospital.

The clinical data were collected from telephone follow-up and medical records. Data on population characteristics such as age, history of spontaneous abortion, and parity of patients were collected. For each patient, the operative time, blood loss, length of hospital stay, and intraoperative or postoperative complications were collected and analyzed. We collected data on maternal and neonatal perinatal outcomes, including gestational age at delivery, the interval between ECC and delivery, late spontaneous abortion, chorioamnionitis, neonatal delivery mode, neonatal delivery weight, rate of neonatal death, and neonatal morbidity.

Cervical insufficiency with prolapsed membranes was assessed by clinician examination using speculums, and visible membranes are shown in Figure 1. Patients were under spinal anesthesia in Trendelenburg position. McDonald cervical cerclage were performed using 1.0-mm sutures (Mersilene; Ethicon, Somerville, NJ, USA) [9]. The technique involves the use of a circular suture allowing traction in the entire cervical circumference. For the prolapsed membranes, the patient's head was lowered into dorsal lithotomy position to retract the prolapsed membranes so that a greater length of the expanded cervix was exposed for surgery. Before the ECC procedure, the amniotic sac was returned inside the uterus to reduce intraoperative risk of membrane rupture. A finger of a glove filled with cotton pads was introduced via the cervical canal to gently push the prolapsed membranes into the uterine cavity during ECC. When the knot was secured, the finger was removed (Figure 2). In some patients with greater amniotic fluid volume and pressure, transabdominal amniocentesis with amniotic fluid reduction was performed under ultrasonography guidance to reduce the volume and pressure of amniotic fluid in the prolapsed sac, allowing the prolapsed amniotic sac to return inside the uterine cavity.

All women underwent ultrasound examination to determine fetal number, viability, and fetal abnormalities by an experienced operator. All women accepted suppression of uterine contractions and preoperative preventive anti-infection treatment. Hydrochloride-lituojun has been routinely used for suppressing uterine muscle contractions. For emergency patients

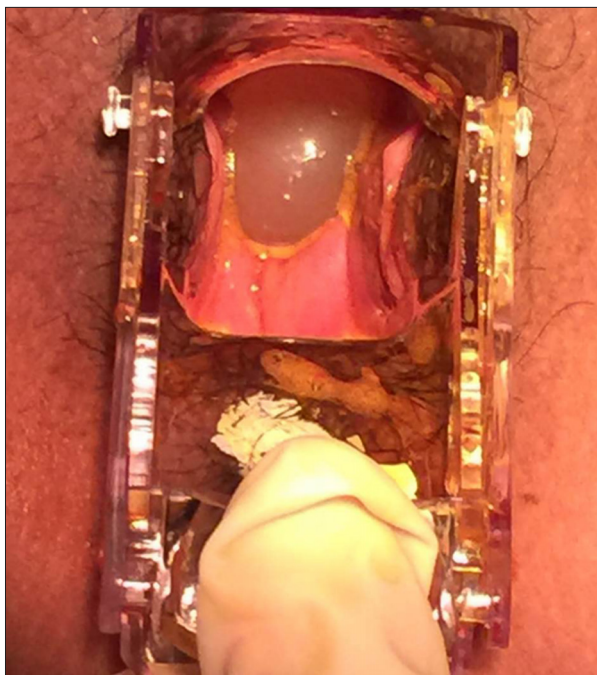


Figure 1. Speculum examination with visible the prolapsed membrane through the cervical into the vagina.

admitted to hospital, the physician opens the cervix and performs comprehensive evaluation of flattening and bleeding to formulate a plan for safe drug use administered under the close observation. Blood pressure, pulse rate, and fetal heart rate should be closely monitored during intravenous drip. Routine use of antibiotics is used to prevent amniotic infection in the perioperative period.

After ECC, all patients remained in hospital for 1-week observation, continued prevention of infection, and inhibition of uterine contractions, and these precautions are the same as used preoperatively. Discharge advice included: (1) Avoid standing for long periods of time and avoid strenuous activities; and (2) Return to hospital for ultrasound examination routinely once a week. If there were active uterine contractions, PROM, or chorioamnionitis, then the cervical cerclage suture was removed. If not, the cervical cerclage suture was removed at 37 gestational weeks or at the time of cesarean delivery.

We collected and analyzed data on obstetric and neonatal outcomes, gestational weeks at diagnosis, gestational weeks at delivery, the time from suture to delivery, incidence of pre-term birth (<37 weeks) and term birth (≥ 37 weeks), incidence of cesarean delivery, and Apgar scores at 5 min after birth.

Statistical analysis was conducted with SPSS 17.0 (SPSS, Inc, Chicago, IL, USA). The clinical data are presented as mean \pm SD.

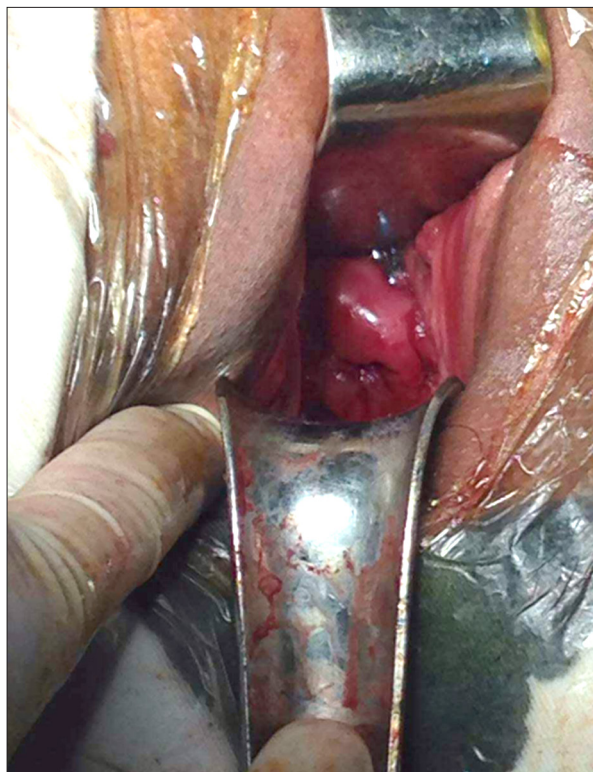


Figure 2. Direct image of the cervical immediately after applying the McDonald cerclage were performed.

Results

The study included 60 women who underwent ECC. There were 10 patients who either did not deliver at the Sixth Medical Center of the PLA General Hospital or who were lost to follow-up; therefore, 50 patients with singleton pregnancy were included for analysis. The maternal population characteristics and surgical data of this study are shown in Table 1. No surgical complications were reported in any included patients. The mean patient age was 30.2 ± 5.5 years and the mean BMI was 23.5 ± 4.6 kg/m². The median gravidity was 2 (range, 1 to 6) and the median parity was 0 (0 to 3). Ten (20%) patients had previously undergone cervical surgical procedures (curettage, conization, and hysteroscopy). Thirty (60%) of the included patients had previous spontaneous abortion. The gestational age at cerclage was 21.3 ± 2.2 weeks. The mean operation time was 60.5 min. The mean blood loss was 20 ml. None of the patients had membrane damage due to surgery. No surgical complications were reported in the study population. Five (10%) patients underwent chorioamnionitis and received antibiotic treatment, but this did not affect the pregnancy outcome.

Obstetrics outcomes are summarized in Table 2. The time interval between ECC and delivery was 11.2 ± 7.1 weeks. The mean gestational age at delivery was 34.1 weeks. ECC prolonged gestation by nearly 10 weeks. The rate of vaginal deliveries was

Table 1. Maternal population characteristics of this study.

Variables	Patients with prolapsed membranes (N= 50)
Age (year)	30.2±5.5
BMI (kg/m ²)	23.5±4.6
Gravidity	2 (1–6)
Parity	0 (0–3)
Previous cervical surgical procedures	10 (20%)
Previous spontaneous abortion	30 (60%)
Length of pregnancy at cerclage, week	21.3±2.2
Operation time (min)	60.5±11.3
Blood loss (ml)	20±10.5
Membrane damage	0 (0%)

Values are given as mean ±SD, number (percentage), or median (range).

Table 2. Obstetric outcomes.

	Patients with prolapsed membranes (N=50)
Suture to delivery interval (week)	11.2±7.1
Length of pregnancy at delivery (week)	34.1±5.5
Chorioamnionitis	5 (10%)
Vaginal delivery	48 (96%)
Cesarean delivery	2 (4%)

Values are given as mean ±SD, number (percentage), or median (range).

96% and the cesarean delivery rate was 4%. The perinatal infant outcomes are summarized in Table 3. Among the 50 neonates delivered after 24 gestational weeks, we found only 6% preterm delivery at less than 28 gestational weeks. The rate of preterm delivery at less than 32 weeks was 60%. There were 10 patients who had pregnancy lasting more than 36 weeks. Only 1 neonatal death occurred in the perinatal period due to preterm delivery. The mean neonatal delivery weight was 2510.7 g. The rate of severe neonatal morbidity was 14%. There were 31 neonates without morbidity. There were 6 neonates with Apgar scores ≤7 at 5 min. Twenty neonates were admitted to the Neonatal Intensive Care Unit (NICU), and the mean NICU stay was 21 days.

Table 3. Perinatal infant outcome.

	Patients with prolapsed membranes (N=50)
Neonatal mortality	1 (2%)
Neonatal survival	49 (98%)
Delivery weight, (g)	2510.7±900.5
Preterm delivery	
<28 week	3 (6%)
<32 week	30 (60%)
<36 week	40 (80%)
≥36 week	10 (20%)
Neonatal morbidity	
Severe	7 (14%)
Minimal	12 (24%)
None	31 (62%)
Apgar score ≤7 at 5 min	6 (12%)
NICU admission	20 (40%)
NICU stay (day)	21±13.4

Values are given as mean ±SD or number (percentage).
NICU – Neonatal Intensive Care Unit.

Discussion

In the present study, we summarize the pregnancy outcomes of 50 women who had prolapsed membranes and who underwent ECC at our hospital. We found that ECC for women who had prolapsed membranes prolonged pregnancy by 10 weeks, and the neonatal survival rate was 98%. There were 15 patients who had chorioamnionitis. The rate of preterm delivery at <36 weeks was 80%. Our results are similar to those of a previous study, which reported that cervical dilation more than 4 cm and prolapsed membranes were associated with a higher risk of pregnancy failure [10].

Surgical therapy is the mainstay and the key point to prolongation of pregnancy [10–12]. Cerclage is the most common method used to treat cervical insufficiency [13]. Most data from previous studies about ECC have been retrospective [10]. A randomized controlled trial [14] that enrolled 23 cases found that, compared with patients treated with bed rest, patients who underwent ECC had significantly longer extension of pregnancy and decreased incidence of preterm delivery. Our study found that the interval from suture to delivery was 11.2±7.1 weeks, and ECC was demonstrated to prolong pregnancy. A previous retrospective study [15] evaluated the effectiveness

of ECC, reporting an interval from suture to delivery similar to that found in the present study. Some previous studies found that physical examination indicating ECC can increase prevent spontaneous preterm delivery by increasing the time between diagnosis and delivery [10,16,17]. To evaluate the true clinical benefit of ECC in practice, more comprehensive evaluation of the predictive factors for successful pregnancy outcomes is needed. Information about risk factors of ECC are needed for counseling women who receive ECC, and all patients should be fully aware of the possible surgical risk.

In 2003, a retrospective study of patients with singleton pregnancies following ECC found risk factors associated with delivery at or after 28 gestational weeks [16]. If the prolapsed membranes do not extend outside the cervix, ECC is associated with better obstetric outcomes, but if the prolapsed membranes extend outside the cervix, ECC is associated with decreased odds of delivery longer than 28 gestational weeks. Gestational age greater than 22 weeks at ECC was associated with successful pregnancy outcomes, and a gestational age less than 22 weeks at ECC was associated with worse pregnancy outcomes. This is consistent with our findings. If the ECC occurred before 22 gestational weeks, it was associated with successful pregnancy outcomes, and in our study, only 3 patients delivered at <28 weeks of pregnancy.

The clinical efficacy of ECC is not fully established. We found that favorable perinatal outcomes can be achieved after ECC, even if the membranes are prolapsed beyond the cervical external, consistent with previous research results [17]. Major complications were chorioamnionitis among women with prolapsed membranes in this study, and there was no obvious

adverse effect associated with use of antibiotics. Our study provides important information about the risks and benefits of ECC for women with prolapsed membranes.

The major strength of this study was the large number of cases. It is the largest sample size and the first study about ECC for severity cervical insufficiency in China. Another strength is the inclusion of only singleton pregnancies, which strengthens our results. The third strength is the strict inclusion and exclusion criteria. Limitations of this study are its retrospective design, the subjectivity of cervical examination, and the potential selection bias. In addition, the study sample size was limited, and there may have been bias due to single-center analysis. In the present study, we found that ECC can effectively prolong pregnancy and achieve good perinatal results. During pregnancy, the cervical length should be monitored, and elective cervical cerclage should be performed as soon as possible instead of waiting until women with prolapsed membranes accept ECC.

Conclusions

ECC was associated with favorable perinatal results. Our results suggest that ECC can be safe and effective. Moreover, this study provides important information about the benefits and risks of ECC for use in counseling patients with cervical insufficiency with prolapsed membranes who are considering ECC, and this information should be useful in clinical practice.

Conflicts of interest

None.

References:

- American College of Obstetricians and Gynecologists. ACOG Practice Bulletin no. 142: Cerclage for the management of cervical insufficiency. *Obstet Gynecol*, 2014; 123: 372–79
- Matthews TJ, MacDorman MF. Infant mortality statistics from the 2010 period linked birth/infant death data set. *Natl Vital Stat Rep*, 2013; 61(8): 1–27
- Stupin JH, David M, Siedentopf JP et al: Emergency cerclage versus bed rest for amniotic sac prolapse before 27 gestational weeks. A retrospective, comparative study of 161 women. *Eur J Obstet Gynecol Reprod Biol*, 2008; 139: 32–37
- Stromme WB, Haywa EW: Intrauterine fetal death in second trimester. *Am J Obstet Gynecol*, 1963; 85: 223–33
- Iams JD, Johnson FF, Sonek J et al: Cervical competence as a continuum: A study of ultrasonographic cervical length and obstetric performance. *Am J Obstet Gynecol*, 1995; 172: 1097–103
- ACOG Practice Bulletin no. 142: Cerclage for the management of cervical insufficiency. *Obstet Gynecol*, 2014; 123(2 Pt 1): 372–79
- Nelson L, Dola T, Tran T et al: Pregnancy outcomes following placement of elective, urgent and emergent cerclage. *J Matern Fetal Neonatal Med*, 2009; 22: 269–73
- Practice bulletin no. 130: Prediction and prevention of preterm birth. *Obstet Gynecol*, 2012; 120: 964–73
- McDonald IA: Suture of the cervix for inevitable miscarriage. *J Obstet Gynaecol Br Emp*, 1957; 64: 346–50
- Abu Hashim H, Al-Inany H, Kilani Z: A review of the contemporary evidence on rescue cervical cerclage. *Int J Gynecol Obstet*, 2014; 124: 198–203
- Algara AC, Rodríguez AG, Vazquez AC et al: Laparoscopic approach for fibroid removal at 18 weeks of pregnancy. *Surg Technol Int*, 2015; 27: 195–97
- Brown R, Gagnon R, Delisle MF et al: Cervical insufficiency and cervical cerclage. *J Obstet Gynaecol Can*, 2013; 35(12): 1115–27
- Harger JH: Cerclage and cervical insufficiency: An evidence-based analysis. *Obstet Gynecol*, 2002; 100(6): 1313–27
- Althuisius SM, Dekker GA, Hummel P et al: Cervical incompetence prevention randomized cerclage trial: Emergency cerclage with bed rest versus bed rest alone. *Am J Obstet Gynecol*, 2003; 189(4): 907–10
- Çavuş Y, Uysal A, Balsak D et al: Emergency cervical cerclage: Effect on pregnancy outcome and mode of delivery. *J Matern Fetal Neonatal Med*, 2014; 27: 80–83
- Terkildsen MF, Parilla BV, Kumar P et al: Factors associated with success of emergent second-trimester cerclage. *Obstet Gynecol*, 2003; 101(3): 565–69
- Debby A, Sadan O, Glezerman M et al: Favorable outcome following emergency second trimester cerclage. *Int J Gynecol Obstet*, 2007; 96: 16–19