

Received: 2017.01.31
Accepted: 2017.03.30
Published: 2017.06.06

ISSN 1941-5923
© Am J Case Rep, 2017; 18: 632-636
DOI: 10.12659/AJCR.903580

Synchronous Gastrointestinal Carcinoid Tumor and Colon Adenocarcinoma: Case Reports and Literature Review

Authors' Contribution:
Study Design A
Data Collection B
Statistical Analysis C
Data Interpretation D
Manuscript Preparation E
Literature Search F
Funds Collection G

ABCDEF 1 **Jessica N. Winn**
ABCDEF 1 **Anjana Sathyamurthy**
ABCDEF 2 **Jessica L. Kneib**
ABCDEF 1 **Jamal A. Ibdah**
ABCDEF 1 **Veysel Tahan**

1 Division of Gastroenterology and Hepatology, University of Missouri, Columbia, MO, U.S.A..
2 Department of Pathology, University of Missouri, Columbia, MO, U.S.A.

Corresponding Author: Veysel Tahan, e-mail: tahanv@health.missouri.edu
Conflict of interest: None declared





Case series

Patient: Male, 40 • Male, 70
Final Diagnosis: Synchronous gastrointestinal carcinoid tumor and colon adenocarcinoma
Symptoms: Weakness
Medication: —
Clinical Procedure: Colonoscopy
Specialty: Gastroenterology and Hepatology

Objective: Rare co-existence of disease or pathology
Background: Coexistence of carcinoid tumor and colorectal adenocarcinoma is rare. In this report, we present two cases and review the current literature for synchronous carcinoid tumor and colorectal carcinoma occurrence.
Case Reports: In both cases, the rectal carcinoid tumors and sigmoid colon adenocarcinomas were detected by colonoscopy. The colon adenocarcinomas were effectively treated with a laparoscopic sigmoidectomy and the carcinoids were successfully removed endoscopically. Our 40-year-old patient was the youngest among 17 reported patient cases.
Conclusions: These two cases demonstrate that the diagnosis of gastrointestinal carcinoid requires a complete assessment of the remainder of the colon for another primary cancer to achieve a timely treatment management strategy.

MeSH Keywords: Adenocarcinoma • Carcinoid Tumor • Colonic Neoplasms • Neoplasms, Multiple Primary • Neuroendocrine Tumors

Full-text PDF: <http://www.amjcaserep.com/abstract/index/idArt/903580>

 1159  2  1  25



Background

Colorectal cancer is one of three most common cancers in men and women worldwide [1]. The rectum is the second most common site for gastrointestinal neuroendocrine tumor (NET); however, it only accounts for 1–2% of all rectal tumors [2]. Although higher stage metastatic carcinoid tumor prognosis is poor and requires molecularly targeted therapies, local stage carcinoid tumor treatment is considered curative after resection, with excellent prognosis. The current literature revealed several cases of concurrent carcinoid tumor and colorectal adenocarcinoma. Here, we report our two cases of synchronous rectal carcinoid and sigmoid colon adenocarcinoma that were diagnosed by colonoscopy. In addition, we conducted a review of the current literature for similar dual gastrointestinal carcinoid and colorectal cancer occurrences.

Case Report

Case #1

A 40-year-old white male presented to the emergency department with a history of hematochezia and abdominal pain for one year. A computerized tomography (CT) scan of abdomen and pelvis was obtained which revealed a focal segment of the sigmoid colon with wall thickening and surrounding prominent lymph nodes. The patient was discharged home on ciprofloxacin and metronidazole therapy. He underwent a colonoscopy one week later. The colonoscopy revealed a 6 cm circumferential, friable, and ulcerated sigmoid colon mass; biopsy revealed moderately differentiated adenocarcinoma. In addition, a 12 mm rectal polyp was also identified and removed with a cold snare. Pathology of this polyp revealed well-differentiated neuroendocrine tumor with free margins (carcinoid tumor; Figure 1A). A CT of the chest was obtained and

this was negative for distant metastasis. The patient underwent laparoscopic sigmoidectomy. Pathology was reported as moderately differentiated adenocarcinoma (Figure 1B) invading the peri-colonic fat with eight microscopic adenocarcinoma tumor deposits. Adjuvant chemotherapy, with leucovorin calcium, 5-fluorouracil, and oxaliplatin-6, was started 4-weeks postoperatively.

Case #2

A 70-year-old male with a history of bright red blood per rectum (BRBPR) underwent CT scan of abdomen and colonoscopy procedures. Stage III adenocarcinoma of the sigmoid colon was detected. Also, a 10 mm rectal polyp was snared and its pathology was consistent with carcinoid tumor with free margins (Figure 2). The patient underwent laparoscopic sigmoidectomy and received adjuvant chemotherapy with 5-fluorouracil and leucovorin. Recent follow-up colonoscopy was negative.

Discussion

While colorectal adenocarcinoma is one of the three most common newly diagnosed internal malignancies in the USA, neuroendocrine tumors are rare and only represent 0.5% of all newly diagnosed cancers with the most common site being the gastrointestinal tract [1]. Dual gastrointestinal carcinoid and colorectal cancer can occur. We conducted a review of the literature and summarized the reported cases with both dual gastrointestinal carcinoid tumor and colorectal adenocarcinoma in Table 1. The first reported case of synchronous carcinoids with non-carcinoid gastrointestinal tract neoplasm was documented in 1949 by Pearson and Fitzgerald [3]. A literature review conducted by Wohaldo et al. in 2010 includes seven presentations of co-existent carcinoid and adenocarcinoma of the gastrointestinal tract [4]. In a study by Cokmert et al. in

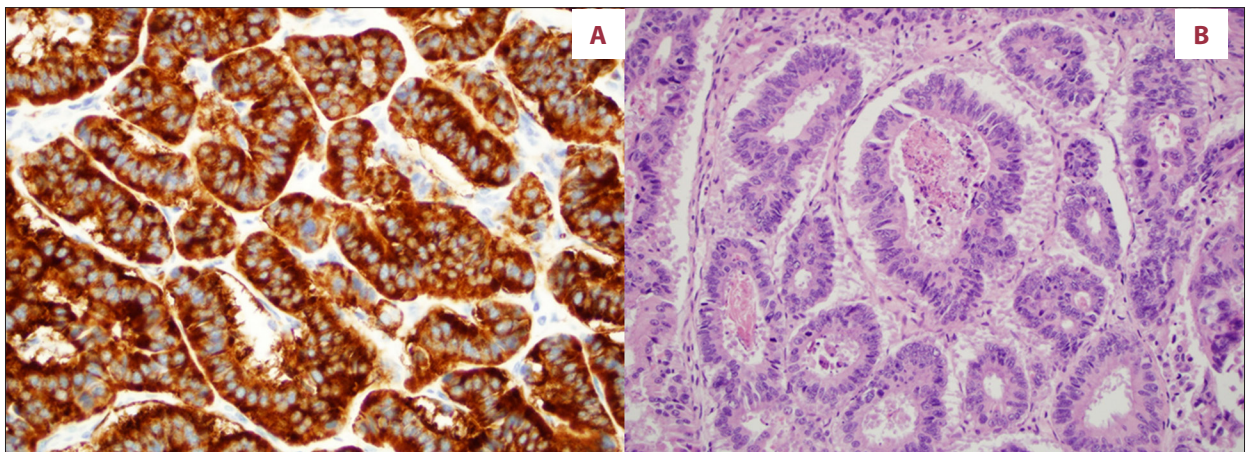


Figure 1. (A) Well differentiated neuroendocrine tumor, grade 1 (carcinoid tumor), synaptophysin immunostain at 400× magnification. (B) Moderately differentiated invasive adenocarcinoma, H&E stain at 200× magnification.

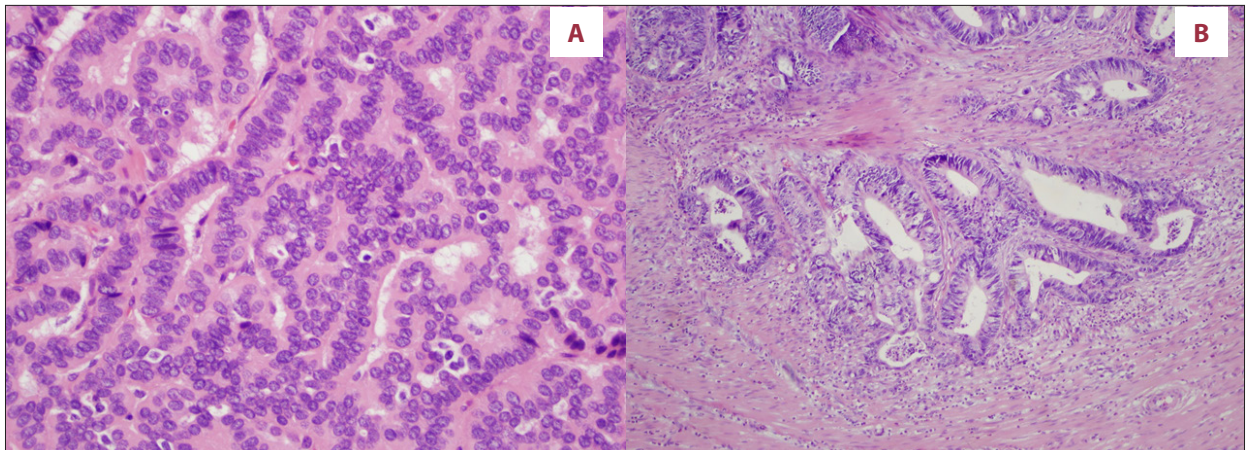


Figure 2. (A) Well differentiated neuroendocrine tumor (carcinoid tumor), H&E stain at 200× magnification. (B) Moderately differentiated invasive adenocarcinoma, H&E stain at 100× magnification.

Table 1. The literature review of cases with both gastrointestinal carcinoid tumor and colon adenocarcinoma.

No	Author (Reference #)	Age	Sex	Location of carcinoid	Location of colon adenocarcinoma	Treatment
1	Pearson and Fitzgerald [3]	88	M	Ileum	Descending colon	N/A
2	Pearson and Fitzgerald [3]	73	M	Stomach	Sigmoid colon	N/A
3	Pearson and Fitzgerald [3]	61	F	Ileum	Descending colon	N/A
4	Cokmert et al. [5]	63	F	Ampulla of vater	Sigmoid colon	Pancreato-duodenectomy, Left hemicolectomy
5	Zhu et al. [6]	64	F	Rectum	Rectum	Low anterior resection of rectum
6	Mohapatra et al. [7]	83	M	Descending colon	Sigmoid colon	Left hemicolectomy
7	Kucinski et al. [17]	72	F	Ileum	Transverse colon	Right hemicolectomy
8	Tse et al. [18]	72	N/A	Ileum	Hepatic flexure of colon	Right hemicolectomy
9	McHugh et al. [19]	74	F	Ileum	Rectum	Anterior rectal resection with segmental resection of the ileum
10	Khubchandani et al. [20]	53	F	Rectum	Rectum	Anterior rectal resection
11	Sacchi et al. [21]	57	N/A	Ileum	Ascending colon	Right hemicolectomy
12	Habal et al. [22]	52	N/A	Rectum	Sigmoid colon	Resection of the sigmoid colon and rectum
13	Cioffi et al. [23]	64	F	Ileum	Ileum	Resection of distal ileum and cecum
14	Aslam et al. [24]	67	F	Ileocecal junction	Sigmoid colon	Subtotal colectomy & resection of terminal ileum
15	Vootla et al. [25]	46	F	Rectal	Hepatic flexure of colon	Right hemicolectomy and adjuvant chemotherapy
16	Present case 1	40	M	Rectum	Sigmoid colon	Snare resection of rectal carcinoid, sigmoid resection and adjuvant chemotherapy
17	Present case 2	70	M	Rectum	Sigmoid colon	Snare resection of rectal carcinoid, sigmoid resection and adjuvant chemotherapy

2013, there was a report of a high-grade neuroendocrine carcinoma located in the ampulla of Vater with synchronous sigmoid colon adenocarcinoma [5]. Data collected by Zhu et al. in 2015 includes a case of synchronous collision neuroendocrine and adenocarcinoma of the rectum [6] and most recently there was a case report of synchronous sigmoid adenocarcinoma and NET of the descending colon [7].

Including our two cases, of the total 17 synchronous carcinoid tumor and colon carcinoma cases reported, nine were females and five were males. The gender in three dual tumor cases was not reported. The median age of these 17 double primary malignant tumor cases was 64 years (range 40–88 years). Sixth decade and higher median age may increase the risk for both types of primary malignant tumors to occur. However, these synchronous tumors can occur even at “early age”, as one of our cases was the youngest case in the literature (Table 1).

Rectal carcinoids only account for 1–2% of all rectal tumors [8]. Tichansky et al. reported that 8% of patients with colorectal carcinoid also had synchronous cancer [9]. While rectal carcinoids are typically nonfunctioning and asymptomatic, their presence should raise awareness of a potential synchronous colorectal cancer [10] as observed in our cases. The rectum was the second most common location of carcinoid tumors (6/17) after the ileum (8/17) involvement in synchronous carcinoid and colon adenocarcinoma cases. Our two presented cases also had rectum carcinoid tumors. The most common adenocarcinoma location in these double primary malignant tumor cases was sigmoid colon (7/17) including our two cases (Table 1).

The pathogenesis of the association between colorectal adenocarcinoma and NET remains unclear. A theory proposed by Kato et al. suggests a common stem cell which may undergo similar genetic mutations and give rise to different types of gastrointestinal malignancies. It was reported that a CK20 positive NET was detected in a patient with a synchronous colorectal adenocarcinoma, which is a common marker detected in colorectal adenocarcinomas [11]. Another study by Reim et al. suggested roles of gastrin and cholecystokinin in tissue growth of NET in the gastrointestinal tract with subsequent transformation into colorectal and gastric cancers [12]. The relationship between NET and secondary gastrointestinal malignancies was also suggested in a study by Prommegger et al., who studied 96 patients with NET and found that 14 patients

had NET and a second primary cancer [13]. Aoyagi et al. suggested a connection between NET and differentiated tubular adenocarcinoma [14].

The European Neuroendocrine Tumor Society (ENETS) provided the most recent colorectal NET guideline in 2016. Endoscopic resection by simple polypectomy or endoscopic mucosal resection (EMR) with modified EMR band ligation were given as treatment options for NETs with no involvement of the muscularis propria. However, if a resection margin shows an incomplete border, then endoscopic submucosal dissection (ESD) and transanal endoscopic microsurgery (TEMS) would be indicated as adequate treatment. Simple polypectomy was enough for complete removal of NETs in both of our cases, as shown by free resection margins [15].

There are no current guidelines for an increased interval of surveillance colonoscopy after detection of gastrointestinal carcinoid [13,14] or gastrointestinal stromal tumor [16]. If a gastrointestinal carcinoid tumor is diagnosed through colonoscopy, timely management is necessary. However, there is no guideline for these synchronous tumors' surveillance. We recommended a close surveillance follow-up given their potential synchronous relationship.

Conclusion

The coexistence of carcinoid tumor and colorectal adenocarcinoma is rare with a total of 17 cases, including our two cases, reported in the literature. We recommend that carcinoid tumor may be another colorectal cancer risk factor with the similar mutations and common genetic markers. Dual primary malignant tumors can be diagnosed by endoscopic procedures. We are hoping that our two cases serve as a simulative impulse for clinicians to do colonoscopy when or if they diagnose any gastrointestinal carcinoid tumor. Detection of any carcinoid warrants thorough evaluation of the whole colon for colorectal cancer and close surveillance so that timely management can be achieved.

Conflict of interest

All the authors have no conflicts of interests to declare.

References:

1. Larson, Mark V: Gastric neoplasms and gastroenteric and pancreatic neuroendocrine tumors. *Mayo Clinic Gastroenterology and Hepatology Board Review*. 5th Ed. New York: Oxford University Press, 2015; 65–66
2. Kjell O: Gastrointestinal carcinoid tumors (gastrointestinal neuroendocrine tumors) and the carcinoid syndrome. *Sleisenger and Fordtran's Gastrointestinal and Liver Disease*. 9th ed. Philadelphia: Saunders Elsevier, 2010; 481–82
3. Pearson CM, Fitzgerald PJ: Carcinoid tumors; A re-emphasis of their malignant nature; Review of 140 cases. *Cancer*, 1949; 2: 1005–26, illust
4. Wohadlo Ł, Darasz Z, Wysocki W: Multifocal colorectal adenocarcinoma with a synchronous multifocal carcinoid of the small intestine – case report and literature review. *Pol Przegl Chir*, 2011; 83: 562–67

- Cokmert S, Demir L, Akder Sari A et al: Synchronous appearance of a high-grade neuroendocrine carcinoma of the ampulla vater and sigmoid colon adenocarcinoma. *Case Rep Oncol Med*, 2013; 2013: 930359
- Zhu JG, Zhang ZT, Wu GC et al: Synchronous collision neuroendocrine tumor and rectal adenocarcinoma: A case report. *Indian J Surg*, 2015; 77(Suppl. 1): 185–87
- Mohapatra S, Ibrarullah M, Mohapatra A, Baisakh MR: Synchronous adenocarcinoma and neuroendocrine carcinoma of the colon: A case report. *J Surg Case Rep*, 2016; 2016: pii: rjw042
- Modlin IM, Lye KD, Kidd M: A 5-decade analysis of 13,715 carcinoid tumors. *Cancer*, 2003; 97: 934–59
- Tichansky DS, Cagir B, Borrazzo E et al: Risk of second cancers in patients with colorectal carcinoids. *Dis Colon Rectum*, 2002; 45: 91–97
- Solcia E, Kloppel G, Sobin LH: *Histological typing of endocrine tumours*. 2nd ed. New York: Springer, 1999; 160
- Kato T, Terashima T, Tomida S et al: Cytokeratin 20-positive large cell neuroendocrine carcinoma of the colon. *Pathol Int*, 2005; 55: 524–29
- Reim D, Weirich G, Neu B et al: Synchronous adenocarcinoma of the lung and neuroendocrine carcinoma of the ileum. *Int J Colorectal Dis*, 2008; 23: 325–27
- Prommegger R, Ensinger C, Steiner P et al: Neuroendocrine tumors and second primary malignancy – a relationship with clinical impact? *Anticancer Res*, 2004; 24: 1049–51
- Aoyagi K, Kizaki J, Isobe T, Akagi Y: A case of gastric cancer with neuroendocrine carcinoma, signet ring cell carcinoma components, and intramural metastases. *Am J Case Rep*, 2016; 17: 274–79
- Ramage JK, De Herder WW, Delle Fave G et al., Vienna Consensus Conference participants: ENETS consensus guidelines update for colorectal neuroendocrine neoplasms. *Neuroendocrinology*, 2016; 103: 139–43
- Gavriilidis P, Nikolaidou A: Colon adenocarcinoma associated with synchronous extramural gastrointestinal stromal tumor (GIST) of the ileum. *Am J Case Rep*, 2015;16: 837–39
- Kuciński A, Pawłowski W, Krasnodębski IW: [Synchronous intestinal tumours – coexisting adenocarcinoma transverse colon and small intestine carcinoid]. *Gastroenterological Review*, 2006; 1(3): 126–28 [in Polish]
- Tse V, Lochhead A, Adams W, Tindal D: Concurrent colonic adenocarcinoma and two ileal carcinoids in a 72-year-old male. *Aust NZJ Surg*, 1997; 67: 739–41
- McHugh S, O'Donnell J, Gillen P: Synchronous association of rectal adenocarcinoma and tree ileal carcinoid: A case report. *World J Surg Oncol*, 2009; 7: 21
- Khubchandani M, Alford JE: Primary carcinoid and carcinoma of the rectum occurring simultaneously: Report of a case. *Dis Colon Rectum*, 1974; 17: 117–22
- Sacchi G, Falchetti M, Fiorentino M et al: Synchronous multiple primary malignant neoplasm of the gastro intestinal tract: Carcinoid of the midgut and adenocarcinoma of the ascending colon. *Pathologica*, 1988; 80: 583–93
- Habal N, Sims C, Bilchik AJ: Gastrointestinal carcinoid tumors and second primary malignancies. *J Surg Oncol*, 2000; 75: 310–16
- Cioffi U, De Simone M, Ferrero S et al: Synchronous adenocarcinoma and carcinoid tumor of the terminal ileum in a Crohn's disease patient. *BMC Cancer*, 2005; 5: 157
- Aslam MI, Salha IB, Muller S, Jameson JS: Synchronous ileal carcinoid and primary colonic neoplasms: A case report. *Cases J*, 2009; 2: 8317
- Vootla V, Ahmed R, Niazi M et al: Synchronous adenocarcinoma of the colon and rectal carcinoid. *Case Rep Gastroenterol*, 2016; 10: 600–4