



## Case report

## Long-term results of surgical excision of conjunctival retention cyst using trypan blue with methylcellulose

Ghada Zein El- Abedin Rajab<sup>a,\*</sup>, Joseph L. Demer<sup>b,c,d,e</sup><sup>a</sup> Department of Ophthalmology, Menoufia University Hospital, Egypt<sup>b</sup> Department of Ophthalmology, Stein Eye Institute, UCLA, Los Angeles, CA, USA<sup>c</sup> Department of Neurology, UCLA, Los Angeles, CA, USA<sup>d</sup> Neuroscience Interdepartmental Program, UCLA, Los Angeles, CA, USA<sup>e</sup> Bioengineering Interdepartmental Program, UCLA, Los Angeles, CA, USA

## ARTICLE INFO

## Keywords:

Conjunctival cyst  
 Trypan blue  
 Ophthalmic viscosurgical devices  
 Methyl cellulose

## ABSTRACT

**Purpose:** Conjunctival retention cysts may recur if not completely removed. However, the cyst wall often ruptures during surgical excision, making complete removal difficult. In order to ensure complete cyst excision, we used a method of staining the inner cyst wall using trypan blue augmented by Methyl cellulose.

**Observation:** Interventional study. Staining was performed by injecting trypan blue using an insulin needle. Then the needle was kept in place and methyl cellulose was injected to make the cyst content viscous to avoid its collapse after removing the needle. By using this technique, it was possible to excise the lesion as a whole. Three patients were included (unilateral). Two patients had cysts that were secondary to trachoma and were followed for up to 2 years without recurrence. A third patient had a conjunctival cyst following strabismus surgery was not successfully removed.

**Conclusion:** This method is simple and effective for complete excision of conjunctival retention cysts exception for cysts post strabismus surgery.

## 1. Introduction

Conjunctival epithelial retention (inclusion) cysts are common, with one or more small cysts often seen in the inferior fornices of healthy people.<sup>1</sup> These cysts resemble epidermal cysts of the eyelids, and can be congenital (primary) or acquired (secondary).<sup>2</sup> Histopathologically, small cysts may form by apposition of conjunctival folds while large, solitary cysts are considered as implantation cysts in which the surface epithelium was implanted into the substantia propria by trauma, surgery, or inflammation.<sup>1</sup> Clinically, conjunctival epithelial retention cysts are thin-walled, containing clear or occasionally turbid fluid, and most commonly occur in either the bulbar conjunctiva or the conjunctival fornix. These cysts are most commonly asymptomatic and therefore may be simply observed; there may be a mild cosmetic blemish.<sup>2</sup> Treatment is indicated only if cysts cause bothersome symptoms. Since the inner epithelial lining of the cyst is secretory, it usually recurs after aspiration of its fluid. Marsupialization or complete excision is necessary to prevent recurrence.<sup>3</sup>

Surgical excision of conjunctival retention cysts is fraught with recurrence due to incomplete removal. During surgical dissection, healthy

conjunctiva may be sacrificed, creating a problem of closure and the need for graft in the case of a large defect. Incomplete excision is not uncommon due to the thin cyst wall, and clear contents and this predisposes to recurrence. New techniques have been devised to achieve complete removal, such as staining of the cyst wall using Indocyanine green (ICG) and trypan blue (TB) combined with the use of ophthalmic viscosurgical devices (OVDs).<sup>4,5</sup> In this study, we introduced a modified surgical technique to ensure complete removal and to preserve as much as possible healthy conjunctiva.

## 2. Finding

Three patients were studied from 3/2013 to 3/2015. The study was approved by the Menoufia University Institutional Review Board and ethical committee.

**Patient 1:** A 20 - year old male had an inferior temporal forniceal cyst of his left eye due to old trachoma (Fig. 1). There were post trachomatous concretions.

**Patient 2:** A 50 - year old male had an upper nasal forniceal cyst of the left eye, loculated into two parts with localized symblepharon due

\* Corresponding author. 10 Gamal Abo El- Ghar St., Sabry Abo Alam St., Shebin El- Kom, Menoufia, Egypt.

E-mail address: [Ghada.mvupgo@gmail.com](mailto:Ghada.mvupgo@gmail.com) (G.Z. El- Abedin Rajab).

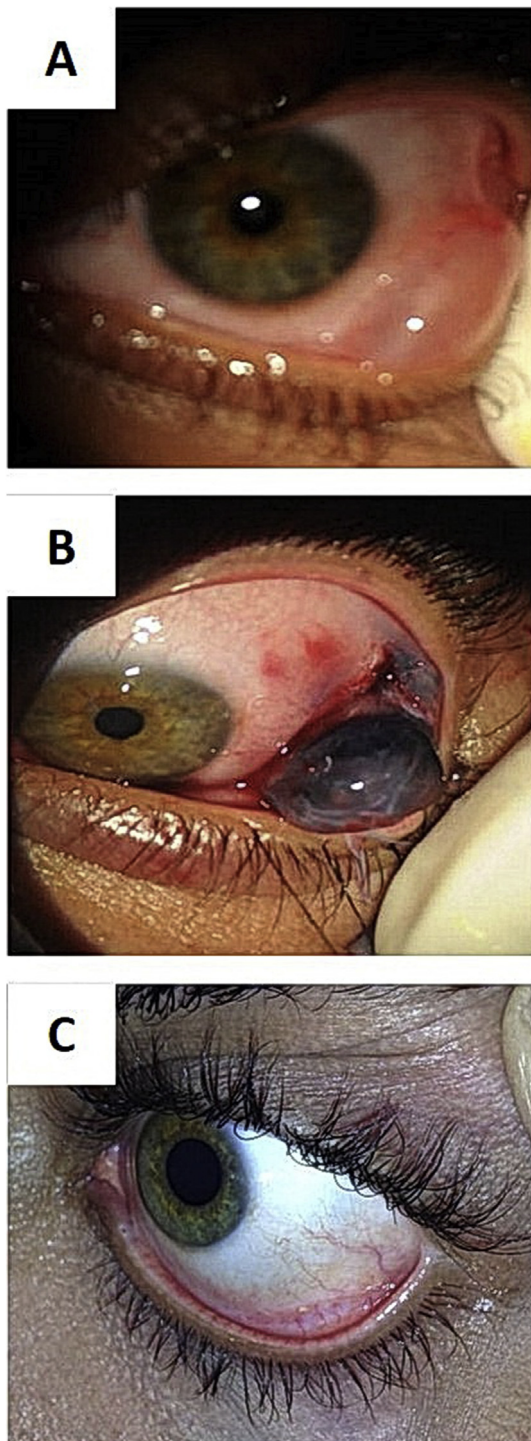
<https://doi.org/10.1016/j.ajoc.2019.01.010>

Received 19 August 2017; Received in revised form 1 July 2018; Accepted 22 January 2019

Available online 06 February 2019

2451-9936/ © 2019 The Authors. Published by Elsevier Inc. This is an open access article under the CC BY-NC-ND license

(<http://creativecommons.org/licenses/by-nc-nd/4.0/>).

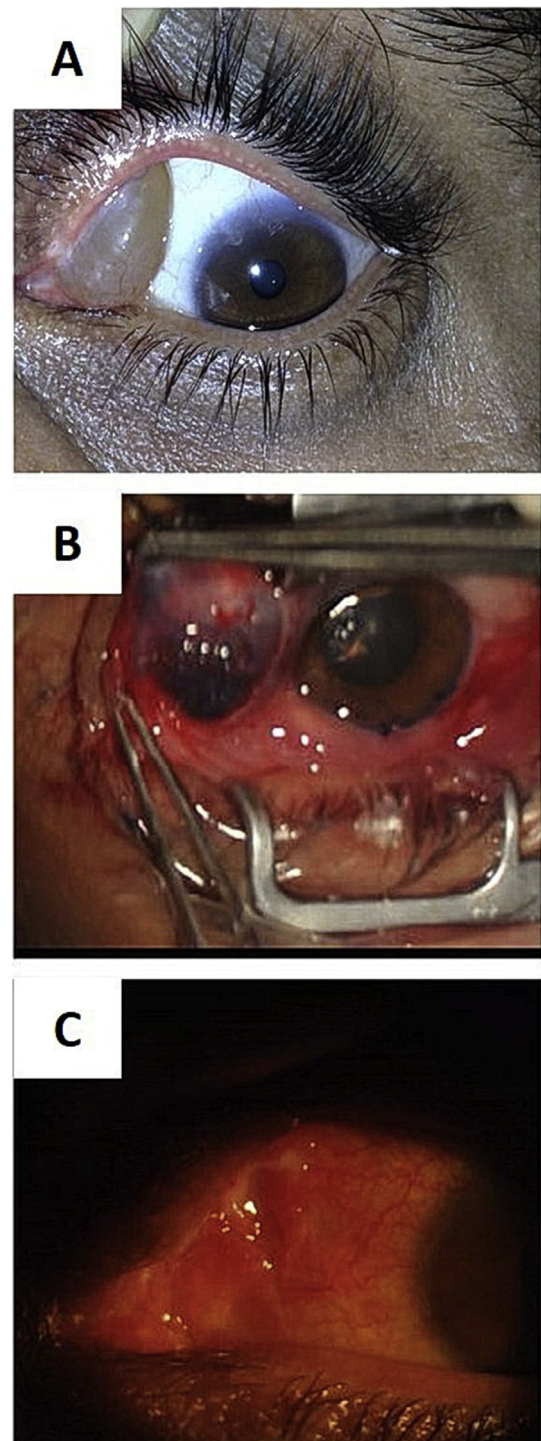


**Fig. 1.** Patient 1: Inferior temporal forniceal cyst of the left eye, post trachoma; Pre-operative photo showing the cyst (A), Intraoperative photo illustrating staining of the cyst wall after injection of trypan blue and stabilization of the cyst with methylcellulose (B), postoperative (C).

to old trachoma (Fig. 2). There were post trachomatous concretions and a localized fornix symblepharon. The cyst was cosmetically disfiguring.

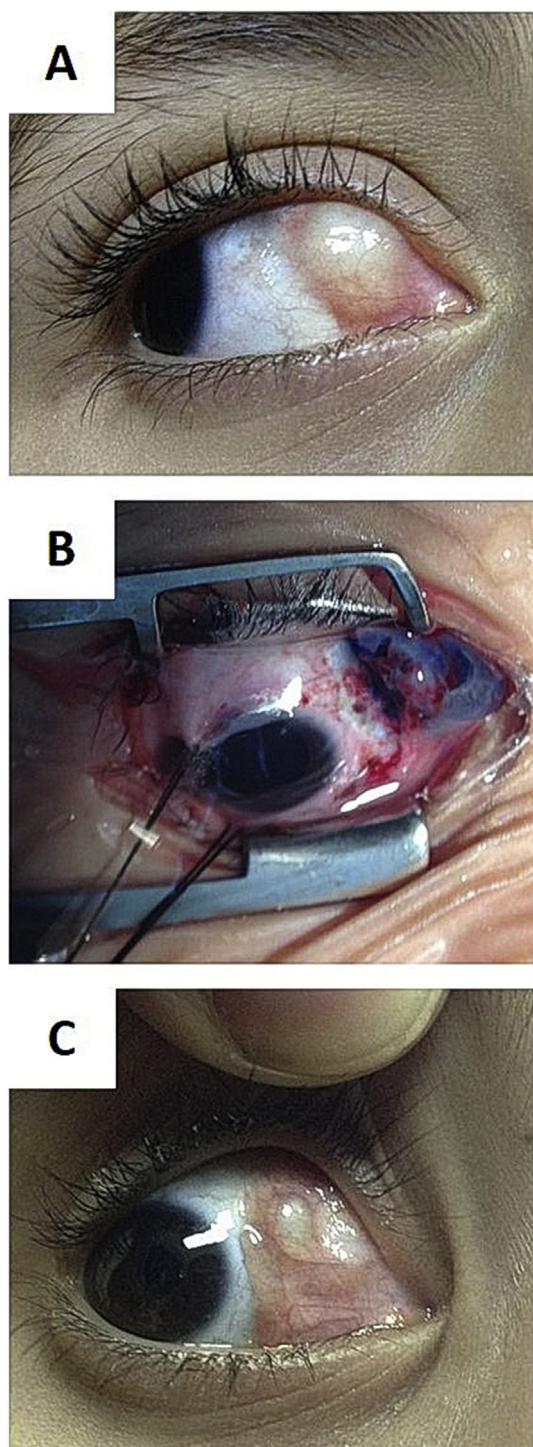
**Patient 3:** 3- year-old girl developed a conjunctival retention cyst shortly following medial rectus muscle resection for exotropia (Fig. 3).

Informed consent was obtained for all patients, who then underwent surgical excision using the following technique. The first two patients had surgery under subtenons anesthesia using lidocaine 2% injected into the lower quadrant opposite the site of the retention cyst, while the



**Fig. 2.** Patient 2: Upper nasal forniceal cyst of the left eye, post-trachoma; pre-operative (A), intraoperative (B), postoperative (C).

third girl had general anesthesia. Traction sutures were applied to improve exposure which varied according to the position of the cyst. A silk 6-0 traction suture in the same quadrant at the limbus to ensure good the exposure. Injection of trypan blue ophthalmic solution 0.6 mg/ml using insulin syringe (27-gauge needle) into the cyst, its amount guided by the size of the cyst, the least amount that results in staining was injected. The needle was kept in place and the syringe replaced by an ampoule containing methyl cellulose (2%). Then, incision of conjunctiva anterior to anterior limit of the cyst with subconjunctival blunt dissection, trying to identify the plane of cleavage between the



**Fig. 3.** Patient 3: Cyst post strabismus surgery; pre-operative (A), intraoperative (b), recurrence of the cyst following unsuccessful excision (C).

undersurface of the conjunctiva and the outer wall of the cyst. After complete dissection, an artery clamp was applied to the base of the cyst, then cut with scissors and cauterized to the edge. Finally, the conjunctival defect was closed by inverted interrupted sutures 8-0 Virgin silk. Postoperative topical steroid and antibiotic eye drops three times a day and ointment at bed time for three weeks were prescribed.

As the cyst wall was very thin, small leaking perforation at the site of initial puncture to the cyst was easily encountered. It happened in first two patients yet despite this, complete removal was achieved due to staining of the inside wall of the conjunctival cyst and viscosity of the

injected methylcellulose. In the third patient, staining by trypan blue spread along the muscle sheath prevented complete cyst removal resulting in recurrence that mandated another surgery to remove the cyst without staining. There was no cyst recurrence in the first two patients up to 2 years. No other complications like symblepharon, granuloma or infection were encountered in the three patients.

### 3. Discussion

Secondary conjunctival cysts are usually acquired due to conjunctival inflammation such as trachoma and vernal keratoconjunctivitis<sup>6,7</sup> or trauma. Cysts can result from conjunctival surgery<sup>8</sup> such as for pterygium<sup>9</sup>, strabismus, scleral buckling<sup>10</sup>, and pars plana vitrectomy.<sup>11</sup> Conjunctival inclusion cysts can be solitary as in the first and the third patient<sup>3</sup> or multiple as in the second patient who had a bipartite cyst).

Conjunctival cysts, particularly if large, can result in irritation, foreign body sensation, corneal astigmatism<sup>12</sup> or cosmetic blemish. In case of inflammation, the first step is to control inflammation and monitor cyst size. Once inflammation is controlled, cyst removal may be required. While the best curative treatment is removal of the cyst without leaving any remnants, treatment with Nd-YAG laser has been reported.<sup>13</sup>

The safety of vital stains and intraocular OVD suggest its safety in extraocular tissue such as conjunctiva. The use of trypan blue stain is not new in intraocular surgery. It has been used for staining of the epithelial lining capsule in cataract surgery<sup>14</sup> and vitreoretinal surgery.<sup>15</sup> Other vital stains such as Indocyanine green (ICG) have been used by Kobayashi et al. These authors used ICG alone in one patient with idiopathic conjunctival cyst<sup>4</sup>; and in 2005, they stained with Healon V combined with 0.06%TB for removal of a conjunctival cyst without recurrence. Use of stain helps visualize the cyst wall and achieve total removal, however, adding viscous material like sodium hyaluronate hinders its collapse during excision.<sup>3</sup> Chan et al. had used a similar method of combination of a stain (Indocyanine green) and viscosurgical device (1% sodium hyaluronate).<sup>16</sup>

Methyl cellulose is a viscodispersible and less expensive than Healon yet can function like Healon to fill the cyst and achieve the same function. However, we did not compare methyl cellulose to Healon. On the other hand, dispersive agents maintain less space than Healon. We found that staining can help in removing the conjunctival retention cysts even after rupture due to their thin walls. However, as seen in the third patient, staining can also make removal more difficult.

### Patient consent

Patient consent had been taken from the first two patients and from the mother of the third patient in an Arabic written form.

### Conflicts of interest

The following authors have no financial disclosures: GR and JD.

### Authorship

All authors attest that they meet the current ICMJE criteria for Authorship.

### Funding

No funding or grant support.

### Acknowledgments

None.

## References

1. Weisenthal RW, Afshari NA, Bouchard CS, et al. External disease and cornea. In: Cantor LB, Rapuano CJ, Cioffi GA, eds. *Basic and Clinical Science Course*. San Francisco: American Academy of Ophthalmology; 2016-2017:240.
2. Jakobiec FA, Bonanno PA, Sigelman J. Conjunctiva adnexal cysts and dermoids. *Arch Ophthalmol*. 1978;96:1404–1409.
3. Bowling B. Conjunctiva. *Bowling B. Kanski's Clinical Ophthalmology A Systematic Approach*. eighth ed. Butterworth Heinemann Elsevier/Saunders; 2016:165–166.
4. Kobayashi A, Saeki A, Nishimura A, et al. Visualization of conjunctival cyst by indocyanine green. *Am J Ophthalmol*. 2002;133:827–828.
5. Kobayashi A, Sugiyama K. Visualization of conjunctival cyst using Healon V and trypan blue. *Cornea*. 2005;24:759–760.
6. Won Lee S, Chan Lee S, Hyung Jin K. Conjunctival inclusion cysts in long standing chronic vernal keratoconjunctivitis. *Kor J Ophthalmol*. 2007;21:251–254.
7. Suzuki K, Okisaka S, Nakagami T. The contribution of inflammatory cell infiltration to conjunctiva inclusion cyst formation. *Nippon Gakkai Zasshi*. 2000;104:170–173.
8. Ho VT, Rao VM, Flanders AE. Postsurgical conjunctival epithelial cysts. *AJNR AM J Arch Ophthalmol*. 1994;15:1181–1183.
9. Kiratli H, Bilgic S, Gokoz O, et al. Conjunctival epithelial inclusion cyst arising from a pterygium. *Br J Ophthalmol*. 1996;80:769–770.
10. Johnson DW, Bartley GB, Garrity WM, et al. Massive epithelium lined inclusion cysts after scleral buckling. *Am J Ophthalmol*. 1992;113:439–442.
11. Bourcier T, Monin C, Baudrimont M, et al. Conjunctiva inclusion cyst following pars plana vitrectomy. *Arch Ophthalmol*. 2003;121:1067.
12. Soong HK, Okayawa RT, Iliff NT. Cornea astigmatism from conjunctiva cyst. *Am J Ophthalmol*. 1982;93:118–119.
13. De Bustros S, Michels RG. Treatment of acquired epithelial inclusion cyst of the conjunctiva using the YAG laser. *Am J Ophthalmol*. 1984;98:807–808.
14. Pandey SK, Werner L, Escobar-Gomez M, et al. Dye-enhanced cataract surgery. Part 1: anterior capsule staining for capsulorhexis in advanced/white cataract. *J Cataract Refract Surg*. 2000;26:1052–1059.
15. Li K, Wong D, Hiscott P, et al. Trypan blue staining of internal limiting membrane and epiretinal membrane during vitrectomy: visual results and histopathological findings. *Br J Ophthalmol*. 2003;87:216–219.
16. Chan RY, Pong JC, Yuen HK, et al. Use of sodium hyaluronate and indocyanine green for conjunctival cyst excision. *Jpn J Ophthalmol*. 2009 May;53:270–271.