



## Review

Pacinian corpuscle hyperplasia: A review of the literature <sup>☆</sup>

Victoria J. Stoj BS <sup>a,\*</sup>, Jonas A. Adalsteinsson MD <sup>b</sup>, Jun Lu MD <sup>b</sup>, Adrienne Berke MD <sup>b</sup>,  
Shari R. Lipner MD, PhD <sup>c</sup>

<sup>a</sup> University of Connecticut School of Medicine, Farmington, CT, United States

<sup>b</sup> Department of Dermatology, University of Connecticut Health Center, Farmington, CT, United States

<sup>c</sup> Department of Dermatology, Weill Cornell Medicine, New York, NY, United States



## ARTICLE INFO

## Article history:

Received 26 July 2020

Received in revised form 8 September 2020

Accepted 21 October 2020

## Keywords:

Pacinian corpuscle hyperplasia

Pacinian corpuscle neuroma

Pacinioma

Pacinian corpuscle hypertrophy

Heterotopic Pacinian corpuscles

Acute myeloid leukemia

Hand pain

Tumors of the hands and feet

Digit tumors

Painful cutaneous tumors

## ABSTRACT

**Objective:** Pacinian corpuscle hyperplasia typically presents as a tender nodule on the volar aspect of the palm or digit, often after trauma. Histologically, it presents as one to multiple normal-sized to enlarged Pacinian corpuscles in the deep dermis or subcutaneous adipose tissue. Given its rarity, its pathogenesis is debated and nomenclature is poorly defined. Herein, we present a case of Pacinian corpuscle hyperplasia and review the current literature.

**Methods:** A literature review was conducted using PubMed with the following search terms: Pacinian corpuscle hyperplasia, Pacinian corpuscle neuroma, Pacinioma, Pacinian corpuscle hypertrophy, and heterotopic Pacinian corpuscles. All case reports and case series were reviewed for histopathologic evidence of true Pacinian corpuscle hyperplasia. Cadaveric studies, cases without true Pacinian corpuscles, and noncutaneous cases were excluded from our analysis.

**Results:** Sixty patients with Pacinian corpuscle hyperplasia of the hands and feet (65 cases, some with >1 location) were reviewed. The mean age of presentation was 49.5 years, and women accounted for 60% of cases. Pain was the most commonly reported symptom (55 of 65 cases; 84.6%). Forty-five cases (69.2%) were localized to a digit, most commonly the second digit (17 of 65 cases; 26.2%), and 18 of 65 cases (27.6%) affected the palm, primarily the distal palm. Surgical excision was curative in 50 of 65 cases (76.9%).

**Conclusion:** Although relatively uncommon, Pacinian corpuscle hyperplasia should be considered in the differential diagnosis of a tender nodule on the digit or distal palm, particularly after trauma.

© 2020 Published by Elsevier Inc. on behalf of Women's Dermatologic Society. This is an open access article under the CC BY-NC-ND license (<http://creativecommons.org/licenses/by-nc-nd/4.0/>).

## Contents

|  |     |
|--|-----|
| Introduction . . . . .                 | 336 |
| Case . . . . .                         | 336 |
| Literature review/discussion . . . . . | 336 |
| Conclusion . . . . .                   | 340 |
| Conflicts of Interest . . . . .        | 340 |
| Funding . . . . .                      | 340 |
| Study Approval . . . . .               | 340 |
| References . . . . .                   | 340 |

<sup>☆</sup> Meeting presentation: This case was presented at the Women's Dermatologic Society Forum on February 1, 2020.

\* Corresponding author.

E-mail address: [vstoj@uchc.edu](mailto:vstoj@uchc.edu) (V.J. Stoj).

## Introduction

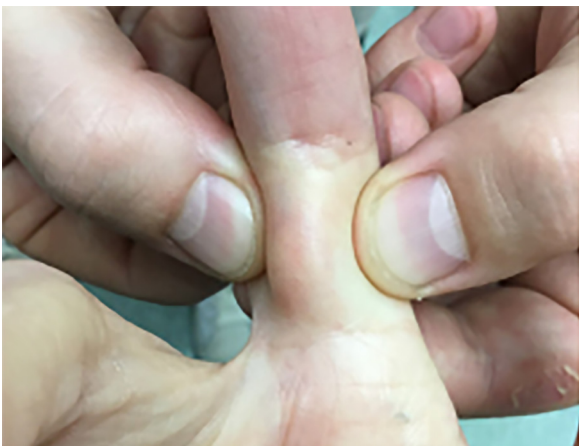Pacinian corpuscles, also called Vater-Pacini or lamellar corpuscles, are rapidly adapting mechanoreceptors that respond to changes in pressure and vibration (Gartner, 2017; Vijayaraghavan et al., 2008). Discovered by Vater in 1741 and first described histologically by Pacini in 1835 (Cauna and Mannan, 1958), Pacinian corpuscles are most often localized to the deep dermis (Quindlen et al., 2015). They are also found in the subcutaneous tissue, the heart, breasts, joints, and mesentery and loose connective tissue (Rhode and Jennings, 1975). Pathology involving Pacinian corpuscles is rare.

Terminology within the literature is inconsistent. Pacinian corpuscle hyperplasia describes a pathologic increase in the size (also called Pacinian hypertrophy) and/or density of mature Pacinian corpuscles. The term Pacinian corpuscle hyperplasia is used interchangeably with Pacinian neuroma and Pacinioma (Fassola et al., 2019; Imai et al., 2003). However, it is distinguished from Pacinian neurofibroma, which is composed of structures resembling Pacinian corpuscles at various stages of development with variable degrees of Schwann cell proliferation (Friedrich and Hugel, 2019). Given their rarity, Pacinian neuroma and Pacinian neurofibroma have been mistakenly conflated; therefore, Pacinian neurofibroma will not be reviewed herein. In this report, we describe a case of Pacinian corpuscle hyperplasia and review the literature to raise awareness for this condition.

## Case

A 69-year-old female patient with a medical history of acute myeloid leukemia (AML) and granulocytic sarcoma in remission presented with a 1-week history of a painful nodule on the right second finger. Her history of AML was complicated by multiple relapses, but she did not have neuropathy. Treatment included bone marrow transplant and chemotherapy. She had a granulocytic sarcoma on the right upper thigh that had regressed 1 year earlier after treatment with radiation and decitabine.

Physical examination was significant for a firm, mobile, 1-cm, flesh-colored subcutaneous nodule on the volar aspect of the right second finger proximal phalanx (Fig. 1). There were no epidermal changes observed on dermoscopy. A 5-mm punch biopsy was performed to rule out metastasized granulocytic sarcoma. During the biopsy, small grape-like clusters were noted in the subcutaneous tissue and were excised.



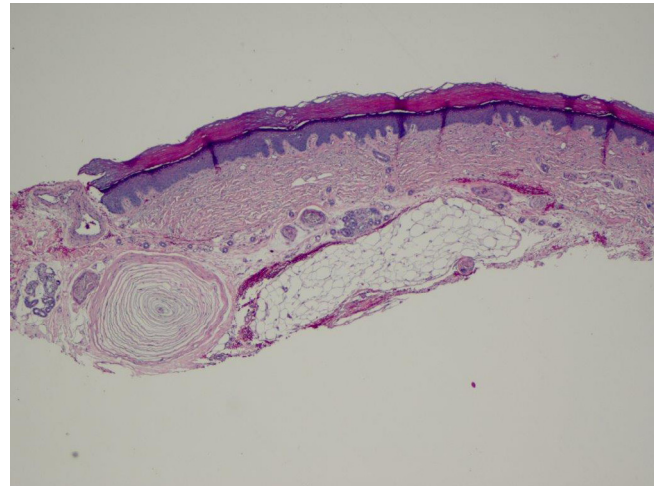
**Fig. 1.** Clinical examination showing painful, firm, mobile, flesh-colored, subcutaneous nodule, 1 cm in diameter, on the volar aspect of the proximal phalanx of the right second finger.

Histopathology with hematoxylin and eosin staining showed a single enlarged Pacinian corpuscle within the adipose tissue, surrounded by normal nerves and blood vessels in the interstitial stroma (Figs. 2 and 3). A diagnosis of Pacinian corpuscle hyperplasia was rendered.

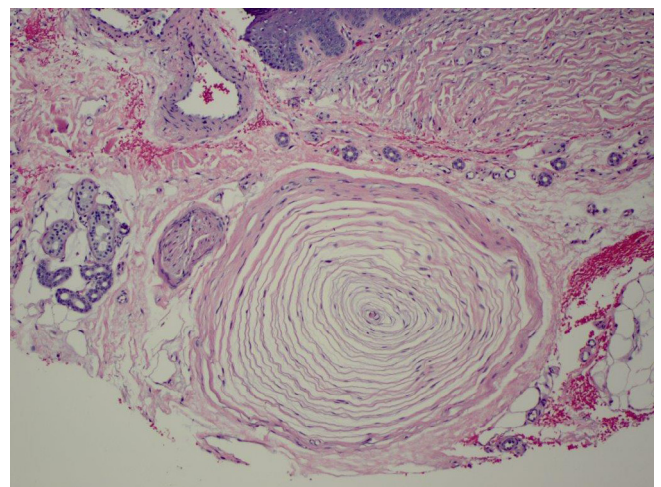
At follow-up 2 weeks later, the pain had subsided and there was no evidence of a residual nodule. In a telephone follow-up 2 months later, the patient reported no recurrence or associated pain. Six months later, she had an AML relapse, followed by subsequent cerebrovascular attacks, and died.

## Literature review/discussion

A normal Pacinian corpuscle measures 1 to 2 mm by 0.1 to 0.7 mm in the skin but up to 5 mm in other organs (Gartner, 2017; Reznik et al., 1998). It is composed of a central core containing an unmyelinated nerve terminal, surrounded by multiple concentric fibrous lamellae (normally 13–15 lamellae; Freitag et al., 1994) and an outer capsule, continuous with the perineurium (Cauna and Mannan, 1958; Imai et al., 2003). Macroscopically, it has been described as a cluster of rice-like, gray-white, ovoid bod-



**Fig. 2.** Histological appearance of Type A Pacinian corpuscle neuroma showing a single enlarged corpuscle with several adjacent normal corpuscles (hematoxylin and eosin staining with 4× magnification).



**Fig. 3.** Histological appearance of single enlarged Pacinian corpuscle (hematoxylin and eosin staining with 20× magnification).

**Table 1**  
History, physical examination, and outcomes of Pacinian corpuscle hyperplasia cases.

| Paper                            | Diagnosis                             | Age, y | Sex | Site                         | Reznik class | Jennings class      | Trauma       | Pain | Mass | Sensory change | Resolved with excision | Other association                                     |
|----------------------------------|---------------------------------------|--------|-----|------------------------------|--------------|---------------------|--------------|------|------|----------------|------------------------|---|
| Patterson, 1956                  | PC neuroma                            | 33     | F   | First digit bilaterally      | 2, 3         | B                   | No           | N    | Y    | N              | UNK                    | Computer operator                                     |
| Zweig and Burns, 1968            | Nerve compression by subepineural PCs | 42     | F   | Web space                    | 1            | A                   | Yes, local   | Y    | N    | N              | Y                      |   |
| Zweig and Burns, 1968            | Nerve compression by subepineural PCs | 54     | M   | Distal palm                  | 1            | A                   | Yes, local   | N    | Y    | Y              | Y                      |   |
| Hart et al., 1971                | Hyperplastic PCs                      | 66     | F   | Second digit                 | 3            | B, D                | Yes, distant | Y    | N    | N              | Y                      | Heat and cold sensitivity; pain radiating to shoulder |
| Sandzen and Baksic, 1974         | Pacinian hyperplasia                  | 59     | F   | Distal palm                  | 2            | B                   | Yes, local   | Y    | Y    | N              | Y                      |   |
| Sandzen and Baksic, 1974         | Pacinian hyperplasia                  | 21     | M   | Third digit                  | 2            | B                   | None         | Y    | Y    | N              | Y                      |   |
| Rhode and Jennings, 1975         | PC neuroma                            | 44     | M   | Distal palm in two locations | 1,2,3        | A, B, C             | Yes, local   | Y    | Y    | Y              | Y                      |   |
| Cameron, 1976                    | Hyperplasia of a PC                   | 17     | F   | First digit                  | 1            | A                   | None         | Y    | N    | Y              | UNK                    | Glomus tumor; required multiple surgeries             |
| Kojima et al., 1977              | PC hyperplasia                        | 50     | F   | Palm                         | 2            | B                   | Yes, local   | Y    | UNK  | UNK            | Y                      |   |
| Schuler and Adamson, 1978        | Pacinian neuroma                      | 47     | F   | Second digit                 | 2            | B                   | None         | Y    | Y    | N              | Y                      |   |
| Schuler and Adamson, 1978        | Pacinian neuroma                      | 55     | M   | Fifth digit                  | 2            | B                   | Yes, local   | Y    | N    | N              | Y                      |   |
| Tsuchida et al., 1979            | PC hyperplasia                        | 36     | F   | Palm                         | 2            | B                   | None         | Y    | UNK  | UNK            | Y                      |   |
| Gama and Mattosinho Franca, 1980 | Nerve compression by PCs              | 35     | F   | First digit                  | 2            | B                   | None         | Y    | Y    | N              | Y                      | Bone insufflation on roentgenogram                    |
| Gama and Mattosinho Franca, 1980 | Nerve compression by PCs              | 23     | F   | Distal palm                  | 3            | B, but enlarged PCs | Yes, local   | Y    | Y    | Y              | Y                      |   |
| Chavoïn et al., 1980             | Proliferation of PCs                  | 51     | M   | Third digit                  | 3            | D                   | Yes, local   | Y    | Y    | N              | Y                      | Required multiple surgeries                           |
| Greider and Flatt, 1982          | Pacinian hyperplasia                  | 69     | M   | Second digit                 | 3            | B, but enlarged PCs | Yes, local   | Y    | Y    | Y              | Y                      |   |
| Yasunaga et al., 1933            | PC hyperplasia                        | 72     | M   | First digit                  | 2            | B                   | None         | Y    | UNK  | UNK            | Y                      | Glomus tumor  |
| Friedman et al., 1984            | Subepineural PC                       | 18     | F   | Second digit                 | 1            | A                   | Yes, local   | Y    | N    | N              | Y                      |   |
| Lang-Stevenson, 1984             | PC hyperplasia and hypertrophy        | 60     | M   | Third and fourth digits      | 3            | UNK                 | None         | N    | N    | N              | N/A                    | Incidental finding                                    |
| Brynildsen, 1985                 | Subepineural PC                       | 33     | F   | Fourth digit                 | 1            | A                   | Yes, local   | N    | N    | Y              | Y                      |   |
| Umemoto et al., 1988             | Pacinian hypertrophy                  | 28     | F   | First digit                  | 3            | C                   | UNK          | Y    | Y    | N              | UNK                    | Progressive enlargement since birth                   |
| Umemoto et al., 1988             | Pacinian hypertrophy                  | 22     | M   | Second digit                 | 3            | C                   | UNK          | Y    | Y    | N              | UNK                    |   |
| Fletcher and Theaker, 1989       | Pacinian neuroma                      | 33     | F   | First digit                  | 2            | B                   | None         | Y    | Y    | N              | Y                      | Pain radiated to elbow                                |
| Fletcher and Theaker, 1989       | Pacinian neuroma                      | 44     | F   | Second digit                 | 2            | B                   | Yes, local   | Y    | Y    | N              | Y                      |   |
| Fletcher and Theaker, 1989       | Pacinian neuroma                      | 54     | M   | Web space                    | 2            | B                   | Yes, local   | Y    | Y    | N              | UNK                    | Pain radiated to elbow                                |
| Jones and Eadie, 1991            | PC hyperplasia                        | 55     | F   | Distal palm                  | 2            | B                   | Yes, distal  | Y    | Y    | Y              | Y                      |   |
| Fraitag et al., 1994             | PC hyperplasia                        | 70     | M   | Third digit                  | 3            | B but enlarged PCs  | None         | Y    | N    | Y              | UNK                    | Locksmith   |
| Kojima, 1992                     | PC hyperplasia                        | 41     | F   | Palm                         | 2            | A, B, D             | None         | Y    | UNK  | UNK            | Y                      | Erosive changes to bone on x-ray                      |
| McPherson and Meals, 1992        | PC neuroma                            | 59     | M   | Second digit                 | 2            | B                   | None         | Y    | Y    | N              | Y                      |   |
| Bas et al., 1993                 | Hyperplastic PC                       | 47     | F   | Fifth digit                  | 1            | A                   | None         | Y    | N    | N              | Y                      | Pain radiating to arm                                 |
| Calder et al., 1995              | Nerve compression by hyperplastic PCs | 68     | F   | Distal palm                  | 2            | B                   | Yes, local   | Y    | Y    | N              | Y                      |   |
| Reznik et al., 1998              | Hyperplasia and hypertrophy of PCs    | 63     | F   | Second digit                 | 3            | B but enlarged PCs  | None         | Y    | Y    | N              | Y                      | Trigger finger  |
| Reznik et al., 1998              | Hyperplasia and hypertrophy of PCs    | 44     | M   | Third digit                  | 3            | B but enlarged PCs  | Yes, local   | Y    | N    | N              | Y                      |   |
| Akyurek et al., 2000             | PC hyperplasia                        | 87     | F   | Distal palm                  | 2            | B                   | None         | N    | N    | N              | N/A                    | Dupuytren's contracture                               |
| Rinaldi et al., 2000             | Pacinian hyperplasia                  | 62     | M   | First digit                  | 2            | B                   | Yes, local   | Y    | Y    | N              | Y                      |   |
| Satge et al., 2001               | Pacinian hyperplasia                  | 66     | F   | Toe                          | 3            | C                   | None         | Y    | N    | N              | Y                      | Morton's tumor  |
| Kumar et al., 2003               | PC hyperplasia                        | 65     | F   | Toe                          | 3            | UNK                 | None         | Y    | N    | N              | Y                      |   |
| Kumar et al., 2003               | PC hyperplasia                        | 32     | M   | Fifth digit                  | 2            | B                   | None         | Y    | N    | N              | Y                      |   |

(continued on next page)

Table 1 (continued)

| Paper                          | Diagnosis                      | Age, y | Sex | Site                    | Reznik class | Jennings class      | Trauma     | Pain | Mass | Sensory change | Resolved with excision | Other association                           |
|--------------------------------|--------------------------------|--------|-----|-------------------------|--------------|---------------------|------------|------|------|----------------|------------------------|---|
| Vaes and De Smet, 2003         | Subepineural PC                | 33     | F   | Second digit            | 1            | A                   | None       | Y    | Y    | N              | Y                      |   |
| Kuruvila et al., 2003          | Pacinian neuroma               | 17     | F   | Web space               | 2, 3         | ND                  | Yes, local | Y    | Y    | N              | Y                      |   |
| Imai et al., 2003              | PC hyperplasia                 | 67     | M   | Fourth digit            | 2            | B                   | Yes, local | Y    | Y    | Y              | Y                      |   |
| Marini et al., 2004            | Pacinian neuroma               | UNK    | F   | Second digit            | UNK          | UNK                 | UNK        | UNK  | UNK  | UNK            | Y                      |   |
| Narayanamurthy et al., 2005    | PC neuroma                     | 88     | F   | First digit             | 3            | B but enlarged PCs  | None       | Y    | Y    | N              | Y                      |   |
| Kenmochi et al., 2006          | Pacinian neuroma               | 57     | F   | Third digit             | 1, 2         | A, B                | Yes, local | Y    | N    | N              | UNK                    |   |
| Yan et al., 2006               | PC hypertrophy                 | 24     | F   | Fourth digit            | 3            | UNK                 | none       | Y    | Y    | Y              | Y                      | NF1   |
| Vijayaraghavan et al., 2008    | PC hyperplasia                 | 45     | F   | Second digit            | 3            | B but enlarged PCs  | Yes, local | Y    | Y    | N              | Y                      |   |
| Yenidunya et al., 2009         | PC hypertrophy                 | 55     | F   | Second digit            | 1            | A                   | Yes, local | Y    | N    | N              | Y                      | 2A burn contracture                         |
| Yenidunya et al., 2009         | PC hyperplasia and hypertrophy | 72     | M   | Palm                    | 3            | UNK                 | None       | N    | Y    | N              | N/A                    | Dupuytren's contracture                     |
| Irie et al., 2011              | Heterotopic PC                 | 24     | M   | First digit             | 1            | A                   | None       | Y    | N    | N              | Y                      | 1 × 1.5 mm                                  |
| Irie et al., 2011              | Heterotopic PC                 | 31     | M   | Distal palm             | 2            | B                   | None       | Y    | N    | Y              | Y                      |   |
| Cho et al., 2012               | Pacinian neuroma               | 45     | F   | First digit             | 3            | UNK                 | Y          | Y    | Y    | N              | Y                      |   |
| Von Campe et al., 2012         | Pacinian neuroma               | 74     | M   | Distal palm             | 3            | UNK                 | None       | Y    | N    | N              | Y                      | Dupuytren's contracture                     |
| Zech et al., 2013              | Mystery case                   | 34     | M   | First digit             | 2            | B                   | Y, local   | Y    | N    | N              | UNK                    | Painter                                     |
| Garcia et al., 2015            | PC hyperplasia and hypertrophy | 50     | F   | Second digit            | 3            | B- but enlarged PCs | Yes, local | Y    | Y    | N              | UNK                    | Required multiple surgeries                 |
| Komforti and Cummings, 2015    | Pacinian hyperplasia           | 65     | F   | First digit             | 3            | C                   | Yes, local | Y    | N    | Y              | Y                      | Glomus tumor                                |
| Mahipathy et al., 2015         | Pacinian neuroma               | 34     | F   | Fifth digit             | 2            | B                   | None       | Y    | Y    | Y              | N                      | Congenital (pain resolved, not neuropraxia) |
| Garrido-Colmenero et al., 2016 | Pacinian neuroma               | 75     | M   | Second digit            | 3            | B- but enlarged PCs | None       | Y    | N    | N              | Y                      | Osteolysis on radiograph                    |
| Jimenez et al., 2017           | PC hyperplasia/neuroma         | 71     | M   | Second digit            | UNK          | B, D                | None       | Y    | Y    | N              | Y                      |   |
| Pickrell et al., 2019          | PC hyperplasia                 | 61     | M   | Second and third digits | 2, 3         | D                   | None       | Y    | N    | N              | Y                      | CREST syndrome; severe Raynaud's; pianist   |
| Friedrich and Hagel, 2019      | Vater-Pacini neuroma           | 54     | F   | Fifth digit             | 2            | B                   | None       | Y    | N    | N              | N                      | NF1   |
| Present case                   | PC Hyperplasia                 | 69     | F   | Second digit            | 2            | B                   | UNK        | Y    | Y    | N              | Y                      | History of acute myeloid leukemia           |

F, female; M, male; N/A, not applicable; N, no; NF1, neurofibromatosis type 1; PC, Pacinian corpuscle; UNK, unknown; Y, yes.

ies. In a cadaveric study of 10 subjects, there were a mean of 300 (192–424) Pacinian corpuscles in the hand, distributed near the digital nerves in the fingers (44%–60%), near the metacarpophalangeal joints (25%–48%), and in the thenar and hypothenar regions (8%–18%; Stark et al., 1998). Maximum normal density is 3 to 5 corpuscles per square centimeter (Lang-Stevenson, 1984; Yan et al., 2006).

Pacinian corpuscle hyperplasia was first described by Patterson in 1956 in a 33-year-old woman who presented with a bilateral enlargement of the distal pulp of her thumbs. On surgical exploration, a gross excess of Pacinian corpuscles was discovered and a diagnosis of Pacinian neuroma was made (Patterson, 1956). In 1975, Rhode and Jennings proposed an anatomical classification of these benign tumors into four subtypes: Type A (a single, enlarged, subepineural corpuscle); Type B (a grape-like cluster of normal-sized Pacinian corpuscles attached to the digital nerve by a fine filament), Type C (a series of slightly enlarged corpuscles arranged in tandem beneath the epineurium, appearing as a branch to the nerve), and Type D (hyperplastic Pacinian corpuscles arranged along the entire length of a digital nerve, each single or paired corpuscle attached to the nerve by a fine nerve fiber; Rhode and Jennings, 1975).

The Rhode and Jennings Pacinian corpuscle hyperplasia classification was both described as sensible and criticized as difficult to apply without a detailed account of the surgery (Fletcher and Theaker, 1989). In 1998, Reznik et al. suggested that Types C and D could be grouped together, simplifying the classification system to three subtypes: Type 1 (a single, enlarged Pacinian corpuscle), Type 2 (a cluster of normal-sized Pacinian corpuscles), and Type 3 (a cluster of enlarged Pacinian corpuscles; Reznik et al., 1998). Both classification systems are currently used to describe Pacinian corpuscle hyperplasia.

The differential diagnosis for a painful cutaneous tumor is broad and includes calcinosis cutis, leiomyoma cutis, eccrine spiradenoma, neuroma, Morton's neuroma, dermatofibroma, tufted angioma, angioliipoma, neurilemmoma, granular cell tumor, glomus tumor, angioendotheliomatosis, metastases, hidradenoma, osteoma cutis, fibromyoxoma, blue rubber bleb nevus, leiomyosarcoma, eccrine angiomatous hamartoma, Dercum's disease, piezogenic papule, thrombus, scar, and keloid (Bhat et al., 2019; Cohen et al., 2019). All these pathologies have been reported in the hands and feet, but only glomus tumor, fibromyoxoma, eccrine angiomatous hamartoma, piezogenic papules, and Morton's neuroma are commonly localized to the hands or feet. Pacinian corpuscle hyperplasia can be distinguished clinically from some of these entities, with its presentation as an isolated flesh-colored nodule on the volar surface of the distal palm or digit; biopsy with histopathology is necessary for confirmation. Given our patient's history of AML and granulocytic sarcoma, metastasis was also considered.

In addition to our case, 60 patients with Pacinian corpuscle hyperplasia of the hands and feet have been reported (Table 1). Cadaveric studies and cases without true Pacinian corpuscles were excluded from our analysis. The mean age of patients at the time of presentation was 49.5 years (range, 17–88 years) with a female predominance (37 of 61 patients; 60.7%; Table 2). Four patients (Lang-Stevenson, 1984; Patterson, 1956; Pickrell et al., 2019; Rhode and Jennings, 1975) presented with Pacinian corpuscle hyperplasia in >1 location (n = 65 cases). Similar to our case, the majority presented with a tender digital nodule. Forty-five cases (69.2%) were localized to a digit, most commonly the second digit (17 of 65 cases; 26.2%), and 18 of 65 cases (27.6%) affected the palm, primarily the distal palm (Fig. 4).

Pain was the most common symptom, reported for 55 of 65 nodules (84.6%). Tenderness was described in 17 cases; other descriptors included throbbing, severe, acute, and burning. Thirty-four patients (52.3%) had a mass or swelling, and 13

**Table 2**  
Summary of demographics of Pacinian corpuscle hyperplasia cases.

| Demographic characteristics                             | n (%)                    |           |
|---|--------------------------|-----------|
| Patients, N = 61  | Mean age, y              | 49.5      |
|   | Male                     | 24 (39.3) |
|   | Female                   | 37 (60.7) |
| Anatomic location, N = 65                               | Palm                     | 4 (6.2)   |
|   | Distal palm/web space    | 14 (21.5) |
|   | First digit              | 13 (20.0) |
|   | Second digit             | 17 (26.2) |
|   | Third digit              | 7 (10.8)  |
|   | Fourth digit             | 3 (4.6)   |
|   | Fifth digit              | 5 (7.7)   |
|   | Toes                     | 2 (3.1)   |
|   | Two locations*           | 4 (6.2)   |
| Patient history and examination characteristics, N = 65 | Pain                     | 55 (84.6) |
|   | Prior trauma             | 28 (43.1) |
|   | Mass                     | 34 (52.3) |
|   | Sensory change           | 13 (20.0) |
| Reznik subtype, N = 65                                  | 1                        | 9 (13.8)  |
|   | 2                        | 24 (36.9) |
|   | 3                        | 22 (33.8) |
|   | Multiple†                | 8 (12.3)  |
|   | Jennings subtype, N = 65 | A         |
| B   |                          | 34 (52.3) |
| C   |                          | 4 (6.2)   |
| D   |                          | 3 (4.6)   |
| Multiple‡   |                          | 6 (9.2)   |
| Surgical intervention, N = 65                           | Resolved with excision   | 50 (76.9) |
|   | Required >1 surgeries    | 3 (4.6)   |

\* Cases with 2 locations included index and middle finger, ring and middle finger, bilateral thumbs, and 2 areas in the distal palm.

† Cases with multiple Reznik subtypes included pairings of 1,2; two 1, 2, 3; and five 2,3.

‡ Cases with multiple Jennings subtypes included pairings of a, b; a, b, c; a, b, d, and two b, d.

(20.0%) presented with sensory changes. The most common Reznik subtypes were Type 2 (36.9%) and Type 3 (33.8%). The most frequent Jennings subtype was B (52.3%), consistent with an earlier review (Fassola et al., 2019). Nine of the 33 cases designated as Jennings subtype B were enlarged rather than normal sized, as traditionally stated. Two cases could not be discerned from the description provided as a specific Reznik class, and 9 were not discernable for Jennings classification. Additionally, one case (Irie et al., 2011) presented as a normal-sized subepineural Pacinian corpuscle that caused pain; it was included as Type 1/A despite technically belonging to neither class.

The pathogenesis of Pacinian corpuscle hyperplasia remains to be elucidated, but prior trauma has been implicated as a potential cause. Injury has been hypothesized to disrupt the blood flow of the arteriovenous anastomoses located in close proximity to Pacinian corpuscles, resulting in the formation of new corpuscles (Cauna and Mannan, 1958; Imai et al., 2003; Jimenez et al., 2017). Our findings of a predilection for the right first three digits in close proximity to the digital nerves and metacarpophalangeal joints (Fig. 4) supports the theory of repetitive trauma leading to hyperplasia of preexisting Pacinian corpuscles. In our review, 43.1% of cases were associated with prior trauma. Work-related exposure to repeated microtraumas has been proposed as a potential risk factor in the case of a locksmith (Fraitag et al., 1994); this reasoning is applicable to cases reviewed of a painter (Zech et al., 2013), computer operator (Patterson, 1956), a woman who experienced repetitive needling trauma from her work with fabrics (Cho et al., 2012), and a pianist (Pickrell et al., 2019). Other associated findings were glomus tumor (4 cases; Greider and Flatt, 1982; Kojima, 1992; Komforti and Cummings, 2015), Dupuytren's con-

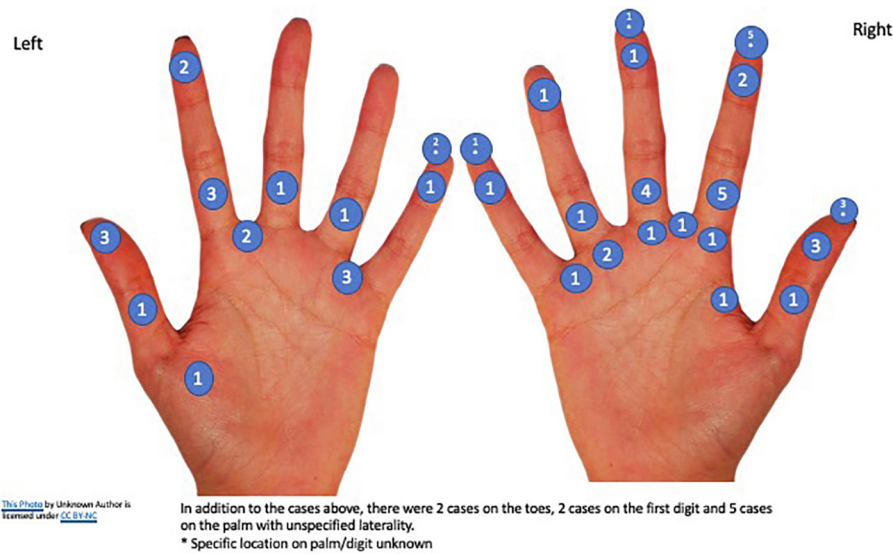


Fig. 4. Distribution of Pacinian corpuscle hyperplasia in the hands and feet.

tracture (3 cases; Akyurek et al., 2000; Von Campe et al., 2012; Yenidunya et al., 2009), and neurofibromatosis (2 cases; Friedrich and Hagel, 2019; Yan et al., 2006). Pacinian corpuscles in the fascia of patients with Dupuytren's disease are larger and stain more intensely for nerve growth factor compared with Pacinian corpuscles in the hands of control patients (Ehrmantant et al., 2004). Burn contracture (Yenidunya et al., 2009) and Raynaud's (Pickrell et al., 2019) were described in one case each. To date, no cases have been associated with hematologic malignancy or immunosuppression as seen in our case.

Surgery is the mainstay of treatment for Pacinian corpuscle hyperplasia. Surgical excision resulted in resolution of symptoms in 50 cases (76.9%). However, three cases (Chavoïn et al., 1980; Garcia et al., 2015; Kojima, 1992) required multiple surgeries to control symptoms due to hyperplastic Pacinian corpuscles found in >1 location along the nerve. In only one case (Mahipathy et al., 2015), the patient reported ongoing symptoms after excision in which pain resolved but neuropraxia persisted.

## Conclusion

The case presented is a classic example of the clinical and histological presentation of Pacinian corpuscle hyperplasia. Although rare, it should be considered in the differential diagnosis of a tender nodule on the digit or distal palm, particularly after trauma. This case, along with previous reports, helps clarify diagnostic terminology and subtype classifications.

## Conflicts of Interest

None.

## Funding

None.

## Study Approval

The author(s) confirm that any aspect of the work covered in this manuscript that has involved human patients has been conducted with the ethical approval of all relevant bodies.

## References

- Akyurek N, Ataoglu O, Cenetoglu S, Ozmen S, Cavusoglu T, Yavuzer R. Pacinian corpuscle hyperplasia coexisting with Dupuytren's contracture. *Ann Plast Surg* 2000;45:220–2.
- Bas L, Oztek I, Numanoglu A. Subepineural hyperplastic Pacinian corpuscle: An unusual cause of digital pain. *Plast Reconstr Surg* 1993;92:151–3.
- Bhat MR, George AA, Jayaraman J. Painful tumors of the skin - from ENGLAND to LEND AN EGG to BLEND TAN EGG. *Indian J Dermatol Venereol Leprol* 2019;85(2):231–4.
- Brynilsden PJ. Painful digital subepineural Pacinian corpuscles (letter). *Plast Reconstr Surg* 1985;75:929–30.
- Calder JS, Holten I, Terenghi G, Smith RW. Digital nerve compression by hyperplastic Pacinian corpuscles. A case report and immunohistochemical study. *J Hand Surg* 1995;20B:218–21.
- Cameron S. Two rare cases of nerve entrapment. *J Bone Joint Surg* 1976;58B:266.
- Cauna N, Mannan G. The structure of human digital Pacinian corpuscles (corpuscular lamellae) and its functional significance. *J Anat* 1958;92:1–20.
- Chavoïn JP, Dunoux R, Mansat M, Costagliola M, Souquet R. Prolifération tumorale douloureuse des corpuscles de Pacini au niveau de la main. *Ann Chir* 1980;34:738–42.
- Cho HH, Hong JS, Park SY, Park HS, Cho S, Lee JH. Tender papule rising on the digit: Pacinian neuroma should be considered in differential diagnosis. *Int J Med Sci* 2012;9:83–5.
- Cohen PR, Erickson CP, Calame A. Painful tumors of the skin: "CALM HOG FLED PEN AND GETS BACK". *Clin Cosmet Invest Dermatol* 2019;12:23.
- Ehrmantant WR, Graham WP, Towfighi J, et al. A histological and anatomical profile of Pacinian corpuscles from Dupuytren's contracture and the expression of nerve growth factor receptor. *Plast Reconstr Surg* 2004;114(3):721–7.
- Fassola I, Wenzke L, Ertel W, Krasnici S. Pacinian neuromas and neurofibromas of the hands and fingers: A systematic review. *J Hand Surg Eur* 2019;44(9):925–31.
- Fletcher CM, Theaker JM. Digital Pacinian neuroma: A distinctive hyperplastic lesion. *Histopathology* 1989;15(3):249–56.
- Fraitag S, Gherardi R, Wechsler J. Hyperplastic Pacinian corpuscles: An uncommonly encountered lesion of the hand. *J Cutan Pathol* 1994;21:457–60.
- Friedman HI, Nichter LS, Morgan RF, Edgerton MT. Subepineural Pacinian corpuscle: A cause of digital pain. *Plast Reconstr Surg* 1984;74:699–703.
- Friedrich RE, Hagel C. Painful Vater-Pacini neuroma of the digit in neurofibromatosis type 1. *GMS Interdiscip Plast Reconstr Surg DGPW* 2019;8. Doc03.
- Gama C, Mattosinho Franca LC. Nerve compression by Pacinian corpuscles. *J Hand Surg* 1980;5:207–10.
- Garcia FC, Acosta DR, Diaz Gonzalez JM, Lima MS. Hyperplasia and hypertrophy of Pacinian corpuscles: A case report. *Am J Dermatopathol* 2015;37:100–1.
- Garrido-Colmenero C, Aneiros-Fernandez J, Blasco-Morente G, Perez-Lopez I, Tercedor-Sanchez J. Severe pain in the fingertip. *Int J Dermatol* 2016;55:709–10.
- Gartner L. *Textbook of histology*. 4th ed. Philadelphia, PA: Elsevier; 2017.
- Greider JL, Flatt AE. Glomus tumor associated with Pacinian hyperplasia-case report. *J Hand Surg Am* 1982;7(2):113–7.
- Hart WR, Thompson NW, Hildreth DH, Abell MR. Hyperplastic Pacinian corpuscles: A cause of digital pain. *Surgery* 1971;70:730–5.
- Imai S, Kikuchi K, Matsusue Y. Digital Pacinian corpuscle hyperplasia. *J Am Soc Surg Hand* 2003;3(3):175–80.

- Irie H, Kato T, Yakushiji T, et al. Painful heterotopic Pacinian corpuscle in the hand: A report of three cases. *Hand Surg* 2011;16(01):81–5.
- Jimenez I, Marcos-Garcia A, Muratore G, Medina J. Pacinian corpuscles neuroma. An exceptional cause of pain in the hand. *J Hand Surg Asian Pac* 2017;22:229–31.
- Jones NF, Eadie P. Pacinian corpuscle hyperplasia in the hand. *J Hand Surg* 1991;16A:865–9.
- Kenmochi A, Satoh T, Fukuyama K, Yokozeki H. Pacinian neuroma. *J Eur Acad Dermatol Venereol* 2006;20:1384–5.
- Kojima T. Pacinian corpuscle hyperplasia in the hand. *J Hand Surg* 1992;17(5):976.
- Kojima T, Kasai S, Aizawa S, Kirino Y. A Case of hyperplasia of pacinian corpuscles. *Jpn J Plas Reconstr Surg* 1977;20:8–12.
- Komforti M, Cummings TJ. An extraordinary association of glomus tumor and Pacinian hyperplasia in the hand of a female patient. *Am J Dermatopathol* 2015;37:719–20.
- Kumar A, Darby AJ, Kelly CP. Pacinian corpuscles hyperplasia—an uncommon cause of digital pain. *Acta Orthop Belg* 2003;69(1):74–6.
- Kuruwila S, Devi KL, Malhotra G, Thomas C. Pacinian neuroma. *Neurosciences* 2003;8(1):53–4.
- Lang-Stevenson AI. Induction of hyperplasia and hypertrophy of Pacinian corpuscles. *Br Med J (Clin Res Ed)* 1984;288. 972e3.
- Mahipathy SR, Durairaj AR, Parthasarathy J. Pacinian neuroma presenting as congenital macrodactyly: A rare case report. *J Clin Diagn Res* 2015;9:22–3.
- Marini MA, Rossi GC, Magariños G. Neuroma Paciniano. *Arch Argent Dermatol* 2004;201–5.
- McPherson SA, Meals RA. Digital Pacinian corpuscle neuroma eroding bone: A case report. *J Hand Surg* 1992;17A:476–8.
- Narayanamurthy VB, Winston AT, Gupta A. A rare case of Pacinian corpuscle neuroma. *Can J Plast Surg* 2005;13(1):43–5.
- Patterson TJ. Pacinian corpuscle neuroma of the thumb pulp. *Br J Plast Surg* 1956;9:230–1.
- Pickrell BB, Talbot SG, Costigan DC, Sampson C. Pacinian hyperplasia presenting with Raynaud's phenomenon. *Case Rep Plast Surg Hand Surg* 2019;6(1):148–52.
- Quindlen JC, Lai VK, Barocas VH. Multiscale mechanical model of the Pacinian corpuscle shows depth and anisotropy contribute to the receptor's characteristic response to indentation. *PLoS Comput Biol* 2015;11(9) e1004370.
- Reznik M, Thiry A, Fridman V. Painful hyperplasia and hypertrophy of Pacinian corpuscles in the hand: Report of two cases with immunohistochemical and ultrastructural studies, and a review of the literature. *Am J Dermatopathol* 1998;20(2):203–7.
- Rhode CM, Jennings Jr WD. Pacinian corpuscle neuroma of digital nerves. *South Med J* 1975;68(1):86–9.
- Rinaldi P, Andreini A, Ercolani C, Bernardi L, Bernardi S. Digital Pacinian hyperplasia. Report of a case associated with foreign body reaction. *Pathologica* 2000;92:36–40.
- Sandzen SC, Baksic RW. Pacinian hyperplasia. *Hand* 1974;6:27–34.
- Satge D, Nabhan J, Nandiegou Y, Hermann B, Goburdhun J, Labrousse F. A Pacinian hyperplasia of the foot. *Foot Ankle Int* 2001;22:342–4.
- Schuler PA, Adamson JE. Pacinian neuroma, an unusual cause of finger pain. *Plast Reconstr Surg* 1978;62:576–9.
- Stark B, Carlstedt T, Hallin RG, Risling M. Distribution of human Pacinian corpuscles in the hand: A cadaver study. *J Hand Surg Br* 1998;23(3):370–2.
- Tsuchida Y, Endo Y, Kojima T, Marumo E, Kirino Y. Painful tumor on the hand. *Orthop Surg* 1979;1694–6.
- Umemoto K, Yanagihara H, Kurimoto T, Hashimoto S. Two cases of Pacinian hypertrophy. *Skin Res* 1988;30:61–5.
- Vaes F, De Smet L. A rare cause of digital pain: The subepineural Pacinian corpuscle. *Eur J Plast Surg* 2003;26(7):370–2.
- Vijayaraghavan R, Chandrashekar R, Belagavi CS, Murthy NB. Painful digital Pacinian corpuscle hyperplasia following dog bite: A case report. *Int J Surg* 2008;6(6): e42–5.
- Von Campe A, Mende K, Omaren H, Meuli-Simmen C. Painful nodules and cords in Dupuytren disease. *J Hand Surg Am* 2012;37:1313–8.
- Yan S, Horangic NJ, Harris BT. Hypertrophy of Pacinian corpuscles in a young patient with neurofibromatosis. *Am J Dermatopathol* 2006;28:202–4.
- Yasunaga H, Abe M, Ikeda K, Shigematsu T, Onomura T, Ogihara K. Pacinian hyperplasia; a report of two cases. *Orthop Surg* 1933;34:1835–8.
- Yenidunya MO, Yenidunya S, Seven E. Pacinian hypertrophy in a type 2A hand burn contracture and Pacinian hypertrophy and hyperplasia in a Dupuytren's contracture. *Burns* 2009;35(3):446–50.
- Zech L, Nolan N, Norton SA. Blue macule on the volar surface of the left thumb—Quiz case. *JAMA Dermatol* 2013;149(1):97.
- Zweig J, Burns H. Compression of digital nerves by Pacinian corpuscles. *J Bone Joint Surg* 1968;50A:999–1001.