

Robotic-Assisted Transthoracic Esophageal Diverticulectomy

Bengi Balci, MD, Gizem Kilinc, MD, Bülent Calik, MD, Gökhan Akbulut, MD

ABSTRACT

Introduction: Esophageal diverticulum is a rare entity with symptoms that include dysphagia, halitosis, chest pain, and regurgitation. Indications for surgery include the presence of any of these symptoms and a diverticulum larger than 3 cm because of the increased risk of malignancy and aspiration. Treatment is open or minimally invasive surgery performed from the transhiatal or transthoracic approach.

Case Description: Three patients were investigated by esophagogastroduodenoscopy, esophageal manometry, and computed tomography and were given the diagnosis of epiphrenic diverticulum of the esophagus.

Management and Outcome: The patients underwent robot-assisted surgery by a transthoracic approach for esophageal diverticulectomy. The mean operative time was 211 min, with no significant blood loss or intraoperative complications.

Discussion: This report of robot-assisted surgery for esophageal diverticulectomy from a transthoracic approach adds to the literature regarding surgical treatment of epiphrenic esophageal diverticulum. It is a feasible method that can be used in selected patients with esophageal diverticulum.

Key Words: Esophageal diverticulum, Robot-assisted surgery, Transthoracic approach.

INTRODUCTION

Esophageal diverticulum is a rare entity that is classified according to its location, as proximal, midesophageal, or epiphrenic. Midesophageal diverticulum is usually seen in patients with chronic pulmonary diseases, whereas epiphrenic diverticulum is a result of increased intraluminal pressure related to esophageal motility disorders.^{1,2}

Although the true incidence is unknown, epiphrenic diverticulum is seen in approximately ~10 to 20% of patients.^{3,4} Those affected usually present with dysphagia, halitosis, regurgitation, heartburn, nausea, vomiting, and chest pain.^{5,6} Surgery is the choice of treatment in patients who have esophageal diverticulum with any of these symptoms. It is also recommended in asymptomatic patients with esophageal diverticulum larger than 3 cm, because of the increased risk of malignancy and aspiration.⁷

Preoperative diagnostic tests and imaging techniques are esophagogastroduodenoscopy (EDG), barium esophagram, esophageal manometry, and computed tomographic (CT) scans to rule out malignancy.⁸

The choice of methods for treatment are the transhiatal versus transthoracic approach and open versus minimally invasive surgery. With the latest advancements in technology, minimally invasive methods, such as video-assisted thoracoscopic surgery (VATS) or laparoscopic or robot-assisted techniques, have been used as the treatment of choice.^{8–10}

We present 3 cases of esophageal diverticulum treated surgically with robot-assisted surgery from the transthoracic approach.

OPERATIVE TECHNIQUE

Surgery was performed with the patient under general anesthesia with double-lumen orotracheal intubation. The patient was placed in the left lateral decubitus position and the right lung was exsufflated by the anesthesiologist. Four trocar sites were determined based on patient and localization of diverticulum (**Figure 1**). After docking of the robotic arms, pleural adhesions were dissected by electrocauterization with a hook on the right robotic arm

Department of General Surgery, Tepecik Education and Research Hospital, Izmir, Turkey (all authors).

Disclosure: none reported.

Address correspondence to: Bengi Balci, MD, Department of General Surgery, Tepecik Education and Research Hospital, Izmir, Turkey. Telephone: +905054508478, Fax: +902324330756, E-mail: bengibalci@gmail.com

DOI: 10.4293/JSLS.2018.00002

© 2018 by JSLS, *Journal of the Society of Laparoendoscopic Surgeons*. Published by the Society of Laparoendoscopic Surgeons, Inc.

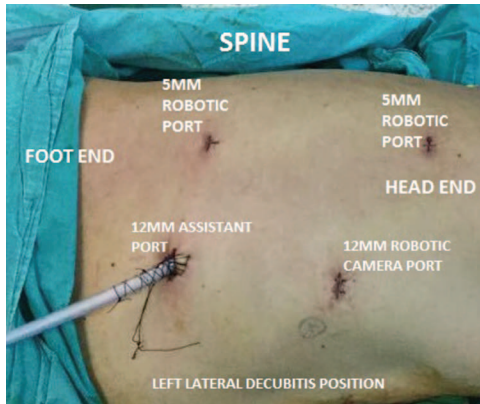


Figure 1. Operative position and ports for robotic transthoracic esophageal diverticulectomy.

and bipolar forceps on the left robotic arm. The esophagus was mobilized, and the diverticulum was identified. The diverticulum was dissected from the pleura and adherent muscle fibers down to the neck of the diverticulum. After the neck was fully exposed, a 48- to 54-French boogie was inserted into the esophagus to avoid narrowing the lumen. Through the assistant port, an Endo-GIA stapler (60 mm length, 3.8 mm staple size; Medtronic, Minneapolis, Minnesota, USA) was inserted to divide the neck of the diverticulum. During this step, meticulous care was taken not to perforate the diverticulum. The diverticulum was removed in an Endo Bag (Medtronic). The staple line was examined for any leakage with methylene blue and no leakage was observed. A thoracic tube was placed into the right hemithorax.

CASE PRESENTATION

Case 1

A 62-year-old man presented with halitosis, dysphagia, and regurgitation. The patient's physical examination and laboratory findings were unremarkable. He was evaluated with EDG, and an epiphrenic diverticulum was observed, localized on the right side of the esophagus 5 cm from the gastroesophageal junction (**Figure 2**). Esophageal manometry did not reveal any motility disorder.

Management and Outcome

The patient underwent robot-assisted transthoracic surgery, as mentioned above in detail. The operative time was 170 min. There were no intraoperative complications nor was there a need for blood transfusion. The patient was started on liquids on postoperative day 2 after radio-

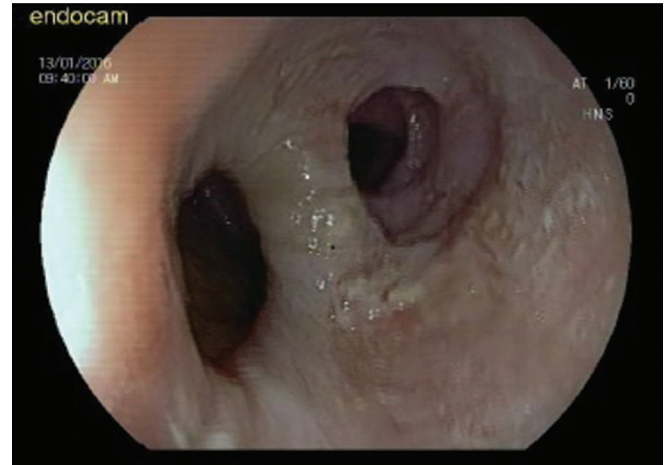


Figure 2. Esophageal 2-cm epiphrenic diverticulum.

logic examination with Gastrografin (Bayer Pharma AG, Leverkusen, Germany) contrast. No leak was found, and the patient was discharged on postoperative day 3.

Specimen pathology revealed a 2 × 1.5-cm esophageal diverticulum. The mucosa of the diverticulum was covered with hyperplastic squamous epithelium, and the wall consisted of the muscle layer.

Case 2

A 65-year-old man, complaining of dysphagia and chest pain, was investigated with EGD, which revealed a large epiphrenic diverticulum on the right side of the esophagus. The patient's physical examination and laboratory findings were unremarkable. A CT scan, which was performed for the evaluation of the patient's underlying pulmonary pathology, also revealed an 8 × 7-cm esophageal diverticulum (**Figure 3**). Esophageal manometry was unsuccessful because of repeated insertion of the probe into the diverticulum.

Management and Outcome

The patient underwent robot-assisted transthoracic surgery for the diverticulum. In addition to the diverticulectomy, wedge biopsies were obtained from the right lung. The operative time was 165 min, and no intraoperative complications occurred.

On postoperative day 2, liquids were started after no leak was found in the radiological examination with Gastrografin. On postoperative day 4, the patient had fever of 38°C (100.4°F). The thoracic tube was still oscillating and draining serous and hemorrhagic fluids with no evidence of leakage. On postoperative day 5, because of the pa-

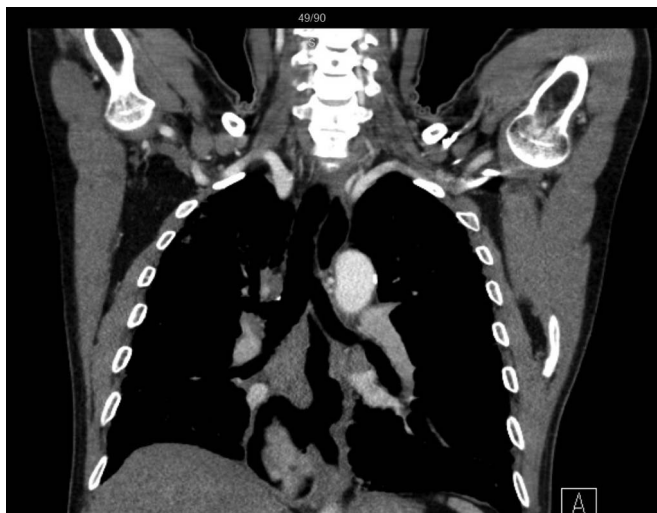


Figure 3. A large 8 × 7-cm epiphrenic diverticulum.

tient’s ongoing fever and respiratory distress, a CT scan was performed for the suspicion of anastomotic leakage, and pleural effusion was observed in the right lung, with free fluid and air in the operative area (**Figure 4**).

The patient’s oral intake was stopped, total parenteral nutrition was started, and the patient was transferred to the intensive care unit. A thoracic tube was placed on the basis of CT scan findings, to drain the purulent fluid. Broad-spectrum antibiotics were started with a presumptive diagnosis of anastomotic leakage and mediastinitis. The patient was intubated upon deterioration of oxygen saturation levels and hemodynamic status. On postoper-

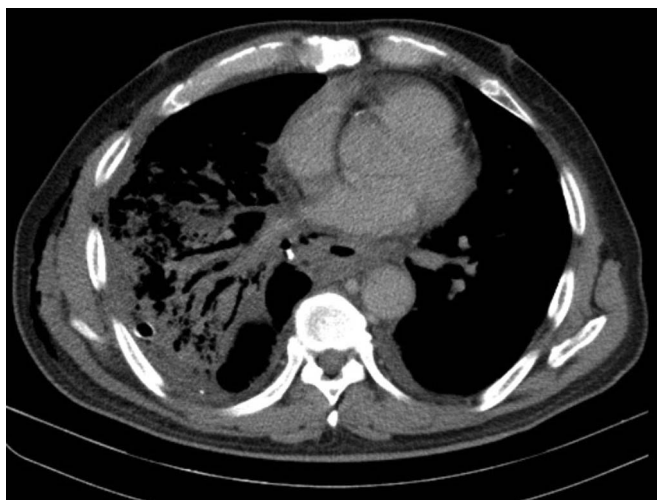


Figure 4. Anastomotic leak from stapler line after robotic diverticulectomy.

ative day 10, a covered stent, measuring 17 cm and 24 mm, was placed in the esophagus via EDG.

The pleural space and the leakage area were irrigated meticulously and drained daily via the thoracic tube. Although, the purulent fluid drainage decreased over time, the hemodynamic status of the patient remained unstable, requiring positive inotropic support. Airway pressures continued to be high with mechanic ventilation. Acute respiratory distress syndrome and decreased daily urine output led to multiorgan dysfunction. The patient was started on hemodialysis filtration. His condition continued to deteriorate, and he died on postoperative day 19.

Case 3

A 75-year-old woman presented with dysphagia and regurgitation. EGD revealed a 4 × 5-cm esophageal diverticulum 8 cm proximal to the gastroesophageal junction. Esophageal manometry did not reveal any motility disorder. The patient had a history of chronic obstructive pulmonary disease treated with inhalers. On physical examination of the respiratory system, diffuse expiratory rhonchi were heard during auscultation. The patients’ laboratory findings were unremarkable. A CT scan of the thorax demonstrated emphysematous changes in the lung parenchyma and calcified nodules in the mediastinum, together with a large diverticulum containing food residue (**Figure 5**).

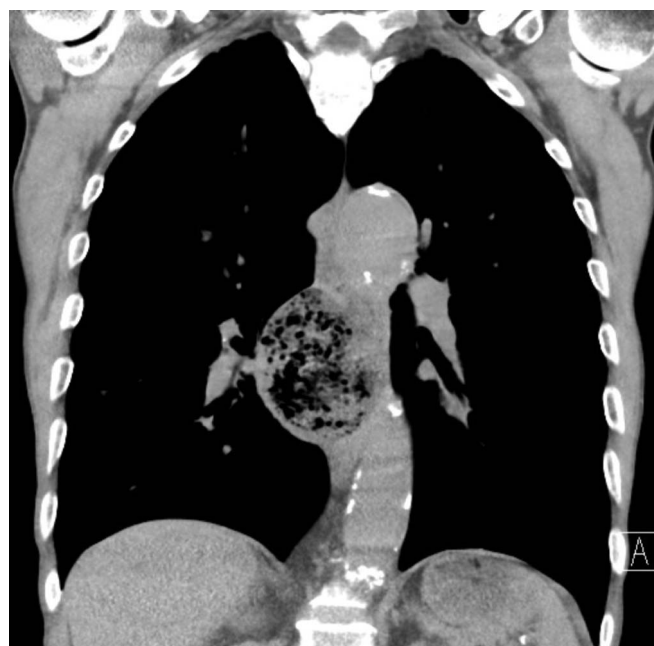

Figure 5. A large diverticulum containing food residue.

Management and Outcome

The patient underwent a robot-assisted transthoracic diverticulectomy. The operative time was 300 min. On postoperative day 3, the patient was started on liquids and tolerated them well. A thoracic tube drained serous and hemorrhagic fluids. On postoperative day 5, the thoracic tube was withdrawn. On postoperative day 6, the patient had respiratory distress, and rales were heard in the right lung on auscultation. A second CT scan of the thorax revealed increased density in the lower zones of the right lung consistent with pneumonia. Empiric antibiotic therapy was started with piperacillin and tazobactam. The patients' respiratory symptoms decreased over time, and she was discharged on postoperative day 17.

Specimen pathology revealed a 7 × 3.5 × 2.5-cm esophageal diverticulum. The mucosa of the diverticulum was covered with squamous epithelium, and the wall consisted of the muscle layer.

DISCUSSION

Esophageal diverticulum is a rare disease classified either as pulsion or traction diverticulum, based on pathogenesis. A pulsion diverticulum consists of mucosa bulging from the muscle layer of the esophagus because of increased intraluminal pressure, whereas a traction divertic-

ulum consists of both the mucosa and muscle layer of the esophagus and is associated with various lung and mediastinal diseases, such as interstitial lung disease, sarcoidosis, and tuberculosis.¹¹⁻¹³

In our patients, although the diagnosis of epiphrenic diverticulum was made with imaging studies, the history of chronic obstructive or interstitial lung disease and pathology results were consistent with traction diverticulum. Pathology specimens of all three cases revealed involvement of both mucosa and muscle layers of the diverticulum.

The preoperative diagnostic tests and imaging techniques chosen for our patients were EGD, esophageal manometry, and CT scans. Esophageal manometry results were found to be normal in 2 of the cases but could not be performed in 1 case because of insertion of the probe repeatedly into the diverticulum.

In literature, the chosen surgical method for epiphrenic diverticulum is diverticulectomy with myotomy and fundoplication.⁸ By decreasing the intraluminal pressure of the esophagus, myotomy and fundoplication seemed to result in a reduction in anastomotic leaks.^{14,15} Besides, these methods have been found to be necessary because of the strong association of hiatal hernia and esophageal motility disorders with epiphrenic diverticulum.^{14,16} How-

Table 1.
Clinical Features of 3 Patients Who Underwent Robot-Assisted Transthoracic Surgery for Esophageal Diverticulum

Variables	Case 1	Case 2	Case 3	Mean
Age (y) and gender	62, M	65, M	75, F	67.3 years
Comorbid diseases	None	Idiopathic pulmonary fibrosis	Chronic obstructive pulmonary diseases	
Diagnosis	Epiphrenic 2-cm diverticulum in	Epiphrenic 8-cm diverticulum	Epiphrenic-midesophageal 7-cm diverticulum	
Esophageal manometry test	Normal	Could not be performed	Normal	
Operative technique	Diverticulectomy by robot-assisted transthoracic approach	Diverticulectomy by robot-assisted transthoracic approach	Diverticulectomy by robot-assisted transthoracic approach	
Anesthesia time (min)	230	210	360	266.6
Docking time (min)	3	4	4	3.6
Operative time (min)	170	165	300	211
Intraoperative complication	None	None	None	
Postoperative complication	None	Anastomotic leak	Pneumonia	
Length of hospital stay	3 days	Exitus	17 days	

ever, there is still no consensus on the type of surgical access, the length of the myotomy, or the type of antireflux technique.^{17,18}

In our cases, the choice of surgical method was robot-assisted diverticulectomy by the transthoracic approach. Ruling out any esophageal motility disorder and hiatal hernia before surgery and identifying associated lung disease led to the diagnosis of traction diverticulum. Therefore, diverticulectomy alone was performed in our patients. Macke et al⁸ reported 6 patients who were treated with diverticulectomy alone in a retrospective study of 57 patients.

Minimally invasive methods for diverticulectomy include VATS, laparoscopic, and robot-assisted techniques. The robotic or laparoscopic transhiatal approach is a common method, because it provides an easier approach for fundoplication.^{4,19} The common morbidities are anastomotic leak, pneumonia, empyema, and atelectasis. Unfortunately, morbidity rates are similar for open and minimally invasive surgical methods.⁸

The transthoracic approach for diverticulectomy via VATS has been reported to provide better visualization and ease of dissection for the more proximal and midesophageal diverticula.⁸

This report adds to the literature on robot-assisted surgery for esophageal diverticulectomy. The transthoracic technique described herein provides an easier approach to the diverticulum, and by complete visualization, dissection of the neck of the diverticulum can be performed safely. Operative times were 165 and 170 min in our cases 1 and 2, which is similar to the duration of the robot-assisted transhiatal approach.⁴ On the other hand, case 3 had a longer operative time (300 min), probably because of several factors, including procedural experience, because it was the first case we had performed using the transthoracic approach.

Two of our patients had traction diverticulum caused by underlying chronic pulmonary disease, which was an additional risk factor for the postoperative morbidities that we encountered.

Anastomotic leak may lead to significant deterioration in patients' hemodynamic status by causing empyema, mediastinitis, and sepsis. There are several management methods for the leak, including reoperation, external drainage, and covered stent placement, which was the choice in our patient in case 2.^{3,8}

The robot-assisted transthoracic approach for esophageal diverticulectomy seems a feasible method to use in se-

lected patients with esophageal diverticulum. Further studies in larger case series are needed to evaluate the morbidity and mortality rates associated with this technique (**Table 1**).

References:

1. Belsey R. Functional disease of the esophagus. *J Thorac Cardiovasc Surg*. 1966;52:164–188.
2. Soares RV, Montenegro M, Pellegrini CA, Oelschläger BK. Laparoscopy as the initial approach for epiphrenic diverticulum. *Surg Endosc*. 2011;25:3740–3746.
3. Bhandarwar AH, Tungenwar PN, Sawakare YM, Wagh AN, Patel CB, Gandhi SS. Large epiphrenic diverticula: a rare case presentation. *Clin Pract*. 2015;5:784.
4. Alecu L, Bărbulescu M, Ursuă B, Barga B, Slavu I. Large oesophageal epiphrenic diverticulum resected by transhiatal robotically-assisted approach: case report. *Chirurgia*. 2015;110:72–77.
5. Blom D. Epiphrenic diverticula. *Operat Tech Gen Surg*. 2006;8:170–180.
6. Herbella FA, Patti MG. Modern pathophysiology and treatment of esophageal diverticula. *Langenbecks Arch Surg*. 2012;397:29–35.
7. Herbella FA, Patti MG. Achalasia and epiphrenic diverticulum. *World J Surg*. 2015;39:1620–1624.
8. Macke AR, Luketich JD, Pennathur A, et al. Thoracic esophageal diverticula: a 15-year experience of minimally invasive surgical management. *Ann Thorac Surg*. 2015;100:1795–1803.
9. Elola-Olaso AM, Mullett TW, Gagliardi RJ. Epiphrenic diverticulum: robotic-assisted transhiatal approach. *Surg Laparosc Endosc Percutan Tech*. 2009;19:184–188.
10. Pernazza G, Monsellato I, Pende V, et al. Fully robotic treatment of an epiphrenic diverticulum: report of a case. *Minim Invasive Ther Allied Technol*. 2012;21:96–100.
11. Raziell A, Landau O, Fintsi Y, Fass R, Charuzi I. Sarcoidosis and giant midesophageal diverticulum. *Dis Esophagus*. 2000;13:317–319.
12. Meyer A, Connell T, Alex G. Gastrointestinal: esophageal traction diverticulum led to tuberculosis diagnosis. *J Gastroenterol Hepatol*. 2014;29:1850.
13. Nagashima O, Matsuno K, Tominaga S, Takahashi K. Esophageal diverticulum with idiopathic pulmonary upper lobe fibrosis. *Intern Med*. 2013;52:159.
14. Olarte P, Padrón OL, Arboleda D. Resección de divertículo epifrénico por laparoscopia [Resection of epiphrenic diverticulum by laparoscopy]. *Rev Colomb Cir*. 2012;27:306–313.

15. Andolfi C, Wiesel O, Fisichella PM. Surgical treatment of epiphrenic diverticulum: technique and controversies (review). *J Laparoendosc Adv Surg Tech A*. 2016;26:905–910.
16. Achim V, Aye RW, Farivar AS, Vallières E, Louie BE. A combined thoracoscopic and laparoscopic approach for high epiphrenic diverticula and the importance of complete myotomy. *Surg Endosc*. 2017;31:788–794.
17. Gonzalez-Calatayud M, Targarona EM, Balague C, et al. Minimally invasive therapy for epiphrenic diverticula: systematic review of literature and report of six cases. *J Minim Access Surg*. 2014;10:169–174.
18. Beiša V, Kvietkauskas M, Beiša B, K Strupas K. Laparoscopic approach in the treatment of large epiphrenic esophageal diverticulum. *Videosurg Miniinv*. 2015;10:584–588.
19. Rossetti G, Fei L, del Genio G, et al. Epiphrenic diverticula mini-invasive surgery: a challenge for expert surgeons: personal experience and review of the literature. *Scand J Surg*. 2013;102:129–135.