



Intraosseous Ganglion Cyst of Scaphoid treated by Curettage and Bone Grafting: Case report and Review

Saurabh Jain¹, Anil Kumar Jain¹, Ish Kumar Dhammi¹, Puneet Mishra¹, Prasant Modi¹

ABSTRACT

Introduction - Intraosseous ganglions, although share same pathology as the soft tissue ganglions are rare entities, further rare in carpals. Cases of intraosseous ganglions are reported in literature mostly in lower limbs and lunate among carpals, with treatment options ranging from curettage and grafting to calcium phosphate cement injection and finally to arthroscopic treatment.

Case report – Here, we present a case of 2 years follow up of 40 years old female with nonspecific clinical finding of wrist and slight limitation of restriction of motion, diagnosed as intraosseous ganglion cyst of scaphoid. This case was treated with curettage and bone grafting having excellent results with visual and analog pain scores reduced from 68 to 11 and range of motion was 90° extension to 80° flexion and full grip strength.

Conclusion - Intraosseous ganglion cyst should be considered in differential diagnosis of chronic dull wrist pain because they produce disabling symptoms which ceases once adequately treated by curettage and bone grafting.

Keywords: Intraosseous Ganglion; scaphoid, curettage and bone grafting

INTRODUCTION

Intraosseous ganglion, contrary to soft tissue counterpart, is a relatively rare pathological entity

occurring most commonly in lower limb especially around ankle and rarely in carpals [1]. We present a case report of intraosseous ganglion cyst of scaphoid, its pathology, clinical and radiological finding and treatment options.

CASE PRESENTATION

A 40 years old female with right hand dominance, presented with complains of pain in right wrist joint since 6 months. Pain was non-radiating and localized at anatomical snuff box. Pain was temporarily relieved by NSAIDS but recurred with increase in activity. Over a period of time the pain gradually increased in intensity from mild to moderate pain that interfered with daily activity. There was no history of trauma, fever, constitutional symptoms or similar pain and swelling elsewhere in body. On examination, marked tenderness was present in region of the volar scaphoid proximal pole as well as overlying the dorsal radial styloid and snuff box. There was no swelling or palpable mass around the wrist. The grip strength was symmetrical normal. Range of motion was non painful and was only slightly less (flexion - 50°, extension - 60°) compared to contra-lateral side (flexion - 80°, extension - 90°).

Her hematological investigations including hemo-gram, ESR, serum calcium, phosphate, alkaline phosphatase, RA factor, uric acid, renal function test were within normal limits. A clinical diagnosis of chronic wrist pain with probable etiology being infective pathology, AVN of lunate, carpal instability, cystic lesions of carpal bones were entertained.

Her radiological examination of right wrist joint showed a well defined non-expansile osteolytic cystic lesion in scaphoid with rim of sclerotic margin & thinning of cortex eroding the volar surface of scaphoid (Fig. 1a,b). Her radiological survey was within normal limits. CT scan confirmed the radiological finding demonstrating osteolytic lesion with sclerotic margins communicating with radio-

¹Dept of Orthopaedics GTB hospital and UCMS, Delhi, India

*Address of Correspondance

Dr Saurabh jain
Dept of Orthopaedics GTB hospital and UCMS, Delhi, India - 110095
Email – jaindrsaurabh@yahoo.com



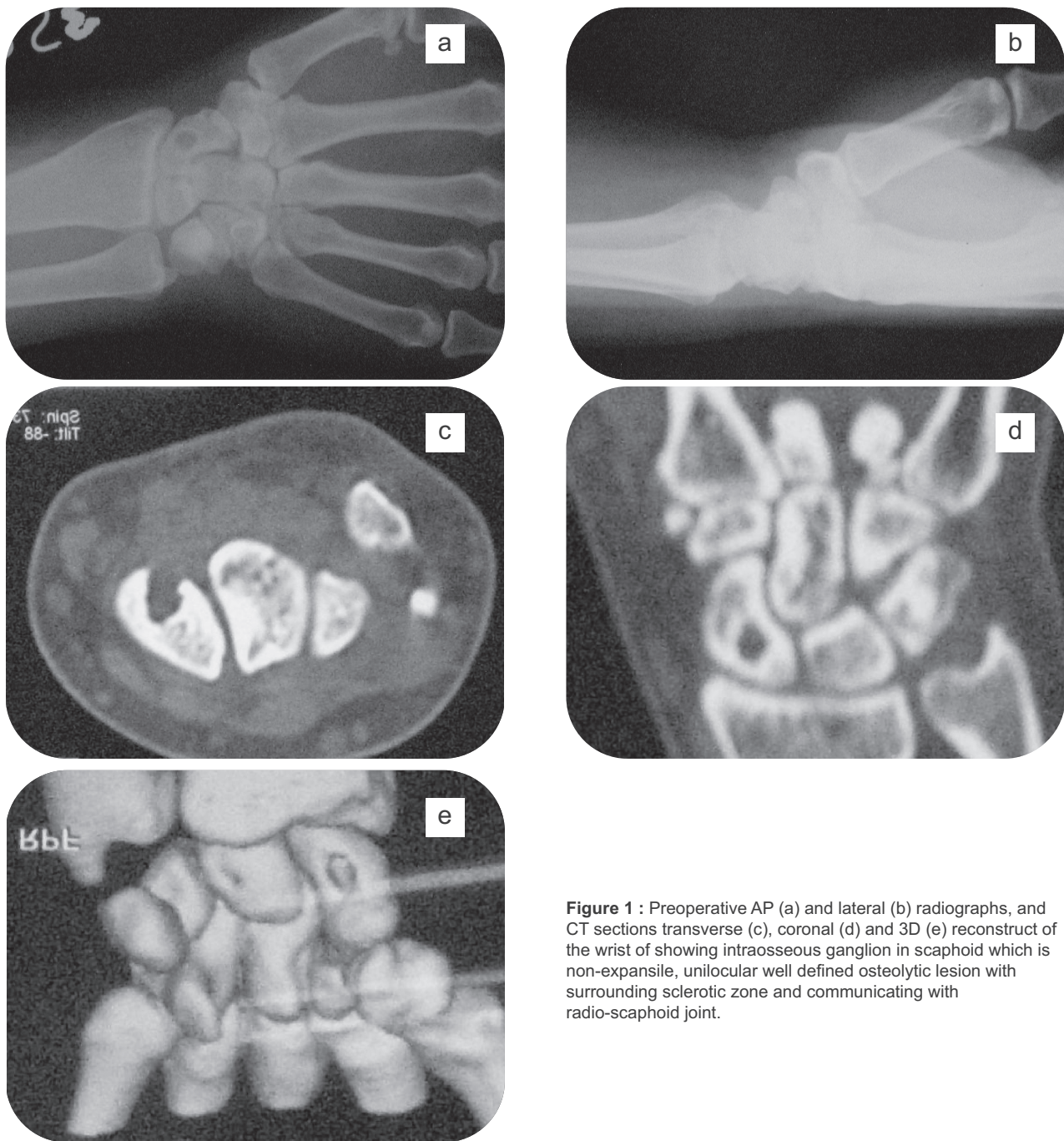


Figure 1 : Preoperative AP (a) and lateral (b) radiographs, and CT sections transverse (c), coronal (d) and 3D (e) reconstruct of the wrist of showing intraosseous ganglion in scaphoid which is non-expansile, unilocular well defined osteolytic lesion with surrounding sclerotic zone and communicating with radio-scaphoid joint.

scaphoid joint and eroding into scaphoid and thinning of its cortex (Fig. 1c,d,e). A radiological differential diagnosis of cystic radiolucent carpal lesion osteoid osteoma, osteoblastoma, ganglion cyst of scaphoid was considered.

She underwent curettage of the cyst and bone grafting. The lesion was approached through volar approach under fluoroscopic guidance. Lesion of around 1cm x 1.5 cm x 0.8 cm was curetted along with marginal excision of surrounding soft tissue. It

was found to be connected to the scapho-radial joint and 3ml gelatinous material was removed. The lesion was then packed with autogenous iliac cortico-cancellous bone grafts and the wound was closed. On histopathological examination of tissues, it was identical to soft tissue ganglion containing myxoid material with free floating macrophages i.e. myxoid degeneration with focal chronic inflammation. Wrist was immobilized in glass holding position for 3 weeks after that gradual mobilization started and full range

of motion achieved at 6 weeks. Patient returned to employment at 6 weeks. Wrist functions improved over 6 months with trabeculations being noted within the grafted scaphoid. At final follow after two years, visual and analog pain scores reduced from 68 to 11 and range of motion was 90° extension to 80° flexion and full grip strength. Radiological examination showed complete bone healing with incorporation of the graft (Fig. 2).

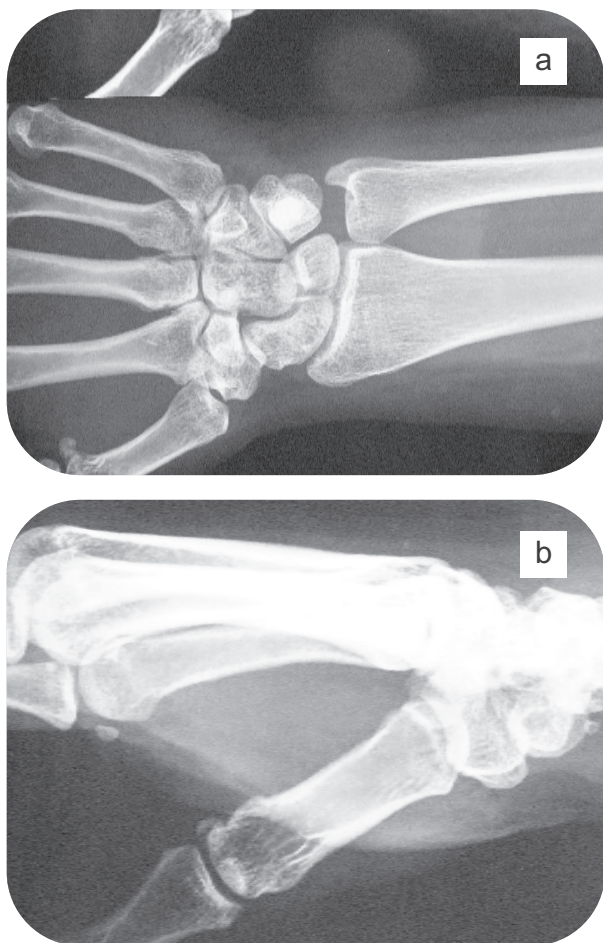


Figure 2 : 2 year post-operative AP (a) and lateral (b) radiographs of the same patients showing healed cyst after undergoing curettage and bone grafting.

DISCUSSION

Intraosseous ganglion is defined as “a benign cystic and often multiloculated lesion made up of fibrous tissue with extensive mucoid changes, located in the subchondral bone adjacent to a joint” [1] The first reported case of intraosseous ganglion was by J.D. Hicks in 1956 [2]. It occurs most commonly in lower limb especially around ankle and femoral head and, rarely in carpal. Among carpals, lunate is the most commonly affected and scaphoid is a rare site of

involvement. Its incidence is 3.7% in unexplained wrist pain [3] Schrank C found the prevalence to carpal cyst to be 9.6% in cadaveric wrist which almost always have a capsular continuity [4]. Van den dungen et al found that 59% of the cases of dorsal wrist ganglion cyst had associated asymptomatic intraosseous ganglion in carpals which are only diagnosed incidentally, 14 % occurring in scaphoid suggesting a common etiology for both types of ganglion cyst explaining this high association rate [5] In our case also the cyst was in scaphoid, having capsular connectivity with the radioscaphoid joint but it was not associated with co-occurrence of the soft tissue ganglion.

Intraosseous ganglions although occur in all age groups but are common in young women [4], as in our case. Pathogenesis of this uncommon lesion is still a topic of debate; however the most popularly accepted theory is due to myxomatous degeneration of connective tissue primarily. The degeneration of connective tissue leads to the formation of cyst with proliferation of fibroblast secreting mucopolysaccharides, developing commonly either within the bone near a joint, not directly in communication with it or from secondary penetration of a juxta-osseous ganglion from adjacent joint into adjacent bone.

Occasionally, there is a history of recent trauma, although it was absent in our case. Acute trauma though not contributing perse the cause but can lead to diagnosis of the non-symptomatic intraosseous ganglion. Other possible predisposing factors can be repeated overuse of the hand. Clinical findings are non reliable as there is only mild to moderate aching discomfort during movement with no history of prior trauma. Physical examination is usually non-conclusive and negative, as in ours. Radiograph discloses a well defined osteolytic lesion with surrounding sclerotic zone. The cyst is usually non-expansile and unilocular but can be multilocular. CT scan and MRI are not necessary but help in planning the treatment and documenting the extent and communication of the lesion with the joint. These imaging can further help in diagnosing the occult fractures as seen as presence of a linear area of low signal intensity within the bone on T1 weighted images that demonstrated high signal intensity on STIR images. Arthrographic studies are also useful in demonstrating communication between intraosseous ganglions and joint. Klingman M demonstrated use of urograffin injection to demonstrate communication between intraosseous ganglion and soft tissue ganglion of scaphoid [6]. Malghem J reported that arthrography followed by CT scan 1-2 hrs after injection of dye is the best

Table 1: Literature review Comparison of the treatment of intraosseous ganglion cysts of carpals

Authors	Lesion site	Treatment	Bone healing	Outcome
Mogen et al [8]	Lunate(2)	Curettage & cancellous bone graft	Not mentioned	Symptom free
Iwahara et al [9]	Lunate(1)	Curettage & cancellous bone graft	Not mentioned	Pain-free
Fealy MJ, Lineaweaver W [10]	Scaphoid(1)	Radial styloidectomy Curettage, bone graft from radial styloid	Healed	Not reported Prolong immobilization,
Yajima H [12]	Scaphoid (1) Lunate (5) Hamate (1)	Curettage & CPC cement	Partial absorption of cement in 4	Pain - 4
Ying et al [13]	Capitate(1)	Curettage, bone marrow & fibrin clot graft	Healed	Excellent, Prolonged immobilization
Bain GI [14]	Lunate (8)	Arthroscopic curettage & Bone grafting	Healed with trabeculation	Excellent
Urburu & Levy [20]	Scaphoid (6) & Lunate (9)	Curettage & cancellous bone graft	Healed	Good-14, partial lunate collapse & arthritis -1
Bowers & Hurst [21]	Scaphoid(1)	Curettage & cortico-cancellous bone graft	Not mentioned	Not mention
Helal & Vemon-Roberts [22]	Pisiform (1)	Excision		Limitation of ROM
Tham & Ireland [23]	Lunate(9)	Curettage & cancellous bone graft	Not mentioned	Excellent- 6 good-2, poor-1
De Smet [24]	Triquetrum(1)	Curettage, bone graft from pisiform		Limitation of ROM
Waizenegger M [25]	Scaphoid(14) Lunate (12)	Curettage & bone graft		No reported
This case	Scaphoid(1)	Curettage & cancellous bone graft	Healed	Excellent after 2 year follow up

procedure to assess communication between ganglion cyst and joint [7]. Bone scan helps to differentiate which other bone cysts, as intraosseous ganglion shows, focal areas of increased radiotracer uptake. Histopathology shows dense fibrous wall and mucoid gelatinous contents rich in hyaluronic acid and mucopolysachride [3]. In our case also the histopathologic report suggested similar findings.

Differential diagnosis includes enchondroma, giant cell tumor, simple bone cyst (bone cyst contain sero or serosanguinous fluid with giant cell in wall and located in metaphyseal area), juxta-articular cyst of OA (occurs late in life) and post traumatic cyst [8]. The absence of other stigmata of joint disease, solitary in nature, large size, myxoid tissue and zone of condensed bone around it are the diagnostic features of the intraosseous ganglion cyst.

Mainstay of treatment is mainly by curettage of lesion & bone graft [9]. Good to excellent results are reported by curettage and bone graft (Table 1). We also performed curettage and bone grafting, via volar approach, giving excellent results

comparable to other reports (Table 1), with returned to employment in 6 weeks, visual and analog pain scores reduced from 68 to 11, improved range of motion, grip strength and wrist score from 51 to 85 points and radio logically occurrence of trabeculations within 6 months.

But in spite of excellent outcome after curettage and bone grafting, the procedure involves donor site complications due to graft harvest like painful scar formation, infection, hematoma, fractures and gait disturbances. To avoid these complications and donor site morbidity Fealy MJ used radial styloid as graft after styloidectomy along with intralesional curettage[10]. Schacherer TG also treated 11 intraosseous ganglions with curettage and bone graft from distal radius showing complete resolution at 20 months follow up[11]. But since they used the distal radius for graft, these patients were immobilized for greater duration thus reducing the final outcome results, decreasing the grip strength, range of motion and reducing benefits of early mobilization and early return to work. Bone graft was replaced with

injectable calcium phosphate bone cement by Yajima et al avoiding all donor site complications which is another option available for repairing defects after curettage of an intraosseous ganglion cyst, but the results were not so promising since 50% cases had persistent pain and 50% had partial absorption of cement [12].

Recently, in an attempt to decrease donor site complications and retaining the advantage of early mobilization, intralesional curettage & bone marrow graft augmented by autologous fibrin clot graft in capitates ganglion cyst was performed by Chen YC with excellent results [13]. Although the results were comparable with procedures involving bone grafting but the complications associated with bone graft harvest were minimized retaining advantage of transfer of osteoprogenitor cells needed for bone regeneration in the lesion with transfer of growth factors as contained in platelet aggregates in fibrin clot.

Arthroscopically assisted minimal invasive technique for debridement, curettage & bone grafting are also developed by Bain GI [14]. Compared to open techniques, arthroscopic procedure demonstrated better results and improved localization with low complication rates, less surgical dissection, less postoperative pain, a shorter recovery time and earlier return to work, but it needs expertise.

Complications due to intraosseous ganglion cyst are fracture and repeated erosion leading to rupture of tendon mainly flexor tendon of finger. Re-occurrence of cyst can occur after bone graft. Reported case of carpal tunnel syndrome and rupture of flexor tendon of index finger are also reported [15-17]. Castellanos reported a case of pathological fracture of the scaphoid due to intraosseous ganglion followed by regression of the cyst after healing of the fracture [18]. Regression of scaphoid ganglion can occur with uneventful healing of the fracture [19]. None of these complications occurred in our case even after 2 year follow up.

CONCLUSION

Intraosseous ganglion cyst should be considered in differential diagnosis of chronic dull wrist pain because they produce disabling symptoms which cease once adequately treated by curettage and bone grafting.

CLINICAL MESSAGE

Intraosseous ganglion cyst should be considered in differential diagnosis of chronic dull wrist pain. The ganglion cysts can be adequately treated by curettage and bone grafting

REFERENCE

- Schajowicz F, Sainz MC, Slullitel JA. Juxtra-articular bone cysts (intra-osseous ganglia). J Bone Joint Surg (Br) 1979; 61;107-16.
- Hicks JD. Ganglion cyst of bones. Australian and New Zealand Journal of surgery.1956; 26;138.
- Magee TH, Rowedder AM, Degnan GG. Intraosseous ganglia of the wrist. Radiology 1995;195; 517-20.
- Schrank C, Meirer R, Satbler A et al. Morphology and topography of intraosseous ganglion cysts in the carpus; an anatomic, histopathologic and magnetic resonance imaging correlation study. J Hand Surg(Am). 2003; 28;1;52-64.
- Van den dungen S, Marchesi S, Ezzedine R, Bindou D, Lorea P. Relationship between dorsal ganglion cysts of the wrist and intraosseous cysts of the carpal bones. Acta Orthop Belg. 2005; 71;5;535-9.
- Klingman M, Roffman M. Bilateral intraosseous ganglia of the scaphoid and lunate bones. J Hand Surg(Br). 1997; 22; 6; 820-1.
- Malghem J, Vande BB, Lecouvet F, Lebon Ch, Maldague B. Atypical ganglion cysts. JBR-BTR.2002; 85;1; 34-42.
- Mogan JV, Newberg AH, Davis PH. Intraosseous ganglion of lunate. J Hand Surg 1981;6;61-3.
- Iwahara T, Hirayama T, Takemitsu Y. Intraosseous ganglion of the lunate. The Hand 1983;15; 297-9.
- Fealy MJ, Lineaweaver W. Intraosseous ganglion cyst of the cyst of the scaphoid. Ann Plast Surg 1995; 34;2; 215-7
- Schacherer TG, Aulicino PL. Intraosseous ganglia of the carpal. Orthop Rev.1991; 20; 10; 889-92.
- Yajima H, Murata K, Kawamura K, Kawate K, Takakura Y. Treatment of intraosseous ganglian and bone cysts of the carpal bones with injectable calcium phosphate bone cement. Hand Surg 2008; 13; 3;167-73.
- Chen YC, Wang SJ, Shen PH et al. Intraosseous ganglion cyst of the capitates treated by intralesional curettage, autogenous bone marrow graft and autogenous fibrin clot graft. J Chin Med Assoc 2007; 70; 5;222-6.
- Bain GI, Turner PC, Ashwood N. Arthroscopically assisted treatment of intraosseous ganglions of the lunate. Tech Hand Up Extrem Surg 2008; 12; 4;202-7.
- Darey PF, Sorelli, PG, Qureshi F, Orakwe S, Ogufero W. Carpal tunnel syndrome caused by an intraosseous ganglion of the capitates. Scand J Plast Reconstr Surg Hand Surg 2004; 38; 6; 379-81.
- Yamazaki H, Kato H, Murakami N. Closed rupture of the flexor tendons of the index finger caused by a pathological fracture secondary to an intraosseous ganglion in the lunate. J Hand Surg Eur 2007; 32; 1; 105-7.
- Masada K, Kanazawa M, Fuji T. Flexor tendon ruptures caused by an intraosseous ganglion of the hook of the hamate. J Hand Surg(Br) 1997; 22; 3; 383-5.
- Castellanos J, Bertran C, Perez R, Roca J. Pathological fracture of the scaphoid caused by intraosseous ganglion followed by regression after the healing of the fracture. J Trauma; 2001; 51; 1; 141-3.
- De Smet L, Fabry G. Regression of an intraosseous ganglion of the scaphoid following fracture. Acta Orthop Belg 1994; 60; 4; 434-5.

Conflict of Interest : NONE
Source of Funding : NONE

