

Case Report

Stafne bone cavity with ectopic salivary gland tissue in the anterior of mandible

Parviz Deyhimi¹, Soheila Darisavi², Saeideh Khalesi¹

¹Dental Research Center and Department of Oral and Maxillofacial Pathology, School of Dentistry, Isfahan University of Medical Sciences, ²Department of Oral and Maxillofacial Pathology, School of Dentistry, Isfahan University of Medical Sciences, Isfahan, Iran

Received: December 2015
Accepted: April 2016

Address for correspondence:
Dr. Saeideh Khalesi,
Department of Oral and
Maxillofacial Pathology,
Dental Research Center,
School of Dentistry, Isfahan
University of Medical
Sciences, Isfahan, Iran.
E-mail: s_khalesi@
dnt.mui.ac.ir

ABSTRACT

Stafne bone cavities (SBCs) are uncommon well-demarcated defects of the mandible, which often occur in the posterior portion of the jaw bone and are usually asymptomatic. Furthermore, SBC is found in men aged 50–70-year-old. Anterior mandibular variants of SBC are very rare. This article describes a case of anterior SBC in a 45-year-old man that resembled endodontic periapical lesions. Upon histopathological examination, it turned out to be a normal salivary gland tissue.

Key Words: Defect, mandibular, bone cyst

INTRODUCTION

Stafne bone cavity (SBC) is a pseudocyst of the jaw bone, which has also been termed lingual mandible bone cavity, lingual mandible bone depression, static, latent, or idiopathic bone cyst, cavity, or defect.^[1-4] This lesion is a nonneoplastic bony lesion, but its radiographic features and clinical manifestations can resemble other intrabony neoplastic lesions.^[5] Stafne bone defect is usually an asymptomatic lesion, but it may be symptomatic and have a predilection for the men of the average age of 50 years.^[3] Most of the reported cases of SBC have occurred near the angle of the mandible, below the inferior alveolar canal. This defect is most often unilateral, but rarely bilateral.^[5] Radiographic observation has shown it a round or ovoid well-defined unilocular radiolucency.^[1] Upon histopathological examination, the cavities are usually filled with normal salivary gland tissue, but in

some cases, skeletal muscle, fibrous connective tissue, adipose tissue, blood vessels, or lymphoid tissue may be seen.^[3,6]

In this article, we describe a case of unusual anterior lingual mandibular salivary gland defect in a 45-year-old man that mimicked a periapical lesion of endodontic origin.

CASE REPORT

A 45-year-old man referred to the Department of Periodontology, School of Dentistry, Isfahan University of Medical Sciences for routine dental and periodontal examinations. The patient's medical history was not significant. He was not a smoker and revealed no history of trauma or jaw surgery. On extraoral examination, he had a normal appearance.

This is an open access article distributed under the terms of the Creative Commons Attribution-NonCommercial-ShareAlike 3.0 License, which allows others to remix, tweak, and build upon the work non-commercially, as long as the author is credited and the new creations are licensed under the identical terms.

For reprints contact: reprints@medknow.com

How to cite this article: Deyhimi P, Darisavi S, Khalesi S. Stafne bone cavity with ectopic salivary gland tissue in the anterior of mandible. Dent Res J 2016;13:454-7.

Access this article online



Website: www.drj.ir
www.drjjournal.net
www.ncbi.nlm.nih.gov/pmc/journals/1480

On intraoral examination, the patient had neither any pain nor swelling on the buccal and lingual aspects of the mandible. The radiographic images showed a well-defined unilocular radiolucency below the apices of the left lateral incisor and left canine teeth [Figure 1].

Furthermore, deep caries was observed in the left lateral incisor. The clinician suspected a periapical lesion of endodontic origin, but unfortunately, the vitality test of the tooth was not done. To rule out any possible existing pathology in anterior mandible, a diagnostic excision biopsy was planned. The surgical exploration revealed the lingual cortex had been destroyed. Further, the gross examination indicated a soft, relatively firm, brownish, gray mass with granular surface measuring approximately 20 mm × 10 mm × 20 mm. Moreover, histopathologic examination showed a normal salivary gland tissue, with many mucous acini and ducts, which was consistent with normal sublingual gland [Figure 2]. The sections from few other areas revealed inflammatory cells, muscle tissue, fat tissue, blood vessels, and nerve bundles [Figure 3]. Thus, based on the clinical, radiographical, and histopathological findings, the final diagnosis of SBC with ectopic salivary gland tissue was made. Clinical and radiographic controls were performed during 3 months of follow-up. No changes in the zone have been detected.

DISCUSSION

For the first time, SBCs were described in 1942.^[7] Most cases of Stafne's bone cavities have been located in the posterior region of mandible, especially between the first molar and the angle of the mandible.^[3] However, a description of Stafne bone in the anterior portion of the mandible was presented for the first time by Richard and Ziskind in 1957.^[8] According to a review of the literature, 52 cases of SBCs in the anterior mandible have been reported so far.^[3,6] The overall incidence of SBC varies from 0.009% to 0.3%.^[3] Because the anterior mandibular bone is a rare location for ectopic salivary gland tissue, the present case is described. Most of the reported cases of anterior located SBCs are between the cuspid and the first molar, but in the present case, the location was found between the apices of the left lateral incisor and cuspid.^[1]

SBCs in the posterior part of the mandible usually have typical clinical and radiographic features that

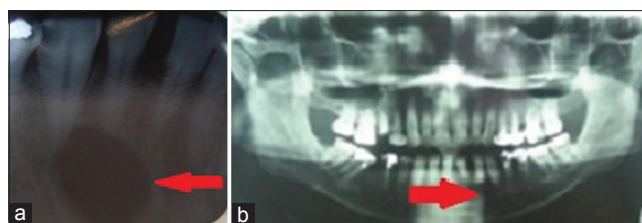


Figure 1: (a) Periapical radiograph showing a well-defined radiolucency below the apex of the left lateral incisor and the left canine teeth. (b) Panoramic image showing the radiolucency in the anterior region of the mandible.

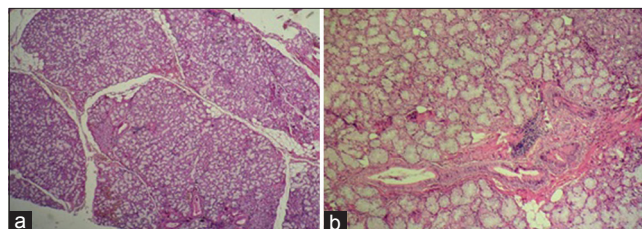


Figure 2: (a) Photomicrograph of the removed tissue showing the normal salivary gland tissue (H and E, ×100). (b) Photomicrograph of the mucous acini and salivary gland ducts (H and E, ×400).

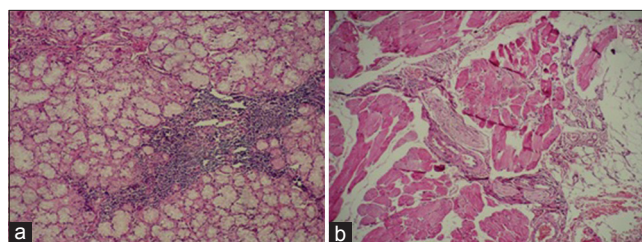


Figure 3: (a) Photomicrograph of the mucous acini and inflammatory cells (H and E, ×400). (b) Photomicrograph of the fat tissue, nerve bundle, blood vessels, and muscles tissue (H and E, ×100).

allow an easy diagnosis. Most of the lesions are asymptomatic and nonprogressive.^[1] Unlike the posterior lesions, differential diagnosis of anterior SBCs may be difficult to make because they are usually noted between or below the teeth roots or are superimposed over the roots or at the locations of the previous extraction sites.^[1] The radiographic appearance of the lesion as a well-defined unilocular radiolucency may be misinterpreted as other unilocular radiolucencies, belonging to that of other various lesions such as salivary gland tumors, central giant cell granuloma, early focal cement-osseous dysplasia, benign neurogenic tumors, bone metastasis, or more frequently cysts (e.g., radicular, residual, lateral periodontal cyst, odontogenic keratocyst).^[1,6] In our case, in view of the associated deep carious lesion and radiolucency in the periapical region of the

left lateral incisor, the first diagnosis was made for an inflammatory periapical lesion of endodontic origin.

Most of the time, endodontic treatment is undertaken owing to this misinterpretation. Biopsy is usually undertaken following failure of endodontic treatment. Thus, to avoid unnecessary endodontic treatment for such lesions, vitality pulp test must be performed.^[3] In our case, vitality test of tooth was not performed, and an excisional biopsy was planned.

According to the reported cases of anterior SBC, wide range, from 18 to 64 years, with a mean of 43 years has been noted, which is similar to our case.^[1] Furthermore, a higher prevalence in males (3:1, males: females) was observed.^[3]

Radiographically, the bony cavities resulting from this lesion usually appear as a circumscribed, unilocular osteolytic radiolucency. The size of the lesions has ranged from 0.5 to 2 cm, with a median size of 1.2 cm.^[1,3,9] Few have observed the presence of a sclerotic border with rare multilocular appearance.^[3] In our case, we observed only a well-circumscribed unilocular radiolucency similar to other reports. According to many studies, the anterior SBCs usually contain normal or inflamed salivary gland tissue of the sublingual gland, with or without varying amounts of fibrous connective tissue and fat tissue.^[1-3] Similar to the previous studies, in histopathological examination of our case, we observed normal salivary gland tissue, fat tissue, and a few blood vessels.

The pathogenesis of SBC is not yet clearly known, but most studies accept the congenital malformation theory, which states that a portion of the salivary gland tissue gets congenitally entrapped during the mandible development.^[1] Thus, this theory could explain the presence of an intact thin lingual cortex, separating the bony lesion from the adjacent salivary gland.^[1,10] However, other views are indicative of the pressure resorption theory in which the pressure from the adjacent structures such as salivary gland tissue, facial artery has been suggested as a possible reason of the development of SBC.^[3,6] Lymphatic infiltration has also been suggested as the cause of hypertrophied salivary gland in the pressure-induced pathogenesis theory.^[6,11] However, in our case, the ectopic salivary gland tissue noted in the anterior mandibular bone was not found in continuity with the adjacent salivary gland tissue and was separated by normal buccal and lingual cortices. Therefore, the present case is in accordance with the developmental theory.

According to most studies, the posterior and anterior variants of SBCs do not need further treatment. Surgical exploration, incisional biopsy, and enucleation are frequently done only for diagnostic reasons.^[1,5] However, in recent studies, the use of different new techniques such as cone beam computer tomography and magnetic resonance imaging for the final diagnosis can be useful to avoid unnecessary surgical explorations.^[3,5]

CONCLUSION

Generally, the management of SBC should be of a conservative approach with radiographic follow-up, and no treatment is necessary. However, surgical exploration and biopsy may be reserved for those cases simulating any other benign or malignant lesions with uncertainty in diagnoses.

Financial support and sponsorship

Nil.

Conflicts of interest

The authors of this manuscript declare that they have no conflicts of interest, real or perceived, financial or non-financial in this article.

REFERENCES

1. de Courten A, Küffer R, Samson J, Lombardi T. Anterior lingual mandibular salivary gland defect (Stafne defect) presenting as a residual cyst. *Oral Surg Oral Med Oral Pathol Oral Radiol Endod* 2002;94:460-4.
2. Reichart PA, Philipsen HP. Lingual mandibular bone depression (Stafne's cavity). In: Reichart PA, Philipsen HP, editors. *Odontogenic Tumors and Allied Lesions*. London: Quintessence; 2004. p. 351-8.
3. Turkoglu K, Orhan K. Stafne bone cavity in the anterior mandible. *J Craniofac Surg* 2010;21:1769-75.
4. Schneider T, Filo K, Locher MC, Gander T, Metzler P, Grätz KW, *et al.* Stafne bone cavities: Systematic algorithm for diagnosis derived from retrospective data over a 5-year period. *Br J Oral Maxillofac Surg* 2014;52:369-74.
5. Bornstein MM, Wiest R, Balsiger R, Reichart PA. Anterior Stafne's bone cavity mimicking a periapical lesion of endodontic origin: Report of two cases. *J Endod* 2009;35:1598-602.
6. Kim H, Seok JY, Lee S, An J, Kim NR, Chung DH, *et al.* Bilateral Stafne bone cavity in the anterior mandible with heterotopic salivary gland tissue: A case report. *Korean J Pathol* 2014;48:248-9.
7. Stafne EC. Bone cavities situated near the angle of the mandible. *J Am Dent Assoc* 1942;29:1969-72.
8. Richard EL, Ziskind J. Aberrant salivary gland tissue in mandible. *Oral Surg Oral Med Oral Pathol* 1957;10:1086-90.
9. Belmonte-Caro R, Vélez-Gutiérrez MJ, García De La Vega-Sosa FJ,

- García-Perla-García A, Infante-Cossío PA, Díaz-Fernández JM, *et al.* A Stafne's cavity with unusual location in the mandibular anterior area. *Med Oral Patol Oral Cir Bucal* 2005;10:173-9.
10. Bouquot JE, Gnepp DR, Dardick I, Hietanen JH. Intraosseous salivary tissue: Jawbone examples of choristomas, hamartomas, embryonic rests, and inflammatory entrapment: Another histogenetic source for intraosseous adenocarcinoma. *Oral Surg Oral Med Oral Pathol Oral Radiol Endod* 2000;90:205-17.
11. Sisman Y, Miloglu O, Sekerci AE, Yilmaz AB, Demirtas O, Tokmak TT. Radiographic evaluation on prevalence of Stafne bone defect: A study from two centres in Turkey. *Dentomaxillofac Radiol* 2012;41:152-8.