

Discoid Lupus Erythematosus Complicated with Pregnancy-induced Hemophagocytic Syndrome

Hideto Takada, Naoki Kimura, Yoko Yoshihashi-Nakazato,
Kimito Kawahata and Hitoshi Kohsaka

Abstract

A 35-year-old woman with discoid lupus erythematosus (DLE) was admitted at 11 weeks' gestation with a persistent fever. Laboratory studies revealed pancytopenia, elevated liver enzymes, and hyperferritinemia. Bone marrow aspiration confirmed the diagnosis of hemophagocytic syndrome (HPS). She had no findings of infection or active systemic lupus erythematosus. The administration of high-dose corticosteroids resolved the clinical and laboratory findings. She delivered a healthy baby at 35 weeks' gestation. This case suggests that DLE can be a predisposing factor for pregnancy-induced HPS.

Key words: hemophagocytic syndrome, pregnancy, discoid lupus erythematosus, systemic lupus erythematosus

(Intern Med 56: 1581-1583, 2017)

(DOI: 10.2169/internalmedicine.56.8156)

Introduction

Hemophagocytic syndrome (HPS) is a severe and life-threatening disease, characterized by the activation of macrophages engulfing erythrocytes, leukocytes, platelets, and their precursor cells in the bone marrow. HPS has been classified according to the underlying etiology as either primary (familial) or secondary (acquired). Primary HPS, also called familial hemophagocytic lymphohistiocytosis (HLH), manifests typically in infants and children with genetic abnormalities affecting the cytotoxic functions of T lymphocytes and natural killer cells. Secondary HPS manifests in patients without genetic abnormalities and occurs in association with a predisposing factor, such as malignancy or autoimmune disease, and/or a trigger, such as an infection (1). To our knowledge, 18 cases of HPS that developed during pregnancy associated with various underlying diseases have been reported in the past (2-8). We herein report the first case of discoid lupus erythematosus (DLE) complicated with pregnancy-induced HPS.

Case Report

A 35-year-old Japanese woman was admitted at 11 weeks' gestation with a persistent high fever and pancytopenia. She had a nine-year history of DLE diagnosed on the basis of well-defined erythematous plaque on her face, scarring alopecia, and histopathologic findings of alopecia: basal vacuolar degeneration and lymphocytic perivascular and peri-appendageal infiltrate (Figure). Although she had been treated with topical corticosteroids and tacrolimus, the skin lesion had persisted for several years.

On admission, her body temperature was 38.6°C. She was normotensive. A physical examination revealed scarring alopecia and erythematous plaque on her face with no change from the previous visit. Laboratory studies revealed pancytopenia with a white blood cell count 2,800/μL (neutrophils 58%), hemoglobin 10.3 g/dL, and platelet count 111,000/μL. Serum liver enzymes (aspartate aminotransferase 114 IU/L, alanine transaminase 71 IU/L, lactate dehydrogenase 556 U/L), ferritin (1,625 ng/mL), triglyceride (177 mg/dL), C-reactive protein (7.3 mg/dL), and complement C3 and C4 levels were elevated. Antinuclear antibodies were weakly positive (1:40, speckled and nuclear patterns).

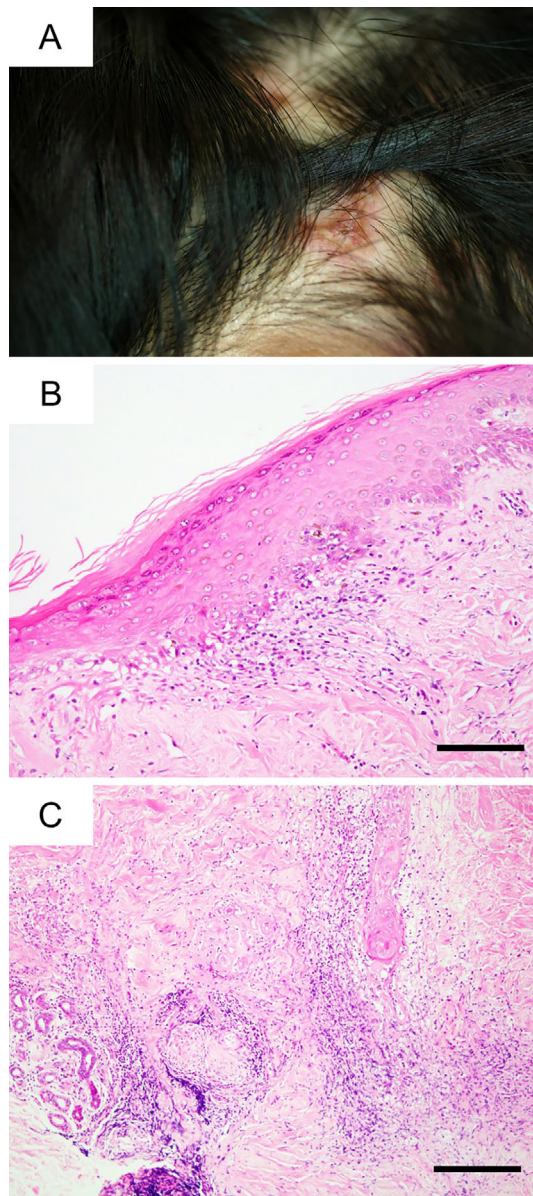


Figure. Clinical and histopathological findings of discoid lupus erythematosus on the scalp. (A) Erythematous plaques with alopecia on the scalp. (B) Basal vacuolar degeneration [Hematoxylin and Eosin (H&E) staining, scale bar=100 μ m]. (C) Lymphocytic perivascular and peri-appendageal infiltrate (H&E staining, scale bar=200 μ m).

Anti-dsDNA, Sm, RNP, SS-A/B, and cardiolipin antibodies were all negative. Direct and indirect Coombs' tests were negative. Haptoglobin levels were within the normal range. Abdominal ultrasound revealed splenomegaly. Transvaginal ultrasound revealed no evidence of fetal distress. Bone marrow aspiration revealed increased numbers of macrophages engulfing myeloid cells, erythroid precursors, and platelets.

Based on the HLH-2004 diagnostic criteria (9), a diagnosis of HPS was made. Blood cultures and chest X-ray revealed no evidence of infection. Serological tests for hepatitis B and C and polymerase chain reaction testing for herpes simplex virus 1/2, varicella zoster virus, Epstein-Barr virus, cytomegalovirus, human herpesvirus 6, and parvovirus were

negative. She had no findings of active systemic lupus erythematosus (SLE) such as malar rash, oral ulcers, arthritis, serositis, renal disorder, neurologic disorder, or immunologic disorder.

She was treated with intravenous methylprednisolone 1 g daily for 3 consecutive days followed by oral prednisolone 60 mg/day (1.0 mg/kg/day). Subsequently, she became afebrile. Her pancytopenia, elevated liver enzymes, and hyperferritinemia resolved within a few weeks. During the remainder of her pregnancy, the disease remained stable on tapering of the prednisolone dose. At 35 weeks' gestation, she delivered a healthy baby. Since then, she has been in remission for more than two years.

Discussion

This is the first case of DLE complicated with pregnancy-induced HPS, which was successfully treated with corticosteroids. This case suggests that DLE can be a predisposing factor for pregnancy-induced HPS.

Up to 28% of patients with DLE develop SLE (10), while 0.9-2.4% of patients with SLE develop HPS (11). We initially suspected that our case progressed from DLE to SLE developing HPS. However, she had no findings of active SLE and met neither the 2012 Systemic Lupus International Collaborating Clinics criteria nor the 1997 American College of Rheumatology classification criteria of SLE.

Among the 18 reported cases of HPS during pregnancy (2-8), 8 cases were associated with infections, 4 with autoimmune diseases (2 with SLE, 1 with adult-onset Still's disease, and 1 with autoimmune hemolytic anemia), and 1 with lymphoma. The remaining 5 cases had no clear underlying diseases. These facts suggest that patients with underlying diseases are prone to develop HPS during pregnancy. In our case, DLE and pregnancy likely acted as a predisposing factor and trigger of HPS, respectively.

In conclusion, physicians should be aware that DLE can be a predisposing factor for pregnancy-induced HPS.

Author's disclosure of potential Conflicts of Interest (COI).

Hitoshi Kohsaka: Honoraria, Ono Pharmaceutical Co., Ltd.; Research funding, Chugai Pharmaceutical Co., Ltd., Mitsubishi Tanabe Pharma Corporation, Ono Pharmaceutical Co., Ltd., Astellas Pharma Inc. and Eisai Co., Ltd.

References

- Ramos-Casals M, Brito-Zerón P, López-Guillermo A, Khamashta MA, Bosch X. Adult haemophagocytic syndrome. *Lancet* **383**: 1503-1516, 2014.
- Dunn T, Cho M, Medeiros B, Logan A, Ungewickell A, Liedtke M. Hemophagocytic lymphohistiocytosis in pregnancy: a case report and review of treatment options. *Hematology* **17**: 325-328, 2012.
- Kim JM, Kwok SK, Ju JH, et al. Macrophage activation syndrome resistant to medical therapy in a patient with systemic lupus erythematosus and its remission with splenectomy. *Rheumatol Int*

- 33: 767-771, 2013.
4. Klein S, Schmidt C, La Rosée P, et al. Fulminant gastrointestinal bleeding caused by EBV-triggered hemophagocytic lymphohistiocytosis: report of a case. *Z Gastroenterol* **52**: 354-359, 2014.
 5. Goulding EA, Barnden KR. Disseminated herpes simplex virus manifesting as pyrexia and cervicitis and leading to reactive hemophagocytic syndrome in pregnancy. *Eur J Obstet Gynecol Reprod Biol* **180**: 198-199, 2014.
 6. Pawar S, Ragesh R, Nischal N, Sharma S, Panda PK, Sharma SK. Unique triad of 'pregnancy, kala azar and hemophagocytic lymphohistiocytic syndrome from a non-endemic region'. *J Assoc Physicians India* **63**: 65-68, 2015.
 7. Tumian NR, Wong CL. Pregnancy-related hemophagocytic lymphohistiocytosis associated with cytomegalovirus infection: a diagnostic and therapeutic challenge. *Taiwan J Obstet Gynecol* **54**: 432-437, 2015.
 8. Samra B, Yasmin M, Arnaout S, Azzi J. Idiopathic hemophagocytic lymphohistiocytosis during pregnancy treated with steroids. *Hematol Rep* **7**: 6100, 2015.
 9. Henter JI, Horne A, Aricó M, et al. HLH-2004: Diagnostic and therapeutic guidelines for hemophagocytic lymphohistiocytosis. *Pediatr Blood Cancer* **48**: 124-131, 2007.
 10. Chong BF, Song J, Olsen NJ. Determining risk factors for developing systemic lupus erythematosus in patients with discoid lupus erythematosus. *Br J Dermatol* **166**: 29-35, 2012.
 11. Kim JM, Kwok SK, Ju JH, Kim HY, Park SH. Reactive hemophagocytic syndrome in adult Korean patients with systemic lupus erythematosus: a case-control study and literature review. *J Rheumatol* **39**: 86-93, 2012.

The Internal Medicine is an Open Access article distributed under the Creative Commons Attribution-NonCommercial-NoDerivatives 4.0 International License. To view the details of this license, please visit (<https://creativecommons.org/licenses/by-nc-nd/4.0/>).