

Effectiveness of sodium thiopentone, propofol, and etomidate as an ideal intravenous anesthetic agent for modified electroconvulsive therapy

ABSTRACT

Introduction: Electroconvulsive therapy (ECT) is a well-established psychiatric treatment in which seizures are electrically induced in patients for therapeutic effects. ECT can produce severe disturbances in the cardiovascular system and a marked increase in cerebral blood flow and intracranial pressure. These cardiovascular changes may be altered using various anesthetic drugs.

Aim and Objectives: This study was undertaken to compare the effects of intravenous (IV) sodium thiopentone, propofol, and etomidate, used as IV anesthetic agents in modified ECT as regards, induction time and quality of anesthesia, alteration of hemodynamics, seizure duration, and recovery time.

Materials and Methods: A total of 90 patients in the age group of 16–60 years of either sex, who had to undergo ECT therapy were divided randomly into three equal groups. Group A received propofol 1% - 1.5 mg/Kg, Group B received etomidate - 0.2 mg/Kg, and Group C received thiopentone 2.5% - 5 mg/Kg. All the patients were monitored for changes in heart rate, systolic blood pressure, diastolic blood pressure, and oxygen saturation at basal, after induction and 1 min, 2 min, 3 min, 5 min, 10 min, 20 min, and 30 min following ECT. Quality of anesthesia, seizure duration, and recovery times were also recorded.

Conclusion: We found that propofol had the advantage of smooth induction, stable hemodynamic parameters and rapid recovery as compared to etomidate and thiopentone. Thiopentone had the advantage over propofol of having longer seizure duration at the cost of a relatively prolonged recovery period. Etomidate had a definite advantage of longer seizure duration.

Key words: Cardiovascular effects, electro-convulsive therapy, etomidate, propofol, sodium thiopentone

Introduction

Electroconvulsive therapy (ECT) is a well-established psychiatric treatment in which seizures are electrically induced in anesthetized patients for therapeutic effects. ECT is most often used as a treatment for severe major depressive disorders with suicidal tendency, not responding

to treatment and is also used in the treatment of mania, catatonia, and schizophrenia.^[1] This technique has proved to be simple and replaced pharmacologically produced seizure therapy.^[2] The efficacy of ECT in alleviating acute depression is dependent on the duration of the induced seizure.^[3,4]

This is an open access article distributed under the terms of the Creative Commons Attribution-NonCommercial-ShareAlike 3.0 License, which allows others to remix, tweak, and build upon the work non-commercially, as long as the author is credited and the new creations are licensed under the identical terms.

For reprints contact: reprints@medknow.com

How to cite this article: Mir AH, Shah NF, Din MU, Langoo SA, Reshi FA. Effectiveness of sodium thiopentone, propofol, and etomidate as an ideal intravenous anesthetic agent for modified electroconvulsive therapy. Saudi J Anaesth 2017;11:26-31.

Access this article online

Website: www.saudija.org	Quick Response Code 
DOI: 10.4103/1658-354X.197339	

ALTAF HUSSAIN MIR, NIDA FAROOQ SHAH¹, MEHRAJ UD DIN, SHABIR AHMAD LANGOO¹, FAYAZ AHMAD RESHI

Department of Anaesthesiology, Government Medical College, ¹Department of Anaesthesiology and Critical Care, Sher-i-Kashmir Institute of Medical Sciences, Srinagar, Jammu and Kashmir, India

Address for correspondence: Dr. Nida Farooq Shah, H. No. 16, Rose Lane Buchpora, Srinagar - 190 011, Jammu and Kashmir, India.
E-mail: shahnida07@gmail.com

Electroencephalographic (EEG) seizure activity lasting from 25 to 50 s is alleged to produce the optimal antidepressant response. Patients experiencing an initial seizure duration of < 15 s or > 120 s achieve a less favorable response to ECT.^[5] Initially, lack of adequate anesthesia or muscle relaxation during ECT lead to bone fractures, dislocation of joints, biting of tongue, and tearing of muscle fibers. In addition, lack of knowledge about the dose parameters of the electric stimulation leads to more adverse cognitive effects.^[6,7] ECT can produce severe disturbances in the cardiovascular system, most commonly a transient period of hypertension and changes in the heart rate (HR).^[8] When an electrical current is applied to the brain, the resultant EEG spike and wave activity is accompanied by a generalized motor seizure and an acute cardiovascular response, which results in marked increase in cerebral blood flow and intracranial pressure.^[9] The hemodynamic response to ECT can produce myocardial ischemia and even infarction,^[10] as well as transient neurologic ischemic deficits, intracerebral hemorrhages, and cortical blindness.^[11,12] Due to trauma caused to the patient physically and psychologically with unmodified direct ECT in the past, it has now been modified with anesthesia.^[3,7] These cardiovascular changes may be altered using various anesthetic drugs and the violent muscular contractions occurring during the convulsions can be reduced by the use of muscle relaxants.^[8] This study was undertaken to compare the effects of intravenous (IV) sodium thiopentone, propofol, and etomidate, used as IV anesthetic agents in modified ECT as regards, induction time and quality of anesthesia, alteration of hemodynamics, seizure duration, and recovery time.

Materials and Methods

After approval from the Institutional ethical committee and written consent from the patient and relatives, the study was conducted in the department of anesthesiology at our Institute. A total of 90 patients in the age group of 16–60 years of either sex, who had to undergo ECT therapy were enrolled in the study. Patients with full stomach, neuromuscular disorders, hypertension and other cardiovascular disorders, epilepsy, hypopituitarism, drug allergy and major illnesses like bronchial asthma and tuberculosis, were excluded from the study. Patients were divided randomly into three equal groups, consisting of thirty patients each, Group A, Group B and Group C. Group A received propofol 1% - 1.5 mg/Kg, Group B received etomidate - 0.2 mg/Kg and Group C received thiopentone 2.5% - 5 mg/Kg. All the patients were kept fasting for 6 h and continued antipsychotic treatment until the day of the procedure (1 h before ECT).

After entering the procedure room, patients were attached to the baseline monitor for continuous monitoring of HR,

electrocardiogram, noninvasive blood pressure and oxygen saturation (SpO₂). An IV line was established, and all the patients were premedicated with IV glycopyrrolate 0.2 mg. Patients were preoxygenated with 100% oxygen for 3 min. General anesthesia was induced with IV anesthetic agent as per the group allocated, till loss of eyelid reflexes. IV succinylcholine 0.5 mg/kg was administered to all patients for neuromuscular relaxation. When fasciculations subsided and adequate neuromuscular relaxation was obtained, an adequate sized bite block was inserted to prevent tongue bite. A brief pulse stimulus for about 1–3 s, frequency 60–90 Hz and pulse width of 1 was given to produce seizures. Seizure duration was monitored by isolated limb method. Subsequently, all the patients were ventilated with face mask with 100% oxygen at a rate of 14–18 breaths/min until spontaneous breathing returned and patient recovered clinically from the state of anesthesia. All the patients were monitored for changes in HR, respiratory rate, systolic blood pressure (SBP), diastolic blood pressure (DBP), and SpO₂ at basal, after induction and 1 min, 2 min, 3 min, 5 min, 10 min, 20 min, and 30 min following ECT. Duration of recovery was recorded from injection of anesthetic agent to time taken to obey vocal commands such as opening of eyes, time for ability to sit unaided and time taken to meet discharge criteria. The collected data were analyzed statistically using one-way ANOVA test. The value of $P < 0.05$ was considered statistically significant.

Results

A total of ninety patients were selected for the study and were randomly divided into three groups of thirty patients each. All the groups were comparable with respect to age, weight, and sex. Of the thirty cases in Group A, 17 were males and 13 were females. In Group B, 14 were males and 16 were females, whereas in Group C, 16 were males and 14 were females. No statistical difference ($P > 0.05$) existed between the three groups as regards to sex distribution. The mean age of patients was 36 years in Group A, 33.8 years in Group B, and 36.2 years in Group C, respectively. Comparison between the three groups with respect to age distribution was statistically insignificant ($P > 0.05$). Mean weight of patients was 61.9 Kg in Group A, 52.13 Kg in Group B and 62.43 Kg in Group C, respectively. The difference was again statistically insignificant ($P > 0.05$) [Table 1].

Induction time

The mean induction time in Group A was 41.9 s, in Group B was 50.9 s whereas in Group C was 48 s. The difference in the induction times between the three groups was statistically significant ($P < 0.001$) [Table 2].

Incidence of side effects during induction

Induction was smooth in Group A compared to Group B and Group C. However, Group A had high incidence of pain on injection (17%) ($P < 0.0001$). Group B had high incidence of myoclonus (35%) ($P < 0.0001$) whereas Group C had higher incidence of cough (12%), tears (6%) and gag reflex (18%) ($P < 0.01$) [Figure 1].

Hemodynamic parameters

Heart rate

There was a significant change in HR from the baseline value in all the three groups, after the administration of ECT ($P < 0.05$). HR increased for up to 2 min after ECT, followed by a decreasing trend and reaching back to baseline values by the end of 10 min. However, with propofol there was less rise in HR compared to etomidate and thiopentone.

Mean systolic blood pressure

The SBP also had the similar variability as that of HR. There was an increase in mean SBP from baseline for up to 2 min and then declining back to baseline in 30 min. The variability was found to be statistically significant ($P < 0.05$), but it was

statistically highly significant in thiopentone and etomidate group. Propofol caused less rise in SBP.

Mean diastolic blood pressure

Like SBP, the mean DBP also showed statistically significant variability for up to 2 min following ECT ($P < 0.05$). However, it was statistically highly significant in thiopentone and etomidate group. Propofol caused less raise in DBP [Table 3].

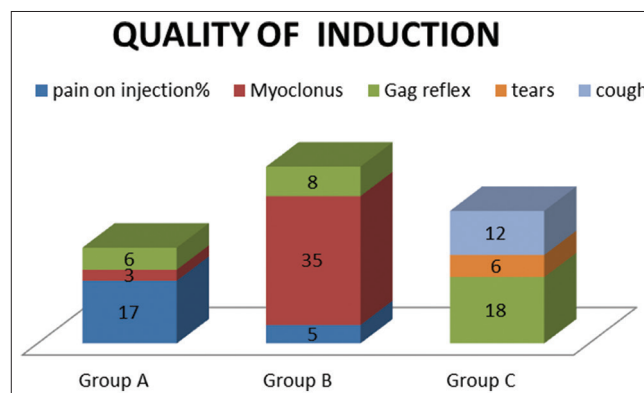


Figure 1: Incidence of side effects during induction in the three groups

Table 1: Age and weight distribution in three groups

Group	Number of cases, (n)	Age (in years)			Remarks	Weight (in kg)			Remarks
		Range	Mean±SD	P		Range	Mean±SD	P	
A	30	20-58	36±10.4	0.570	Not significant	48-76	61.9±6.5	0.94	Not significant
B	30	21-58	33.8±9.5			51-78	62.13±6.7		
C	30	21-56	36.2±9.06			50-76	62.43±5.8		

Group A: Propofol; Group B: Etomidate; Group C: Thiopentone; SD: Standard deviation

Table 2: Induction time and seizure duration in three groups

Group	Induction time (in seconds)					Seizure duration (in seconds)				
	Range	Mean±SD	P			Range	Mean±SD	P		
			A versus B	B versus C	A versus C			A versus B	B versus C	A versus C
A	35-48	41.9±3.5	<0.001	>0.05	<0.05	14-37	27.6±4.7	<0.0001	<0.0001	>0.05
B	45-55	50.9±4.2				43-85	56.5±9.6			
C	43-53	48±3.9				20-44	30.2±5.4			

Group A: Propofol; Group B: Etomidate; Group C: Thiopentone; SD: Standard deviation

Table 3: Comparing the hemodynamic parameters between the three groups

Time (min)	Mean±SD								
	Heart rate (beats/min)			Mean systolic blood pressure (mmHg)			Mean diastolic blood pressure (mmHg)		
	Group A	Group B	Group C	Group A	Group B	Group C	Group A	Group B	Group C
Pre-ECT	79.4±6.2	80.4±5.7	82±5.9	118.86±10.6	120.90±12.3	118.06±12.2	74.1±6.9	77.33±7.2	74.00±8.8
1	94±10.4	106±12.6	105±14.4	145.20±19.9	160.73±16.4	166.23±14.5	83.2±9.27	94.1±8.2	98±8.5
2	98±10.8	123±10.5	125±20.2	148.06±20.6	165.03±11.8	170.00±17.2	87±10.3	96.0±6.4	100±11.7
3	96±9.4	120±18.5	123±21.2	135.46±17.8	151.73±10.6	153.70±15.9	79.7±8.9	92.3±5.4	94±8.4
5	89.3±10	112±19.7	114±23.5	128.80±14.9	138.63±20.0	142.03±13.4	78.13±10.2	82.8±7.7	83.4±8.4
10	80.4±9.8	78.2±12	80±12.3	121.06±9.64	129.46±12.1	126.50±11.0	77.30±6.23	80.1±6.1	79.0±7.6
20	78±7.2	76.23±6.5	76±10	120.03±10.6	124.46±11.4	121.90±10.8	75±5.12	78.5±5.0	75.5±6.5
30	77±7.7	75.9±7.3	76.5±8.4	118.03±9.8	120.93±10.8	118.66±10.0	75.6±5.7	75.4±5.6	74.5±6.6

Group A: Propofol; Group B: Etomidate; Group C: Thiopentone; SD: Standard deviation

Seizure duration

Mean seizure duration was 27.6 s in Group A, 56.5 s in Group B and 30.2 s in Group C, respectively. Seizure duration was significantly shorter in propofol and thiopentone group as compared to etomidate group ($P < 0.0001$) [Table 2].

Recovery

The recovery of cognition, orientation, and neuromuscular coordination was significantly fast in propofol group ($P < 0.001$) followed by etomidate group and thiopentone group [Table 4 and Figure 2].

Discussion

ECT is a unique therapy that provokes seizure by applying an electrical current to the human central nervous system. ECT has a well-established role in the management of patients who have not responded to psychopharmacological treatment.^[13] The search for an ideal anesthetic agent for

ECT has been an ongoing process.^[14,15] The efficacy of ECT requires knowledge of anesthetic precepts, understanding of the interaction between anesthetic drugs and seizure activity, and awareness of the physiological effects of ECT as well as the treatment of those effects. The perfect induction agent for ECT would ensure rapid unconsciousness, less hemodynamic effects, minimal effects on seizure duration or amplitude, rapid recovery, and should be inexpensive.^[16]

Historically, because of its short duration of action and minimal effect on seizure threshold, methohexitone was considered the IV anesthetic of choice for ECT.^[17] Psychomotor functions recover more quickly after administration of methohexitone compared with thiopentone and etomidate.^[18]

This study compared propofol, etomidate, and thiopentone sodium as anesthetic agents for ECT. We found that the induction was rapid with propofol as compared to etomidate and thiopentone, which was statistically significant ($P < 0.001$). Induction time with propofol was 41.9 ± 3.5 s and that for thiopentone was 48 ± 3.9 s. This was comparable to the study conducted by Usha et al.,^[19] Arya et al.,^[20] and Omprakash et al.^[21] Induction time with etomidate was 50.9 ± 4.2 s, which was comparable to the study of Bergen et al.^[22] We also found that the induction was comparatively smooth with propofol ($P < 0.001$) compared to thiopentone and etomidate. Similar results were obtained by Usha et al.,^[19] Arya et al.,^[20] Omprakash et al.^[21] and Khalid et al.^[23]

The efficacy of ECT in alleviating acute depression is dependent on the duration of the induced seizure. EEG seizure activity lasting from 25 to 50 s is alleged to produce the optimal antidepressant response.^[3,4] Because many of the anesthetic drugs used for ECT have anticonvulsant properties, they would be expected to decrease the duration of ECT-induced seizure activity in a dose-dependent manner and could adversely affect the efficacy of the ECT treatment except etomidate which causes an increase in seizure duration.^[24] In this study, mean duration of seizure activity with propofol was 27.6 ± 4.7 s. Similar results were obtained by Bauer et al.^[25] We also observed that mean seizure duration with etomidate was 56.5 ± 9.6 s which was comparable to the study conducted by Avramov et al.,^[26] and that with thiopentone was 30.2 ± 5.4 s which was comparable to the results obtained by Usha et al.^[19] Mean seizure duration was found to be significantly longer ($P < 0.0001$) for the etomidate group as compared to the propofol and thiopentone group.

The mechanism of the cardiovascular disturbances during ECT is the result of intense stimulation of the autonomic nervous

Table 4: Comparison between the recovery times in the three groups

	Group	Time range (in min)	Mean±SD	P
Consciousness	A	5.5-9	6.5 ± 0.28	Group A versus B <0.001
	B	7-10.5	7.5 ± 0.32	
	C	7.2-10.9	8.2 ± 0.70	
Obey command	A	6-9.5	7.1 ± 0.32	Group A versus C <0.001
	B	7.5-10.4	9.1 ± 0.37	
	C	8.2-11	10.3 ± 0.52	
Orientation	A	7.8-9.8	8.9 ± 0.26	Group B versus C >0.05
	B	9-13.4	11.7 ± 0.39	
	C	10-13.8	12.12 ± 0.53	
Ability to sit unaided	A	10-14.5	11.56 ± 0.40	
	B	10.4-16.8	13.6 ± 0.20	
	C	12-18.4	14.4 ± 0.66	
Time taken to meet discharge criteria	A	12.5-18.7	14.25 ± 0.56	
	B	13.6-19.6	16.5 ± 0.70	
	C	14-21.4	16.9 ± 0.76	

Group A: Propofol; Group B: Etomidate; Group C: Thiopentone; SD: Standard deviation

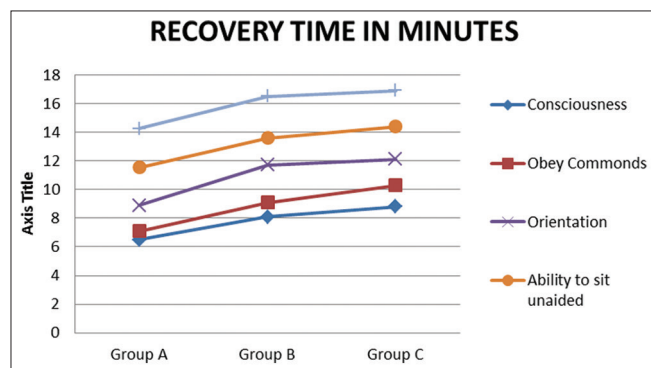


Figure 2: The recovery time in the three groups (Group A = propofol, Group B = etomidate, Group C = thiopentone)

system and a large increase in circulating catecholamines. In patients with severe cardiovascular disease, acute increases in arterial pressure and/or HR may be hazardous, and indeed, the most common causes of mortality following ECT are myocardial infarction and ventricular dysrhythmias.^[27] During our study, we found that increase in the systemic arterial pressure following ECT, with propofol, was comparatively less than that with etomidate and thiopentone. Change in the mean SBP, in propofol group, was 25–30 mmHg above the preinduction value in the first 2 min and reached to the preinduction value at 30 min. With etomidate, mean SBP increased by 40–45 mmHg above the preinduction value in the first 2 min while with thiopentone, change in the mean SBP was 45–50 mmHg above the baseline value in the first 2 min. Propofol also caused a little increase in mean DBP (compared to etomidate and thiopentone), with the mean change being around 9–13 mmHg above the preinduction value in the first 2 min. With etomidate, the mean DBP increased by 15–20 mmHg above the preinduction value in first 2 min and with thiopentone, an increase of 24–26 mmHg was observed. HR changes following propofol was significantly lower than that following etomidate and thiopentone in first 2 min of ECT. The mean change in HR after ECT varied from 40 to 45 beats/min above preinduction values with etomidate and thiopentone. While with propofol the HR change was 15–18 beats/min above the pre-induction values in the first 2 min followed by a decrease in the HR over the next 10 min. The significant rise in HR after ECT with thiopentone and etomidate as compared to propofol was also noted by Boey and Lai,^[28] Arya *et al.*^[20] and Singhal *et al.*^[29] Dwyer *et al.*^[30] and Rampton *et al.*^[31] compared propofol and methohexitone for ECT and found a similar cardiovascular response with the administration of propofol. The increase in HR, SBP, and DBP after ECT was observed in all the three groups but it was statistically highly significant in thiopentone group and etomidate group. Propofol blunt the sympathetic response, so there was less increase in HR, SBP, and DBP. In this study propofol seemed superior to thiopentone and etomidate in attenuating the physiological response to ECT with minimal hemodynamic changes. No dysrhythmias were seen during ECT, in our study.

Although all the three drugs used in this study showed a very short time for recovery, the best one was propofol ($P < 0.001$). This correlates well with the study conducted by Rosa *et al.*^[32] Clinical superiority for practical purposes could not be proved, as time differences detected were around only about 2 min between drug groups. An important point is that higher charges given are commonly associated with more frequent post-ictal confusion. The significantly higher mean charge used with propofol did not prevent it to show the best post anesthetic recovery profile.

Conclusion

The present study concluded that there were individual advantages of all three inducing agents over one another when the study parameters were individualized. Propofol had the advantage of smooth induction, stable hemodynamic parameters, and rapid recovery as compared to etomidate and thiopentone. However it was associated with shorter seizure duration. Thiopentone sodium had the advantage over propofol of having longer seizure duration at the cost of a relatively prolonged recovery period. Etomidate had a definite advantage of a longer seizure duration which could be used for better clinical efficacy over thiopentone sodium and propofol. However it was associated with myoclonic jerks during induction.

There was no clear advantage of any drug over another when all the study parameters were considered. Further studies should be designed to use a combination of drugs so that optimal effects of each drug can be judiciously used.

Financial support and sponsorship

Nil.

Conflicts of interest

There are no conflicts of interest.

References

1. Scott AI. The ECT Handbook. 2nd ed. The Third Report of the Royal College of Psychiatrists' Special Committee on ECT. London: Royal College of Psychiatrists; 2008. p. 7-26.
2. Chanpattana W. The origins of electroconvulsive therapy. *J Psychiatr Assoc Thailand* 2000;45:371-80.
3. Thompson JW, Weiner RD, Myers CP. Use of ECT in the United States in 1975, 1980, and 1986. *Am J Psychiatry* 1994;151:1657-61.
4. Weiner RD. American Psychiatric Association Committee on Electroconvulsive Therapy. *The Practice of Electroconvulsive Therapy: Recommendations for Treatment, Training, and Privileging: A Task Force Report of the American Psychiatric Association*. Washington, DC: American Psychiatric Association; 2001.
5. Sackeim HA, Devanand DP, Prudic J. Stimulus intensity, seizure threshold, and seizure duration: Impact on the efficacy and safety of electroconvulsive therapy. *Psychiatr Clin North Am* 1991;14:803-43.
6. Nott MR, Watts JS. A fractured hip during electro-convulsive therapy. *Eur J Anaesthesiol* 1999;16:265-7.
7. Ekinci M, Hsu JJ, Bruck M, Braun RA. Diazepam as an anti-convulsant agent in ECT. *Am J Psychiatry* 1964;120:903-4.
8. Painuly N, Chakrabarti S. Combined use of electroconvulsive therapy and antipsychotics in schizophrenia: The Indian evidence. A review and a meta-analysis. *J ECT* 2006;22:59-66.
9. Saito S, Miyoshi S, Yoshikawa D, Shimada H, Morita T, Kitani Y. Regional cerebral oxygen saturation during electroconvulsive therapy: Monitoring by near-infrared spectrophotometry. *Anesth Analg* 1996;83:726-30.
10. López-Gómez D, Sánchez-Corral MA, Cobo JV, Jara F, Esplugas E. Myocardial infarction after electroconvulsive therapy. *Rev Esp Cardiol* 1999;52:536.

11. Weisberg LA, Elliott D, Mielke D. Intracerebral hemorrhage following electroconvulsive therapy. *Neurology* 1991;41:1849.
12. Rikher KV, Johnson R, Kamal M. Cortical blindness after electroconvulsive therapy. *J Am Board Fam Pract* 1997;10:141-3.
13. Dexter F, Macario A, Cowen DS. Staffing and case scheduling for anesthesia in geographically dispersed locations outside of operating rooms. *Curr Opin Anaesthesiol* 2006;19:453-8.
14. Ostwald P, Doenicke AW. Etomidate revisited. *Curr Opin Anaesthesiol* 1998;11:391-8.
15. Doenicke AW, Roizen MF, Kugler J, Kroll H, Foss J, Ostwald P. Reducing myoclonus after etomidate. *Anesthesiology* 1999;90:113-9.
16. Folk JW, Kellner CH, Beale MD, Conroy JM, Duc TA. Anesthesia for electroconvulsive therapy: A review. *J ECT* 2000;16:157-70.
17. O'Flaherty D, Giesecke AH. Electroconvulsive therapy and anesthesia. *Curr Opin Anesthesiol* 1991;4:436-40.
18. Korttila K, Linnoila M, Ertama P, Häkkinen S. Recovery and simulated driving after intravenous anesthesia with thiopental, methohexital, propofol, or alphadione. *Anesthesiology* 1975;43:291-9.
19. Usha D, Vinod K. Comparison of thiopentone and propofol as better anaesthetic agent for modified electroconvulsive therapy. *Asian J Pharm Clin Res* 2012;5:227-3.
20. Arya A, Singh M, Gurwara AK. A comparison of thiopentone sodium, propofol and midazolam for electroconvulsive therapy. *J Anesthesia Clin Pharmacol* 2008;24:291-4.
21. Omprakash TM, Ali MI, Anand B, Devi MG, Surender P. Comparison of thiopentone sodium and propofol in ECT anesthesia. *Indian J Psycho Med* 2008;30:48-50.
22. Bergen JM, Smith DC. A review of etomidate for rapid sequence intubation in the emergency department. *J Emerg Med* 1997;15:221-30.
23. Khalid N, Atkins M, Kirov G. The effects of etomidate on seizure duration and electrical stimulus dose in seizure-resistant patients during electroconvulsive therapy. *J ECT* 2006;22:184-8.
24. Ding Z, White PF. Anesthesia for electroconvulsive therapy. *Anesth Analg* 2002;94:1351-64.
25. Bauer J, Hageman I, Dam H, Báez A, Bolwig T, Roed J, *et al.* Comparison of propofol and thiopental as anesthetic agents for electroconvulsive therapy: A randomized, blinded comparison of seizure duration, stimulus charge, clinical effect, and cognitive side effects. *J ECT* 2009;25:85-90.
26. Avramov MN, Husain MM, White PF. The comparative effects of methohexital, propofol, and etomidate for electroconvulsive therapy. *Anesth Analg* 1995;81:596-602.
27. Uppal V, Dourich J, Macferlane A. Anesthesia for ECT. *Contin Educ Anesth Crit Care Pain* 2010;10:192-6.
28. Boey WK, Lai FO. Comparison of propofol and thiopentone as anaesthetic agents for electroconvulsive therapy. *Anaesthesia* 1990;45:623-8.
29. Singhal SK, Dey N, Bhardwaj M, Malhotra N, Gupta R, Thakur A. Comparison of propofol and thiopentone sodium as induction agents for modified electroconvulsive therapy. *J Anesth Clin Pharmacol* 2002;18:393-6.
30. Dwyer R, McCaughey W, Lavery J, McCarthy G, Dundee JW. Comparison of propofol and methohexital as anaesthetic agents for electroconvulsive therapy. *Anaesthesia* 1988;43:459-62.
31. Rampton AJ, Griffin RM, Stuart CS, Durcan JJ, Huddy NC, Abbott MA. Comparison of methohexital and propofol for electroconvulsive therapy: Effects on hemodynamic responses and seizure duration. *Anesthesiology* 1989;70:412-7.
32. Rosa MA, Rosa MO, Belegarde IM, Bueno CR, Fregni F. Recovery after ECT: Comparison of propofol, etomidate and thiopental. *Rev Bras Psiquiatr* 2008;30:149-51.