



Hemadsorption as rescue therapy for patients with multisystem organ failure in pediatric intensive care—Report of two cases reports and review of the literature

Lisa-Maria Steurer¹  | Gerald Schlager¹ | Kambis Sadeghi¹ | Johann Golej¹ | Dominik Wiedemann² | Michael Hermon¹

¹Division of Neonatology, Pediatric Intensive Care & Neuropediatrics, Department of Pediatric and Adolescent Medicine, Medical University of Vienna, Vienna, Austria

²Department of Cardiac Surgery, Medical University of Vienna, Vienna, Austria

Correspondence

Michael Hermon, Comprehensive Center for Pediatrics, Division of Neonatology, Pediatric Intensive Care & Neuropediatrics, Department of Pediatric and Adolescent Medicine, Medical University of Vienna, Währinger Gürtel, 1090 Vienna, Austria.
Email: michael.hermon@meduniwien.ac.at

Abstract

Hemadsorption via the cytokine-adsorber CytoSorb (CytoSorbents Europe, Berlin, Germany) has successfully been used as an adjunctive method in adults, mainly for the purpose of immunomodulation under acute inflammatory conditions such as sepsis and cardiac surgery. In recent years, there has been growing interest in its use in pediatric intensive care to improve outcomes in patients with multiple organ failure following an inflammatory illness. Literature on the application of CytoSorb in neonatal and pediatric patients is scarce, though the implication is that it could be an effective last-resort treatment option in critically ill pediatric patients. Herein we present the clinical cases of two pediatric patients successfully treated with a combination of the CytoSorb hemadsorber, continuous renal replacement therapy, and extracorporeal membrane oxygenation due to multiple organ failure following different underlying medical conditions. Patient 1 was a 7-month-old male child with Down's syndrome admitted to the Pediatric Intensive Care Unit (PICU) after congenital heart surgery, who developed antimicrobial-resistant septic shock and severe acute respiratory distress syndrome. Patient 2 was a 2-year-old male child admitted to the PICU with influenza A-associated acute liver failure resulting in hyperammonemia, lactate acidosis, hemodynamic instability, and acute kidney failure. In both patients, hemadsorption with CytoSorb was initiated as an adjunctive rescue therapy to treat refractory multisystem organ failure. Improvement of laboratory and clinical parameters was observed within hours of treatment initiation. The application of the hemadsorber—developed for use in adults—proved simple and safe for use in both of our low-weight pediatric patients.

KEYWORDS

blood purification, CytoSorb, hemadsorption, liver failure, multiple organ failure, pediatric acute respiratory distress syndrome, septic shock

This is an open access article under the terms of the Creative Commons Attribution-NonCommercial License, which permits use, distribution and reproduction in any medium, provided the original work is properly cited and is not used for commercial purposes.

© 2021 The Authors. *Artificial Organs* published by International Center for Artificial Organ and Transplantation (ICAOT) and Wiley Periodicals LLC.



1 | INTRODUCTION

The use of extracorporeal blood purification methods for immunomodulation under acute inflammatory conditions following infectious and noninfectious origins has evolved in recent years.^{1,2} CytoSorb (CytoSorbents Europe, Berlin, Germany, approved in 2011 in Europe) is, to date, the only CE-certified hemadsorber for use in patients with severe cytokinaemia.³ The device consists of a cartridge filled with biocompatible porous polymer beads with a mean diameter of 450 μm . The overall adsorption surface of 1 adsorber cartridge column is $>45\,000\text{ m}^2$. Hydrophobic molecules of up to 55 kDa, mainly cytokines and a broad selection of inflammatory mediators (eg, chemokines, DAMPs, PAMPs), as well as other toxins, drugs, and substances such as myoglobin, bilirubin, and ammonia, are irreversibly captured, bound to the adsorber beads and eliminated from the bloodstream.⁴ Cytosorb has thus been successfully used for different clinical conditions such as liver failure, pancreatitis, burns and trauma, intoxications, and rhabdomyolysis, though the main indications are the treatment of septic shock and hyperinflammation following cardiac surgery.^{1,5}

The CytoSorb hemadsorber has been proven to be effective in reducing cytokine levels as well as the risk of organ failure and mortality in multiple preclinical studies using animal models of sepsis.^{6,7} Because of its approval, CytoSorb's safety profile has been tested in several thousand clinical cases. However, clear evidence of its efficacy via large randomized controlled trials is, to date, unavailable.^{1,8,9}

Clinical experience with CytoSorb in pediatric patients is limited to several case reports and one small case series. Since scientific literature about the use of CytoSorb and blood purification in children, in general, is scarce, its use is still experimental, poses potential risks to pediatric patients, and requires a high level of expertise of the responsible pediatric intensivists.

Herein, we present case reports of the successful application of hemadsorption with CytoSorb in two pediatric patients with body weights under 15 kg.

Written informed consent for publishing these case reports was signed by the patients' legal guardians and approval was obtained from the local ethics committee at the Medical University of Vienna.

2 | CASE REPORTS

2.1 | Patient 1

A 7-month-old, 7 kg male child with Down's syndrome and congenital heart disease (coarctation of the aorta and atrioventricular septal defect [AVSD]) was admitted to the Department of Pediatrics and Adolescent Medicine of the

Medical University of Vienna for elective cardiac surgery in June 2019. Aortic coarctation repair with resection, end-to-end anastomosis, and pulmonary artery banding had already been performed on the third day of life. Hospital readmission was necessary for elective AVSD correction and debanding, which was performed without complications. After initial extubation and transfer to the pediatric cardiology IMC ward on Day 4 after cardiac surgery, the patient had to be retransferred to the ICU and reintubated due to respiratory decompensation 2 days later. After treatment of atelectasis and of bilateral chylothorax, the patient was again weaned from mechanical ventilation 3 days later by means of a high-flow nasal cannula. Postoperative C-reactive protein (CRP) elevation without clear focus necessitated antibiotic therapy with Cefuroxime. Antibiotic treatment was stopped after normalization of inflammation parameters on Day 12 after surgery. The following day, the infant became febrile, developed dyspnea, and had a pale complexion (Day 1 of sepsis, D1). Laboratory testing revealed elevated inflammation parameters (IL-6 $>50\,000\text{ pg/mL}$, CRP 8.3 mg/dL) and pancytopenia (thrombopenia $45\,000/\mu\text{L}$, hemoglobin (Hb) 9.9 g/dL , hematocrit (Ht) 29.6% , leucopenia $1900/\mu\text{L}$) substantiating the clinical suspicion of gram-negative sepsis. After a complete septic workup, antibiotic treatment was initiated with Piperacillin/Tazobactam, Gentamicin, and Vancomycin. Blood culture results were available within 6 hours after treatment initiation and revealed *Enterobacter cloacae complex* and *Staphylococcus epidermidis*. Therefore, Piperacillin/Tazobactam was switched to Meropenem. Antimicrobial treatment was further escalated to Ciprofloxacin and Linezolid because of drastically increasing inflammation parameters and clinical deterioration. Fluconazole was added empirically and Pentaglobin and Pentoxifyllin were administered as adjuvant sepsis therapy.

Although both identified pathogens were sensitive to the administered antibiotics according to antimicrobial susceptibility testing, inflammation parameters further increased and the treatment was unable to prevent the patient's continuing hemodynamic deterioration. He developed septic shock, requiring catecholamines and reintubation. Fresh frozen plasma, erythrocytes, and platelets were substituted as necessary and granulocyte-colony stimulating factor was administered to treat neutropenia. The patient's hemodynamic and respiratory situation gradually worsened (Sequential Sepsis-related Organ Failure Score [SOFA] score 20, increasing lactate 4.6 mmol/L). Severe acute respiratory distress syndrome (ARDS) was diagnosed and treated according to PALICC recommendations, including the use of elevated positive end-expiratory pressure of 12 mm Hg, prone position, corticosteroids, and surfactant administration. Venoarterial-extracorporeal membrane oxygenation (VA-ECMO) support became necessary on Day 3 of sepsis following progressive



lung failure in accordance with pediatric ARDS guidelines, with an oxygenation index (OI) of 50 and a paO_2/FiO_2 ratio of 60 mm Hg.

Due to increasing anasarca following the capillary leak and deteriorating renal function, continuous renal replacement therapy (CRRT) in the continuous veno-venous hemodiafiltration (CVVHDF) modality was initiated to improve the patient's fluid balance. CRRT was performed using a blood-primed HF60 membrane of the Prismaflex System (Prismaflex, Baxter Healthcare, Vienna, Austria) connected to the ECMO circuit, parallel to the pump (shown in Figure 1). The decision to commence hemadsorption with CytoSorb was made as an adjunctive, last-resort treatment modality due to the ongoing septic inflammation. The adsorber was primed with 150 mL of erythrocytes and fresh frozen plasma (1:1) and inserted in the CRRT circuit, in series with the hemofilter in a postfilter position. The patient received a continuous

infusion of unfractionated heparin sodium to keep postfilter activated clotting time between 160 and 180 seconds. Blood flow was maintained at 100–150 mL/min, and the same adsorption column remained in place for 40 hours.

Under combined treatment with ECMO, CVVHDF, and CytoSorb, rapid clinical stabilization was achieved in terms of the improved respiratory situation, hemodynamics, and laboratory parameters (shown in Table 1). Moreover, SOFA scores declined markedly. After the first 12 hours of CytoSorb application, there was a pronounced drop in IL-6, procalcitonin (PCT), and CRP. The patient required only half the amount of vasopressor support compared with levels before initiation of therapy, and catecholamines were discontinued after 40 hours of combined CytoSorb, continuous CVVHDF, and ECMO treatment. With increasing urine output, hemodiafiltration was only necessary for a further 8 hours, and ECMO support was discontinued after a total of 10 days of

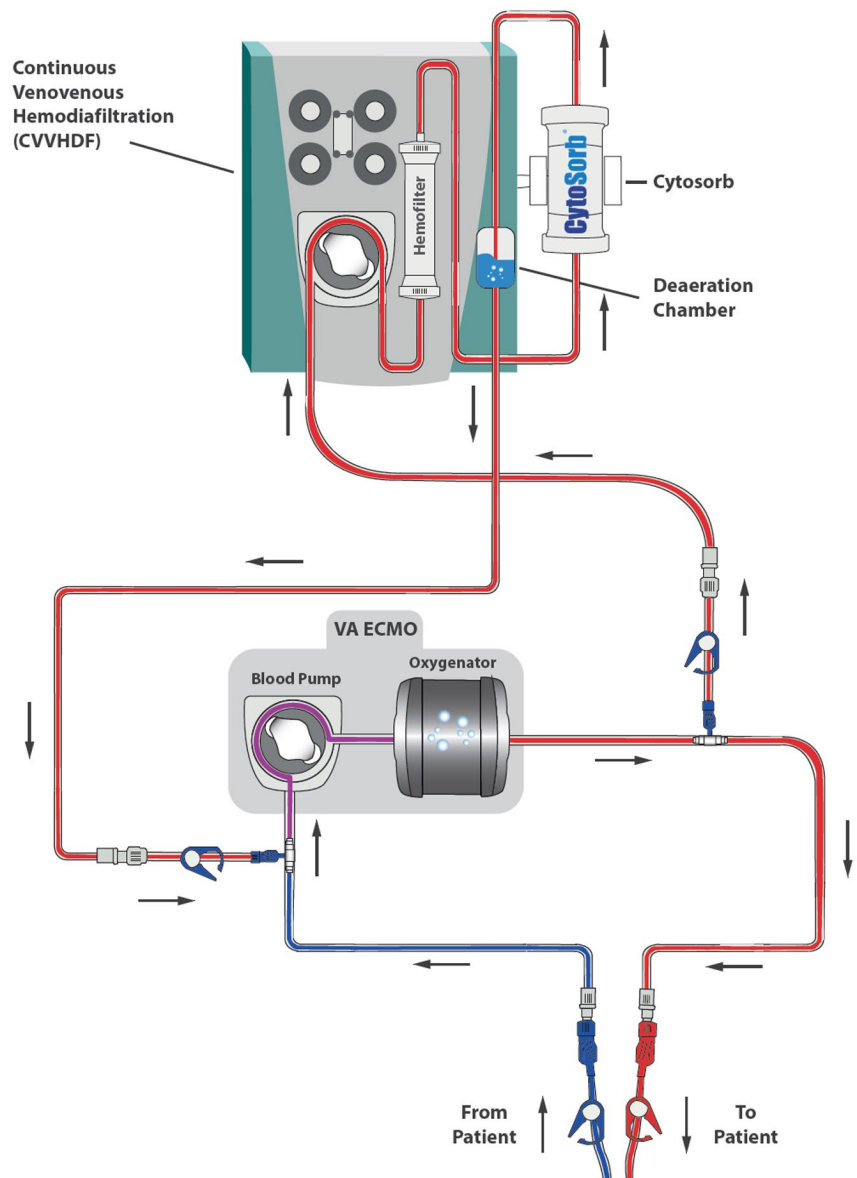


FIGURE 1 Connection of CytoSorb into standard CRRT (CVVHDF) circuit in postpump position, connected in parallel into standard VA-ECMO circuit (Patient 1) [Color figure can be viewed at wileyonlinelibrary.com]

**TABLE 1** Summary of hemodynamic and respiratory variables and inflammation parameters before, during, and after combined treatment with CytoSorb (CS)/CVVHDF/ECMO (Patient 1)

	Before treatment initiation	12 hours CS/CVVHDF/ECMO	24 hours CS/CVVHDF/ECMO	End of CS treatment (40 hours)
CRP mg/dL	42	11	/	8
IL6 pg/mL	640	335	/	77
PCT ng/mL	41	3.4	/	1.8
Norepinephrine $\mu\text{g}/\text{kg}/\text{min}$	0.35	0.17	0.05	0
Lactate mmol/L	4.6	3.8	2.7	3.0
UPR mL/kg/h	2.2	/	/	13
SOFA score	20	16	14	8
FiO ₂ %	100	40	35	25
Pmax mbar	34	25	23	27
OI (MAP \times FiO ₂ /PaO ₂) \times 100	51	9	2.2	2.7

treatment. The patient was successfully weaned from mechanical ventilation 2 weeks later. After an additional 14 days of noninvasive respiratory support (NIV-PC, NIV-NAVA), the patient was discharged from the PICU and transferred to the pediatric cardiology IMC ward. The patient was finally discharged home 2 weeks later in good clinical condition and with normal lung function.

2.2 | Patient 2

The 22-month-old male child of consanguineous parents weighing 14 kg presented at the pediatric emergency department in March 2019 with a history of fever (39°C), cough, diarrhea, and vomiting for 2 days.

The patient's past medical history included 2 previous episodes of acute liver failure following febrile infection (November 2017 and February 2018), during which he developed toxic encephalopathy with subsequent symptomatic epilepsy and psychomotor retardation. Previous diagnostic workups including whole-exome sequencing, congenital disorder of glycosylation diagnostics, and inborn errors of metabolism had been inconclusive. Family history revealed that the patient's brother had recently died from infection-associated acute liver failure, and likewise, extensive testing had to be unable to show a causative medical condition.

Upon presentation (D1), the patient appeared unwell, with altered consciousness, tachycardia (158/min), and mild jugular retractions. Capillary blood gas analysis revealed uncompensated metabolic acidosis (pH 7.12, pCO₂ 25 mm Hg, HCO₃ 9.8 mmol/L, BE -19.8 mmol/L, lactate 14.7 mmol/L) and hypoglycemia (22 mg/dL). The patient was immediately admitted to the PICU where he was intubated and subsequently mechanically ventilated. Hemodynamic instability (RR 83/31 (45) mm Hg) required initiation of vasoactive treatment with noradrenaline. Hypoglycemia was treated

with intravenous dextrose 20% and did not reoccur under continuous iv administration.

Upon admission (D1), CBC showed leukocytosis (19.08 G/L), and normocytic, normochromic, hypo-regenerative anemia (Hb 10.2 g/dL, Ht 31.5%, reticulocytes 0.69%). Biochemical laboratory results revealed abnormal liver function tests (AST 2297 U/L, ALT 633 U/L, GGT 94 U/L, total bilirubin 2.4 mg/dL) and mild hyperammonemia (135 $\mu\text{mol}/\text{L}$). Coagulation tests showed pathologic levels of INR (2.6) and TPZ (19%), and hypofibrinogenemia (125 mg/dL), while single factor analysis demonstrated markedly reduced activity of factors II, V, VII, VIII, IX, and X.

Management included continuous administration of TRIS buffer solution, repeated administration of fresh frozen plasma and erythrocyte concentrates, and initiation of treatment with L-arginine and sodium-benzoate following increasing hyperammonemia (max. 536 $\mu\text{mol}/\text{L}$). Antibiotic therapy with Cefotaxim and Vancomycin was initiated due to elevated inflammatory parameters (CRP 2.81 mg/dL, IL-6 393.6 pg/mL, PCT 5.25 ng/mL). Viral testing was positive for influenza A, and Oseltamivir was administered from D1 to D7. Blood cultures as well as PCR analysis taken from tracheal secretions and urine were repeatedly negative, despite the growth of *Candida albicans* in tracheal secretions on D7.

Under this therapeutic management, hyperammonemia, lactate acidosis, and inflammation parameters decreased; but due to worsening hemodynamic instability, the patient began to require epinephrine in combination with norepinephrine. Additionally, he developed acute kidney failure (creatinine 2.05 mg/dL, BUN 33.3 mg/dL, anuria). Consequently, CVVHDF (Prismaflex, Baxter) was commenced (D5) after inserting a hemodialysis catheter into the right external jugular vein. Throughout CVVHDF, hypotension and bradycardia continued, with the patient requiring increasing doses of inotropic agents and vasopressors. In addition, bilirubin levels increased dramatically (up to 26 mg/dL), so the decision was



made to start adjunctive treatment with the CytoSorb hemadsorber (D11-D12 and D13-D14). The cartridge column was primed with 150 mL erythrocyte concentrate and 5% albumin solution in a 1:1 ratio and inserted into the CRRT circuit in series in a postfilter position (shown in Figure 2). The patient received unfractionated heparin sodium for anticoagulation. Blood flow was maintained between 100 and 150 mL/min and the adsorber column was exchanged after 24 hours as recommended by the manufacturer. Within the first 12 hours after CytoSorb initiation, bilirubin levels dropped from 26.2 to 6.6 mg/dL. After 2 treatment courses of 24 hours each, the patient's hemodynamic and respiratory situation improved (summarized in Table 2). Catecholamine support was suspended and, as urinary output normalized, discontinuation of CVVDHF was possible on D15. The patient's respiratory situation increased dramatically under CytoSorb treatment, both in terms of lower oxygen requirement and also under gradually decreased inspiratory pressure. Weaning from mechanical ventilation was well-tolerated and he was extubated on D19. He was transferred from ICU on D29 and discharged home after 8 more weeks in a stable clinical condition with normal liver function tests.

3 | DISCUSSION

In these reported cases, we used the CytoSorb hemadsorber as an adjunctive last-resort treatment option for pediatric intensive care patients with multisystem organ failure, although to date its use in children has been experimental.

Patient 1 was an infant with therapy refractory septic shock and severe ARDS requiring ECMO and CRRT. The

underlying condition of Down's syndrome with congenital heart disease requiring cardiac surgery made the overall situation very challenging. In combination with inadequate response to standard therapy and persistently high serum levels of inflammatory parameters despite an appropriate sixfold antibiotic regimen, mortality risk was high. This was underlined by our patient's OI of 51; mortality risk for pARDS when OI exceeds 16 has been reported at 40%,¹⁰ while predicted mortality with a pediatric SOFA score of 20 is estimated at 50%.¹¹

Combined treatment with VA-ECMO, CVVHDF, and hemadsorption with Cytosorb led to a decrease of CRP, PCT, and IL-6 levels within hours of therapy initiation, accompanied by a significant improvement in hemodynamic status as indicated by stabilized blood pressure, increasing urine output, and reduced lactate levels in our patient. Moreover, the need for platelet replacement and other blood products decreased.

The rationale for use of CytoSorb in sepsis and septic shock is to filter excessively released pro-inflammatory and anti-inflammatory mediators from the bloodstream. This may theoretically restore immuno-homeostasis, mitigate a "cytokine storm," and reduce life-threatening organ dysfunction caused by a dysregulated host response to infection.¹²⁻¹⁶ It has been shown that mortality in sepsis is highest when both pro-inflammatory and anti-inflammatory cytokine levels are highest.¹⁷

Similar to the pathogenesis of sepsis and septic shock, pathogen-associated and damage-associated molecular patterns (PAMPs and DAMPs), that are released by infection or necrosis, are also thought to be involved in the development of acute-on-chronic liver failure.^{18,19} These molecules

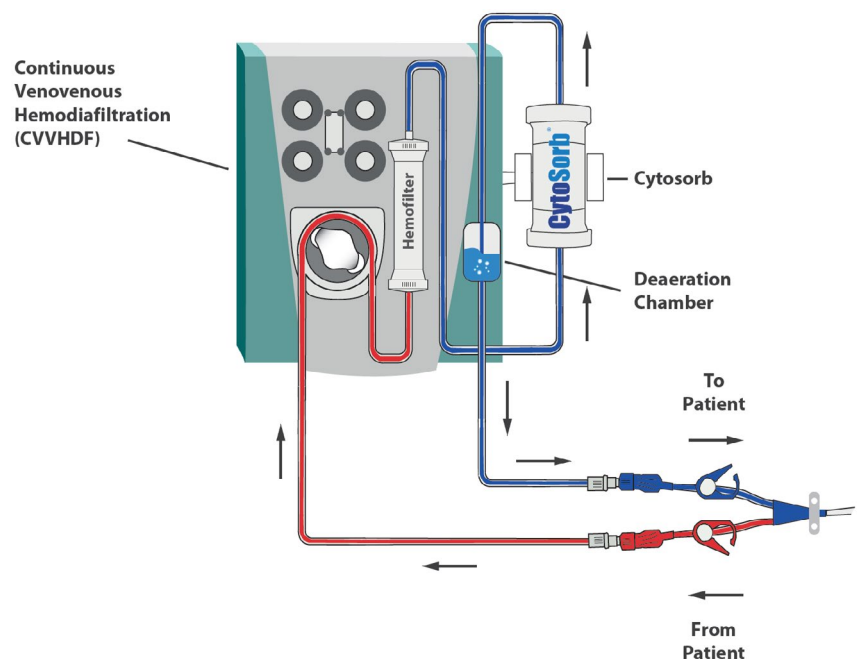


FIGURE 2 Connection of CytoSorb into standard CRRT (CVVHDF) circuit in postpump position (Patient 2) [Color figure can be viewed at wileyonlinelibrary.com]

**TABLE 2** Summary of hemodynamic and respiratory variables and laboratory parameters (Patient 2)

	Admission	Before CVVHDF	Before CS	After 12 hours CS	After 24 hours CS	After CS	2 days after end of treatment	Discharge PICU
Ammonia $\mu\text{mol/L}$	135	333	86	93	43	98	48	38
AST U/L	2297	1215	120	69	95	137	157	128
ALT U/L	633	122	27	10	32	28	37	61
GGT mg/dL	94	46	43	/	22	22	46	1236
LDH U/L	8606	1449	1753	/	1133	700	1012	446
Bilirubin mg/dL	2.4	4.8	26.2	6.6	8.8	5.3	13.4	6.6
Creatinine mg/dL	0.71	2.05	0.28	/	0.34	0.34	0.65	<0.15
BUN mg/dL	19.6	33.3	6.0	/	5.7	10.9	59	16.6
UPR mL/kg/h	3.07	0.27	0.3	0.20	0.05	1.79	4.11	4.7
Lactate mmol/L	17.0	6.0	3.7	4.6	3.8	2.7	2.6	1.7
Pmax mbar	20	36	34	29	28	17	24	/
FiO ₂ %	0.4	100	0.45	0.25	0.25	0.3	0.3	0.4
Norepinephrine $\mu\text{g/kg/min}$	0.14	0.357	0.06	0.1	0.06	0.01	0	0
Epinephrine $\mu\text{g}/$ kg/min	0	0.119	0	0	0	0	0	0
CRP mg/dL	2.9	0.7	2.8	2.18	4.2	1.5	4.6	0.5
IL6 pg/mL	331	74.0	550	90	46.4	28.8	328	14.6
PCT ng/mL	5.6	/	0.81	0.35	/	/	2.3	0.65

seem to trigger an excessive inflammatory response that causes organ failure.²⁰ CytoSorb hemadsorption removes PAMPs and DAMPs from the bloodstream and might thereby potentially reduce organ damage. Based on these considerations, CytoSorb was applied for Patient 2 who suffered from infection-triggered acute liver failure.

Our findings are in line with previously published data on CytoSorb application in the case of sepsis and septic shock, although literature pertaining specifically to the pediatric population is scarce. Moreover, existing data in adults are mainly based on retrospective analyses and case series and results are partly conflicting.^{1,2,21}

After several *in vivo* and *ex vivo* animal studies, numerous case reports and case series showed hemodynamic stabilization in septic patients combined with a reduction of circulating cytokines and chemokines, and a potential improvement of clinical outcomes was postulated.^{1,2,6,7} An international registry on the use of CytoSorb published by Friesecke et al included data from 198 ICU patients from 22 different countries.²² Results showed that sepsis was the most common indication for CytoSorb use. The authors reported reduced observed mortality of 65% versus the predicted risk of death of 78% according to APACHE II scores and reduced IL6 levels after treatment (median 5000 pg/mL before and 289 pg/mL after treatment). However, there was no significant decrease in SOFA scores after treatment. More recently, Paul et al performed a multicentered observational study that

prospectively analyzed CytoSorb treatment along with the standard of care in 45 septic patients and found a 52% reduction in IL-6 levels, significant improvement of sepsis scores (SOFA, APACHE II), and a reduced actual versus predicted mortality (48.8% vs. 56.6%).²³

However, there have been few randomized clinical trials evaluating clinically relevant outcomes. The first and largest randomized controlled trial to date was carried out by Schädler et al.²⁴ This multicenter study evaluated the effect on IL-6 elimination in 97 septic patients suffering from septic shock, multiple organ failure, and/or ARDS randomized to cytokine adsorption with conventional treatment or standard of care alone. Despite the removal of IL-6 under CytoSorb treatment, patients' IL-6 levels were not significantly lower in the treatment group. In addition, no statistically significant differences were detected in terms of organ function parameters and survival. However, the authors stated that their study was not powered to detect differences in mortality and that their patients' cytokine levels were only moderately elevated with a median IL-6 level of 500 pg/mL. Interestingly, it has been reported that the reduction of systemic IL-6 levels was only significant when they exceeded 1000 pg/mL.^{25,26} This most likely reflects the concentration-dependent clearance effect of the hemadsorber and could explain the good response in our Patient 1 regarding the fast reduction of his high IL-6, PCT, and CRP levels during CytoSorb hemadsorption. Another aspect is that cytokine hemadsorption in



the cited study was only applied for 6 hours each day for a period of 7 days, whereas cytokine production and release during sepsis is thought to be continuous.²⁴ This could have been a further advantage in the treatment of our Patient 1, where hemadsorption was continuously applied over a period of 40 hours. The first randomized clinical trial investigating CytoSorb as a standalone treatment without CRRT in adults with septic shock reported a significant reduction in PCT plasma levels and a reduced need for norepinephrine.^{27,28} With the onset of the COVID-19 pandemic, another field of application for cytokine adsorption has emerged. Although the use of CytoSorb has been recommended by the FDA for the treatment of SARS-CoV-2-associated cytokine storm,²⁹ first randomized controlled trials could not show a significant reduction in serum IL-6 or any benefit for survival.³⁰

However, to date, robust data through large-scale RCTs investigating potential effects on sepsis-related organ injury and survival are still lacking.^{1,2}

Aside from several isolated case reports, the largest two studies to date evaluating hemadsorption use in a pediatric cohort were retrospective analyses and comprised 8 and 10 pediatric patients with bodyweight between 3.5 and 52 kg.^{31,32} Bottari et al reported that the use of CytoSorb in combination with CVVHDF and/or ECMO in pediatric patients experiencing septic shock was associated with rapid hemodynamic stabilization within the first 2 days of treatment and a significant reduction in IL-6, IL-10, and TNF- α .³¹ The need for vasopressors and inotropic agents was reduced by more than half in up to 70% of these patients after 48 hours. The median removal ratio for IL-6, IL-10, and TNF- α was 80%, 90%, and 29%, respectively.³¹ Milella et al analyzed 10 pediatric patients suffering from multiple organ failure of various etiologies and observed a decrease in inflammatory parameters and catecholamine demand accompanied by improved organ functions.³² The authors of both cited case series reported no complications or adverse effects through the application of CytoSorb.^{31,32} Further pediatric case reports included patients between the age of 3 days to 17 years of age. CytoSorb treatment in these case reports had been applied for various different indications such as sepsis and septic shock, ARDS, cardiac shock, SIRS following cardiac surgery, toxic shock syndrome following an insect bite, acute kidney injury following rhabdomyolysis, and drug-induced cytokine release syndrome, and most recently in a patient with severe MIS-C (a multisystem inflammatory syndrome in children) following SARS-CoV-2 infection.³³⁻⁴⁰

As the hemadsorber is designed for use in adults, existing safety profile data and application recommendations cannot easily be extrapolated for use in pediatric patients. First, the extracorporeal blood volume of the adsorber column is 150 mL, which constitutes a considerable portion of the circulating blood volume of a neonate or a young infant. Inserting the cartridge column in the extracorporeal circuit can thus

result in hemodilution when primed with crystalloids, or lead to severe hypotension, even when primed with blood.

The youngest reported patient to date, a neonate weighing 4 kg treated with CytoSorb for refractory shock following congenital heart surgery, experienced severe hypotension when the device was inserted in the extracorporeal circuit.³³ The authors stated, however, that hypotension was rapidly resolved after the administration of fresh frozen plasma and red cell concentrates. In Patient 2, we also observed a hypotensive deterioration when the adsorber was added to the extracorporeal circuit. After administration of 10 mL/kg crystalloids and transient elevation of norepinephrine, the patient's blood pressure rapidly stabilized.

An additional factor is blood flow. According to CytoSorb's manufacturer, the recommended blood flow is 150-700 mL/min. However, this is not feasible for low-weight pediatric patients and there is no available data on the safety and effectiveness of using lower flow rates. We maintained blood flow rates at 100-150 mL/min due to a paucity of recommendations in pediatric patients. Other studies have reported blood flow as low as 40 mL/min without negative effects.³⁴

CytoSorb adsorption columns are authorized for a maximum treatment duration of 24 h/device.⁴¹ We acted in accordance with this recommendation in Patient 2 but did not change the adsorber column during the total treatment course of 40 hours in Patient 1 because of his low body weight, as previously described in other case reports of infants with body weights under 10 kg.³³⁻³⁵ The priming volume of the hemadsorber is 150 mL, which accounts for approximately 25% of the patient's total blood volume and this bears the risk of hypotension and hemodilution. In order to avoid these risks, we decided not to change the column. The other aspect was that we did not observe a decline in the treatment effect. It is thought that the adsorption capacity of CytoSorb is saturable after approximately 8 hours in the clinical setting which can be evidenced by a rebound in systemic cytokine levels or by an increase in vasopressor demand. This effect can be tapered by changing the adsorption column.² However, we did not observe any rebound effect in our patient. A possible explanation of this phenomenon could be that we used lower blood flow rates.

Studies in adults have shown that early CytoSorb treatment initiation within the first 24 hours of sepsis resulted in better outcomes.^{23,42-44} However, this was not feasible in our pediatric patients, where CytoSorb was only applied as salvage therapy after standard of care treatment was not successful.

Another aspect of CytoSorb treatment is that it is not selective to cytokines and toxic agents. Rather, it clears all hydrophobic molecules of up to approximately 55 kDa from the bloodstream, including physiologic mediators such as albumin, platelets, neutrophils, monocytes, some antibiotics,

**TABLE 3** Summary of published pediatric cases with CytoSorb application

	Study design	Age	Weight kg	Etiology of MSOF	Comorbidity	Blood flow mL/min	Cycles of CS	Hours per cycle	CRRT	ECMO	Outcomes	Adverse events	Hospital discharge
Bottari et al 2020 ³¹	Retrospective case series (n = 8)	1-13 years	10-45	Septic shock	IDDM, CKD, HUS, HLH, Ewing sarcoma, cystic fibrosis	/	3-4	24	Yes	3× VA 1× VV	Significantly improved vasoactive-inotropic score, 80% removal ratio for IL6, 90% for IL10, 29% for TNF α	None	7/8
Milella et al 2019 ³²	Retrospective case series (n = 10)	1-312 months	3.5-52	Septic shock, cardiac failure, ARDS	HLH, acute myocarditis, HUS, AML, ADEM, CAVC, Fontan procedure	200	1-3	17-24	Yes	No	Decrease in inflammatory parameters/ catecholamine demand, improved organ function, early treatment onset (within 24-48 hours after diagnosis) beneficial for survival	None	5/10
Perez et al 2019 ³³	Case report	3 days	4	Cardiac shock, refractory vasoplegia	HLHS	/	1	72	No	MCS	Hemodynamic stabilization within hours (blood pressure, lactate, diuresis)	Severe hypotension, vancomycin intoxication after CS	Yes
Saparov et al 2019 ³⁵	Case report	8 months	5.6	fungal-bacterial sepsis	laryngeal stenosis, bilateral pneumonia	56	1	36	Yes	No	Normalization of IL6, S100, PCT, CRP within 12 hours, weaning from vasopressors	None	Yes
Cirstoveanu et al 2017 ³⁴	Case report	9 months	9	Sepsis/SIRS after cardiac surgery	Tetralogy of Fallot	40	1	49	Yes	No	Improved cardiovascular status, ventilation settings and hepatocellular necrosis	None	Yes



	Study design	Age	Weight kg	Etiology of MSOF	Comorbidity	Blood flow mL/ min	Cycles of CS	Hours per cycle	CRRT	ECMO	Outcomes	Adverse events	Hospital discharge
Berkes et al 2017 ³⁶	Case report	5 years	/	TSS following an insect bite	Down's syndrome	40	1	72	Yes	No	Stabilized hemodynamics, improved respiratory status, vanishing of erythrodermia/ purpura/petechiae	None	Yes
Padiyar et al 2019 ³⁸	Clinical case letter	6 years	/	AKI following rhabdomyolysis	Viral myositis following Influenza B and Enterovirus infection	/	1	72	Yes	No	Hemodynamic stabilization	None	Yes
Bottari et al 2020 ³⁹	Case report	14 years	/	Drug induced cytokine release syndrome, sHLH, ARDS	B cell precursor acute lymphoblastic leukemia	/	5	12-24	Yes	No	Dramatic reduction of ferritin levels, IL6, TNF α , increased paO ₂ / FiO ₂ ration, improved chest radiographs	None	Yes
Bottari et al 2021 ⁴⁰	Case report	14 years	45	MIS-C following SARS- CoV-2 infection	/	/	4	12-24	Yes	No	Rapid recovery of myocardial function, reduction in pro-BNP, lactate, inflammatory biomarkers	None	Yes
Keles et al 2019 ³⁷	Short communication	17 years	54	Sepsis/ARDS	Collapsing glomerulopathy under immunosuppressive therapy	150-200	3	8	Yes	No	Decreasing need for blood products improvement of neutropenia, renal function and respiratory status within hours	None	Yes



and other drugs.⁴⁴ Because this effect is concentration dependent, physiologic mediators are not influenced in a clinically relevant manner according to the manufacturer.⁴ The reported clearance of albumin, for example, is estimated at <5% and for platelets, <10% in adults.²⁴ Both our patients required albumin and platelets replacement during CytoSorb application. In Patient 1, serum albumin dropped from 19.9 to 10.1 g/L within the first 4 hours after initiation of treatment. Under continuous albumin infusion of 2 g/kg/d, albumin serum levels were stable between 20 and 26 g/L. We also noticed that platelet depletion increased during treatment. In Patient 1's septic condition, the need for platelet transfusions rose from once to twice daily during CytoSorb treatment. His platelet count before initiation of CytoSorb was 10 G/L and dropped to 8 G/L despite substitution. After another transfusion, the platelet count rose to 27 G/L and then dropped to 5 G/L again within several hours. Our observations can only demonstrate a temporal association. However, if this increased requirement for platelet transfusions was a direct result of the adsorber—with more pronounced and rapid platelet depletion than has been reported in adults—this particularity should be systematically investigated in larger studies.

Regarding the influence of CytoSorb on pharmacokinetics, the manufacturer recommends monitoring plasma levels of antibiotics such as piperacillin, meropenem, linezolid, and glycopeptides.⁴⁵ In the aforementioned newborn case described by Perez et al, the authors explained that vancomycin dosing was adapted in accordance with plasma levels under CytoSorb treatment. They cautioned that after removing the adsorber, vancomycin rapidly reached toxic plasma levels resulting in acute kidney damage.³³

Most published pediatric case reports do not report such adverse effects, however, plasma levels of administered drugs were often not monitored.³⁵⁻³⁷ Table 3 summarizes the published literature on pediatric CytoSorb application.

Although designed for use in adults, the application of the CytoSorb hemadsorber in patients with bodyweight <45 kg is not contraindicated and is not regarded as off-label use. However, in these cases, the responsibility for individual use in pediatric patients is left to the physician's discretion and it is recommended to adjust blood flow rates to reduce the risk of an adverse effect, according to the official instructions for use.⁴⁶

Given the special considerations described above, hemadsorption in pediatric patients should be restricted to individualized indications, where predicted mortality is high under standard care treatment and where anticipated benefits outweigh potential risks. Those potential adverse events include hemodilution and hypotension that could result in cardiac arrest, reduction of serum albumin, platelets, and neutrophils, as well as altered serum levels of hydrophobic antibiotics and other drugs. Therefore, CytoSorb application

in children requires a high level of expertise of the medical staff and close monitoring of patients. Platelet and absolute neutrophil count and serum albumin should be monitored at close intervals to allow rapid and appropriate substitution. In addition, plasma levels of hydrophobic drugs need to be measured, including digoxin and antibiotics such as piperacillin, meropenem, glycopeptides, aminoglycosides, linezolid, and clindamycin. Priming with or administration of red blood cells during priming should be considered in newborns and small children, where the extracorporeal volume of the cartridge column exceeds 10% of the patient's total blood volume.⁴⁷

4 | CONCLUSION

Our observation suggests that hemadsorption with CytoSorb contributed to the favorable outcomes of our 2 patients suffering from multisystem organ failure following refractory septic shock and acute liver failure. Its application was safe, efficient, and did not cause any notable complications.

Whether our positive experience with CytoSorb can be generalized across a broader cohort under pediatric and neonatal intensive care settings requires further investigation through large-scale randomized controlled trials. To date, its use in pediatric patients is still experimental. Recommendations for specific pediatric challenges such as optimal blood flow in low-weight patients, length of treatment, and plasma level surveillance of certain drugs and physiologic agents remain to be determined. From a medical device design perspective, a smaller cartridge column with lower dead space volume could be favorable for applying this treatment modality across different indications in pediatric intensive care and neonatology.

ACKNOWLEDGMENT

The authors thank Dr Philipp Steinbauer for providing graphic illustrations.

DISCLOSURE

CytoSorbents provided financial support for a professional editing service on our request. The authors are solely responsible for the content of the manuscript as well as treatment decisions and management of their patients. CytoSorbents was not involved in the development of the manuscript or the choice of the journal and was not provided the opportunity to review a preliminary version of the manuscript. The authors received no financial support or other forms of compensation related to the development of the manuscript or the clinical use of CytoSorb. The company has never been involved in treatment decisions nor has there ever been any influence on our clinical effort to use their products.



AUTHOR CONTRIBUTIONS

Concept/design: Steurer, Hermon

Drafting article: Steurer

Critical revision of article: Schlager, Sadeghi, Golej, Wiedemann, Hermon

Approval of article: Schlager, Sadeghi, Golej, Wiedemann, Hermon

ORCID

Lisa-Maria Steurer  <https://orcid.org/0000-0002-8665-2127>

REFERENCES

- Ankawi G, Xie Y, Yang B, Xie Y, Xie P, Ronco C. What have we learned about the use of Cytosorb adsorption columns? *Blood Purif.* 2019;48:196–202.
- Honore PM, Hoste E, Molnár Z, Jacobs R, Joannes-Boyau O, Malbrain MLNG, et al. Cytokine removal in human septic shock: where are we and where are we going? *Ann Intensive Care.* 2019;9(1):56.
- Datzmann T, Träger K. Extracorporeal membrane oxygenation and cytokine adsorption. *J Thorac Dis.* 2018;10 Suppl 5:S653–60.
- CytoSorbents Europe [Internet]. Berlin: Der Adsorber; c2021 [cited 2021 Jan 31]. Available from: <https://cytosorb-therapy.com/de/der-adsorber/>
- CytoSorbents Europe [Internet]. Berlin: Fields of Application; c2021 [cited 2021 Jan 31]. Available from: <https://cytosorb-therapy.com/en/the-therapy/fields-of-application/>
- Peng ZY, Carter MJ, Kellum JA. Effects of hemadsorption on cytokine removal on short-term survival in septic rats. *Crit Care Med.* 2008;36:1573–7.
- Linden K, Scaravilli V, Kreyer SF, Belenkiy SM, Stewart IJ, Chung KK, et al. Evaluation of the Cytosorb hemadsorptive column in a pig model of severe smoke and burn injury. *Shock.* 2015;44:487–95.
- CytoSorbents Europe [Internet]. Berlin: Die Studien; c2021 [cited 2021 Jan 31]. Available from: <https://cytosorb-therapy.com/de/die-studien/>
- Houschyar KS, Pyles MN, Rein S, Nietzsche I, Duscher D, Maan ZN, et al. Continuous hemoadsorption with a cytokine adsorber during sepsis—a review of the literature. *Int J Artif Organs.* 2017;40:205–11.
- Khemani RG, Smith LS, Zimmerman JJ, Erickson S, Pediatric Acute Lung Injury Consensus Conference Group. Pediatric acute respiratory distress syndrome: definition, incidence, and epidemiology: proceedings from the Pediatric Acute Lung Injury Consensus Conference. *Pediatr Crit Care Med.* 2015;16 Suppl 1:S23–40.
- Matics TJ, Sanchez-Pinto LN. Adaptation and validation of a pediatric sequential organ failure assessment score and evaluation of the sepsis-3 definitions in critically ill children. *JAMA Pediatr.* 2017;171:e172352.
- Pinsky MR, Vincent JL, Deviere J, Alegre M, Kahn RJ, Dupont E. Serum cytokine levels in human septic shock. Relation to multiple-system organ failure and mortality. *Chest.* 1993;103:565–75.
- Gogos CA, Drosou E, Bassaris HP, Skoutelis A. Pro- versus anti-inflammatory cytokine profile in patients with severe sepsis: a marker for prognosis and future therapeutic options. *J Infect Dis.* 2000;181:176–80.
- Angus DC, van der Poll T. Severe sepsis and septic shock. *N Engl J Med.* 2013;369:840–51.
- Singer M, Deutschman CS, Seymour CW, Shankar-Hari M, Annane D, Bauer M, et al. The Third International Consensus definitions for sepsis and septic shock (sepsis-3). *JAMA.* 2016;315:801–10.
- Ronco C, Tetta C, Mariano F, Wratten ML, Bonello M, Bordoni V, et al. Interpreting the mechanisms of continuous renal replacement therapy in sepsis: the peak concentration hypothesis. *Artif Organs.* 2003;27:792–801.
- Kellum JA, Kong L, Fink MP, Weissfeld LA, Yealy DM, Pinsky MR, et al. Understanding the inflammatory cytokine response in pneumonia and sepsis: results of the Genetic and Inflammatory Markers of Sepsis (GenIMS) study. *Arch Intern Med.* 2007;167:1655–63.
- Clària J, Arroyo V, Moreau R. The acute-on-chronic liver failure syndrome, or when the innate immune system goes astray. *J Immunol.* 2016;197:3755–61.
- Chen P, Wang YY, Chen C, Guan J, Zhu HH, Chen Z. The immunological roles in acute-on-chronic liver failure: an update. *Hepatobiliary Pancreat Dis Int.* 2019;18:403–11.
- Ocskay K, Kanjo A, Gede N, Szakács Z, Pár G, Erőss B, et al. Uncertainty in the impact of liver support systems in acute-on-chronic liver failure: a systematic review and network meta-analysis. *Ann Intensive Care.* 2021;11:10.
- Cutuli SL, Grieco DL, De Pascale G, Antonelli M. Hemadsorption. *Curr Opin Anaesthesiol.* 2021;34:113–8.
- Friesecke S, Träger K, Schitteck GA, Molnar Z, Bach F, Kogelmann K, et al. International registry on the use of the CytoSorb® adsorber in ICU patients: study protocol and preliminary results. *Med Klin Intensivmed Notfmed.* 2019;114:699–707.
- Paul R, Sathe P, Kumar S, Prasad S, Aleem M, Sakhalvalkar P. Multicentered prospective investigator initiated study to evaluate the clinical outcomes with extracorporeal cytokine adsorption device (CytoSorb®) in patients with sepsis and septic shock. *World J Crit Care Med.* 2021;10:22–34.
- Schädler D, Pausch C, Heise D, Meier-Hellmann A, Brederlau J, Weiler N, et al. The effect of a novel extracorporeal cytokine hemoadsorption device on IL-6 elimination in septic patients: a randomized controlled trial. *PLoS ONE.* 2017;12:e0187015.
- Kobe Y, Oda S, Matsuda K, Nakamura M, Hirasawa H. Direct hemoperfusion with a cytokine-adsorbing device for the treatment of persistent or severe hypercytokinemia: a pilot study. *Blood Purif.* 2007;25:446–53.
- Shiga H, Hirasawa H, Nishida O, Oda S, Nakamura M, Mashiko K, et al. Continuous hemodiafiltration with a cytokine-adsorbing hemofilter in patients with septic shock: a preliminary report. *Blood Purif.* 2014;38:211–8.
- Oeveges N, Hawchar F, Laszlo I, Trasy D, Ondrik Z, Molnar Z. Early cytokine adsorption in septic shock (ACCESS-trial): results of a proof concept, pilot study. *Crit Care.* 2018;22 Suppl 1:82.
- Hawchar F, Laszlo I, Oeveges N, Trasy D, Ondrik Z, Molnar Z. Extracorporeal cytokine adsorption in septic shock: a proof of concept randomized, controlled pilot study. *J Crit Care.* 2019;49:172–8.
- US Food and Drug Administration. CytoSorb® emergency use authorization for use in patients with COVID-19 infection [Internet]. 2020. [cited 2021 Jul 4]. Available from: <https://www.fda.gov/media/136866/download>
- Supady A, Weber E, Rieder M, Lothar A, Niklaus T, Zahn T, et al. Cytokine adsorption in patients with severe COVID-19 pneumonia requiring extracorporeal membrane oxygenation (CYCOV):



- a single centre, open-label, randomised, controlled trial. *Lancet Respir Med.* 2021;9:755–62.
31. Bottari G, Guzzo I, Marano M, Stoppa F, Ravà L, Di Nardo M, et al. Hemoperfusion with Cytosorb in pediatric patients with septic shock: a retrospective observational study. *Int J Artif Organs.* 2020;43:587–93.
 32. Milella L, Ficarella MT, Calabrese G, Sisto M, Grieco RL, Moliterni P, et al. Application of hemadsorption in neonatal and pediatric hyperinflammatory states: a case series. *Am J Pediatr.* 2019;5:34–42.
 33. Perez MH, Maitre G, Longchamp D, Amiet V, Natterer J, Ferry T, et al. CytoSorb® hemoadsorption and mechanical circulatory support in a newborn with refractory shock after congenital heart surgery. *Int J Artif Organs.* 2019;42:521–4.
 34. Cirstoveanu CG, Barascu I, Mc Kenzie Stancu S. Hemadsorption with adult CytoSorb® in a low weight pediatric case. *Case Rep Crit Care.* 2017;2017:6987167.
 35. Saparov A, Sazonov V, Tobylbaeva Z, Isakov S, Bekpan A, Autilipov D, et al. First successful hemoadsorption using CytoSorb® in a septic pediatric patient in Kazakhstan: a case report. *Int J Artif Organs.* 2019;42:315–7.
 36. Berkes A, Szikszay E, Kappelmayer J, Kerényi A, Szabó T, Ujhelyi L, et al. Use of hemadsorption in a case of pediatric toxic shock syndrome. *Case Rep Crit Care.* 2017;2017:3818407.
 37. Keles E, Fidan K, Yenicesu I, Kalkan G. Successful application of CytoSorb® hemadsorption in an immunocompromised teenager with collapsing glomerulopathy, acute respiratory distress syndrome, and sepsis. *Int J Artif Organs.* 2019;42:765–9.
 38. Padiyar S, Deokar A, Birajdar S, Walawalkar A, Doshi H. Cytosorb for management of acute kidney injury due to rhabdomyolysis in a child. *Indian Pediatr.* 2019;56:974–6.
 39. Bottari G, Merli P, Guzzo I, Stoppa F, Ruggeri A, Di Nardo M, et al. Multimodal therapeutic approach of cytokine release syndrome developing in a child given chimeric antigen receptor-modified T cell infusion. *Crit Care Explor.* 2020;2:e0071.
 40. Bottari G, Confalone V, Cotugno N, Guzzo I, Perdichizzi S, Manno EC, et al. Efficacy of CytoSorb in a pediatric case of severe multisystem inflammatory syndrome (MIS-C): a clinical case report. *Front Pediatr.* 2021;9:676298.
 41. CytoSorbents Europe [Internet]. Berlin: Technische Daten des Adsorbers; c2021 [cited 2021 Jan 31]. Available from: <https://cytosorb-therapy.com/de/der-adsorber/technische-daten-des-cytosorb-adsorber/>
 42. Kogelmann K, Jarczack D, Scheller M, Drüner M. Hemoadsorption by CytoSorb in septic patients: a case series. *Crit Care.* 2017;21:74.
 43. Bonavia A, Groff A, Karamchandani K, Singbartl K. Clinical utility of extracorporeal cytokine hemoadsorption therapy: a literature review. *Blood Purif.* 2018;46:337–49.
 44. CytoSorbents Europe [Internet]. Berlin: Die Therapie; c2021 [cited 2021 Jan 31]. Available from: <https://cytosorb-therapy.com/de/die-therapie/therapieeffekte/>
 45. Morris C, Gray L, Giovannelli M. Early report: the use of Cytosorb™ haemabsorption column as an adjunct in managing severe sepsis: initial experiences, review and recommendations. *J Intensive Care Soc.* 2015;16:257–64.
 46. CytoSorbents Inc. CytoSorb™ 300 mL device—instructions for use. 2012 [cited 2021 Jul 4]. Available from: https://www.biocon.com/docs/prescribing_information/ccd/CytoSorb_DeviceInstructionsForUse.pdf
 47. Bottari G, Di Nardo M, Gleeson J, Minoia F, Moscatelli A, Cecchetti C, et al. Extracorporeal blood purification techniques in children with hyper-inflammatory syndromes: a clinical overview. *Minerva Anesthesiol.* 2019;85:531–42.

How to cite this article: Steurer L-M, Schlager G, Sadeghi K, Golej J, Wiedemann D, Hermon M. Hemadsorption as rescue therapy for patients with multisystem organ failure in pediatric intensive care—Two case reports and review of the literature. *Artif. Organs.* 2021;45:1582–1593. <https://doi.org/10.1111/aor.14047>