

Use of nasal packing as a splint for stabilizing nasal alar repairs



Sabrina Dahak, MS,^a Monica Janeczek, MD,^b and Shari Ochoa, MD^b
Phoenix and Scottsdale, Arizona

Key words: Mohs micrographic surgery; reconstruction; scars; tumors; wound healing.

INTRODUCTION

External nasal valve collapse is a common consequence of large surgical defects involving the nasal ala. Current reconstructive techniques involve the use of suspension sutures, alar batten cartilage grafts, and nasal stents using nasopharyngeal airway tubing.¹⁻³ We describe a novel technique for stabilizing nasal alar repairs that minimizes scar contracture, maintains airway patency, aids in postoperative hemostasis, and stabilizes the graft/flap to the wound bed.

CASE REPORT

An 80-year-old Caucasian woman with a history of multiple nonmelanoma skin cancers was referred for Mohs micrographic surgery for surgical treatment of a nodular basal cell carcinoma on the left nasal ala. Preoperative lesion size was 1.0×0.9 cm. The patient underwent one stage of Mohs micrographic surgery to achieve tumor-free margins. The tumor-free defect measured 1.6×0.9 cm. In view of the size and location of the defect, it was felt that immediate reconstruction with a cheek-to-nose interpolation flap overlying an auricular cartilage graft would provide optimal function and cosmesis. The cartilage graft donor site was the left antihelix.

To prevent nasal alar collapse, an M-type nasal pack with airway (Shippert Medical Technology) was used as a splint to stabilize the surgical repair. The nasal pack was trimmed with a scalpel blade to a comfortable length for the patient when inserted. The nasal pack was wrapped in Xeroform. The packing was inserted into the affected nostril until it was approximately flush with the alar rim (Fig 1, A). The attached string was secured as part of the

external pressure band (Fig 1, B). Packing was replaced by the Mohs surgeon at the first dressing change at 72 hours to minimize the risk of toxic shock syndrome. Subsequent removal of the nasal packing was performed at the time of suture removal on postoperative day 7. Postoperative outcomes are depicted in Fig 2.

DISCUSSION

Many factors should be considered during the reconstruction of nasal alar surgical defects. The preferred reconstructive method will depend on the defect size, depth, involved anatomic structures, and independent patient factors. Three proposed algorithms have been described by Chen et al⁴ based on the above variables to optimize patient outcomes. The principal factors to consider, based on this algorithm, are the size and depth of the surgical defect. If the nasal alar defect is limited to the skin with cartilage intact, reconstruction can proceed without consideration for structural support to the ala. If the cartilage or fibrous layer of the skin is involved, support to the alar rim is required to prevent external nasal valve collapse. Large nasal alar repairs may require external stabilization to prevent nasal alar collapse. The surgical repair described in this report represents a novel method to provide external stabilization. Previously described reconstructive techniques involve the use of suspension sutures, alar batten cartilage grafts, and nasal stents using nasopharyngeal airway tubing.¹⁻³ Alar batten cartilage grafts are typically placed laterally to provide support and increased stiffness to the nasal side walls and prevent collapse.⁵ However, this repair may add additional volume and

From the University of Arizona College of Medicine - Phoenix, Phoenix, Arizona^a; Department of Dermatology, Mayo Clinic, Scottsdale.^b

Funding sources: None.

IRB approval status: Not applicable.

Correspondence to: Dr Monica Janeczek, MD, Department of Dermatology, Mayo Clinic, 13400 East Shea Boulevard, Scottsdale, AZ 85259. E-mail: Janeczek.monica@mayo.edu.

JAAD Case Reports 2022;22:60-1.

2352-5126

© 2022 by the American Academy of Dermatology, Inc. Published by Elsevier, Inc. This is an open access article under the CC BY-NC-ND license (<http://creativecommons.org/licenses/by-nc-nd/4.0/>).

<https://doi.org/10.1016/j.jdc.2022.02.007>

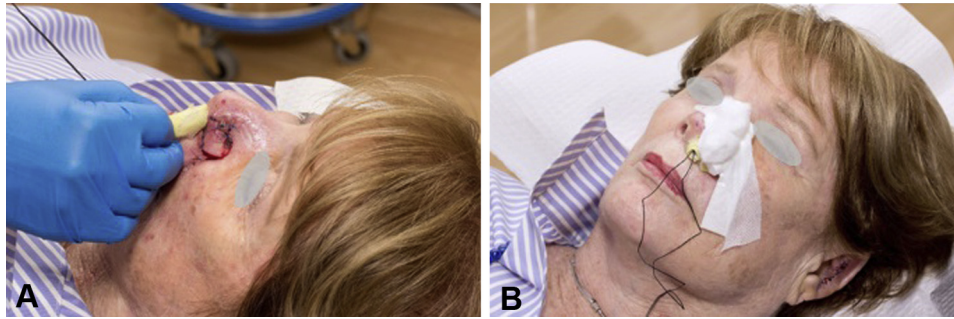


Fig 1. **A**, Nasal packing wrapped in Xeroform is inserted into affected nasal ala. **B**, Packing is secured with external pressure bandage.

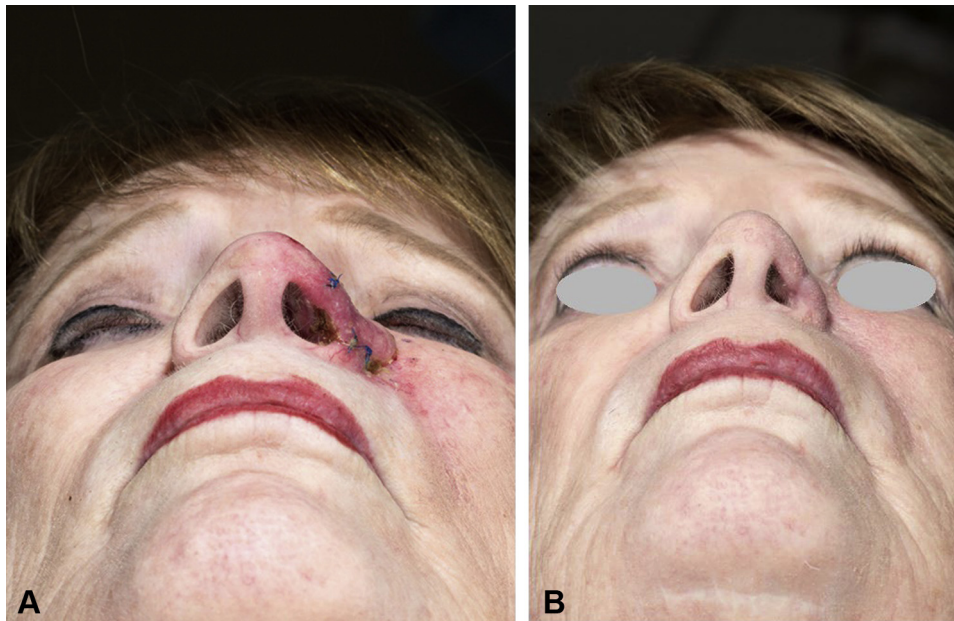


Fig 2. Postoperative outcome at 18 days (**A**) and 68 days (**B**) postprocedure (no intervention).

weight to the defect, which can result in inward collapse of the noncartilaginous tissues. Nasal valve suspension provides lateral pull on the nasal sidewall.⁵ This technique may result in over-extension of the defect given the lateral vector.⁵ Mechanical nasal stents, such as strips or cones, have been described as means to prevent alar collapse.⁶ However, these devices may be difficult to find in common practice. Nasal packing has been described in the otolaryngology literature to provide hemostasis after surgery, support for nasal structures, and to prevent adhesions and stenosis.⁷ We describe a novel method, in which an M-type nasal pack is used for Mohs surgical repair. This method stabilizes the graft/flap, minimizes scar contracture, maintains airway patency, and aids in postoperative hemostasis.

Conflicts of interest

None disclosed.

REFERENCES

1. Byrd DR, Otley CC, Nguyen TH. Alar batten cartilage grafting in nasal reconstruction: functional and cosmetic results. *J Am Acad Dermatol*. 2000;43(5 Pt 1):833-836. <https://doi.org/10.1067/mjd.2000.107740>
2. Egan KK, Kim DW. A novel intranasal stent for functional rhinoplasty and nostril stenosis. *Laryngoscope*. 2005;115(5):903-909. <https://doi.org/10.1097/01.MLG.0000153705.47361.1E>
3. Wittkopf M, Wittkopf J, Ries WR. The diagnosis and treatment of nasal valve collapse. *Curr Opin Otolaryngol Head Neck Surg*. 2008;16(1):10-13. <https://doi.org/10.1097/MOO.0b013e3282f396ef>
4. Chen C, Patel R, Chi J. Comprehensive algorithm for nasal ala reconstruction: utility of the auricular composite graft. *Surg J (N Y)*. 2018;4(2):e55-e61. <https://doi.org/10.1055/s-0038-1639581>
5. Nuara MJ, Mobley SR. Nasal valve suspension revisited. *Laryngoscope*. 2007;117(12):2100-2106. <https://doi.org/10.1097/MLG.0b013e32814842cd>
6. Rhee JS, Weaver EM, Park SS, et al. Clinical consensus statement: diagnosis and management of nasal valve compromise. *Otolaryngol Head Neck Surg*. 2010;143(1):48-59. <https://doi.org/10.1016/j.otohns.2010.04.019>
7. Weber RK. Nasal packing and stenting. *GMS Curr Top Otorhinolaryngol Head Neck Surg*. 2009;8:Doc02. <https://doi.org/10.3205/cto000054>