

Available online at www.sciencedirect.com

ScienceDirect

journal homepage: www.elsevier.com/locate/radcr

Case Report

The spectrum of symptomatic arterialized developmental venous anomalies: case reports [☆]

João de Deus da Costa Alves Jr, MD, MSc, José Roberto Falco Fonseca, MD, PhD,
Gleyson Moraes Rios, MD, Jorge Murilo Barbosa De Sousa, MD, MSc*

Department of Interventional Neuroradiology, Neuroev Clinic, Mandaqui Hospital, Sepaco Hospital, IGESP Hospital,
São Paulo, Brazil

ARTICLE INFO

Article history:

Received 5 May 2022

Revised 8 July 2022

Accepted 13 July 2022

Keywords:

Developmental venous anomaly

Arterialized DVAs

Symptomatic DVAs

Cerebral angiography

ABSTRACT

Developmental venous anomaly (DVA) is an anatomical variation of the intracranial venous system, usually without clinical repercussion. In most cases, DVAs are incidentally diagnosed and should be considered as benign conditions. In rare circumstances, DVAs may become symptomatic due to mechanical or flow-related etiologies. The authors present three cases of symptomatic arterialized DVAs: a 28-year-old male with hematoma at the splenium of the corpus callosum and intraventricular hemorrhage, a 53-year-old male patient with a history of epileptic seizures starting recently, and a 25-year-old male patient, previously healthy who started with persistent headaches and hemosiderin deposition in brain parenchyma. These rare cases of arterialized DVAs are conditions that can cause symptoms or show more aggressive behavior with bleeding.

© 2022 The Authors. Published by Elsevier Inc. on behalf of University of Washington.

This is an open access article under the CC BY-NC-ND license

(<http://creativecommons.org/licenses/by-nc-nd/4.0/>)

Introduction

The Developmental Venous Anomaly (DVA) was first described by Lasjaunias et al in 1986, to describe an extreme anatomical variation in the venous system, usually observed incidentally in neuroimaging tests [1].

Radiological findings usually demonstrate a 'caput medusae' appearance, with centrifugal or centripetal orientation, according to the dominant venous recruitment pattern in vascular imaging. DVAs are generally asymptomatic, even though hemorrhagic strokes are described and

most of them are related to the coexistence of cavernous malformations (CM) [2,3].

Furthermore, DVAs can rarely present symptoms, even without the presence of CMs or other adjacent vascular malformations. DVAs with outflow changes or arterialized patterns may present symptoms and intracranial hemorrhage [3,4].

Therefore, DVAs are not always benign or clinically silent. Three rare cases of symptomatic arterialized DVAs are hereby highlighted: clinical presentations, angiographic features, management strategies and follow-ups.

[☆] Competing Interests: All authors declare no conflict of interest.

* Corresponding author.

E-mail address: jorgemurilobs@gmail.com.br (J.M.B. De Sousa).

<https://doi.org/10.1016/j.radcr.2022.07.056>

1930-0433/© 2022 The Authors. Published by Elsevier Inc. on behalf of University of Washington. This is an open access article under the CC BY-NC-ND license (<http://creativecommons.org/licenses/by-nc-nd/4.0/>)

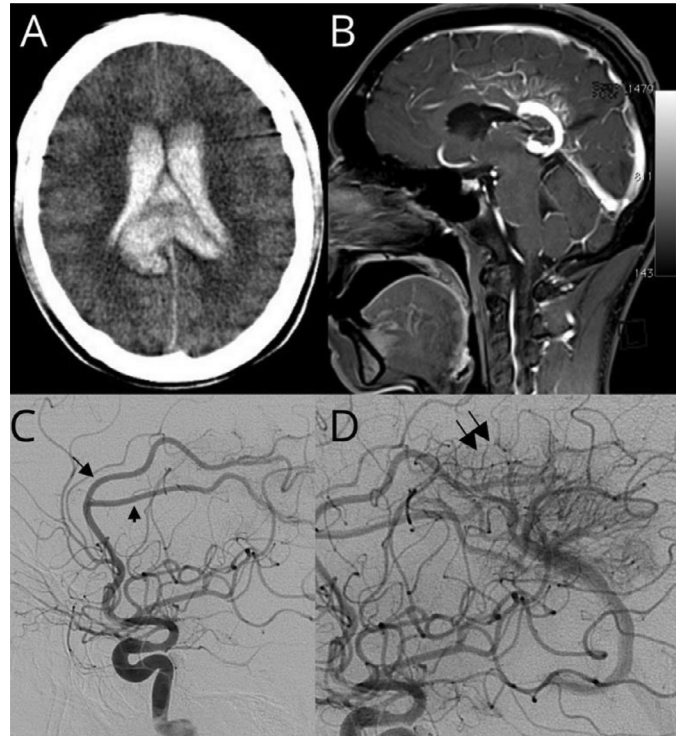


Fig. 1 – Case 1. (A) Noncontrast CT of the brain showed acute hematoma at the splenium of the corpus callosum and intraventricular hemorrhage. (B) T1-weighted post-gadolinium sagittal MRI showing DVA with dilated medullary veins draining into the deep venous system. (C) Right lateral carotid angiogram showing ectasia of the arteries that feed the parenchyma adjacent to the DVA (arrows). (D) Right lateral carotid angiogram showed arterialized features and arteriovenous shunt, with capillary stain (arrows) and early filling of the venous collector.

Case reports

Case 1

A 28-year-old male presented to an emergency care center with a history of sudden headache, vomiting, and loss of consciousness. A computed tomography (CT) scan showed an acute hematoma at the splenium of the corpus callosum and intraventricular hemorrhage (Fig. 1A). A brain magnetic resonance imaging (MRI) showed a DVA in the right cingulate gyrus region with dilated medullary vein draining into the deep venous system. No CMs were observed (Fig. 1B). A digital subtraction angiography is shown in Figures 1C and D. An arterialized DVA fed by the right pericallosal artery is seen in the right carotid artery angiography. He was treated with external ventricular drain placement. He was discharged without neurological deficits or symptoms (modified Rankin Scale - mRS zero), was discontinued from follow-up after 10 years, and had no further intracranial hemorrhage.

Case 2

A 53-year-old male patient has been referred from a neurologist with a history of epileptic seizures starting approximately 4 months ago. He exhibited visual aura, behavioral arrest, and sometimes secondary generalization. Seizure-free patient af-

ter initiation of antiepileptic drugs. A brain MRI showed a DVA in the right parietal-occipital area. Digital subtraction angiography showed the DVA with an arterialized appearance, as described in Figures 2A and B. Follow-up was discontinued after 5 years, and the patient was kept on clinical treatment only, with good seizure control.

Case 3

A 25-year-old male patient, previously healthy started with persistent headaches with a 2-month evolution. He was admitted to our hospital for investigation. MRI showed hemosiderin deposition in the right basal ganglia region and a DVA with a 'caput medusae' appearance without any evidence of associated CMs (Figs. 2C and D). Digital subtraction angiography shows an arterialized DVA with early-draining veins for 2 compartments, right basal vein and right internal cerebral vein. The patient was discharged with symptomatic management of headaches.

Discussion

DVAs are variations of normal transmedullary veins draining brain parenchyma and have a reported rate between 5% and 10% in modern series. They are described as a network of thin-walled, dilated transmedullary veins draining into a large col-

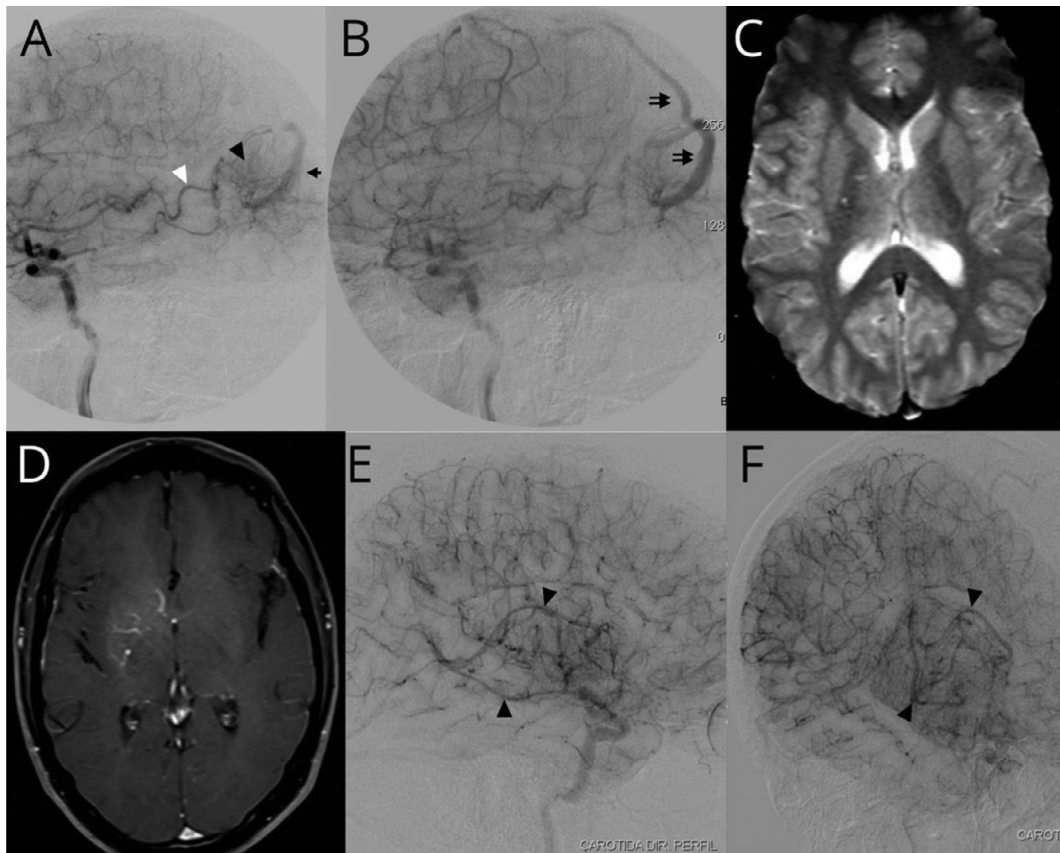


Fig. 2 – Cases 2 and 3. (A) Right lateral carotid angiogram from Case 2 showed a DVA with arterialized features, early filling of the venous collector (arrow) on arterial phase, capillary stain on parenchyma (black head arrow) and ectasia of cortical branch of the middle cerebral artery (white head arrow). (B) Right lateral carotid angiogram from Case 2 showed a DVA with early filling of the venous collector (arrows). (C) Brain MRI gradient echo sequence from Case 3 with focal hemorrhage in the right basal ganglia region. (D) Gadolinium-enhanced T1-weighted image from Case 3 showing the appearance of a DVA with its ‘caput medusae’. (E) Right lateral carotid angiogram from Case 3 showed arterialized features and arteriovenous shunt, with early filling of the venous collectors (black head arrows). (F) Oblique carotid angiogram from Case 3 with two independent venous collectors, right basal vein and right internal cerebral vein (black head arrows).

lector vein, which lacks a layer of smooth muscle and elastic lamina [5,6].

Nearly all DVAs are considered benign. Most bleeding cases are related to the association with CMs. Under rare circumstances, without CMs association, they can cause symptoms such as headaches, seizures, focal neurological deficits, and dizziness. The risk of a hemorrhagic stroke due to an isolated DVA is only between 0.15% and 0.68% [3,7].

A DVA angioarchitecture presents a slimmed vascular wall and little compliance with the flow and pressure variation. Thus, restriction to vascular drainage can promote regional venous hypertension, venous infarction and hemorrhage. On the other hand, the increase in the flow in DVA by the association with arteriovenous shunt is also a factor of venous hypertension and hemorrhage. This subgroup of DVAs with arteriovenous shunt has several synonyms: parenchymal arteriovenous malformation predominantly venous, DVAs associated with capillary spots, venous angioma with arterial supply, atypical DVAs. Pereira et al [3] adopts the term arterialized DVAs, which we consider appropriate because it reflects the pathophysiological aspect.

The association of DVAs and arteriovenous shunt/microshunts is infrequent and supports the rarity of this radiological presentation [2–4]. We identified three cases of arterialized DVAs in our database: a case related to intracranial hemorrhage, a case related to atypical headache and hemosiderin deposition on MRI, a case associated with epilepsy.

Little is known about the natural history of arterialized DVAs, given the rarity of the imaging presentation. A series of published cases such as those by Ruiz et al [5] points to a benign course of DVAs with a low rate of bleeding, but without distinction between cases of typical DVAs, DVAs associated with CMs or arterialized DVAs. However, Pereira et al [3] describes an association of arterialized DVAs with bleeding and seizure episodes, suggesting greater morbidity.

According to Pereira et al, the pathomechanisms underlying symptomatic DVAs are classified as mechanical, flow related, and idiopathic. Their review had reported that the mechanical causes, including hydrocephalus and neurovascular compression syndromes, accounted for 14/69 cases; flow related causes, related to an increase in inflow into the DVA or to an obstruction of the outflow, accounted for 49/69 cases;

and idiopathic causes were identified in 6/69 cases. Only 11/69 cases were arterialized DVAs [3].

The evaluation of a noninvasive neuroimaging method must be done carefully, and the identification of arteries with ectasia or arteries adjacent to DVAs must be valued as an indication of the presence of a shunt.

Digital subtraction angiography is the gold standard imaging modality for the diagnosis of arterialized DVAs. These lesions appeared to be typical DVAs on MRI, however on catheter angiography they are visualized on the arterial phase.

The underlying pathomechanisms are better characterized by the following angiographic imaging aspects [2–5]:

- The assessment of cerebral circulation time with early venous drainage (Figs. 1D, 2A, 2E) suggests less vascular resistance due to the presence of micro-shunts, usually tiny, sometimes shown only by superselective angiography using microcatheters. The absence of a nidus stands out.
- The exuberant arteriocapillary filling in the projection of the brain parenchyma adjacent to DVAs are described as capillary spots or capillary stains (Figs. 1D, 2A) due to the reactivation of angiogenesis and local vascular proliferation.
- The ectasia of one or more arteries (Figs. 1C, 2A), which feeds the parenchyma adjacent to the DVA, suggests greater blood supply, hemodynamic stress and consequent vascular remodeling.

The treatment strategy for symptomatic DVAs (arterialized or not) should not focus on the DVAs. However, treatment should be complication related, such as hematoma, seizure control, headache management, and treatment of associated vascular malformations. Likewise, the normal venous outflow must be preserved, because the obstruction of the collector veins would lead to cerebral infarction and subsequent complications [3,4].

Conclusion

Within the spectrum of symptomatic DVAs, some demonstrate arterIALIZED venous filling and hemodynamic changes, representing micro-shunts. These are potentially related to

more severe symptoms. Digital subtraction angiography is the gold standard imaging modality for the diagnosis.

Patient consent

Written consent to publish potentially identifying information, such as details or the case and photographs, was obtained from the patients or their legal guardians.

We further confirm that any aspect of the work covered in this manuscript that has involved human patients has been conducted with the ethical approval of all relevant bodies.

REFERENCES

- [1] Lasjaunias P, Burrows P, Planet C. Developmental venous anomalies (DVA): the so-called venous angioma. *Neurosurg. Rev* 1986;9:233–42. doi:10.1007/BF01743138.
- [2] Roccatagliata L, van den Berg R, Soderman M, Boulin A, Condette-Auliac S, Rodesch G. Developmental venous anomalies with capillary stain: a subgroup of symptomatic DVAs? *Neuroradiology* 2012;54:475–80. doi:10.1007/s00234-011-0890-y.
- [3] Pereira VM, Geibprasert S, Krings T, Aurboonyawat T, Ozanne A, Toulgoat F, et al. Pathomechanisms of symptomatic developmental venous anomalies. *Stroke* 2008;39:3201–15. doi:10.1161/STROKEAHA.108.521799.
- [4] Oran I, Kiroglu Y, Yurt A, Ozer FD, Acar F, Dalbasti T, et al. Developmental venous anomaly (DVA) with arterial component: a rare cause of intracranial haemorrhage. *Neuroradiology* 2009;51:25–32. doi:10.1007/s00234-008-0456-9.
- [5] San Millán Ruíz D, Yilmaz H, Gailloud P. Cerebral developmental venous anomalies: current concepts. *Ann Neurol* 2009;66:271–83. doi:10.1002/ana.21754.
- [6] Brinjikji W, El-Rida El-Masri A, Wald JT, Lanzino G. Prevalence of developmental venous anomalies increases with age. *Stroke* 2017;48:1997–9. doi:10.1161/STROKEAHA.116.016145.
- [7] Naff NJ, Wemmer J, Hoenig-Rigamonti K, Rigamonti DR. A longitudinal study of patients with venous malformations documentation of a negligible hemorrhage risk and benign natural history. *Neurology* 1998;50:1709–14. doi:10.1212/WNL.50.6.1709.