



Venous pattern of polymicrogyria detected by susceptibility weighted imaging (SWI)

Rajeev K Verma^{1,2}, Franca Wagner¹, Christian Weisstanner¹, Susi Strozzi³ and Matthias F Lang^{1,4}

Abstract

We report a case of a 9-year-old boy presenting with spastic-dystonic movement disorder of the right arm. MRI showed vast unilateral left-sided polymicrogyria (PMG) with perisylvian, temporal, frontal, and parietal location. Corresponding to the distinctly reduced gyration, the focal pattern of cortical veins in susceptibility weighted imaging (SWI) was absent due to missing sulcal depth. In contrast, adjacent regions with sufficient sulcal depth revealed a pattern with numerically increased and finer cortical veins. Therefore, with its atypical venous pattern SWI indicates an abnormal parenchymal anatomy and might be an additional helpful tool for diagnosing PMG.

Keywords

Susceptibility weighted imaging (SWI), polymicrogyria (PMG), cortical veins, magnetic resonance imaging (MRI), cortical malformation

Date received: 21 April 2015; revised: 22 October 2015; accepted: 22 October 2015

Introduction

Polymicrogyria (PMG) is a malformation of cerebral cortical development. The term describes a pathologic cortical pattern with multiple distinctly small convolutions (1,2). PMG shows heterogeneous clinical manifestations and imaging patterns (1–3). Macroscopically, it has an irregular or pebbled cortical surface and the distribution varies from bilateral symmetrical to asymmetrical to unilateral forms. Magnetic resonance imaging (MRI) is the modality of choice for assessment of PMG. Key features are undulation and irregularity of the cortical surface, apparent thickening of polymicrogyric cortex as well as stippling and irregularity at the gray-white junction (3). In standard practice, T1-weighted (T1W), T2-weighted (T2W), and FLAIR MR sequences are used to image these alterations. As a relatively new sequence, SWI has not yet been evaluated in PMG. SWI is widely applied for diagnostic purposes, e.g. for detection of intracranial hemorrhage, calcification, or cerebral venous thrombosis (4). In addition, pattern alterations of cortical veins have been described in several studies. Due to

the higher paramagnetic properties of deoxyhemoglobin compared to oxyhemoglobin, signal loss in cortical veins is more pronounced leading to a prominent appearance of cortical veins compared to normal oxygenated veins. This can be used, for example, in acute ischemic stroke or hemiplegic migraine (5–7), where malperfused areas show a prominent appearance of cortical veins due to higher deoxyhemoglobin levels. The opposite effect, with diminished or rarified cortical

¹University Institute of Diagnostic and Interventional Neuroradiology, Inselspital, University of Bern, Bern, Switzerland

²Institute of Radiology, Tiefenau Hospital, Spital Netz Bern, Bern, Switzerland

³Division of Neuropaediatrics, Inselspital, University of Bern, Bern, Switzerland

⁴University Institute of Diagnostic, Interventional and Pediatric Radiology, Inselspital, University of Bern, Bern, Switzerland

Corresponding author:

Rajeev K Verma, Institute of Diagnostic and Interventional Neuroradiology, Inselspital Bern, Freiburgstrasse 4, 3010 Bern, Switzerland.

Email: rajeev.verma@insel.ch



veins, has been described in ictal hyperperfused areas (8).

Case report

We present a case of a 9-year-old boy who presented a spastic-dystonic movement disorder of the right arm. The clinical neurological investigation showed sinking of the arm in the arm extension test, flexion in the elbow, wrist, and in digits IV and V, as well as dysdiadochokinesis and clumsy coordination of the right arm.

MRI showed typical features of PMG in T2W images, with an undulated and irregular surface of the cortex, seemingly thickened polymicrogyric cortex and irregularity along the gray-white junction (Fig. 1a, c, e). The changes were unilateral on the left and pronounced in the perisylvian location (Fig. 1c), but also clearly in the fronto-parieto-temporal cortex including the pre- and postcentral gyrus (Fig. 1a, e). Susceptibility weighted imaging (SWI) patterns of cortical veins of the left hemisphere varied and differed distinctly from a normal appearance. Regions with PMG and extensively limited gyration showed no cortical veins (Fig. 1b). The deepest affected sulcus was the Sylvian fissure, where cortical vein appearance was increased in number and finer compared to the normal appearance of the unaffected right hemisphere (Fig. 1d). In areas with some deeper sulci, the veins also appeared regionally concentrated and slightly increased in number (Fig. 1e).

Discussion

PMG is one of the most common malformations of cortical development with overfolding and abnormal lamination (9) and is diagnosed clinically and by MRI. T1W and T2W thin section images allow the differentiation of polymicrogyria and pachygyria (10). Due to a pronounced reduction of sulcal depth, the surface area of the cortex is decreased and cortical veins have to travel on the cortical surface rather than in the depth of the sulci. As shown in Fig. 1a in our patient the left temporal lobe with PMG shows a missing cortical vein pattern in SWI due to the absence of sulci compared to the normal developed right temporal lobe. Cortical veins are thinner and numerically increased in the heavily PMG-affected left Sylvian fissure of the same patient (Fig. 1d), apparently due to a lack of additional finer sulci in the Sylvian fissure, as seen on the normally developed right side. Moreover, a similar finding in this patient can be seen fronto-parietal (Fig. 1e, f). In this location, distribution of cortical veins is asymmetric with a reduction in sulcus-poor polymicrogyrial areas (Fig. 1e, f, arrows) and with a concentration in polymicrogyrial areas with some

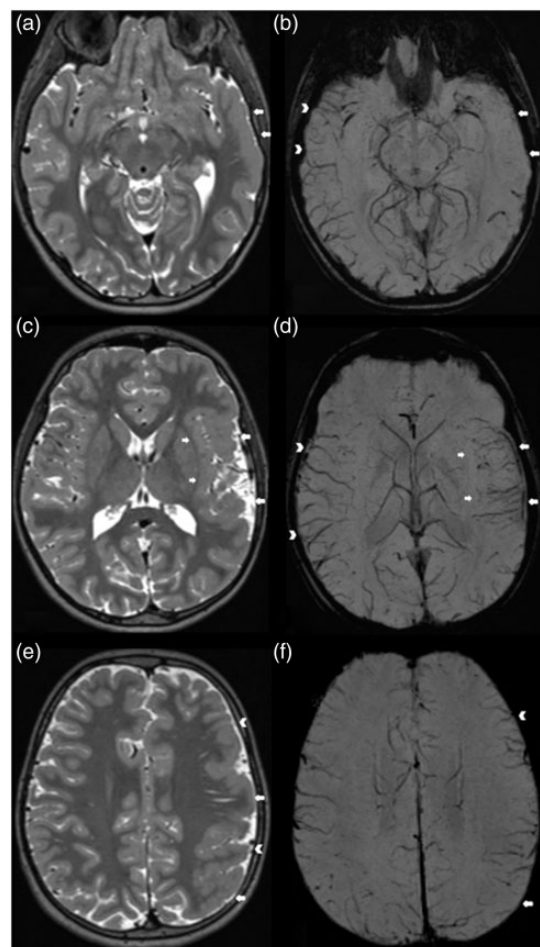


Fig. 1. Different pathological patterns of cortical veins in areas with PMG. PMG is seen in the left hemisphere in (a, c, e) (T2W images). The left temporal lobe reveals PMG and a complete absent pattern of cortical veins in SWI (arrows in (a, b)), while the cortical veins in the healthy right hemisphere appear regular. The affected perisylvian location (arrows in (c)) shows a pattern of finer and numerical increased cortical veins (arrows in (d)) compared to the regular right side (arrowheads in (d)). An asymmetrical distribution of cortical veins can be seen in PMG regions with different sulcal depths: The fronto-parietal areas reveal general PMG (arrows and arrowheads in (e)) with rarefaction of the cortical venous pattern in SWI in areas with extensively less gyration (arrows in (e, f)), but concentration and slight increase of the cortical venous pattern in SWI in areas with deeper sulci (arrowheads in (e, f)).

sulci (Fig. 1e, f, arrowheads). This case demonstrates a clear correlation between the pathological surface anatomy of PMG areas as seen in the T2W images and the appearance of cortical veins in SW images. Besides an abnormal anatomy, another possibility for focally missing cortical veins might be hypothetical a focal hyperperfusion, that leads to a reduced deoxyhemoglobin in cortical veins with less paramagnetic properties, as recently described in status epilepticus (8).

Another new study revealed a hyperperfusion in cortical dysplasia due to a higher microvessel density (11). This study supports the theory of reduced deoxyhemoglobin content in cortical veins. However, this would imply that a diminished appearance of cortical veins occurs in PMG areas in general, and as demonstrated in Fig. 1, this is not the case, since polymicrogyral areas with some sulcal depth show cortical veins.

The changed anatomy in PMG, with extensively reduced sulci, leads to the presented atypical venous appearance in SWI. SWI shows clear pathological venous pattern in the affected areas, indicating an abnormal parenchymal anatomy. Diagnosis of PMG can be difficult if low-field MR scanners or thicker imaging slices are used.

In conclusion, SWI might be a very helpful sequence in these cases for detecting PMG, further an additional marker in thin-slice MRI.

Declaration of conflicting interests

The author(s) declared no potential conflicts of interest with respect to the research, authorship, and/or publication of this article.

Funding

The author(s) received no financial support for the research, authorship, and/or publication of this article.

References

1. Guerrini R, Dobyns WB. Malformations of cortical development: clinical features and genetic causes. *Lancet Neurol* 2014;13:710–726.
2. Barkovich AJ, Kuzniecky RI, Jackson GD, et al. A developmental and genetic classification for malformations of cortical development. *Neurology* 2005;65:1873–1887.
3. Leventer RJ, Jansen A, Pilz DT, et al. Clinical and imaging heterogeneity of polymicrogyria: a study of 328 patients. *Brain* 2010;133:1415–1427.
4. Mittal S, Wu Z, Neelavalli J, et al. Susceptibility-weighted imaging: technical aspects and clinical applications, part 2. *Am J Neuroradiol* 2009;30:232–252.
5. Kao HW, Tsai FY, Hasso AN. Predicting stroke evolution: comparison of susceptibility-weighted MR imaging with MR perfusion. *Eur Radiol* 2012;22:1397–1403.
6. Verma RK, Hsieh K, Gratz PP, et al. Leptomeningeal collateralization in acute ischemic stroke: impact on prominent cortical veins in susceptibility-weighted imaging. *Eur J Radiol* 2014;83:1448–1454.
7. Bosemani T, Burton VJ, Felling RJ, et al. Pediatric hemiplegic migraine: role of multiple MRI techniques in evaluation of reversible hypoperfusion. *Cephalalgia* 2014;34:311–315.
8. Aellen J, Abela E, Buerki SE, et al. Focal hemodynamic patterns of status epilepticus detected by susceptibility weighted imaging (SWI). *Eur Radiol* 2014;24:2980–2988.
9. Leventer RJ, Phelan EM, Coleman LT, et al. Clinical and imaging features of cortical malformations in childhood. *Neurology* 1999;53:715–722.
10. Raybaud C, Girard N, Canto-Moreira N, et al. High-definition magnetic resonance imaging identification of cortical dysplasias: micropolygyria versus lissencephaly. In: Guerrini R, Andermann F, Canapicchi R, et al. (eds) *Dysplasias of Cerebral Cortex and Epilepsy*. Philadelphia, PA: Lippincott-Raven, 1996, pp.131–143.
11. Wintermark P, Lechpammer M, Warfield SK, et al. Perfusion imaging of focal cortical dysplasia using arterial spin labeling: correlation with histopathological vascular density. *J Child Neurol* 2013;28:1474–1482.