

Injectable Tissue Replacement and Regeneration: Anatomic Fat Grafting to Restore Decayed Facial Tissues

Steven R. Cohen, MD*
Hayley Womack, BS†

Summary: Aging is a dynamic process that can be modeled and understood tissue by tissue and cell by cell. Numerous authors have helped us understand the anatomy of facial fat compartments and the effects of aging on our facial tissues such as skin, fat, bone and fibrous ligaments. Injectable tissue replacement and regeneration (ITR2) is a method to replace decayed tissues of the face using “like tissues” in an effort to delay or slow the rate of tissue decay seen in facial aging. Facial topography and proportion analysis are performed to diagnose individual-specific losses of facial fat. The degree of sun damage and skin thinning is noted as is the degree of loss in the superficial fat compartment. Deep compartment fat loss is evaluated as is pyriform aperture, orbital, mandibular ramus, mandibular body, and chin resorption. From this analysis, a detailed treatment plan is formulated. Using a mechanical device, 3 different fat grafts are created: 2 mm (millifat), 1 mm (microfat), and 500 microns (cell optimized, matrix rich nanofat); anatomic replacement of all areas of tissue loss is carried out. Millifat is used for deep compartment and bone losses, microfat for superficial fat losses above the facial musculature and nanofat is used intradermally and as a biological cream for topical application. The rationale behind this standardized approach is explained and the scientific foundations for the idea are presented. Reduction in tissue decay appears to be a valid observation, but awaits others confirmation. (*Plast Reconstr Surg Glob Open* 2019;7:e2293; doi: 10.1097/GOX.0000000000002293; Published online 12 August 2019.)

BACKGROUND

Recent advances in our understanding of facial aging have resulted in significant insights into facial soft tissue and bony volume loss. Lambros¹ documented soft tissue photometric changes showing that the soft tissue of the face deflates with aging. Rohrich and Pessa² clarified the anatomy of the superficial and deep fat compartments and recommended that fat be injected into specific deep fat compartments in the face. Kahn and Shaw³ and Mendelson and Wong⁴ separately documented how the facial skeleton ages, losing broad surface areas of bone without the corresponding shrinkage of the soft tissue envelope. Advances in genetics have provided a basis for measuring

early interventions that have the potential to slow aging of cells and the finding of stem and regenerative cells in fat introduced the possibility of regenerating aging tissues, which was shown by Rigotti et al⁵ and supported by recent work by Cohen.^{6–8} Controlled trials of enzymatically derived stromal vascular fraction (SVF) in scleroderma and osteoarthritis have not reached statistical significance but have shown improvement over controls to the range of 20%–30% and in certain cases (ie, diffuse disease in scleroderma hands) statistically significant clinical benefits.^{9,10} There are almost no other therapies in aesthetics other than fat grafting, SVF-enriched fat grafting, nanofat grafting, platelet rich plasma, and growth factors that have demonstrated neoangiogenesis and “trophic” effects to some degree in virtually all subjects.^{5,11}

When a patient comes in for a consult for facial aging, they are evaluated at that particular moment in time. Yet, aging happens over a lifetime with growth and development primarily occurring during the first 22 years followed

From the *Division of Plastic Surgery, FACES+ Plastic Surgery, Skin, and Laser Center, University of California, San Diego, San Diego, Calif.; and †University of California, San Diego, San Diego, Calif. Received for publication March 11, 2019; accepted April 16, 2019.

Copyright © 2019 The Authors. Published by Wolters Kluwer Health, Inc. on behalf of The American Society of Plastic Surgeons. This is an open-access article distributed under the terms of the Creative Commons Attribution-Non Commercial-No Derivatives License 4.0 (CCBY-NC-ND), where it is permissible to download and share the work provided it is properly cited. The work cannot be changed in any way or used commercially without permission from the journal. DOI: 10.1097/GOX.0000000000002293

Disclosure: S.R.C. is an investigator in Allergan and Ampersand; stock options, advisor in ClearFast/BevMD; stock options, royalties in Millenium Medical; royalties in Stryker, Tulip, and Nanocube; and stock options in Mage Group. The other author has no financial interest to declare in relation to the content of this article.

by a continual and gradual decay of tissues until death. The anatomic and histologic changes due to aging can be seen in the skin, fat compartments, and underlying bone and in the dynamic relationships existing between them. Phenotypic shifts such as photodamage, laxity, and volume loss are the most prevalent results of these physical changes, although severity varies per individual. These changes are interrelated, and we can begin to model aging as a continuum of anatomic and physiologic changes occurring in an individual's tissues and cells. The question we should be asking is: "Can we model the anatomic and physiologic changes in our tissues and cells as they age and replace and/or regenerate the affected tissues as they decay, perhaps earlier in the decay process, thereby reducing the rate of decay and/or reversing or delaying aging in our tissues?" (Fig. 1).

UNDERSTANDING FACIAL AGING

Aging ultimately occurs as a complex interaction between our individual genetic composition and our particular responses to the outside and inside environment. These interactions lead to progressive deterioration of tissues and cells over time, beginning during the stage of growth and development. Our bodies do their best to supply new cells as others die, but this is not sustainable and decay accelerates.

The Skin

The skin is a complex organ that suffers from losses in function and integrity as the intrinsic and extrinsic processes of aging occur. Reduced thickness of the epidermis (about 6.4% per decade on average), decreased fibroblast content leading to slower collagen turnover rates, and increased elastin calcification are core characteristics of age disruptions in the skin.¹²⁻¹⁵ With continual sun damage, the rete pegs that engage the undersurface of the dermis as kind of "a tongue in groove" attachment begin to regress and the dermoepidermal junction becomes flattened. The thinning layers of the skin become more susceptible to separation due to both loss of microcirculation

and disengagement of rete pegs, 2 common consequences of sun damage.¹⁶⁻¹⁹ Aged skin has the histologic appearance of chronic inflammation (Fig. 2).

The Fat Compartments

Fat is separated into compartments by facial musculature and fascial ligaments (Figs. 3 and 4). Morphological changes in these compartments can be understood by analyzing the topography of the face.² True ligaments in the face arise from the periosteum, whereas as false ligaments do not start at the periosteal surface.²⁰ As the fascial septae move closer to the skin surface, they progressively arborize, leading to smaller and smaller subcompartments within the superficial fat compartments (Fig. 5).²¹ With age, there is a redistribution and loss of fat throughout the face along with changes in the intracellular matrix, decreased proliferation of cells (ie, preadipocytes), and reduced adhesion between tissues and the skin.²² Tear trough deformities appear as deep fat loss occurs in the periorbital region and medial SOOF. Decay of tissues in the malar fat pad results in ptosis, a phenomenon which enhances the appearance of tear trough deformities. Both the nasolabial folds and perioral lines gradually deepen. The patterns of these changes vary across individuals with most exhibiting combinations of superficial and deep compartment fat loss.

The Craniofacial Bones

Craniofacial growth is thought to be one of continuous expansion throughout life.²³ As the face ages, the orbits and pyriform aperture expand (Fig. 6). There is nonuniform resorption occurring simultaneously in the midface skeleton. The maxillary angle decreases significantly, around 10 degrees when young (age < 30 y) and older patients (age > 60 y) were compared, resulting in a loss of projection.^{4,24} The mandibular body gradually shrinks in height and width. In early adulthood, the facial skeleton reaches a "peak projection" and subsequent site-specific resorption begins to occur, particularly around the orbit, maxilla, pyriform region, and mandible.⁴

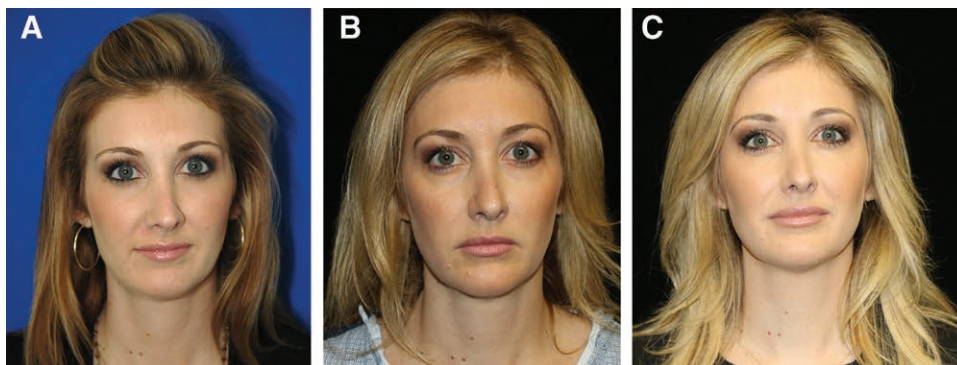


Fig. 1. A 33-year-old patient is shown (A) and (B) 6 years later, just before receiving full facial ITR² rejuvenation. In (B), the subtle signs of aging around the eyes, marionette basins, cheeks and pyriform region can be appreciated. At this stage, by replacing the lost volume in an anatomically precise manner that addresses all areas of deep and superficial fat loss, bone loss, skin atrophy, and photodamage, tissue mass is increased, blood supply improved, sustaining and replacing lost tissues and reducing or even reversing some elements of decay, and aging. C, Patient is shown 6 months after ITR². ITR², injectable tissue replacement and regeneration.

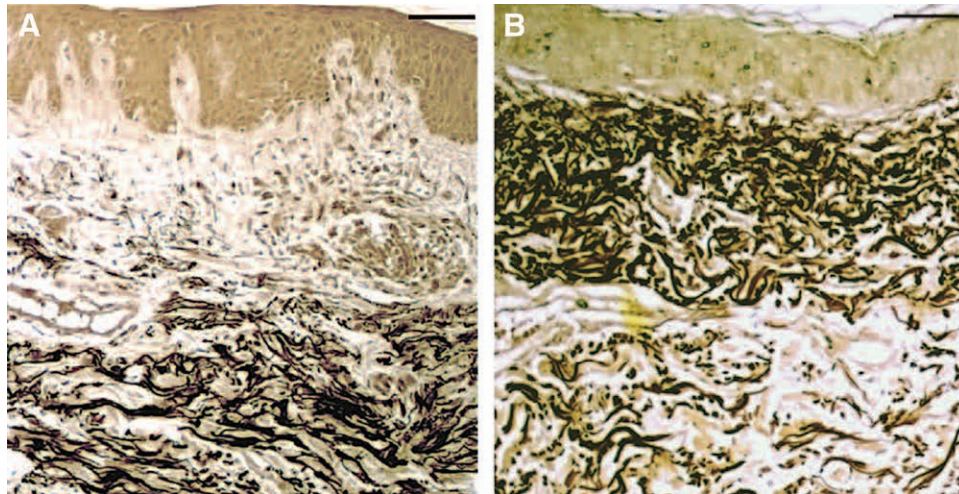


Fig. 2. In these photomicrographs, aged skin (A) has been treated with mechanically dissociated, SVF-enriched fat grafts (B). Three months after treatment, regeneration of elastin and collagen can be seen with improvement in capillary density. Reprinted with permission from *Plastic and Reconstr Surg.* 2015;135:999–1009.

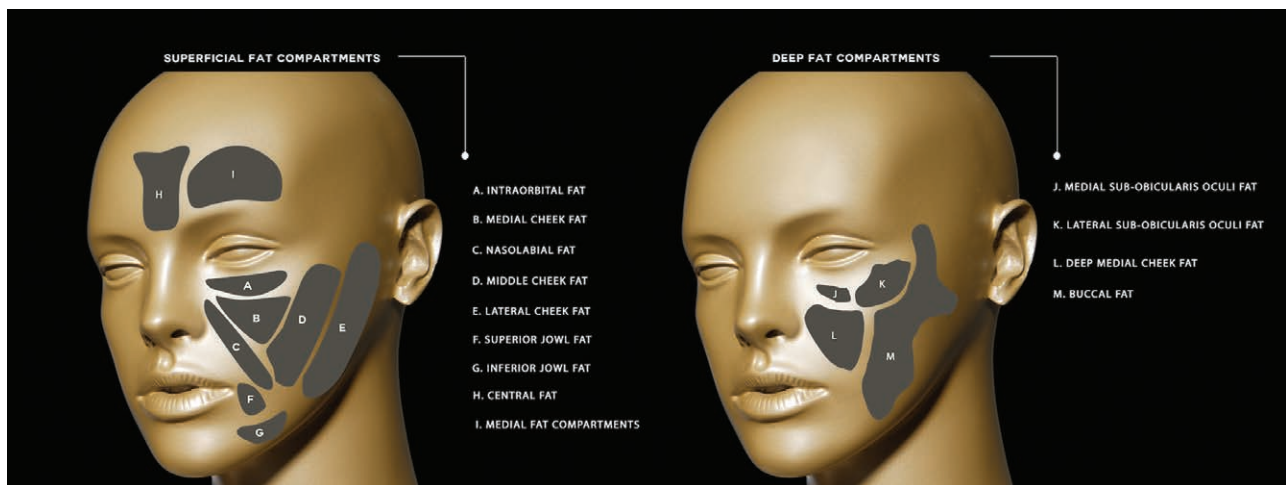


Fig. 3. The superficial and deep fat compartments of the face.

Two interesting and somewhat related theories pertaining to aging of the facial skeleton are Wolff's Law and the Functional Matrix Hypothesis. Wolff's Law proposes that bone shape changes in response to load.^{25–28} From this, we can infer the atrophy and intrinsic aging of both the subcutaneous superficial and deep fat compartments may lead to reduced loading on the craniofacial skeleton thus producing patterns of bone loss. Depending on the underlying dentition, these bony changes can be accelerated as masticatory loading is changed thus contributing to the erosion of facial volume. The Functional Matrix Hypothesis suggests that bone growth is primarily stimulated by genetic processes; however, with time a secondary, compensatory response to the expansion of the surrounding soft tissue matrix occurs.²⁹

The Retaining Ligaments

The idea that ligaments, especially the zygomatic retaining ligament, stretch with age remains a supposition.

In one study, Lambros¹ suggested that the fibrous network in the face, including the retaining ligaments are relatively immobile and the changes taking place in the aging face are not solely due to gravitational forces, but losses in soft tissue and bone.¹ In surgery, retaining ligaments are difficult to cut, which leads us to think age-related stretching of these ligaments is unlikely unless there is histologic or gross findings of ligamentous tears and disruptions. When we think about a person who has lost substantial weight, the belt does not increase in size, rather, it has a relative appearance of redundancy. The lax appearance of one's belt after weight loss may be analogous to what has been observed in the retaining ligaments in the face, as the underlying deep and superficial fat compartments begin to atrophy, the ligaments appear redundant. Slack retaining ligaments could potentially transmit less force to the underlying bone therefore potentiating bone atrophy as theorized by Wolff's Law.²⁵

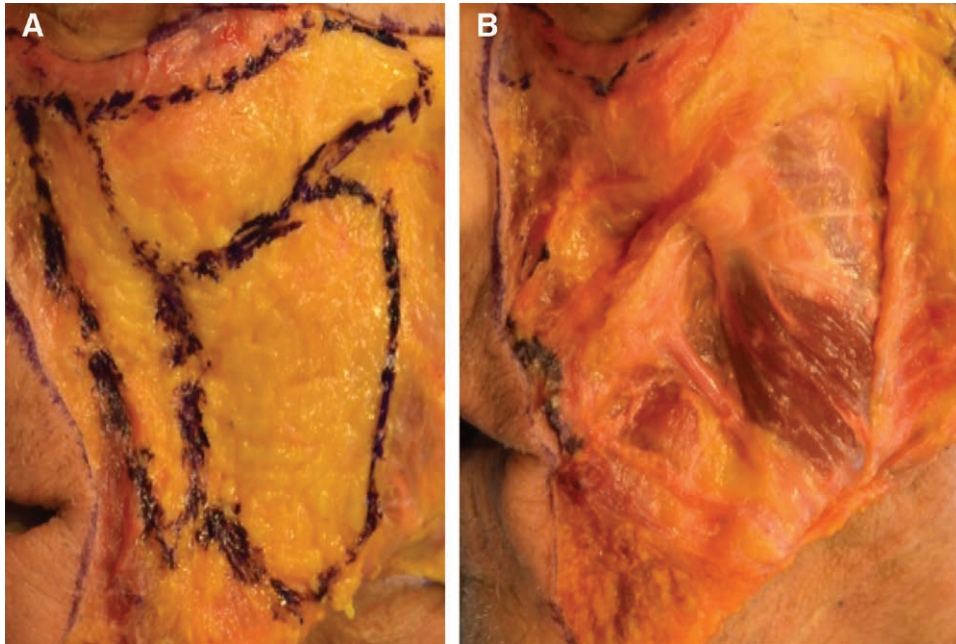


Fig. 4. Cadaver dissections of superficial (A) and deep (B) fat compartments of the midface. Note the deep fat compartments are below the muscles and more “pillowy,” like buccal fat, whereas the superficial fat is more tightly clustered parcels separated by increasingly arborized fascial extensions.

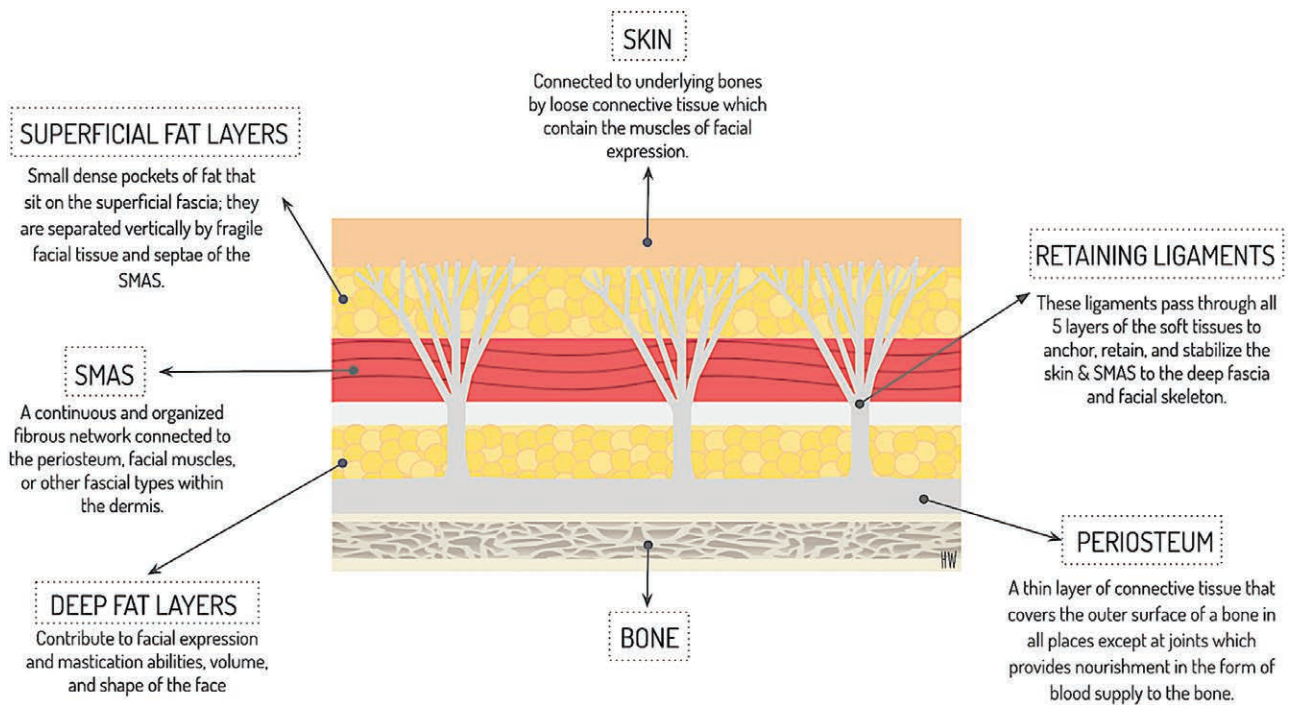


Fig. 5. Arborization of the retaining ligaments through the 5 facial layers. SMAS, superficial muscular aponeurotic system.

INJECTABLE TISSUE REPLACEMENT AND REGENERATION

Injectable Tissue Replacement and Regeneration (ITR²) is a new, standardized method of fat grafting which:

1. diagnoses the anatomic components of volume loss by evaluating the surface topography of the face;
2. addresses specific anatomic losses of these different tissues, including skin, facial fat in the deep and superficial compartments, and bone; and
3. replaces these anatomic losses of fat and bone with autogenous or allogeneic fat grafts (and allogeneic bone) that are sized for structural replacement of

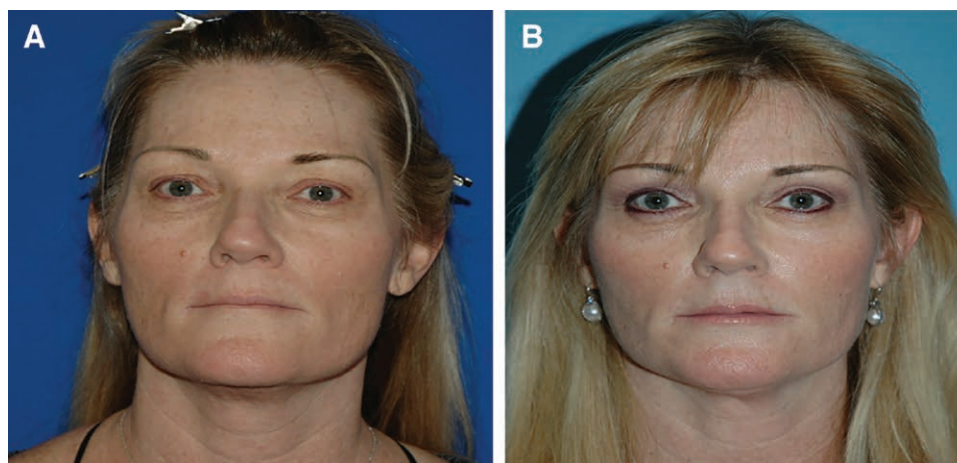

Fig. 6. A 54-year-old woman who presented with modest sun damage, superficial and deep compartment fat loss and mild laxity seen in the jowls and neck. Orbital expansion created a subtle appearance of pseudoptosis and “senile” enophthalmos, which according to the patient looked as if her “eyes were falling back into her skull.” The appearance of the aged orbit and periorbital tissues in some patients is analogous to a posttraumatic orbital deformity, where correction of the orbital volume enlargement corrects the pseudoptosis (A). This patient underwent ITR² fat grafting to all areas of tissue loss, including the upper eyelid sulcus beneath the orbicularis, intraorbital fat grafting in the inferior lateral aspect of the orbit, the lips and pyriform, deep and superficial fat compartments of the cheeks, upper and lower eyelids, supraorbital rims, forehead and temples as well as the inferior mandibular border and gonial angle along with “pinch” upper and lower blepharoplasties. B, Patient is shown at 1 year postoperatively. ITR², injectable tissue replacement and regeneration.

bone and deep fat losses, superficial fat replacement, and dermal and epithelial replacement and/or regeneration (Fig. 7). (See Video 1 [online], which displays full facial rejuvenation pre-facelift using the Injectable Tissue Replacement and Regeneration technique.)

Regenerative effects may be augmented with Nanofat (primarily a matrix product that, depending on how its processed, contains adipocyte-derived stem cells, SVF cells, and growth factors), Platelet Rich Plasma, and mechanically dissociated SVF.³⁰ This combination of anatomic fat replacement supplemented with a menu of regenerative ingredients can be tailored to patient-specific needs.

In ITR², the basic principles of the Coleman technique are both preserved and expanded upon through the introduction of an anatomic and regenerative approach, which replenishes fat in the superficial and deep fat compartments and the supraperiosteal regions of the pyriform and mandible as well as other areas of bone, fat, and skin atrophy.³¹ We believe, as Coleman does, that small microparticles of fat are placed into tissues to optimize their interface. Fat is not uniformly distributed in the face, but separated into compartments both above and below the facial musculature and facial ligaments.² Fat is more tightly clustered in the superficial compartments above the muscles and larger and more loosely organized in the deep compartments below the facial musculature. Analysis of facial topography helps us understand and see the anatomic changes occurring in various layers of the face (Fig. 7) (See Video 1 [online],

which displays full facial rejuvenation pre-facelift using the Injectable Tissue Replacement and Regeneration technique.)²

As surgical artists, it is tempting to use fat as if it were “clay” for the sculptor, to be placed wherever we think it may create an aesthetic outcome. However, with our present understanding of the anatomy of the face and how it ages, it is highly important to place the fat in proper sized grafts into the correct anatomical compartments of loss.^{32–34} ITR² attempts to mimic the parcel sizes seen in the deep and superficial compartments and account for safety by modifying fat into different sizes according to the fat compartment treated, degree of bone loss, and extent of skin damage (See Video 1 [online], which displays full facial rejuvenation pre-facelift using the Injectable Tissue Replacement and Regeneration technique).

The ITR² technique begins with a 14-gauge needle puncture to create an entry site for a 12-holed cannula with openings measuring 2.5 mm in diameter. The harvest results in 2.5-mm fat parcel sizes, referred to as Millifat, which is then rinsed with Ringers Lactate and permit the solution to decant. The fat is then processed using the Nanocube (Lipocube, Inc., London, England) resizing device, which creates 2 more parcel sizes: Microfat (1 mm) and Nanofat (>500 microns) (See Video 2 [online], which displays harvested fat is resized from millifat into microfat and nanofat using Nanocube from Lipocube, Inc., London, England).^{34,35}

One cleaning is completed with Ringer’s lactate and decanting, a portion of Millifat is set to the side for later use to replenish deep fat compartment loss and bone

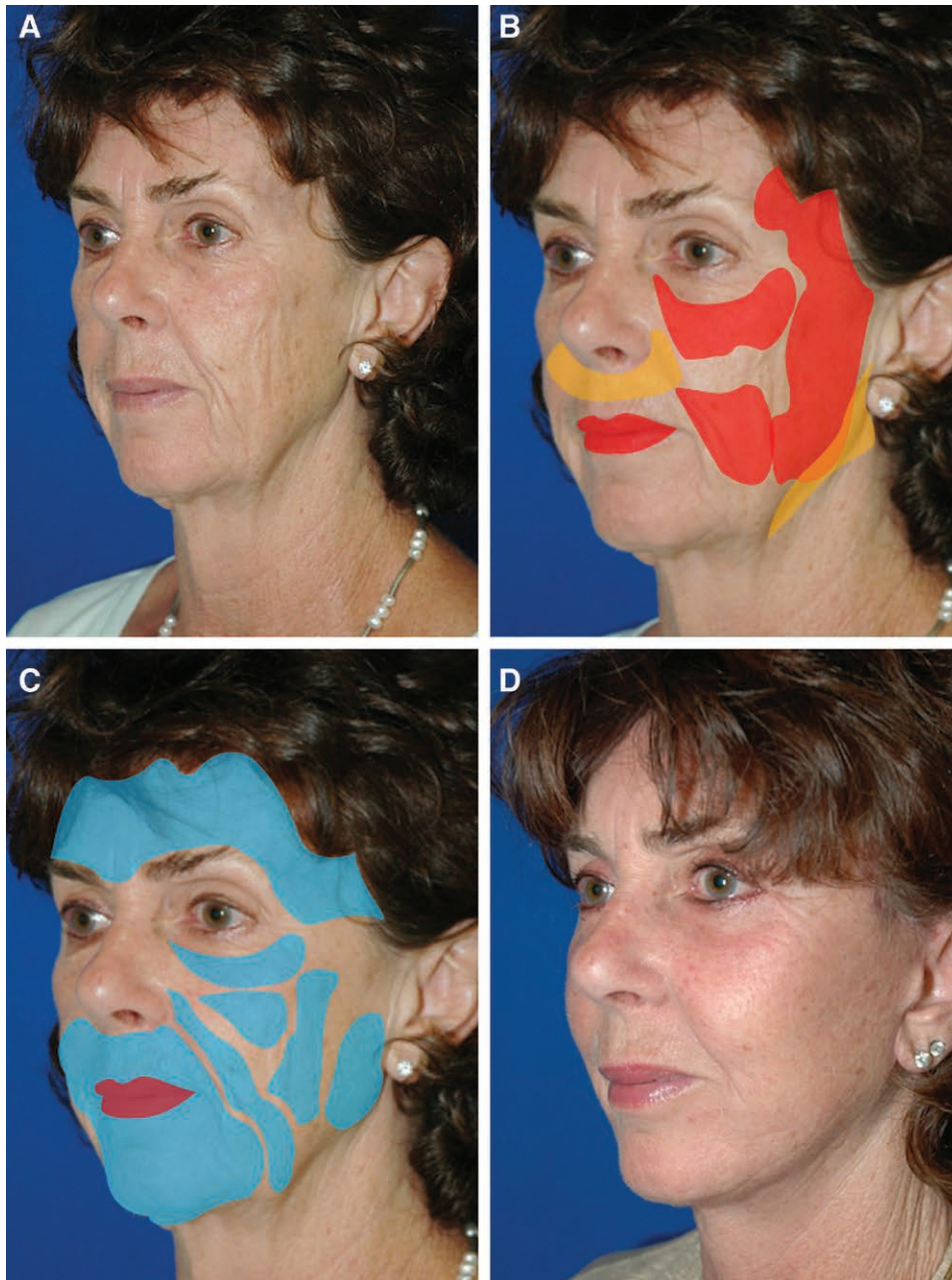

Fig. 7. A, A 67-year-old patient is shown with fat loss in superficial and deep fat compartments, modest sun damage, and modest skin laxity. B, The ITR² treatment plan is created for each individual patient based on areas of bone and fat loss and skin thinning. The red overlays represent areas of deep fat loss to be treated with millifat, and the orange areas represent areas of bone loss to be addressed with millifat. C, The blue overlays represent areas of superficial fat loss to be treated with microfat and/or nanofat. D, Patient is shown 6 months postoperatively. ITR², injectable tissue replacement and regeneration.

recession. The remaining fat is transferred into 20-ml syringes to be further processed into Microfat and Nanofat using the Nanocube kit (See Video 2 [online]).

Millifat is used for deep compartment fat loss, areas of bone loss, and for treatment of the aging nose and senile enophthalmos; microfat is used for superficial fat compartments, intradermal injection in deeper creases, and rhytids and hands; nanofat is used for tear troughs,

intra-dermal injection, microneedling into the epithelium and dermis, and as a biocream compounded with a liposomal transdermal delivery vehicle. This newly standardized fat grafting technique was evaluated after ITR² and facelift surgery.^{32,35} Improvement in facial volume (measured via 3D photometry) was seen up to 24 months following treatment with no weight gain in any of the patients.³⁵ These findings need to be validated in



Fig. 8. The 12-holed harvesting cannula with 2.5 mm diameter hole sizes used for direct harvest of millifat.

larger studies, but they do make sense when one considers the dynamic changes that occur as a fat graft becomes incorporated.

Generally, fillers are injected based on an aesthetic, but not anatomic approach. Although, Swift and Remington³⁶ and Mendelson²¹ have used a more anatomically and proportion-oriented approach to improve aesthetic outcomes with synthetic fillers³⁷; synthetic fillers have very little beneficial effects to the tissues surrounding them. When ITR² is performed, anatomic replacement of the lost tissues is addressed and there is a gain of soft tissue mass. Neovascularization occurs to some degree in virtually every patient.^{5,38,39}

TREATMENT PLANNING AND FACIAL ANALYSIS FOR ITR²

Different patterns of fat loss and bone can be seen in a patient's facial topography. For instance, take the 3 women shown in Figures 6A, 7A, and 9A. Figure 6A shows a 54-year-old woman who presented with modest sun damage, superficial and deep compartment fat loss, and mild laxity seen in the jowls and neck. Orbital expansion created a subtle appearance of pseudoptosis and "senile" enophthalmos. The appearance of the aged orbit and periorbital tissues in some patients is analogous to a posttraumatic orbital deformity, where correction of the orbital volume enlargement corrects the pseudoptosis.⁴⁰ This patient underwent ITR² to all areas of tissue loss, including the upper eyelid sulcus beneath the orbicularis, intraorbital fat grafting in the inferior lateral aspect of the orbit, the lips and pyriform, deep and superficial fat compartments of the cheeks, upper and lower eyelids, supraorbital rims, forehead and temples, and the inferior mandibular border and gonial angle along with "pinch" upper and lower blepharoplasties (Fig. 6B).

The other 2 women in Figures 7A and 9A have superficial and deep fat loss as well as dermal and epithelial thinning. Both patients required fat grafting in the superficial and deep compartments as well as in areas of bone loss. A Fractional 1927-nm laser was used and Millifat was placed in the buccal space, deep temporal extension of the buccal fat pad, lips, and supraorbital rims. Microfat was placed in the subcutaneous plane of the forehead and perioral tissues as well as the upper and lower eyelids. Nanofat was microneedled into the skin of the entire face (**See Video 3 [online]**, which displays nanofat combined with a liposomal transport agent and used in conjunction with microneedling).

High SMAS facelifts along with pinch upper and lower blepharoplasties were performed in both of these patients (Figs. 7B and 9B).

Genetics play a significant role in how stem and regenerative cells perform. Harvested cells consist of the same genetic makeup of the host, so we can expect similar behavior of this tissue once engraftment takes place. Some people age more rapidly than others and their tissues and cells will likely be less effective when used for regenerative effects. As with any autologous and allogeneic tissues, patients will need to understand that realistically serial treatments may need to be repeated to reduce tissue decay.

In our clinic, ITR² is recommended in patients requesting more than one filler and, in most patients, seek-

ing facial rejuvenation (Fig. 7). Serial resurfacing with fractional lasers in combination with platelet rich plasma (PRP) and/or nanofat provides ongoing stimulation of tissue and may delay decay in the skin and dermis as well as underlying tissue. Facial motion is reduced using neurotoxins. Sun protection and proper nutrition and exercise can help to further delay aging in tissues.

ITR² COMBINED WITH OTHER REGENERATIVE TREATMENTS

Although ITR² can be performed with fat alone, to achieve fully individualized treatments for patients, it is usually used in combination with treatments such as SVF-enriched fat, platelet rich plasma, nanofat, and fractional lasers. The layers of the face age through various intertwining processes. To counteract these processes, it makes sense to use multiple treatments which function to enhance and support each other when replacing and regenerating decayed tissue. Depending on the degree of facial laxity, energy-based devices to a range of different face and neck lift options including high SMAS, SMASectomy, plication and digastric muscle, and gland reduction are implemented as needed.

SVF-enriched Fat

In 2001, Zuk et al^{7,41} published an article entitled “Multilineage Cells from Human Adipose Tissue: Implications for Cell-Based Therapies.” This article, along with subsequent publications by the same author, opened up the possibilities of using cell populations within fat for a variety of therapies. The cell populations found within fat are primarily vascular and stromal cells, hence the terminology SVF.

The SVF is everything but the adipose cells. It is a mixed population of mesenchymal stem cells, preadipocytes, endothelial and smooth muscle cells, pericytes, tissue macrophages, adipocyte-derived stem cells, a variety of undefined SVF cells, and white blood cells.⁴² Stem cells only account for about 1% of this population; however, relative to bone marrow which contains about 5,000 SVF cells per milliliter, fat contains 500,000 of these cells.⁴² In addition to the SVF cells, numerous growth factors such as bFGF, IGF-1, VEGF, and PDGF-BB are expressed.⁴³

The use of SVF in patients has somewhat unanticipated regenerative effects.⁴⁴ For instance, when SVF-enriched fat is utilized in nasolabial folds and lips, there is a broad perioral effect (Fig. 10). Rigotti et al⁵ showed that mechanically dissociated SVF-enriched fat demonstrated histologic evidence of regeneration in both elastin and collagen fiber architecture as well as angiogenesis (Fig. 2). Efficacy of adipose tissue supplemented with stem and regenerative cells obtained from the SVF of fat has been demonstrated by other authors.^{45–47}

ITR² in Combination with Fractional Laser Resurfacing:

Our team has had experience with fractional lasers since their introduction in 2004. The injury that occurs with the fractional 1,927 nm wavelength laser and a fractionated CO₂ laser provides numerous microscopic

openings through which vitamins, peptides, cosmeceuticals, certain sized growth factors or fragments, and other agents can be delivered (Masters of Aesthetics Meeting, San Diego, Calif., 2018).^{48–51} We have recently studied a group of 33 patients who had combination resurfacing and regenerative treatments with Nanofat and fractional 1,927-nm lasers and demonstrated substantially more new elastin fibers than fractional lasers alone. It appears that application of Nanofat within a short time after fractional 1,927-nm laser leads to marked improvement in the elastin fibers, and compared with historical controls, more rapid healing and a one- to two-point improvement on a Likert scale for wrinkles and texture across all Fitzpatrick skin types (abstract was presented at Master of Aesthetics August 2018) (Fig. 9).⁴⁸

PRP ± ITR²

PRP is defined as plasma with a platelet count above the count in that of peripheral blood.⁵² When activated, platelets release several growth factors making them beneficial to the replacement and regeneration of decayed tissue.^{49,53,54} These growth factors stimulate processes such as matrix formation, cell proliferation, cell differentiation, and angiogenesis.⁵² Modarressi⁵² demonstrated that PRP fat grafts results in better overall fat grafting survival as well as a reduction in bruising and inflammation. Studies by Li et al⁵⁵ and Modarressi⁵² demonstrated that the addition of PRP to fat grafts increased fat cell survival rate and adipose stem cell proliferation. The volume of fat grafts was improved and the overall retention was improved.^{52,55} PRP is utilized as an injection into the tissues or mixed 20%–80% fat and injected via cannulas. Our preference is to use PRP with all patients undergoing ITR², we recommend its use every 4–6 months as maintenance to prevent or delay tissue decay.⁵²

CONCLUSIONS

Aging is a dynamic process that can be modeled. ITR² is a method to replace decayed tissues of the face using “like tissues” in an effort to delay or slow the rate of tissue decay seen in facial aging. Facial topography and proportion analysis are performed to diagnose individual-specific losses of facial fat. The degree of sun damage and skin thinning is noted as is the degree of loss in the superficial fat compartment. Deep compartment fat loss is evaluated as is pyriform aperture, orbital, mandibular ramus, mandibular body, and chin resorption. From this analysis, a detailed treatment plan is formulated.

Using a new mechanical device, Nanocube, 3 different fat grafts are created: 2.5 mm (milliflat), 1 mm (microfat), and 800 microns (cell optimized, matrix rich nanofat). Anatomic replacement of all areas of tissue loss is carried out.⁴⁵ Milliflat is used for deep compartment and bone losses, microfat for superficial fat losses above the facial musculature, and nanofat is used intradermally and as a biological cream for topical application. In some patients, more fat will survive, and the volume improvement and regenerative effects may be more pronounced. In others, less effect will be noted. In part, this variability is related

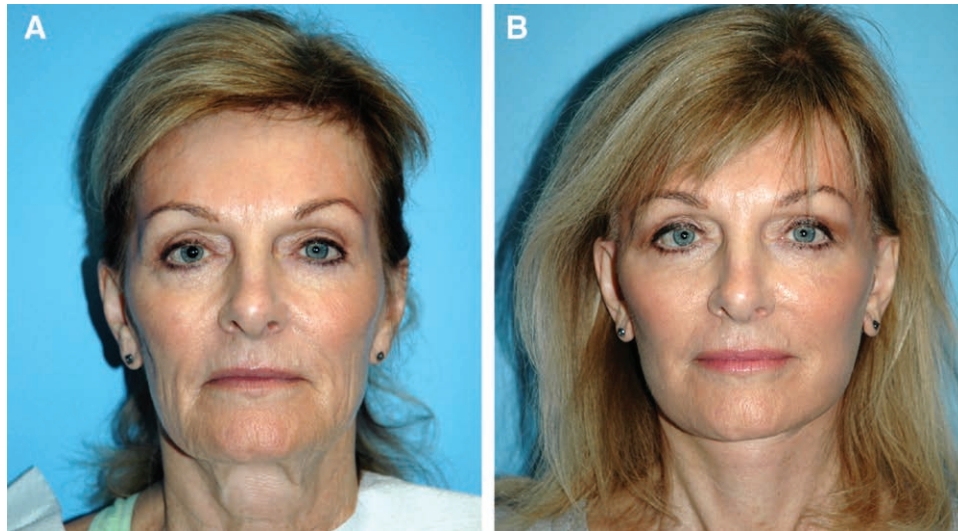

Fig. 9. A, A 70-year-old patient with superficial fat and deep fat loss is shown preoperatively. B, Patient is shown 6 months postoperatively after being treated with a facelift (high SMAS), Platysmaplasty, U/L Bleph, 18 ml of SVF-enriched fat grafting in 3 sizes to the upper eyelid sulcus, lips, buccal fat pad, temporal regions, forehead, perioral tissues, deep medial cheek and medial and lateral SOOF, and a dual fractional laser. SMAS, superficial muscular aponeurotic system; SOOF, suborbicularis oculi fat; SVF, stromal vascular fraction.

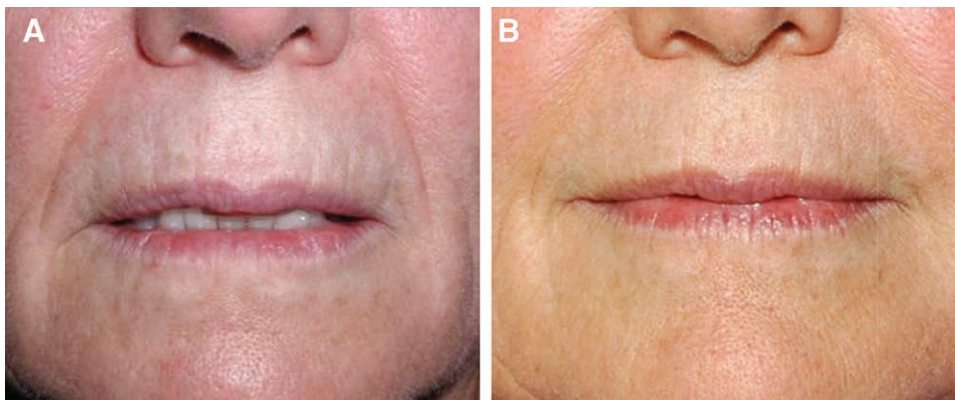


Fig. 10. A, Patient is shown preoperatively with deepened nasolabial folds and fine lines around the lips. B, Patient is shown 6 years postoperatively after her perioral region was injected with SVF-enriched cells to treat nasolabial folds, lips and radial wrinkle lines of the perioral tissues that had deepened due to age. SVF, stromal vascular fraction.

to the use of our own materials, which are under our genetic controls. Some people age more rapidly in the same environment as another person with similar exposure. Because we are working with the individual's cells and tissues, likely these are subject to the same inherent variability. This does not mean a treatment does not work, it means that it works to lesser extent in some individuals. This special topic paper is a compilation of many ideas, gathered under an umbrella of a new concept, ITR².

Steven R. Cohen, MD
 4510 Executive Drive
 Suite 200, San Diego, CA 92121
 E-mail: scohen@facesplus.com

REFERENCES

1. Lambros V. Observations on periorbital and midface aging. *Plast Reconstr Surg.* 2007;120:1367–1376; discussion 1377.
2. Rohrich RJ, Pessa JE. The fat compartments of the face: anatomy and clinical implications for cosmetic surgery. *Plast Reconstr Surg.* 2007;119:2219–2227; discussion 2228.
3. Kahn DM, Shaw RB Jr. Aging of the bony orbit: a three-dimensional computed tomographic study. *Aesthet Surg J.* 2008;28:258–264.
4. Mendelson B, Wong CH. Changes in the facial skeleton with aging: implications and clinical applications in facial rejuvenation. *Aesthetic Plast Surg.* 2012;36:753–760.
5. Rigotti G, Charles-de-Sá L, Gontijo-de-Amorim NF, et al. Expanded stem cells, stromal-vascular fraction, and platelet-rich plasma enriched fat: comparing results of different facial reju-

- venation approaches in a clinical trial. *Aesthet Surg J*. 2016;36:261–270.
6. Hannum G, Guinney J, Zhao L, et al. Genome-wide methylation profiles reveal quantitative views of human aging rates. *Mol Cell*. 2013;49:359–367.
 7. Zuk PA, Zhu M, Mizuno H, et al. Multilineage cells from human adipose tissue: implications for cell-based therapies. *Tissue Eng*. 2001;7:211–228.
 8. Cohen SR. Commentary on: expanded stem cells, stromal-vascular fraction, and platelet-rich plasma enriched fat: comparing results of different facial rejuvenation approaches in a clinical trial. *Aesthet Surg J*. 2016;36:271–274.
 9. Cytori Therapeutics. Scleroderma treatment with celution processed adipose derived regenerative cells (STAR). In: *ClinicalTrials.gov [Internet]*. Bethesda, Md.: National Library of Medicine (US).
 10. Cytori Therapeutics. Celution prepared adipose derived regenerative cells in the treatment of osteoarthritis of the knee (ACT-OA Knee). In: *ClinicalTrials.gov [Internet]*. Bethesda, Md.: National Library of Medicine (US).
 11. Kamakura T, Kataoka J, Maeda K, et al. Platelet-rich plasma with basic fibroblast growth factor for treatment of wrinkles and depressed areas of the skin. *Plast Reconstr Surg*. 2015;136:931–939.
 12. Duncan KO, Leffell DJ. Preoperative assessment of the elderly patient. *Dermatol Clin*. 1997;15:583–593.
 13. Waller JM, Maibach HI. Age and skin structure and function, a quantitative approach (I): blood flow, pH, thickness, and ultrasound echogenicity. *Skin Res Technol*. 2005;11:221–235.
 14. Harvell JD, Maibach HI. Percutaneous absorption and inflammation in aged skin: a review. *J Am Acad Dermatol*. 1994;31:1015–1021.
 15. Oribe HA, Bucks DA, Maibach HI. Percutaneous absorption of hydrocortisone and testosterone on the vulva and forearm: effect of the menopause and site. *Br J Dermatol*. 1996;134:229–233.
 16. Martini F. *Fundamentals of Anatomy and Physiology*. San Francisco: Benjamin-Cummings; 2004.
 17. Südel KM, Venzke K, Mielke H, et al. Novel aspects of intrinsic and extrinsic aging of human skin: beneficial effects of soy extract. *Photochem Photobiol*. 2005;81:581–587.
 18. Neerken S, Lucassen GW, Bisschop MA, et al. Characterization of age-related effects in human skin: a comparative study that applies confocal laser scanning microscopy and optical coherence tomography. *J Biomed Opt*. 2004;9:274–281.
 19. Grove GL. Physiologic changes in older skin. *Clin Geriatr Med*. 1989;5:115–125.
 20. Alghoul M, Codner MA. Retaining ligaments of the face: review of anatomy and clinical applications. *Aesthet Surg J*. 2013;33:769–782.
 21. Mendelson BC. Extended sub-SMAS dissection and cheek elevation. *Clin Plast Surg*. 1995;22:325–339.
 22. Gosain AK, Klein MH, Sudhakar PV, et al. A volumetric analysis of soft-tissue changes in the aging midface using high-resolution MRI: implications for facial rejuvenation. *Plast Reconstr Surg*. 2005;115:1143–1152; discussion 1153.
 23. Enlow DH. A morphogenetic analysis of facial growth. *Am J Orthod*. 1966;52:283–299.
 24. Pessa JE. An algorithm of facial aging: verification of lambros's theory by three-dimensional stereolithography, with reference to the pathogenesis of midfacial aging, scleral show, and the lateral suborbital trough deformity. *Plast Reconstr Surg*. 2000;106:479–488; discussion 489.
 25. Woo SL, Kuei SC, Amiel D, et al. The effect of prolonged physical training on the properties of long bone: a study of Wolff's law. *J Bone Joint Surg Am*. 1981;63:780–787.
 26. Wallace JM, Rajachar RM, Allen MR, et al. Exercise-induced changes in the cortical bone of growing mice are bone- and gender-specific. *Bone*. 2007;40:1120–1127.
 27. Chen JH, Liu C, You L, et al. Boning up on Wolff's law: mechanical regulation of the cells that make and maintain bone. *J Biomech*. 2010;43:108–118.
 28. Boskey AL, Coleman R. Aging and bone. *J Dent Res*. 2010;89:1333–1348.
 29. Premkumar S. *Control Mechanisms in Craniofacial Growth*. Craniofacial Growth JP Medical Ltd; New Delhi, India. 2011:70–78.
 30. Tonnard P, Verpaele A, Peeters G, et al. Nanofat grafting: basic research and clinical applications. *Plast Reconstr Surg*. 2013;132:1017–1026.
 31. Coleman SR, Katzel EB. Fat grafting for facial filling and regeneration. *Clin Plast Surg*. 2015;42:289–300.
 32. Cohen SR, Hewett S, Ross L, et al. Regenerative cells for facial surgery: biofilling and biocontouring. *Aesthet Surg J*. 2017;37:S16–S32.
 33. Rohrich RJ, Ghavami A, Constantine FC, et al. Lift-and-fill 445 face lift: integrating the fat compartments. *Plast Reconstr Surg*. 2014;133:756–767.
 34. Sykes JM, Cotofana S, Trevidic P, et al. Upper face: clinical anatomy and regional approaches. *Plast Reconstr Surg*. 2015;136:204S–218S.
 35. Cohen SR, Hewett S, Ross L, et al. Progressive improvement in midfacial volume 18 to 24 months after simultaneous fat grafting and facelift: an insight to fat graft remodeling [published online October 18, 2019]. *Aesthet Surg J*. doi:10.1093/asj/sjy279.
 36. Swift A, Remington K. Beautification™: a global approach to facial beauty. *Clin Plast Surg*. 2011;38:347–377, v.
 37. Surek C, Beut J, Stephens R, et al. Volumizing viaducts of the midface: defining the beut techniques. *Aesthet Surg J*. 2015;35:121–134.
 38. Pallua N, Pulsfort AK, Suschek C, et al. Content of the growth factors bfgf, IGF-1, VEGF, and PDGF-BB in freshly harvested lipoaspirate after centrifugation and incubation. *Plast Reconstr Surg*. 2009;123:826–833.
 39. Rubina K, Kalinina N, Efimenko A, et al. Adipose stromal cells stimulate angiogenesis via promoting progenitor cell differentiation, secretion of angiogenic factors and enhancing vessel maturation. *Tissue Eng Part A*. 2009;15:2039–2050.
 40. Cohen SR, Kawamoto HK Jr. Analysis and results of treatment of established posttraumatic facial deformities. *Plast Reconstr Surg*. 1992;90:574–584.
 41. Zuk PA, Zhu M, Ashjian P, et al. Human adipose tissue is a source of multipotent stem cells. *Mol Biol Cell*. 2002;13:4279–4295.
 42. Gaur M, Dobke M, Lunyak VV. Mesenchymal stem cells from adipose tissue in clinical applications for dermatological indications and skin aging. *Int J Mol Sci*. 2017;18:208.
 43. Nagaoka A, Yoshida H, Nakamura S, et al. Regulation of hyaluronan (HA) metabolism mediated by HYBID (hyaluronan-binding protein involved in HA depolymerization, KIAA1199) and HA synthases in growth factor-stimulated fibroblasts. *J Biol Chem*. 2015;290:30910–30923.
 44. Charles-de-Sa L, Gontijo-de-Amorim NF, Maeda Takiya C, et al. Antiaging treatment of the facial skin by fat graft and adipose-derived stem cells. *Plastic and Reconstr Surg*. 2015;135:999–1009.
 45. Kølbe SF, Fischer-Nielsen A, Mathiasen AB, et al. Enrichment of autologous fat grafts with ex-vivo expanded adipose tissue-derived stem cells for graft survival: a randomised placebo-controlled trial. *Lancet*. 2013;382:1113–1120.
 46. Mailey B, Saba S, Baker J, et al. A comparison of cell-enriched fat transfer to conventional fat grafting after aesthetic procedures using a patient satisfaction survey. *Ann Plast Surg*. 2013;70:410–415.

47. Tanikawa DY, Agüena M, Bueno DF, et al. Fat grafts supplemented with adipose-derived stromal cells in the rehabilitation of patients with craniofacial microsomnia. *Plast Reconstr Surg*. 2013;132:141–152.
48. Cohen S, Goodacre, A. Nanofat plus fractional laser accelerates healing and improves outcomes. Paper presented at Master of Aesthetics; August 2018.
49. Nita AC, Orzan OA, Filipescu M, et al. Fat graft, laser CO₂ and platelet-rich-plasma synergy in scars treatment. *J Med Life*. 2013;6:430–433.
50. Min S, Yoon JY, Park SY, et al. Combination of platelet rich plasma in fractional carbon dioxide laser treatment increased clinical efficacy of for acne scar by enhancement of collagen production and modulation of laser-induced inflammation. *Lasers Surg Med*. 2018;50:302–310.
51. Genina EA, Bashkatov AN, Dolotov LE, et al. Transcutaneous delivery of micro- and nanoparticles with laser microporation. *J Biomed Opt*. 2013;18:111406.
52. Modarressi A. Platelet rich plasma (PRP) improves fat grafting outcomes. *World J Plast Surg*. 2013;2:6–13.
53. Gentile P, Di Pasquali C, Bocchini I, et al. Breast reconstruction with autologous fat graft mixed with platelet-rich plasma. *Surg Innov*. 2013;20:370–376.
54. Liang ZJ, Lu X, Li DQ, et al. Precise intradermal injection of nanofat-derived stromal cells combined with platelet-rich fibrin improves the efficacy of facial skin rejuvenation. *Cell Physiol Biochem*. 2018;47:316–329.
55. Li H, Zimmerlin L, Marra KG, et al. Adipogenic potential of adipose stem cell subpopulations. *Plast Reconstr Surg*. 2011;128:663–672.