

# Effects of oxybutynin in children with posterior urethral valves post fulguration: Report in a select cohort of children

Joshua Jonathan Norris<sup>1</sup>, Jeffrey Pradeep Raj<sup>2,#</sup>, Tia Teresa Thomas<sup>1</sup>,  
Tijo Thomas Maleperambal<sup>1</sup>, Attibele Mahadevaiah Shubha<sup>3</sup>

<sup>1</sup>Medical Student, St. John's Medical College, <sup>2</sup>Department of Pharmacology, St. John's Medical College, <sup>3</sup>Department of Paediatric Surgery, St. John's Medical College Hospital, Bengaluru, Karnataka, India

#Present Affiliation: Department of Clinical Pharmacology, Seth GS Medical College and King Edward Memorial Hospital, Parel, Mumbai - 400 012, Maharashtra, India

## ABSTRACT

**Objectives:** Posterior urethral valves (PUV) is the commonest obstructive uropathy with varied consequences. Though valve fulguration is the treatment of choice, appropriate bladder management modifies outcome and includes rational use of anticholinergics. Here, we aim to evaluate the effects of oxybutynin on the bladder and urinary tract morphology and function. Concurrently, we document adverse effects encountered, patient compliance, and medication adherence. **Methods:** A retrospective study of children below 5 years of age (2012–2017) post fulguration and on oxybutynin for at least 6 months. Patient demographics, clinical features, renal ultrasound, micturating cystourethrogram, dimercaptosuccinic acid scan, adverse effects, and pill count for medication adherence were collated. **Results:** 48 children below the age of 5 years were included, and 12 were excluded either due to the presence of concomitant problems or were not on oxybutynin. Of the 36, four were lost to follow-up and one had died due to an unrelated condition. Thus, a total of 31 children were analyzed. At follow-up, 28/31 patients were asymptomatic, two had daytime incontinence, and one had recurrent urinary tract infection. All patients except one have preserved renal function tests. On ultrasonography, hydroureteronephrosis worsened in only 1/25 children and two showed significant post void residues. The resolution of vesicoureteral reflux was noted in almost 50%. 4/31 renal units had progressive scars. Only two parents defaulted medication. Urodynamic study done in half of these children showed stable bladder pressures except in two. **Conclusion:** Oxybutynin therapy following adequate valve fulguration aids upper tracts preservation by stabilizing deranged bladder dynamics. The medication is well tolerated with minimal or no side effects.

**Keywords:** Anticholinergics, bladder dynamics, medication adherence, oxybutynin, posterior urethral valve

## Introduction

Posterior urethral valves (PUV) is a congenital obstructive defect of the male urethra with an incidence of one in 25,000 live births.

**Address for correspondence:** Dr. Attibele Mahadevaiah Shubha,  
Department of Paediatric Surgery, St. John's Medical  
College Hospital, Bengaluru - 560 034, Karnataka, India.  
E-mail: dramshubha@yahoo.co.in

Received: 26-12-2020

Revised: 27-06-2021

Accepted: 09-07-2021

Published: 05-11-2021

It is one of the commonest surgical causes of chronic kidney disease in children requiring renal replacement therapy.<sup>[1]</sup> The embryological defect is thought to be either due to abnormal insertion of the Wolffian ducts into the urethra or merely due to a persistence of the cloacal membrane.<sup>[2]</sup> Ultrasonography as a screening modality demonstrates an enlarged/thick bladder wall with or without diverticula, dilated posterior urethra, and bilateral hydroureteronephrosis (HUN).

This is an open access journal, and articles are distributed under the terms of the Creative Commons Attribution-NonCommercial-ShareAlike 4.0 License, which allows others to remix, tweak, and build upon the work non-commercially, as long as appropriate credit is given and the new creations are licensed under the identical terms.

For reprints contact: WKHLRPMedknow\_reprints@wolterskluwer.com

**How to cite this article:** Norris JJ, Raj JP, Thomas TT, Maleperambal TT, Shubha AM. Effects of oxybutynin in children with posterior urethral valves post fulguration: Report in a select cohort of children. J Family Med Prim Care 2021;10:3706-11.

### Access this article online

#### Quick Response Code:



Website:  
www.jfmpc.com

DOI:  
10.4103/jfmpc.jfmpc\_2554\_20

Micturating cystourethrogram (MCU) shows a small bladder with sacculations/trabeculations, bladder neck hypertrophy, and dilated posterior urethra with or without vesicoureteral reflux (VUR) and remains the gold standard diagnostic investigation in PUV.<sup>[5]</sup> Treatment involves both surgical repair and pharmacotherapy. Early valve fulguration is proven to be superior to diversion procedures (vesicostomy/ureterostomy)<sup>[4]</sup> and is considered the optimal management modality following initial stabilization of deranged renal function, metabolic parameters, and coexisting urinary tract infection (UTI).<sup>[5]</sup> However, the long-term outcome in children with PUV often depends on the pharmacotherapeutic management of bladder dysfunction resulting from hypertonic, hyperreflexic, small capacity, noncompliant bladder.<sup>[6]</sup> Anticholinergic drugs are the preferred choice and oxybutynin is the first-line anticholinergic agent that is commonly used. It exerts an antispasmodic effect on the smooth muscles of the bladder by inhibiting the muscarinic action.<sup>[7]</sup> Tolterodine is a newer drug from this class but is currently approved only for use in adults.<sup>[8]</sup> Here, we report a single-center experience on the use of oxybutynin post fulguration in children with PUV less than 5 years of age: its beneficial effects on bladder and urinary tract morphology and function, the adverse effects encountered, and medication adherence.

## Methods

This was a retrospective observational study of children who underwent fulguration for PUV in our center between 2012 and 2017 at a tertiary care hospital in South India. All children who underwent fulguration from the neonatal period to 5 years of age and on oxybutynin, following up in the comprehensive nephrology urology clinic were included in the study. Children whose parents did not consent, those above 5 years of age at the time of the procedure, and those who were not on oxybutynin were excluded. As a departmental protocol, all children with PUV are started on oxybutynin, 6-month post fulguration at 0.2 mg/kg/day in two divided doses. Exceptions are those children with good bladder morphology as noted during cystoscopy and without complaints of lower urinary tract symptoms (irritative or obstructive like frequency, dribbling, and daytime and nighttime incontinence), those who did not tolerate oxybutynin, and those with significant persistent post void residues (PVR) on post fulguration follow-up ultrasound. The study was approved by the institutional ethics committee vide study no 167/2016 and was done following the guidelines of the Indian Council of Medical Research (2006) and Central Drug Standard Control Organization (CDSCO) Good Clinical Practice Guidelines (GCP) (2001) that have their origins in the Declaration of Helsinki.

A written informed consent was obtained from the parents of the study participants and a semistructured pilot-tested standardized questionnaire was administered to them in the language of their convenience. This questionnaire comprised of basic demographic details, brief antenatal and neonatal medical history, biochemical parameters, renal ultrasonogram, MCU,

and dimercaptosuccinic acid (DMSA) scan and urodynamic study (UDS) report. We assessed for medication adherence using memory recall over the last 30 days and data regarding the side effects of oxybutynin were collected by asking the parent as well as by going through their medical records.

Bladder wall morphology, the status of HUN, and PVR were compared using data from ultrasound scans. VUR and PVR were assessed using MCUs. The status of renal scarring was determined by DMSA scans. Bladder compliance and filling and voiding detrusor pressures were documented in whom urodynamics was done. Medication compliance was assessed using pill count over one month during the last month of the 6-month follow-up and those with <80% pill intake were considered as noncompliant.

Data entry was done in Excel and Epi Info™ Version 7. (Publisher: CDC, USA, 2011) and analysis was performed with an IBM SPSS Statistics for Windows, Version 20.0 (Publisher: IBM Corp., USA, 2011). Demographic characteristics, medication adherence, and changes noted from the various scans were summarized using descriptive statistics. Changes in biochemical parameters were assessed using the Wilcoxon signed-rank test before and after fulguration. Statistical significance was set at  $P < 0.05$ . Though we proposed to study the risk factors for poor medication adherence using multivariate analysis, the number of noncompliant children was very less making the analysis less meaningful.

## Results

There was a total of 48 children who underwent fulguration for PUV between 2012 and 2017. Of these, 12 children were excluded as they either had concomitant problems like anterior urethral stricture, chronic renal failure or were not on oxybutynin. Out of the total of 36 children, four children were lost to follow-up and one child had expired due to an unrelated condition. Thus, at the time of final follow-up and results computation, 31 children were available. The age at presentation ranged from day 1 to 5 years. The age at fulguration was between day 4 of birth and 48 months. The relevant clinical features are summarized in Table 1. The most common clinical presentation was poor urinary stream noted in 20/36 children (55.56%) followed by antenatal diagnosis in 18/36 children (50%). Besides undergoing transurethral fulguration (TUF), antecedent surgical procedures like vesicostomy, nephroureterectomy, and left loop ureterostomy and concomitant circumcision were performed as deemed appropriate by the surgical team, which are summarized in Table 1. Post fulguration on oxybutynin for 6 months or more, 28/31 patients (90%) were asymptomatic with a good urinary stream. Two children had daytime incontinence and one child had recurrent UTI which eventually settled.

The mean (SD) of pre and post intervention values of laboratory parameters are tabulated in Table 2. There is a significant fall in the mean creatinine ( $P = 0.007$ ) and improvement in bicarbonate ( $P = 0.003$ ) post intervention. Low plasma

**Table 1: Clinical characteristics of the study participants**

Clinical characteristics at baseline		Frequency (%); n=36
Clinical presentation	Antenatal diagnosis	18 (50.00)
	Poor urinary stream	20 (55.56)
	Urinary tract infection	15 (41.67)
	Acute renal failure	12 (33.33)
	Mass per abdomen	3 (8.33)*
Concomitant surgeries	Circumcision	8 (25.00)
	Vesicostomy	3 (8.33)
	Nephroureterectomy	4 (11.11)†
	Left loop ureterostomy	2 (5.56)

\*Palpable kidneys in two participants and urinoma in one participant. †left side in three participants and right side in one participant

**Table 2: Summary of laboratory findings pre and post intervention**

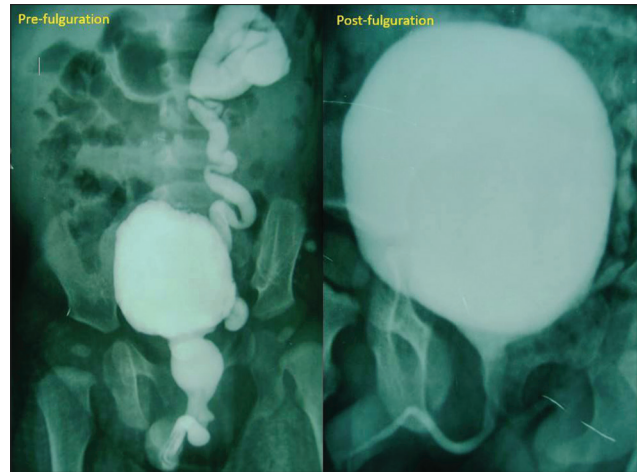
Parameter	Pre-intervention		Post-intervention		P†
	n	Mean (SD)	n	Mean (SD)	
Creatinine*	33	1.26 (1.35)	29	0.39 (0.19)	0.007
Bicarbonate*	32	18.80 (3.32)	21	20.64 (2.38)	0.003

\*n=28 patients had all the three parameters before and after intervention. †Based on Wilcoxon signed-rank test

bicarbonate levels were seen in 9/32 children at presentation. However, at the end of 6-month post intervention, 7/9 patients normalized, while 2/9 patients still required increased oral supplementation of bicarbonate, probably an indication of occult tubular dysfunction.

Renal ultrasound revealed bilateral HUN in 25/31 patients, and 3/31 had unilateral left-sided HUN at presentation. At 6 months, 20% (5/25) of those with bilateral HUN had complete resolution. All the 3 children who had only unilateral HUN at presentation also had complete resolution. In the remaining with bilateral HUN, unilateral resolution was seen in 6/25 (24%) children (where HUN persisted on the right side in 5/6 patients and on the left-sided in 1/6 patients). There was no change in 13/25 patients (52%) and 1 patient with bilateral HUN had deterioration.

Initial MCU revealed a total of 16 refluxing units. In follow-up, complete resolution was noted in 7/16 units (43.75%) and no change in 9/16 units (56.25%). Figure 1 highlights near-normal posterior urethra, improved bladder morphology, and resolution of reflux post fulguration at follow-up on oxybutynin. However, there were 2 new refluxing units where one patient with unilateral right Grade V VUR developed bilateral VUR and the other patient had new-onset VUR in the right solitary functioning kidney. These 2 patients also documented persistent significant PVR. This is probably a combination of the effect of oxybutynin combined with ineffective bladder emptying. In all, a total of 3/31 patients had significant PVR during follow-up, all of whom were started on clean intermittent catheterization (CIC). The above changes are not attributable to myogenic failure secondary to oxybutynin as these children were still voiding well with MCU showing moderate capacity bladder and resolution of reflux but with PVR [Figure 2] unlike a large bladder suggestive



**Figure 1:** MCU at prefulguration: dilated posterior urethra, small, irregular bladder, and left Gr V VUR. MCU at follow-up: normal posterior urethra, good capacity smooth bladder, and left transient Gr I VUR

of myogenic failure. Two children have undergone UDS, which shows normal pressure bladders, and one with new-onset reflux was awaiting UDS at follow-up. All these children have been compliant with CIC.

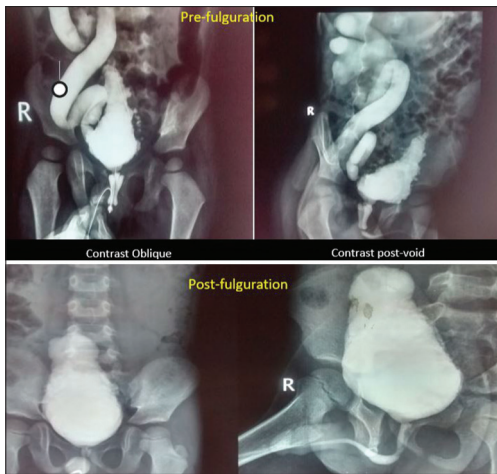
DMSA showed no progression of scars in 27/31 patients, while 4/31 had progression. Among those who progressed, 1 patient had poor medication adherence, while 2 others had completely stopped oxybutynin. However, post intervention all patients had preserved differential renal functions. Urodynamics done in 14 of these children, 11 documented near-normal bladder pressure [Figure 3], whereas two children had detrusor pressure (Pdet) >40 cms of H<sub>2</sub>O during filling.

The number of patients who were compliant with medications was 29/31 (94%). The 2 patients who were not compliant were counseled and restarted on oxybutynin. The common adverse effects reported were transient constipation and feeling feverish, both of which were well accepted by parents and children.

## Discussion

We conducted a retrospective observational study and report the course of disease in children diagnosed with PUV and on oxybutynin for at least 6-month post-TUF. Antenatal diagnosis was made in at least half our study population. This is in accordance with the reports published in other studies. Ezel *et al.*<sup>[9]</sup> reported a single-center experience of 22 years with 64 children where the median age of diagnosis of PUV was one month (range 1–132 months) and 51.5% were diagnosed antenatally. Another retrospective study over a 29-year period reported that 42.5% (n = 77/181) of the total 181 South African boys with PUV were diagnosed in their first month of life.<sup>[10]</sup> However, a recent report from India shows that 76% (n = 78/102) have been detected antenatally, which is higher than what we have reported.<sup>[11]</sup> This is probably due to the changing antenatal care policies in our country where

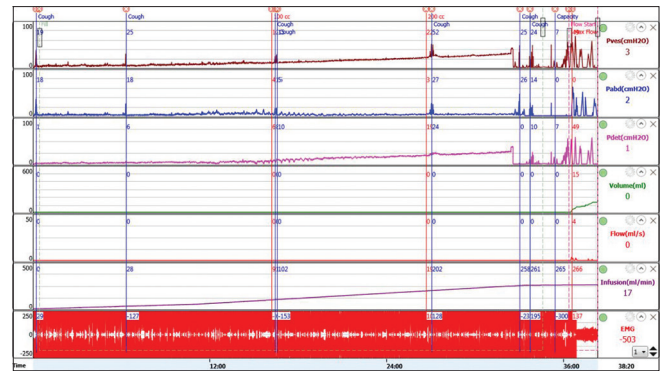




**Figure 2:** MCU at prefulguration: dilated posterior urethra, small irregular bladder, right Gr V VUR. MCU at follow-up: normal posterior urethra, moderate capacity bladder, and resolved VUR with significant post void residue

the government is incentivizing pregnant mothers to seek professional antenatal care at designated hospitals and primary health care centers.<sup>[12]</sup> The most common presenting complaints in our study were poor urinary stream (55.56%) and recurrent UTI (41.67%). A registry-based study from new south wales analyzing 57 children reported that half of them presented with UTI.<sup>[13]</sup> Petersen *et al.*<sup>[10]</sup> reported that  $n = 109/181$  (60.2%) patients presented with UTI and  $n = 78/181$  (43.1%) children with poor urinary stream.<sup>[10]</sup>

Almost 90% of our children were asymptomatic in terms of lower urinary tract symptoms and reported to have a good urinary stream. Anticholinergic agents have commonly been used for long-term management of children who have reduced bladder compliance and the resulting overactivity during bladder filling.<sup>[14]</sup> Invitro studies have shown oxybutynin to inhibit stretch-induced bladder smooth muscle proliferation thereby retaining normal intravesical pressure and less collagen infiltration in the detrusor both of which demonstrate the protective effect of oxybutynin on the structure and function of the bladder.<sup>[15]</sup> This property makes it a drug of choice in treating abnormal bladders in children with posterior urethral valves. However, the main concern in using anticholinergic therapy is a reversible iatrogenic myogenic failure resulting in the overdistended bladder, worsening reflux, and incontinence.<sup>[16]</sup> We report three patients in whom PVR was significant and two of them had worsening reflux during the follow-up period. In a study by Casey *et al.*,<sup>[17]</sup> four out of 18 children on oxybutynin after TUF had increasing bladder capacity. In the study by Kim *et al.*,<sup>[18]</sup> two out of 21 children experienced myogenic failure. The mainstay of treatment for myogenic failure is to stop the anticholinergic therapy<sup>[16]</sup> and start on clean intermittent catheterization to facilitate bladder emptying.<sup>[19]</sup> Thus, addressing urethral obstruction and appropriate use of anticholinergic drugs documented visible preservation of structure and function of the urinary bladder and the entire renal system. There was a significant improvement in the functioning of the kidneys as reflected by stable blood



**Figure 3:** UDS on oxybutynin. Good capacity, compliant bladder with normal detrusor pressure (Pdet)

urea and serum creatinine levels and maintenance of tubular functions by adequate bicarbonate supplements. The combined use of oxybutynin and PUV fulguration has resulted in resolution of the HUN in renal ultrasound scans and the resolution of VUR in MCU, thereby reflecting an improvement in bladder function. On a similar note, preservation of cortical function and nonprogression of scars on DMSA add to the beneficial effects of the treatment on bladder dynamics.

Anticholinergics are usually associated with a plethora of side effects; some of the common ones include dry mouth, dry eyes, constipation, and urinary retention.<sup>[20]</sup> Dryness of mouth is usually the most common side effect encountered.<sup>[21]</sup> However, we did not come across this adverse effect probably because our patients being young could not comprehend regarding dryness of mouth and also the use of extended-release medications is known to have a lesser incidence of dry mouth.<sup>[22,23]</sup>

Currently, with the governments' initiative to promote institutionalized perinatal care, the role of primary care physicians in the early recognition of PUVs would go a long way in facilitating early referral, initiating prompt treatment and thus better long-term outcomes. The 2011 Indian Census revealed that 68.84% of our growing population lives in rural areas and a sizeable number of tertiary care medical visits are made by such rural inhabitants, especially with regard to targeted pediatric, surgical, and obstetric care.<sup>[24]</sup> Thus, post-TUF follow-up visits if entrusted with a primary care physician to monitor medication adherence for better treatment outcomes would, to an extent, prevent financial burden on the rural families. This study sheds light on the benefits of the use of oxybutynin in children with PUV and reiterates its good safety profile, thereby making it a good candidate for follow-up at the primary care level.

Our study has a few limitations. The data collated was retrospective. It was also not possible to have a control group as management of PUV with oxybutynin and fulguration have become the standard of care. Factors predicting poor medication adherence was one of our objectives and this could not be assessed as the sample size was small with just two patients

fulfilling the criteria for poor medication adherence. The accuracy of valve fulguration is also judged by improvement in symptoms and investigations in follow-up and, therefore, it is difficult to objectively quantify the outcomes of adequate valve fulguration and use of oxybutynin individually. The above said effects have not been supplemented with UDS<sup>[25]</sup> in all included children because they undergo UDS only by 4.5–5 years of age as per the departmental protocol. The future follow-up of these children shall, of course, include the urodynamic correlation and alteration of management accordingly.

## Conclusion

The study highlights the effects of oxybutynin in children with posterior urethral valves post TUF. Adequate valve fulguration and oxybutynin therapy in children with PUV evidently improve the function and dynamics of valve bladder thereby preventing structural damage to the upper tracts. The adverse effects encountered are minimal and easily manageable when sought early. Compliance and adherence to medication are satisfactory with very few side effects. Myogenic failure is a legitimate concern and we recommend close monitoring of bladder capacity, PVR, and HUN correlated with urodynamic changes after initiating anticholinergic therapy.

## Recommendations

Oxybutynin therapy post adequate valve fulguration in children with PUV is recommended to improve the function of urinary bladder and prevent structural damage to the upper urinary tracts along with close monitoring for myogenic failure.

## Ethics approval

This study was approved by the Institutional Ethics Committee of St. John's Medical College and Hospital, Bengaluru, India. Reg. No. IEC No 167/2016.

## Financial support and sponsorship

We would like to acknowledge the Research Society of St. Johns Medical College, Bengaluru for funding the study.

## Conflicts of interest

There are no conflicts of interest.

## References

1. Kumar S, Fisk NM. Distal urinary obstruction. *Clin Perinatol* 2003;30:507-19.
2. Levin TL, Han B, Little BP. Congenital anomalies of the male urethra. *Pediatr Radiol* 2007;37:851-62; quiz 945.
3. Berrocal T, Rivas S, Jaureguizar E, Gómez-León N, Lobato R, Martínez-Urrutia MJ, *et al.* Contrast-enhanced sonourethrography versus conventional micturition cystourethrography in the assessment of the urethra: Preliminary study. *Cir Pediatr* 2004;17:58-60.
4. Chatterjee US, Basu AK, Mitra D. Insight into posterior urethral valve from our experience: Paradigm appended to abate renal failure. *J Indian Assoc Pediatr Surg* 2020;25:297-305.
5. Glassberg KI. The valve bladder syndrome: 20 years later. *J Urol* 2001;166:1406-14.
6. Gupta DK, Bajpai M, Charles AR, Srinivas M, Dave S, Lal A, *et al.* Advantages of fulguration of posterior urethral valves by Nd: YAG laser. *Indian J Urol* 2000;17:37-40.
7. McCrery RJ, Appell RA. Oxybutynin: An overview of the available formulations. *Ther Clin Risk Manag* 2006;2:19-24.
8. Detrol® (FDA Approved Patient Label). New York: Pfizer Inc.; 2016. <https://www.pfizermedicalinformation.com/en-us/detrol/fda-label>. [Last accessed on 2019 Mar 6].
9. Ezel Çelaklı M, Ekinçi Z, Bozkaya Yücel B, Mutlu N, Günlemez A, Bek K. Outcome of posterior urethral valve in 64 children. Single center experience of 22 years. *Minerva Urol Nefrol* 2019;71:651-6.
10. Petersen KL, Moore DP, Kala UK. Posterior urethral valves in South African boys: Outcomes and challenges. *S Afr Med J* 2018;108:667-70.
11. Sarma VP. The posterior urethral valves revisited: Embryological correlation, clinical classification, and risk stratification of the spectrum. *Ann Pediatr Surg* 2021;16:36.
12. Srinivasan R, Ganesan SK, Premkumar PS, Kang G. Influence of publicly funded conditional cash transfer programmes on utilization patterns of healthcare services for acute childhood illness. *Int Health* 2020;12:339-43.
13. Thakkar D, Deshpande AV, Kennedy SE. Epidemiology and demography of recently diagnosed cases of posterior urethral valves. *Pediatr Res* 2014;76:560-3.
14. Alhasso AA, McKinlay J, Patrick K, Stewart L. Anticholinergic drugs versus non-drug active therapies for overactive bladder syndrome in adults. *Cochrane Database Syst Rev* 2006;4:CD003193.
15. Scheepe JR, de Jong BW, Wolffenbuttel KP, Arentshorst ME, Lodder P, Kok DJ. Effect of oxybutynin on structural changes of the obstructed guinea pig bladder. *J Urol* 2007;178:1807-12.
16. Misseri R, Combs AJ, Horowitz M, Donohoe JM, Glassberg KI. Myogenic failure in posterior urethral valve disease: Real or imagined? *J Urol* 2002;168:1844-8; discussion 1848.
17. Casey JT, Hagerty JA, Maizels M, Chaviano AH, Yerkes E, Lindgren BW, *et al.* Early administration of oxybutynin improves bladder function and clinical outcomes in newborns with posterior urethral valves. *J Urol* 2012;188 (4 Suppl):1516-20.
18. Kim YH, Horowitz M, Combs AJ, Nitti VW, Borer J, Glassberg KI. Management of posterior urethral valves on the basis of urodynamic findings. *J Urol* 1997;158:1011-6.
19. Sharma S, Joshi M, Gupta DK, Abraham M, Mathur P, Mahajan JK, *et al.* Consensus on the management of posterior urethral valves from antenatal period to puberty. *J Indian Assoc Pediatr Surg* 2019;24:4-14.
20. Lieberman JA. Managing anticholinergic side effects. *Prim Care Companion J Clin Psychiatry* 2004;6(Suppl 2):20-3.
21. Thomas J. Etiopathogenesis and management of bladder dysfunction in patients with posterior urethral valves. *Indian J Urol* 2010;26:480-9.
22. Versi E, Appell R, Mobley D, Patton W, Saltzstein D. Dry mouth with conventional and controlled-release oxybutynin in urinary incontinence. The Ditropan XL study group.

- Obstet Gynecol 2000;95:718-21.
23. Briatico G, Pampena R, Fulgione E, Babino G, Giorgio CM, D'Ambra I, *et al.* Real-life experience with oral oxybutynin long-term continuous therapy in severe hyperhidrosis and systematic review of the literature. *Dermatol Ther* 2021;34:e14832.
  24. Kumar P, Kumar R. Rural health scenario - Role of family medicine: Academy of family physicians of India position paper. *J Fam Med Prim Care* 2018;7:1157-62.
  25. Guha Vaze P, Saha S, Sinha R, Banerjee S. Urodynamics in posterior urethral valve: Pursuit of prognostication or optimisation. *J Pediatr Urol* 2021;17:111.e1-8.