

Presumed Necrotizing Viral Retinitis after Intravitreal Triamcinolone Injection: Case Report

Jeong Mo Han¹, Jeeyun Ahn², Kyu Hyung Park², Se Joon Woo²

¹Department of Ophthalmology, Seoul National University Hospital, Seoul National University College of Medicine, Seoul, Korea

²Department of Ophthalmology, Seoul National University Bundang Hospital, Seoul National University College of Medicine, Seongnam, Korea

A 56-year-old man presented with anterior chamber inflammation, increased intraocular pressure, peripheral retinal infiltration, and generalized retinal arterial obstruction suggesting acute retinal necrosis five months after intravitreal triamcinolone acetonide injection (IVTA). He was treated with intravenous antiviral agents and aspirin. Shortly after treatment, retinal infiltrations were resolved, and partial recanalization of the obstructed vessel was observed. Viral retinitis may occur as an opportunistic infection following IVTA due to the local immune modulatory effect of the steroid; hence, close observation following IVTA is necessary.

Key Words: Acute retinal necrosis, Herpetic retinitis, Intravitreal injections, Intravitreal triamcinolone acetonide injection

Intravitreal injections of corticosteroid are recommended for a broad spectrum of ophthalmologic conditions. A beneficial role of intravitreal steroid injections has been reported for diabetic macular edema, exudative age-related macular degeneration, macular edema secondary to retinal vein occlusion, chronic uveitis, and pseudophakic cystoids macular edema [1,2].

Intravitreal steroid injections have potential complications, such as cataract development, increased intraocular pressure (IOP), retinal hemorrhage, retinal detachment, and endophthalmitis [3]. Although steroids reduce local inflammation and retinal edema, they simultaneously decrease local defenses against pathologic agents [3-10]. Viral retinitis following intravitreal triamcinolone acetonide injections (IVTAs) in immunocompetent patients has been reported [3-10], suggesting an association between intravitreal steroids and opportunistic infections. However, the association among intravitreal injection of corticosteroid, viral retinitis, and the pathogenesis of viral retinitis has not been determined. In this report, we present a case of viral retinitis following IVTA in an immunocompetent patient and review the relevant literature.

Received: August 13, 2010 Accepted: December 1, 2010

Corresponding Author: Se Joon Woo, MD. Department of Ophthalmology, Seoul National University Bundang Hospital, #300 Gumi-dong, Bundang-gu, Seongnam 463-707, Korea. Tel: 82-31-787-7377, Fax: 82-31-787-4057, E-mail: sejoon1@hanmail.net

© 2011 The Korean Ophthalmological Society

This is an Open Access article distributed under the terms of the Creative Commons Attribution Non-Commercial License (<http://creativecommons.org/licenses/by-nc/3.0/>) which permits unrestricted non-commercial use, distribution, and reproduction in any medium, provided the original work is properly cited.

Case Report

A 56-year-old man presented to our uveitis clinic for evaluation of a visual disturbance in his right eye. He had been diagnosed with diabetes four years previously and was controlling blood glucose with oral medications. His visual acuity was 20 / 40 in the right eye (OD) and 20 / 30 in the left eye. Fundus examination showed moderate non-proliferative diabetic retinopathy in both eyes and macular edema OD (Fig. 1). The foveal thickness was 465 μ m OD as observed by optical coherence tomography (OCT; Stratus OCT, Carl Zeiss Meditec, Dublin, CA, USA). We administered IVTA (4 mg) for treatment of the diabetic macular edema using an aseptic technique including irrigation of the conjunctival sac with diluted betadine solution and prescribed oral and topical antibiotics for one week after injection. After IVTA, the visual acuity improved to 20 / 32 OD and the macular edema decreased to 357 μ m OD on OCT.

Five months after the IVTA, the patient returned to our clinic for right eye visual deterioration. The visual acuity was 20 / 200 OD and the intraocular pressure was 23 mmHg according to Goldmann applanation tonometer (GAT) measurement. Slit lamp examination of the right eye revealed fine keratic precipitates on the corneal endothelium and moderate (grade +2 inflammatory cells) inflammation in the anterior chamber. Fundus examination showed severe generalized arterial obstruction, vitreous opacity, and a white necrotic retina in the inferotemporal periphery (Figs. 1B and 2A, black arrows).

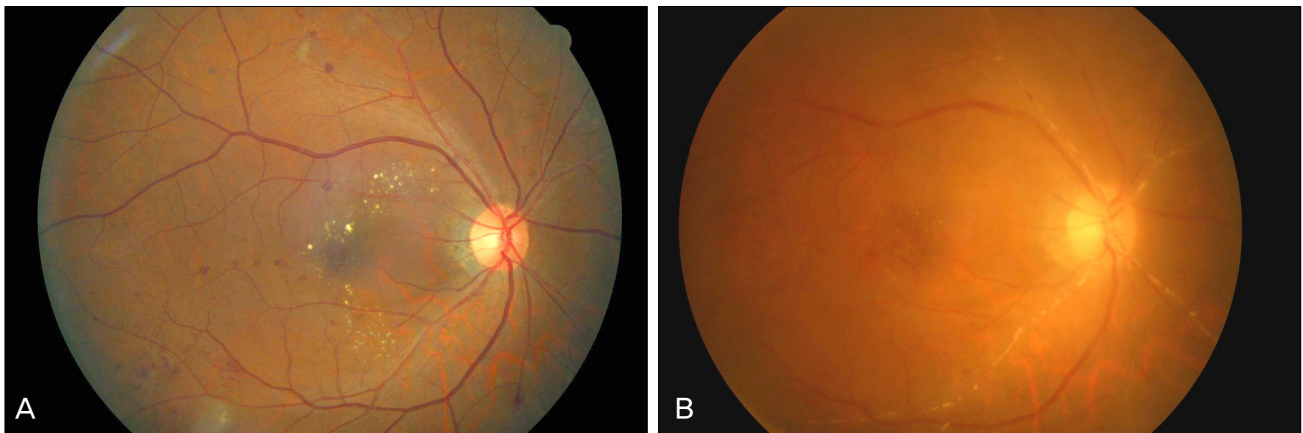


Fig. 1. Fundus photography of the right eye. (A) Before intravitreal injection of triamcinolone acetonide (IVTA), only mild diabetic changes can be seen. (B) Five months after IVTA, anterior chamber inflammation, severe arterial obstruction, and vitreous opacity developed.

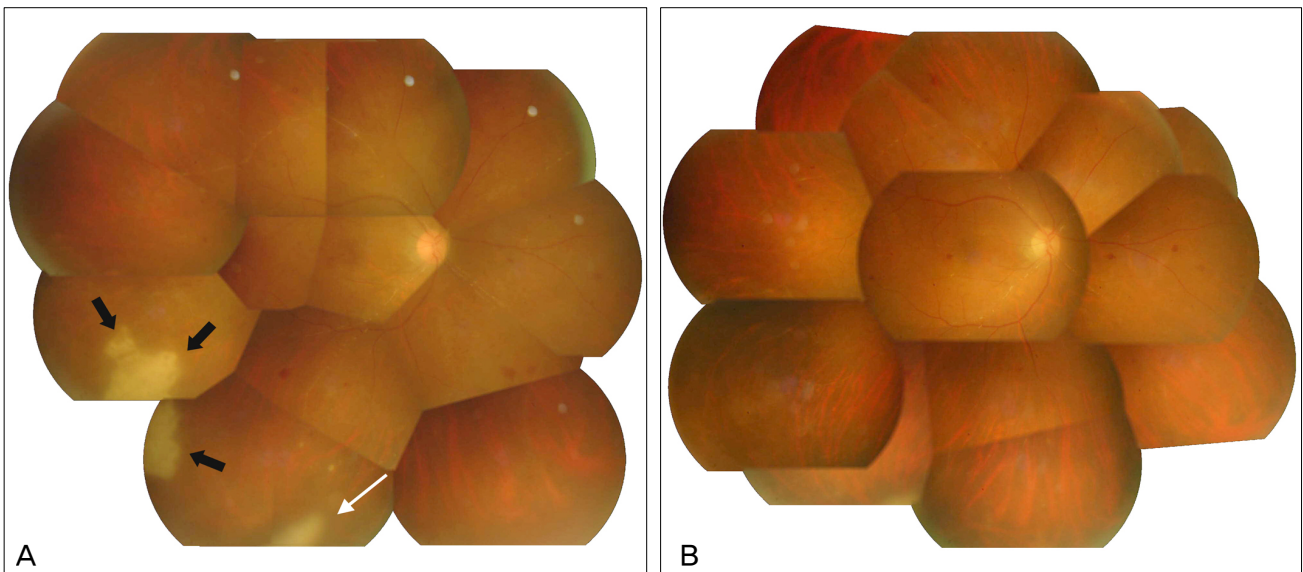


Fig. 2. Montage fundus photography. (A) Five months after intravitreal triamcinolone acetonide injection, anterior chamber inflammation, severe arterial obstruction, and vitreous opacity developed. A white necrotic retinal area (black arrows) and vitreous opacity developed. Intravitreal triamcinolone is still visible in the inferior vitreous (white arrow). (B) After anti-viral treatment, the necrotic retinal area and vitreous opacity were gradually resolved. One month after antiviral medication, the white retinal necrotic area eventually disappeared.

Remnant triamcinolone particles were still visible in the inferior vitreous. (Fig. 2A, white arrow) After presumed diagnosis of viral retinitis, in particular acute retinal necrosis, laboratory work-up, including anterior chamber paracentesis for viral polymerase chain reaction (PCR), was performed. However, no viral DNA was detected by PCR, including herpes simplex virus (HSV), varicella zoster virus (VZV), cytomegalovirus (CMV), or Epstein-Barr virus. Blood tests for human immunodeficiency virus and syphilis were negative, and the CD4 cell count was within normal limits. Intravenous acyclovir was administered for ten days, and oral valaciclovir was given for the following three weeks. Along with antiviral medications, oral aspirin and oral/topical steroids were prescribed. One week after initiation of antiviral medications, the size of the white retinal necrotic area decreased

and eventually disappeared at one month (Fig. 2B). Barrier laser was performed around the necrotic retina for prevention of retinal breaks and detachment. After three months, blood samples for viral serology testing were collected. Anti-HSV, anti-CMV, and anti-VZV IgG were detected, but the IgM titers were negative. During routine six month follow-up visits, the visual acuity was limited to 20 / 100 OD due to cataract and epiretinal membrane (ERM). One year after the IVTA, vitrectomy for ERM removal combined with cataract operation was performed, and the visual acuity was restored to 20 / 40 OD.

Discussion

Our case is presumed to be a form of acute retinal necrosis

Table 1. Published cases of viral retinitis after intravitreal corticosteroid implantation

Authors	Age	Sex	Indication for IVTA	Systemic diseases	Triamcinolone acetamide		Diagnosis	Cause	Diagnosis confirmation	Interval to retinitis	Immunocompromised state	AC	Peak IOP	VA before IVTA	Visual acuity		Vitrectomy for treatment	Antiviral medication
					No. of injections	Dose (mg)									VA after retinitis	Final VA		
Saidel et al. [4]	75	M	CSME from DR	NIDDM	1	4	CMV retinitis	CMV	Vitreous PCR	4 mon	Immunocompetent	Trace	N/A	20/40	20/80	20/400	Yes	Oral
Toh et al. [5]	62	F	Exudative AMD (with PDT)	None	1	4	ARN	HSV	Serum IgG and IgM	5 mon	Immunocompetent	1+	40	6/18	NA	6/36*	No	IV, oral
Aggermann et al. [6]	69	M	CME from CRVO	None	1	4	Necrotizing herpetic retinal necrosis	HSV	Serum IgG	3 wk	Immunocompetent	4+	27	1/200	NLP	NLP	Yes	Systemic†
Delyfer et al. [7]	77	M	Exudative AMD (with PDT)	NIDDM	1	20	CMV retinitis	CMV	AC PCR	3 mon	Immunocompetent	N/A	26	N/A	CF	20/200	No‡	Intravitreal, IV, oral
Delyfer et al. [7]	69	M	CME from CRVO	NIDDM	3	8	CMV retinitis	CMV	AC PCR	3 mon	Immunocompetent	2+	23	N/A	20/200	20/400	No‡	IV, oral
Ufret-Vincenty et al. [11]	65	M	CME/vitreitis	Behcet disease		Retisert × 2	CMV retinitis	CMV	Clinical	5 mon after Retisert no. 2	Immunocompetent	N/A	N/A	20/40	20/50	20/40	No	Intravitreal injection, implant
Sekiryu et al. [8]	63	M	CME from BRVO	NIDDM	1	4	CMV retinitis	CMV	AC PCR	7 mon	Immunocompetent	(+) [§]	48	20/40	20/200	20/32	No	IV, oral
Park et al. [9]	77	F	CME from CRVO	None	1	4	CMV retinitis	CMV	AC PCR	4 mon	Immunocompetent	Many	N/A	N/A	LP	HM	No	Intravitreal
Tugal-Tutkum et al. [10]	30	M	Panuveitis	Behcet disease	1	N/A	CMV retinitis	CMV	Vitreous and serum PCR	14 wk	Immunocompetent	4+	N/A	20/200	20/200	20/63 ^{¶¶}	Yes	Intravitreal, IV
Shah et al. [3]	62	N/A	CME from BRVO	NIDDM	2	20	CMV retinitis	CMV	Vitreous PCR	26 wk	Immunocompetent	3+	N/A	20/200	20/400	N/A	Yes	Oral
Shah et al. [3]	43	N/A	CME from IRU	AIDS	1	20	CMV retinitis	CMV	Prior CMV retinitis, clinical appearance	13 wk	Immunocompromised	N/A	N/A	20/40	20/40	N/A	No	
Han et al. (present case)	56	M	CSME from DR	NIDDM	1	4	ARN	VZV or HSV	Serum IgG, response to treatment	5 mon	Immunocompetent	2+	23	20/40	20/200	20/40	No [#]	IV, oral

IVTA = intravitreal triamcinolone injection; AC = anterior chamber; IOP = intraocular pressure; VA = visual acuity; CSME = clinically significant macular edema; DR = diabetic retinopathy; NIDDM = non-insulin dependent diabetes mellitus; CMV = cytomegalovirus; PDT = photodynamic therapy; ARN = acute retinal necrosis; HSV = herpes simplex virus; N/A = not available; AMD = age-related macular degeneration; BRVO = branch retinal vein occlusion; CME = cystoid macular edema; CRVO = central retinal vein occlusion; ERM = epiretinal membrane; HIV = human immunodeficiency virus; IRF = intraretinal fluid; IRU = immune recovery uveitis; IV = intravenous; PCR = polymerase chain reaction; VZV = varicella zoster virus. *Visual acuity was limited to 6 / 36 due to cataract formation. †Oral or IV antiviral treatment were administered. Exact route of drug administration was not mentioned. ‡Vitrectomy was performed before viral retinitis was developed. §Anterior chamber inflammation was mentioned but the grade of inflammation was not available. ¶After cataract surgery, visual acuity was improved to 20 / 63. #After cataract surgery and vitrectomy for epiretinal membrane removal, visual acuity was improved to 20 / 40.

(ARN) considering the prompt response to antiviral treatment, serum viral IgG results, and typical clinical presentations, although we failed to reveal the causative organism by PCR or serology. The causative association between IVTA and ARN was presumed by the visualization of triamcinolone particles at the time of ARN occurrence and no underlying systemic immune deficiency.

Other possible diagnoses include CMV retinitis and intraocular lymphoma. In CMV retinitis, early lesions are located along the retinal blood vessels and sometimes on the fovea or disc. Intraocular lymphoma/leukemia could also produce whitish infiltrative subretinal lesions. However, in our case, ARN is the more likely diagnosis because a yellow-white retinal lesion was initially noticed in the peripheral retina, and occlusive vasculopathy involving all retinal arteries was observed with anterior chamber reactions, which are the pathognomonic findings of ARN. Follow-up examination showed no evidence of lymphoma or leukemia.

To date, there are 12 case reports of necrotizing herpetic retinopathy, including nine of CMV retinitis and three of ARN in ten immunocompetent patients, of whom two immunocompromised patients received intravitreal corticosteroid injections (Table 1) [3-11]. The mean age of patients with necrotizing herpetic retinopathy associated with intravitreal corticosteroid injection ranged from 30 to 77 years (range, 63.75 ± 14.13 years). PCR was performed for diagnosis of pathogens in all cases except one [6], which had a lack of vitreous due to previous vitrectomy. The diagnosis was confirmed in seven cases (63.6%) by detection of viral DNA. The IOP of the infected eye according to the available IOP data in case reports was 23 to 48 mmHg (mean, 32.8 ± 10.7 mmHg). Elevated IOP is a common clinical feature of necrotizing herpetic retinopathy associated with intravitreal corticosteroid injection. All case reports mentioned inflammatory cells in the anterior chamber. The interval between intravitreal corticosteroid injection and retinitis ranged from three weeks to seven months (range, 4.0 ± 1.7 months).

Local immune deficiency by intravitreal steroid injections has been suggested as the most likely pathogenesis for necrotizing herpetic retinopathy [3-10]. A history of viral retinitis, such as CMV retinitis, was not clear except in only one case of CMV retinitis. However, reactivation of a virus from prior subclinical infections may play an important role in viral retinitis after IVTA, as well as in new viral infections.

Bacterial endophthalmitis, one of the most serious complications of an IVTA, presents 7.5 days after injection [12], which is earlier than that of necrotizing herpetic retinopathy (four months on average). Bacterial endophthalmitis usually develops through the inoculation of bacteria into the sterile vitreous, whereas necrotizing herpetic retinopathy can develop by reactivation or by new inoculations. Beer et al. [13] reported that triamcinolone was detected in the aqueous humor more than three months after IVTA. Moreover, triamcinolone can remain in the vitreous longer than in the aqueous humor

[14]. The persistent immunocompromised state of the posterior segment after IVTA appears to mimic the intraocular state of the immunocompromised patient and may be the main mechanism of viral retinitis, either by reactivation or by a new infection of a virus.

In conclusion, we report a case of presumed ARN after IVTA and propose that physicians should be aware of the possibility of necrotizing herpetic retinopathy after IVTA. Heightened suspicion and prompt treatment using antiviral agents could act to preserve visual acuity.

Conflict of Interest

No potential conflict of interest relevant to this article was reported.

References

1. Kramar M, Vu L, Whitson JT, He YG. The effect of intravitreal triamcinolone on intraocular pressure. *Curr Med Res Opin* 2007;23:1253-8.
2. Yilmaz T, Weaver CD, Gallagher MJ, et al. Intravitreal triamcinolone acetonide injection for treatment of refractory diabetic macular edema: a systematic review. *Ophthalmology* 2009;116:902-11.
3. Shah AM, Oster SF, Freeman WR. Viral retinitis after intravitreal triamcinolone injection in patients with predisposing medical comorbidities. *Am J Ophthalmol* 2010;149:433-40.e1.
4. Saidel MA, Berreen J, Margolis TP. Cytomegalovirus retinitis after intravitreal triamcinolone in an immunocompetent patient. *Am J Ophthalmol* 2005;140:1141-3.
5. Toh T, Borthwick JH. Acute retinal necrosis post intravitreal injection of triamcinolone acetonide. *Clin Experiment Ophthalmol* 2006;34:380-2.
6. Aggermann T, Stolba U, Brunner S, Binder S. Endophthalmitis with retinal necrosis following intravitreal triamcinolone acetonide injection. *Ophthalmologica* 2006;220:131-3.
7. Delyfer MN, Rougier MB, Hubschman JP, et al. Cytomegalovirus retinitis following intravitreal injection of triamcinolone: report of two cases. *Acta Ophthalmol Scand* 2007;85:681-3.
8. Sekiryu T, Iida T, Kaneko H, Saito M. Cytomegalovirus retinitis after intravitreal triamcinolone acetonide in an immunocompetent patient. *Jpn J Ophthalmol* 2008;52:414-6.
9. Park YS, Byeon SH. Cytomegalovirus retinitis after intravitreal triamcinolone injection in a patient with central retinal vein occlusion. *Korean J Ophthalmol* 2008;22:143-4.
10. Tugal-Tutkun I, Araz B, Cagatay A. CMV retinitis after intravitreal triamcinolone acetonide injection in a patient with Behcet's uveitis. *Int Ophthalmol* 2010;30:591-3.
11. Ufret-Vincenty RL, Singh RP, Lowder CY, Kaiser PK. Cytomegalovirus retinitis after fluocinolone acetonide (Retisert) implant. *Am J Ophthalmol* 2007;143:334-5.
12. Moshfeghi DM, Kaiser PK, Scott IU, et al. Acute endophthalmitis following intravitreal triamcinolone acetonide injection. *Am J Ophthalmol* 2003;136:791-6.
13. Beer PM, Bakri SJ, Singh RJ, et al. Intraocular concentration and pharmacokinetics of triamcinolone acetonide after a single intravitreal injection. *Ophthalmology* 2003;110:681-6.
14. Cheng L, Banker AS, Martin M, et al. Triamcinolone acetonide concentration of aqueous humor after decanted 20-mg intravitreal injection. *Ophthalmology* 2009;116:1356-9.