

Rare ocular manifestations in keratosis follicularis (Darier–White disease)

Savitha H Kanakpur, Divya Upendra Caculo

Keratosis follicularis (Darier's disease) is a rare (1 in 30,000–100,000) genetic autosomal-dominant predominantly dermatological disorder characterized by hyperkeratosis and acantholysis due to a defective calcium transport in the cells. Ocular findings, if present, are very rare in this condition. Here, we are reporting a case of keratosis follicularis (Darier's disease) with ocular manifestations that have not been reported so far to the best of our knowledge.

Key words: Darier–White disease, cataract, ecchymosis, subconjunctival hemorrhage

Keratosis follicularis, also known as Darier–White disease, dyskeratosis follicularis syndrome, and psorospermosis,^[1] is a rare genetic autosomal-dominant condition with intrafamilial and interfamilial variability in severity with 100% penetrance in late teenage life. It has been mapped to 12q23-24 "keratin cluster."^[2] It was initially described by Prince Marrow in 1886 and by Darier and White in 1889. The worldwide prevalence is reported to range between

1/30,000–100,000.^[3] Major manifestations include the presence of greasy, hyperkeratotic papules on middle chest, upper shoulders, neck, and face. Apart from skin lesions, 90% of patients have nail changes. Fragile nail plate with longitudinal white and red striations in the nails is pathognomonic. Ocular manifestations of Darier's disease reported are punctate corneal epithelial defects, opacities in periphery of cornea,^[2,4] corneal subepithelial infiltrations, corneal ulcerations, and conjunctival keratosis.^[1] Here, we present a patient with Darier's disease having unusual ocular findings, which has not been reported so far.

Case Report

A 20-year-old female presented to our outpatient department with diminution of vision in the right eye for the past 3–4 months. There was no history of trauma, no history of redness, watering, photophobia, or discharge from the eye. The patient had multiple hyperkeratotic lesions on her face, back, trunk [Fig. 1], and nails had also been affected since birth [Fig. 2]. A family history of similar condition was present in her father.

Detailed ocular examination was done which included visual acuity examination.

- Right eye visual acuity was perception of light with projection of rays accurate
- Left eye visual acuity was 6/6
- Slit-lamp examination of the right eye revealed the presence of fine, pigmented old keratic precipitates on the lower part of the endothelium [Fig. 3], total cortical cataract
- The corneal sensations of the right eye were found to be diminished
- Left eye anterior segment was normal

This is an open access article distributed under the terms of the Creative Commons Attribution-NonCommercial-ShareAlike 3.0 License, which allows others to remix, tweak, and build upon the work non-commercially, as long as the author is credited and the new creations are licensed under the identical terms.

For reprints contact: reprints@medknow.com

Cite this article as: Kanakpur SH, Caculo DU. Rare ocular manifestations in keratosis follicularis (Darier–White disease). Indian J Ophthalmol 2017;65:874-6.

Access this article online	
Quick Response Code:	Website: www.ijjo.in
	DOI: 10.4103/ijjo.IJO_852_16

Department of Ophthalmology, Karnataka Institute of Medical Sciences, Hubli, Karnataka, India

Correspondence to: Dr. Divya Upendra Caculo, Mahalakshmi Building, Dr. Dada Vaidya Road, Panaji-Goa - 403 001, India. E-mail: divyacaculo@gmail.com

Manuscript received: 08.11.16; **Revision accepted:** 01.08.17

- Fundus examination, A-scan, and B-scan of the right eye and left eye were within normal limits
- Intraocular pressure of right eye was 12 mmHg and the left eye was 10 mmHg
- On dermatological evaluation and histopathologic confirmation, a diagnosis of Darier–White disease was made
- Routine blood investigations also showed as normal.

Patient was prepped for cataract surgery with posterior chamber intraocular lens under local anesthesia under guarded visual prognosis. Medical fitness was obtained, and test doses for injection lignocaine 2% with adrenaline 1:100,000 and injection bupivacaine 0.5% were given. Topical proparacaine was instilled into the dilated eye 15 min before surgery and patient was prepared for block. Ten percent povidone-iodine solution was used to scrub the eyelids before the block, and within 15 s of scrubbing, the patient developed tense lid edema and chemosis of the right eye. No block was administered. An injection of hydrocortisone was given and few minutes later the swelling subsided. The next day, the patient developed ecchymosis and subconjunctival hemorrhage. Surgery was deferred till the subsidence of edema and subconjunctival hemorrhage [Fig. 4].

Patient was taken 3 weeks later and the same 10% povidone-iodine solution was used to paint other areas with lesion to rule out hypersensitivity reaction. No change was observed. Before surgery, the eyelids were gently cleaned with 10% povidone-iodine and not thoroughly scrubbed as had been done previously. Phacoemulsification with clear corneal incision with foldable posterior chamber intraocular lens was performed under topical anesthesia.

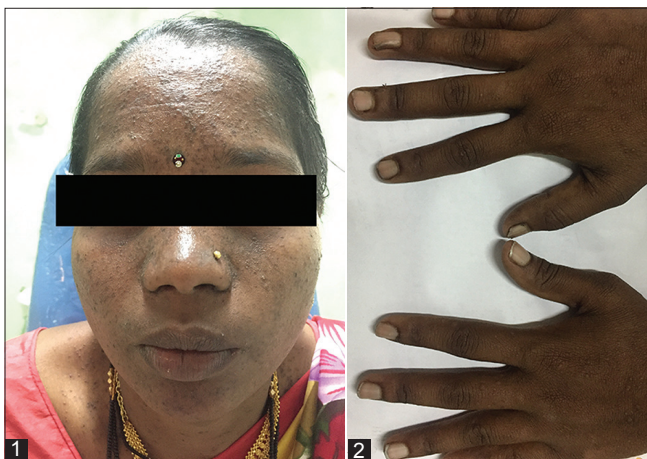Postoperative period was uneventful, and the patient enjoys 6/6 vision.

Discussion

Dermatologic manifestations include areas of papules with greasy scales and crusts which are hyperkeratotic, itchy, odoriferous, and prone to secondary bacterial infection. Lesions are seen distributed in a seborrheic pattern on the face, at the hair margins, the middle and upper chest,

intertriginous areas, ears and back, exacerbated by heat, exercise, and sunlight. Hemorrhage is rarely seen in these lesions. Skin changes typically begin in the late first to fourth decades, most commonly beginning around the time of puberty.^[2] Characteristic nail changes include red or white longitudinal bands of varying width ending in a pathognomonic notch at the free margin of the nail, and nails are often very brittle. Being a predominantly dermatological disease, ocular manifestations are rare in keratosis follicularis. They can present as punctate corneal epithelial defects (photophobia), asymptomatic opacities in periphery of cornea,^[4,5] bilateral corneal subepithelial infiltrations, corneal ulcerations, or conjunctival keratosis.^[1] Patients with Darier's are also prone to recurrent herpes keratitis^[6] and episcleritis. There have been rare reports of other abnormalities including cataract, basal cell carcinoma,^[7] retinal detachment, and in some patients, typical retinitis pigmentosa^[8] and even horn-like growths^[9] along the lid margin. Diagnosis is made predominantly on clinical features and histopathological examination [Fig. 5]. On light microscopy, features of dyskeratosis with classic corps, ronds, and grains believed to represent dead or dying keratinocytes, acantholysis, and suprabasal cleaving or lacunae are typical. Electron microscopy shows a decrease in the number of desmosomes with loss of tonofilament-desmosomal association in epidermal cells.^[2] The patient here presented with hyperkeratotic lesions on her forehead, face, upper back, and hands. She also had white longitudinal striations in her nails and ophthalmologically presented with unilateral total cortical cataract and old keratic precipitates. Since no other factors were found to cause this, we conclude that she had an episode of herpes simplex virus uveitis that resulted in such a lesion. We also observed lid edema and ecchymosis in the periorbital region on scrubbing the skin and attribute this to skin irritation which may have caused hemorrhage into the skin lesion and exacerbation of the condition.

Pathogenesis lies in ATP2A2 defective gene that encodes the sarco/endoplasmic reticulum Ca⁺ ATPase isoform 2 (SERCA2). It is a calcium pump and SERCA2 plays an important role in cell-to-cell adhesion and abnormal keratinization. Abnormal keratinocyte-keratinocyte adhesion



Figures 1 and 2: (1) Multiple hyperkeratotic lesions on skin. (2) Nail changes - white longitudinal band seen all along the length of the nail. Nail changes typically do not involve all the nails

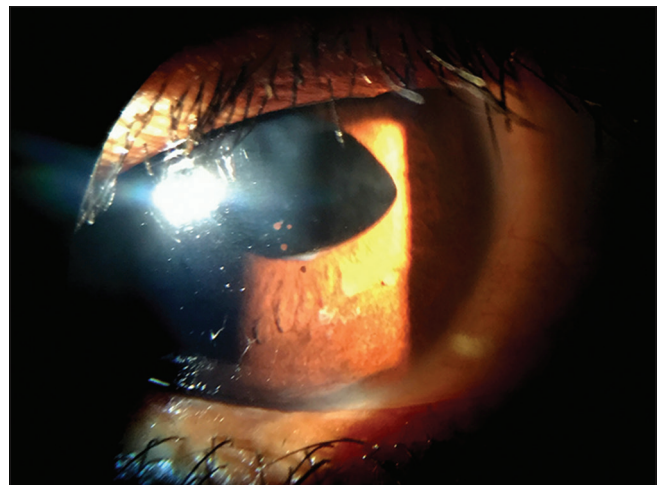


Figure 3: Postoperative picture of the right eye showing keratic precipitates

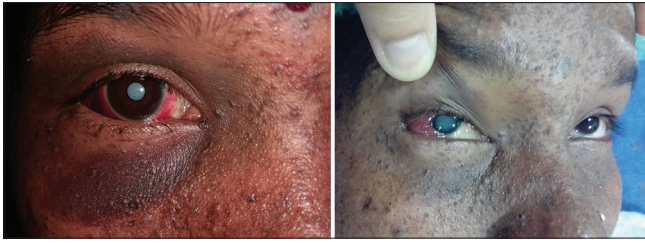


Figure 4: Subconjunctival hemorrhage with ecchymosis seen on vigorous lid scrubbing

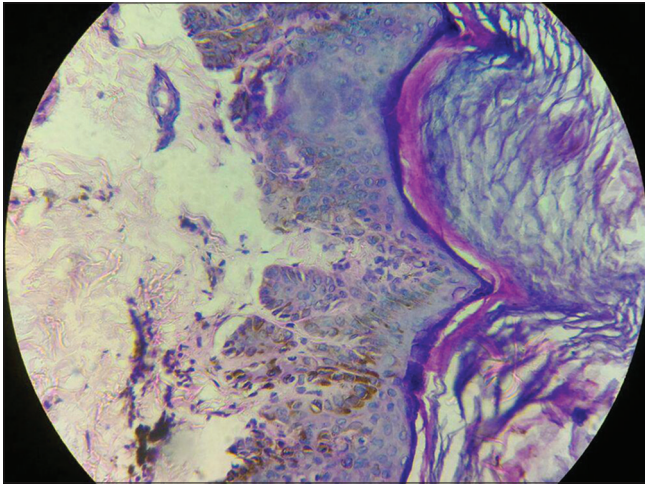


Figure 5: Histopathologic picture showing hyperkeratosis with irregular acanthosis and papillomatosis with focal areas of dyskeratosis suggestive of Darier–White disease

and aberrant epidermal keratinization are seen with loss of desmosomes, breakdown of desmosome–keratin intermediate filament attachment, and perinuclear aggregates of keratin intermediate filament. Some studies have suggested that alterations in calcium regulation could affect synthesis, folding, or trafficking of the desmosomal proteins, which probably caused opacification of the lens due to affection of the lens epithelium responsible for the formation of transparent fibers. Alternatively, another theory states that calcium dysregulation leads to impaired control of cell cycle checkpoints, leading to increased epidermal sensitivity to skin trauma and subsequent keratinocyte apoptosis, which might explain the lesions that occurred after scrubbing of the eye.^[10]

Conclusion

To conclude, Darier–White disease is a skin disorder with ocular manifestations that one has to keep in mind while treating such patients.

Declaration of patient consent

The authors certify that they have obtained all appropriate patient consent forms. In the form the patient(s) has/have given his/her/their consent for his/her/their images and other clinical information to be reported in the journal. The patients understand that their names and initials will not be published and due efforts will be made to conceal their identity, but anonymity cannot be guaranteed.

Financial support and sponsorship

Nil.

Conflicts of interest

There are no conflicts of interest.

References

1. Roy F. Ocular Syndromes and Systemic Diseases. 3rd ed. Iowa: MedRounds Publications Inc.; 2008. p. 108.
2. Sybert V. Genetic Skin Disorders. New York: Oxford University Press; c1997. p. 88-92.
3. Takagi A, Kamijo M, Ikeda S. Darier disease. *J Dermatol* 2016;43:275-9.
4. Blackman HJ, Rodrigues MM, Peck GL. Corneal epithelial lesions in keratosis follicularis (Darier's disease). *Ophthalmology* 1980;87:931-43.
5. Mohamed KN. Darier's disease and corneal opacity. *Dermatologica* 1991;182:205.
6. Radia M, Gilhooley MJ, Panos C, Claoué C. Recurrent presumed herpes simplex keratitis and episcleritis in keratosis follicularis (Darier's disease). *BMJ Case Rep* 2015;2015. pii: Bcr2015210772.
7. Russell DJ, Dutton JJ, Fowler AM. Darier disease mimicking Basal cell carcinoma of the eyelid. *Ophthal Plast Reconstr Surg* 2009;25:144-6.
8. Itin P, Büchner SA, Gloor B. Darier's disease and retinitis pigmentosa; is there a pathogenetic relationship? *Br J Dermatol* 1988;119:397-402.
9. Wright JC. Darier's disease. *Am J Ophthalmol* 1963;55:134-6.
10. Savignac M, Simon M, Edir A, Guibbal L, Hovnanian A. SERCA2 dysfunction in Darier disease causes endoplasmic reticulum stress and impaired cell-to-cell adhesion strength: Rescue by Miglustat. *J Invest Dermatol* 2014;134:1961-70.