

Uncemented femoral revision arthroplasty using a modular tapered, fluted titanium stem

5- to 16-year results of 163 cases

Dieter C Wirtz^{1*}, Sascha Gravius^{1*}, Rudolf Ascherl², Miguel Thorweihe¹, Raimund Forst⁴, Ulrich Noeth³, Uwe M Maus⁵, Matthias D Wimmer¹, Günther Zeiler⁶ and Moritz C Deml¹

¹Department of Orthopaedic and Trauma Surgery, University Hospital Bonn, Bonn; ²Department of Orthopaedic Surgery, Zeisigwald Hospital Bethanien, Chemnitz; ³Department of Orthopaedic Surgery, University Hospital Würzburg, Würzburg; ⁴Department of Orthopaedic Surgery, University Hospital Erlangen/Nürnberg, Erlangen; ⁵Department of Orthopaedic Surgery, Pius-Hospital Oldenburg, Oldenburg; ⁶Department of Orthopaedic Surgery, Rummelsberg Hospital, Schwarzenbruck, Germany.

*These authors contributed equally.

Correspondence: dieter.wirtz@ukb.uni-bonn.de

Submitted 14-01-04. Accepted 14-05-29

Background and purpose — Due to the relative lack of reports on the medium- to long-term clinical and radiographic results of modular femoral cementless revision, we conducted this study to evaluate the medium- to long-term results of uncemented femoral stem revisions using the modular MRP-TITAN stem with distal diaphyseal fixation in a consecutive patient series.

Patients and methods — We retrospectively analyzed 163 femoral stem revisions performed between 1993 and 2001 with a mean follow-up of 10 (5–16) years. Clinical assessment included the Harris hip score (HHS) with reference to comorbidities and femoral defect sizes classified by Charnley and Paprosky. Intraoperative and postoperative complications were analyzed and the failure rate of the MRP stem for any reason was examined.

Results — Mean HHS improved up to the last follow-up (37 (SD 24) vs. 79 (SD 19); $p < 0.001$). 99 cases (61%) had extensive bone defects (Paprosky IIB–III). Radiographic evaluation showed stable stem anchorage in 151 cases (93%) at the last follow-up. 10 implants (6%) failed for various reasons. Neither a breakage of a stem nor loosening of the Morse taper junction was recorded. Kaplan-Meier survival analysis revealed a 10-year survival probability of 97% (95% CI: 95–100).

Interpretation — This is one of the largest medium- to long-term analyses of cementless modular revision stems with distal diaphyseal anchorage. The modular MRP-TITAN was reliable, with a Kaplan-Meier survival probability of 97% at 10 years.

Long-term outcome of femoral revision arthroplasty depends on proper restoration of joint mechanics by reconstructing the anatomic center of rotation in combination with fixation that provides long-term stability (Gravius et al. 2011).

The published medium- to long-term survival rates of cemented revision THA are between 35% and 91% (Kavanagh and Fitzgerald 1985, Retpen et al. 1989, Stromberg and Herberts 1996, Weber et al. 1996). One stage cemented stem revision leads to increased bone loss (Rader and Eulert 2005) and is associated with a much higher rate of re-revision than cementless femoral stem revision (Dohmae et al. 1988). Cemented revision stems only appear to be advisable for less active patients with an average life expectancy of less than 10 years (Weiss et al. 2011). In comparison, uncemented revision hip arthroplasty gives medium- to long-term survival rates of 60–97% (Head et al. 2001, Engh et al. 2002, Kwong et al. 2003).

Over the years, uncemented modular revision stems have become increasingly popular (Fink et al. 2009). In complex revision surgery, modular uncemented femoral implants may overcome the limitations of non-modular and mostly straight stems—for example, the difficulty in establishing femoral leg length, femoral anteversion, and soft tissue tension (Berry 2002, Mumme et al. 2004, Gutierrez et al. 2007). Modular cementless implant systems with a distal diaphyseal press-fit concept provide greater variability in difficult anatomical situations than non-modular revision stems (Berry 2002). The modular-designed components offer the opportunity to customize the prosthesis intraoperatively to the individual ana-



Figure 1. The MRP-TITAN curved stem, shown with and without proximal extension and distal locking bolts.

tomical situation, allowing nearly physiological joint reconstruction (Gravius et al. 2011).

Based on published studies, the modular cementless MRP-TITAN revision stem with its distal diaphyseal fixation concept has well-proven short-term effectiveness in femoral revision, especially for large femoral defects (types IIC and III, as described by Paprosky et al. (1990)). Previous studies have shown low mechanical failure rates of 2–5% after 4–5 years of follow-up (Wirtz et al. 2000, Mumme et al. 2004, 2007).

Due to the relative lack of medium- to long-term results of femoral modular cementless revision surgery in the literature, we investigated the clinical and radiographic medium- to long-term outcome of femoral revision arthroplasty with the MRP-TITAN stem in a consecutive patient series.

Patients and methods

Implant

The modular MRP-TITAN stem (Peter Brehm GmbH, Weisendorf, Germany) of titanium alloy (Ti6Al7Nb) is designed for cementless implantation with initial distal diaphyseal press-fit fixation (Wirtz et al. 2000, Mumme et al. 2004, 2007). Essentially, the modularity is achieved with 3 components: (1) the distally tapered femoral stem with longitudinal parabolic ribs; (2) the optional extension sleeve; and (3) 3 different neck models with a standard Euro taper—12/14. The neck components are available with different neck-stem angles of 130°

(37-mm offset) and 123° (47-mm offset). All components are locked in situ with a special proximal expansion bolt. Intraoperatively, the surgeon is able to adjust the overall length between 190 mm and 420 mm with an adjustable free range of rotation of the proximal neck. The head-trochanter distance is adjusted by changing the size of head and the femoral neck component. To reach a proper rotational stability in larger metaphyseal bone defects, the longer curved stems (260 mm and 320 mm) are available with 2 distal transversal drill holes to insert locking bolts if necessary (Figure 1).

Patients

Between 1993 and 2003, 163 cementless femoral revision arthroplasties using the MRP-TITAN stem were performed in 159 consecutive patients with a minimum follow-up of 5 years.

The patients were operated in 4 German centers specialized in revision THA in clinical routine. The data presented were analyzed retrospectively as anonymized aggregated data.

Inclusion criteria were as follows: revision THA with a bone deficiency graded Paprosky I–III (Paprosky et al. 1990). Exclusion criteria were (1) ASA 4 grading, (2) cardiac insufficiency graded NYHA IV, (3) systemic or local neoplasia, and (4) bone deficiency which would preclude the use of a diaphyseal press-fit fixation of the MRP-TITAN stem.

Clinical evaluation

Clinical evaluation included intraoperative and postoperative complications, reason for revision surgery, implant failure, pre- and postoperative function as measured by the Harris hip score (HHS) with reference to the Charnley classification (Charnley 1972), and femoral bone defects according to Paprosky et al. (1990). In addition, the patients' subjective satisfaction with revision surgery was recorded routinely. They had to state whether they were very satisfied, partly satisfied, or not satisfied.

Radiographic evaluation

A plain pelvis radiograph and a Lauensteins' view were obtained preoperatively and in the clinical follow-up routine (scale 1:1.15). The radiographs were evaluated by one senior surgeon who was blind regarding patient data, for signs of implant loosening as described by Kavanagh and Fitzgerald (1985), periprosthetic radiolucencies in zones 1–7 according to Gruen, secondary axial implant migration, and varus or valgus tilt.

As reference for measurements and correction for magnification, we used the diameter of the prosthesis head and the prosthesis. Implant tilting of more than 5° was regarded as clinically significant, and it was estimated by measuring the angle between the medial cortical femur and the medial side of the prosthesis. Periprosthetic changes of the bony structure (regeneration, resorption, radiolucencies, and osteolysis) were assessed according to the methods published by Engh et al. (1990).

Table 1. Patient data

Patients, n	159
Prostheses, n	163
Patients who died with follow-up of > 5 years, n	3
Mean age at implantation (SD) (range)	66 (10) (32–87)
Mean age at last follow-up (SD) (range)	76 (10), (48 – 97)
Sex (F / M)	97 / 62
Males, %	39
Mean weight (SD) (range), kg	75 (13) (44–110)
Mean height (SD) (range), cm	167 (9) (112–192)
Mean BMI (SD) (range), kg/m ²	27 (4) (16–50)
Mean HHS preoperatively (SD) (range)	37 (24) (4–97)
Mean HHS postoperatively (SD) (range)	79 (19) (4–100)
Left / Right	86 / 77
Indication for revision THA, n (%)	
Aseptic stem loosening	
originally cemented	95 (58)
originally uncemented	61 (37)
Septic stem loosening	
originally cemented	4 (3)
originally uncemented	3 (2)

Implants with axial migration of > 5 mm, progressive signs of osteolysis, and/or complete periprosthetic radiolucency were classified as unstable or loosened.

The preoperative proximal femoral bone defects were classified as described by Paprosky et al. (1990) and Pak et al. (1993). When most of the patients in our study had been operated, Paprosky published the first version of his defect classification. In this version, he only classified the defect as grades I, IIA, IIB, IIC, and III. This must be considered when our results are being analyzed. If there were any discrepancies between the preoperative and intraoperative findings, the intraoperative classification was considered definitive.

The Brooker classification was used to evaluate periarticular ossifications (PAO).

Statistics

The recorded, anonymized analog values were digitized and exported to Microsoft Excel 2010 and SPSS version 21.0. We performed Kaplan-Meier survivorship analysis with the endpoint “failure of the implant for any reason” using SPSS. The testing between groups was done with log-rank test. The 95% confidence interval (CI) was calculated as described by Altman et al. (2000). We used the paired t-test and an ANOVA with post hoc Bonferroni analysis in the case of multiple-comparison testing.

Results

138 cases (85%) were revised completely; in 13 cases (8%), only the stem was exchanged. In 12 cases (7%) a Girdlestone situation was existend after 2-stage treatment of a periprosthetic joint infection. Marked bony defects (type IIB, IIC, and III according to Paprosky) were found in 99 cases (61%). In

Table 2. Pre- and postoperative Harris hip score in relation to Charnley classification and to the prevailing bone defects classified by the criteria of Paprosky et al.

	n (%)	HHS preop., mean (SD)	HHS postop., mean (SD)	p-value
Charnley classification				
Charnley A	65 (40)	44 ^{a, b} (28)	83 (18)	< 0.001
Charnley B	78 (48)	34 ^a (22)	78 (18)	< 0.001
Charnley C	20 (12)	25 ^b (19)	76 (21)	< 0.001
Femoral defect class				
Paprosky I	29 (18)	52 ^{c, d, e} (24)	87 (12)	< 0.001
Paprosky II A	35 (22)	36 (23)	74 (26)	< 0.001
Paprosky II B	43 (26)	36 ^c (23)	83 (15)	< 0.001
Paprosky II C	23 (14)	27 ^d (20)	74 (21)	< 0.001
Paprosky III	33 (20)	33 ^e (22)	78 (15)	< 0.001

^{a, b} The mean preoperative HHS values were significantly different between groups A and B ($p = 0.04$) and groups A and C ($p = 0.007$), but not between groups B and C. There was no significant difference in mean postoperative HHS values between Charnley groups. ^{c, d, e} The difference in mean preoperative HHS values was significant between groups I and IIB ($p = 0.04$), I and IIC ($p = 0.001$), and I and III ($p = 0.02$). There was no significant difference in mean preoperative HHS values between the other groups and there was no significant difference in mean postoperative HHS values between any of the Paprosky groups.

51 cases (31%), the proximal femoral deficiency was augmented by cancellous autograft and/or allograft. (Tables 1 and 2; Figures 2 and 3)

Clinical evaluation

Clinically, the HHS improved from a mean preoperative score of 37 (SD 24; 4–97) points to 79 (SD 19; 4–100) points at the last follow-up ($p < 0.001$). Comparison of the pre- and postoperative HHS with relation to the prevailing bone defects classified by the criteria of Paprosky (types I–III) showed an increase in HHS at the last follow-up for each type of bone defect ($p < 0.001$). The postoperative functional result was the same in patients with only slight femoral bone defects (Paprosky type I and IIA) and in those with larger defects (Paprosky type IIB, IIC, and III). With respect to prevailing comorbidities according to Charnley (types A–C), the healthier patients in group A had a higher preoperative HHS than those in groups B and C; the postoperative HHS values showed no significant differences between groups (Table 2).

According to the patients' subjective satisfaction statements, 130 (80%) were very satisfied with the result achieved, 28 patients (17%) were only partially satisfied, and 5 patients (3%) were not satisfied.

Radiographic evaluation

141 cases (87%) had stable stem integration with good contact between implant and bone without any migration and radiolucencies. 15 cases (9%) showed a radiolucency of less than 1 mm in 1 Gruen zone. In 7 cases (4%), radiolucencies of more than 1 mm in 1 zone were detected, but without any

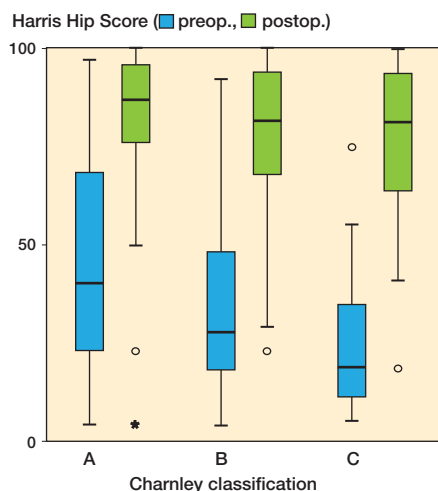


Figure 2. Pre- and postoperative HHS values according to the Charnley classification.

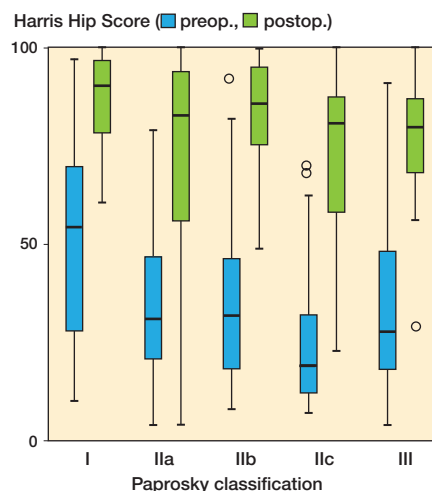


Figure 3. Pre- and postoperative HHS values according to the Paprosky classification.

Table 3. Complications

	n
Intraoperative complications	
Anesthesia-related	0
Shaft fissures	18
Pre-existing shaft fissure	0
Shaft fracture	6
Pre-existing shaft fracture	1
Trochanteric fracture	5
Vascular lesion	0
Lesion of the peroneal nerve	2
Early postoperative complications (< 6 weeks)	
Phlebothrombosis	4
Pulmonary embolism	1
Hematoma	2
Hematoma requiring revision	0
Wound healing disorder	3
Deep infection	3
Pneumonia	0
Dislocation (once)	2
Dislocations (recurrent)	4
Periprosthetic fracture	1
Late postoperative complications (> 6 weeks)	
Periprosthetic fracture	5
Acetabular cup loosening	5
Dislocation (once)	5
Dislocations (recurrent)	9
Aseptic loosening	1
Late infection	1
Subsidence ≤ 5 mm	10
Subsidence > 5 mm	7
Lysis around Morse taper junction	2

Table 4. Failures

	n
Failures overall	10 (6%)
Subsidence > 5 mm	7
Progressive radiolucent lines/aseptic loosening	1
Periprosthetic infection	1
Periprosthetic fracture (Vancouver B2)	1

progression during the follow-up period and with no evidence of aseptic loosening. All these stems showed a satisfactory distal fixation. Most radiolucencies were observed in zones 1 and 7.

The radiographic analysis revealed stem migration of ≤ 5 mm in 10 cases (6%). No further subsidence occurred after

1 year. They were classified as being “secondary stabilized” without any clinical criteria of loosening.

Complications and reasons for revision

Intraoperative complications occurred in 30 cases (18%) (Table 3).

In 8 cases (5%), the MRP-TITAN failed due to aseptic loosening; in 7 (4%) of these cases, subsidence of more than 5 mm was recorded. An example of aseptic subsidence is shown in Figure 4. In 1 case (1%), the MRP failed due to late infection and was treated with a 2-stage exchange procedure (Figure 5).

Overall, traumatic periprosthetic fractures occurred in 5 cases (3%). In 4 of these cases, the implant was stable and the fracture was successfully treated by open reduction and internal fixation. In 1 case (1%), the stem was unstable in a case of Vancouver B2 fracture; thus, the stem had to be exchanged with a longer variant to bridge the fracture sufficiently. An additional open reduction and internal plate fixation was performed.

The overall failure rate was 6%, with 10 failed prostheses (Table 4). None of the MRP-TITAN stems had breakage or uncoupling of the modular components.

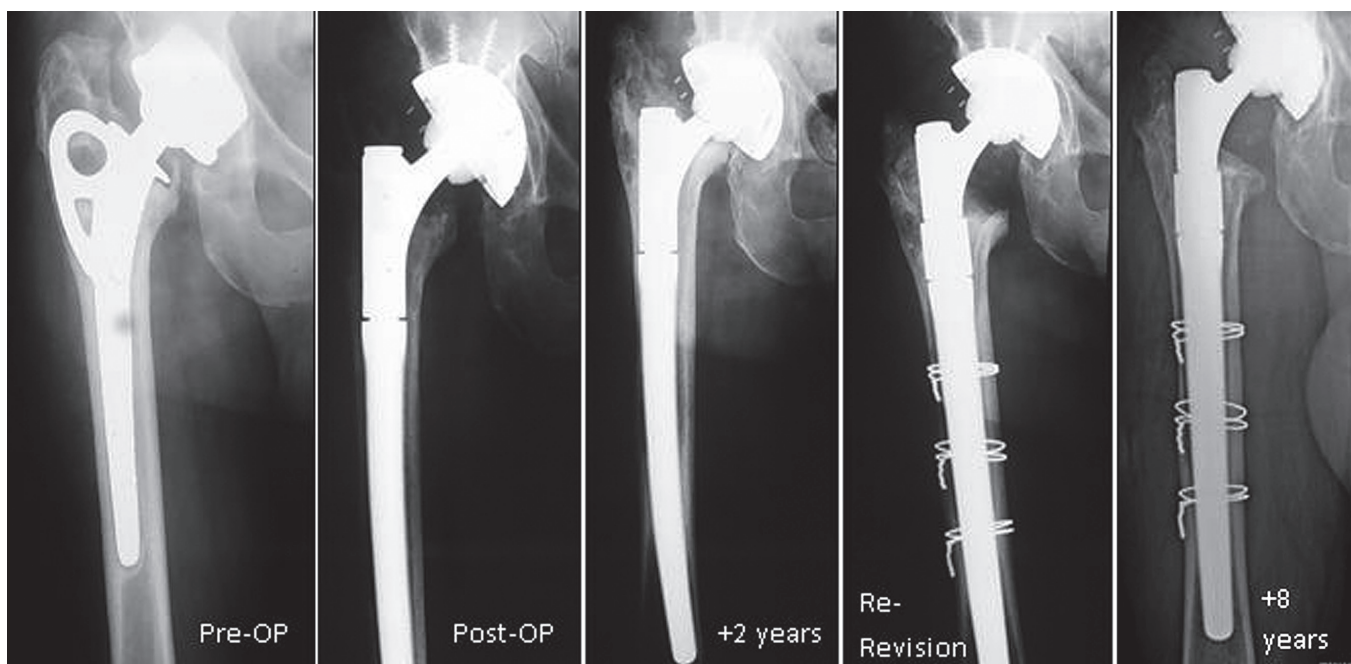


Figure 4. Subsidence with aseptic loosening of an MRP stem 2 years after revision. Revision of an aseptic loosened cementless stem and rough-surfaced Judet cup was performed with a curved MRP stem and a cementless cup in a 77-year-old man. 2 years after revision, there was a proximal 15 mm of subsidence with clinically almost fully impaired function. After exclusion of a periprosthetic infection by joint aspiration and microbiological investigation, a re-revision of the stem was performed. The cup showed a proper thigh ingrowth. A thicker MRP stem was implanted, showing good osseous integration 8 years postoperatively.

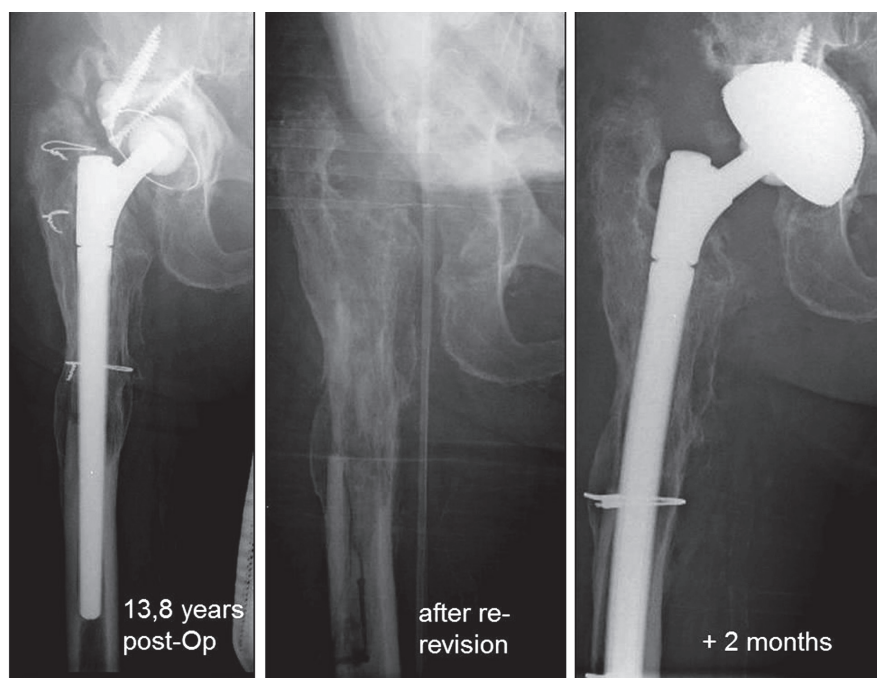


Figure 5. A 75-year-old male patient with periprosthetic infection 13.8 years after revision surgery. Explantation with a femoral fenestration and a wide debridement was performed. Two months later, the infection consolidated; thus, a re-revision with a curved MRP stem and a cementless cup could be performed. The previously performed fenestration was secured with 2 wires around the femur.

Kaplan-Meier survival rate

The Kaplan-Meier survival probability for the MRP-TITAN stem with failure defined as being for any reason was 97% after 10 years (CI: 95–100) and 85% after 15 years (CI: 73–97) (Figure 6 and Table 5).

Subgroup analysis of stem survival according to pre-existing femoral defect size as classified by Paprosky showed no significant differences in survival rates ($p = 0.7$). The statistical analysis of survival according to comorbidities as classified by Charnley showed significantly lower survival in group C ($p = 0.01$) (Figures 7 and 8; Tables 6 and 7).

Discussion

We found that the previously published promising preliminary results regarding stem survival (Wirtz et al. 2000, Mumme et al. 2004, 2007, Wimmer et al. 2013) still remained at medium- to long-term follow-up in a large consecutive patient

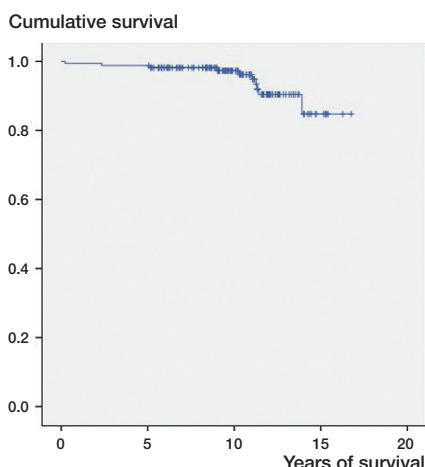


Figure 6. Kaplan-Meier overall survival rate.

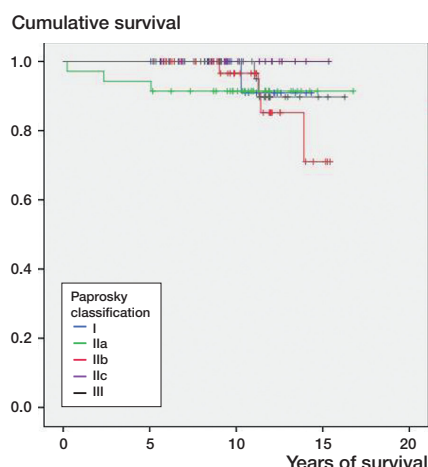


Figure 7. Kaplan-Meier survival rate according to size of the femoral defect (Paprosky).

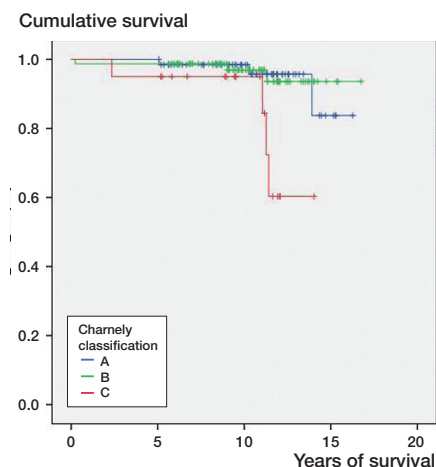


Figure 8. Kaplan-Meier survival rate according to comorbidities (Charnley classification).

Table 5. Details of Kaplan-Meier overall survival rate

Years of survival	Survival rate, %	95% CI
5	99	97–100
10	97	95–100
15	85	73–97

Table 6. Details of Kaplan-Meier survival rate according to size of the femoral defect (Paprosky)

	Years of survival	Survival rate, %	95% CI
Paprosky I	12	91	74–100
Paprosky IIa	12	91	82–100
Paprosky IIb	12	85	69–100
Paprosky IIc	12	100	n.a.
Paprosky III	12	90	76–100

Table 7. Details of Kaplan-Meier survival rate according to comorbidities (Charnley classification)

	Years of survival	Survival rate, %	95% CI
Charnley A	10	98	95–100
	12.5	96	90–100
Charnley B	10	97	93–100
	12.5	94	86–100
Charnley C	10	95	86–100
	12.5	60	28–92

series. We found a Kaplan-Meier survival rate of 97% after a mean follow-up of 10 years. These results appear encouraging compared to reported rates of aseptic loosening of 4–16% for femoral cementless revision THA with extensive porous-

coated stems, the Wagner stem and the modular Revitan system (Wagner and Wagner 1993, Böhm and Bischel 2001, Warren et al. 2002, Weeden and Paprosky 2002, Gutierrez et al. 2007, Fink et al. 2009, Randhawa et al. 2009)

Stem subsidence has been regarded as the major reason for failure of cement-free revision stems (Patel et al. 2010). Most subsidence of cementless stems appears to occur during the first year (Warren et al. 2002, Fink et al. 2009) as result of an insufficient initial diaphyseal press fit without secondary stabilization (Lie et al. 2004).

We found 7 stem failures (4%) due to axial migration and 1 aseptic loosening (1%). The modular Revitan stem has shown subsidence of 8–10% depending on the technique used for implantation (Fink et al. 2009). This may be caused by the specific geometry of the MRP stem. The combination of distal diaphyseal press-fit anchoring in the isthmus of the femur and the fluted taper shape of the stem with relatively sharp, indented longitudinal shaft-rips with the rough corundum-blasted implant surface, leading to minimal axial migration by facilitating bone ingrowth. Nevertheless, the main reason for failure of the implant was subsidence of more than 5 mm, even in our patients. Compared to other studies, the MRP showed a lower subsidence rate but the challenge of shaft revision with proper initial press fit still appears to be one of the main difficulties to be overcome. The crucial surgical factor is to ream the diaphyseal femoral canal to achieve a broad area of contact between implant and cortical bone over a distance of at least 7 cm (Mumme et al. 2007). Fink et al. (2009) published a minimum distance of 3 cm for the Revitan shaft. This might explain the higher rate of subsidence in their patients.

The overall dislocation rate (n = 20; 12%) was comparable with published results in equivalent bone-defect situations (Wagner and Wagner 1993, Böhm and Bischel 2001, Warren et al. 2002, Weeden and Paprosky 2002, Gutierrez et al. 2007). The potential advantage of modular stems might be the easy possibility of treating recurrent dislocations successfully by

altering the anteversion of the neck module and increasing the femoral offset without removing the distally fixed, tapered femoral stem.

Although it is well known that fretting and corrosion occur at all modular interfaces (Salvati et al. 1995), we did not observe any osteolysis in the periprosthetic bone around the modular junctions of the MRP-titanium stem. These clinical findings agree with the results of retrieval and laboratory studies reported by Schramm et al. (2000) and Gravius et al. (2007), who found in several material tests that the modular junctions of the MRP-titanium stem were stable and resistant to relevant wear mechanisms. This appears to be mainly due to the manufacturing process of optimizing the Morse taper junctions by adding induced internal stresses on their surface using the shot-peening technique, to avoid fracture and wear in modular connections.

A subgroup analysis with reference to the Charnley classification (types A–C) showed an improved HHS in each group. Regarding bone defects (Paprosky types I–III), we found an increase comparing the preoperative HHS and the last follow-up HHS measured for each type of bone defect. The postoperative functional result was the same in patients with only slight bone defects of the femur (Paprosky type I and IIa) and in those with larger defects (Paprosky type IIb, IIc, and III). Even though the formally healthier patients in group Charnley A had a higher mean preoperative HHS, the postoperative HHS in all groups were similar. The same could be shown for femoral defects according to Paprosky. Thus, proper reconstruction of the hip leads to an equivalent functional result regardless of the size of a pre-existing bony defect and comorbidities. These results are comparable to those for modular and non-modular cementless femoral revision implants published by Wagner and Wagner (1993), Grunig et al. (1997), Böhm and Bischel (2001), Gutierrez et al. (2007), and Fink et al. (2009)—and to our previously published short-term results (Wirtz et al. 2000, Mumme et al. 2004, 2007).

Kaplan-Meier survival analysis of the subgroups of the femoral defect classification according to Paprosky showed similar outcome for the single defect groups. Thus, we can conclude that the MRP-TITAN is equally reliable for Paprosky defects of classes I–III. Subgroup analyses dependent on comorbidities showed lower prosthesis survival in the more disabled patients (group C). The comorbidities may lead to a propensity for falls and osteoporosis, which would increase the risk of periprosthetic fractures or loosening of the prosthesis (Franklin and Malchau 2007).

The present study had some shortcomings. Firstly, due to the multicenter design, several surgeons performed the operations, even though all of them were experienced attending surgeons and used the MRP-TITAN stem in surgical practice over a period of years. This might be compensated by the high number of patients recruited.

Secondly, the design—as a retrospective and descriptive study without any control group—leads to a low level of evi-

dence. Future prospective controlled trials would seem essential. Even so, we have presented one of the largest series of cementless modular revision stems with a medium- to long-term follow-up.

Lastly, we did not include patients with extensive metaphyseal and diaphyseal defect situations with cortical thinning and a wide diaphyseal medullary canal. We could not therefore assess the success of the MRP-TITAN stem in cases of very large meta- and diaphyseal bone loss, which would diminish diaphyseal press-fit fixation and should be regarded as a contraindication.

In summary, the MRP-TITAN revision stem appears to be reliable in cases of femoral bone defects of types I–III according to Paprosky, as well as in cases with high functional deficiencies (Charnley type B and C), with a Kaplan-Meier survival rate of 97% after a mean follow-up of 10 years.

MCD, MT, MDW, and SG did the retrospective and descriptive analysis, carried out the statistical analysis of the dataset and drafted the manuscript. MCD, MT, RA, UN, UM, and RF contributed by performing patient follow-up visits, radiographic analysis, gathering of data, and translation or revision of the manuscript. DCW conceived the study and its design, was one of the main surgeons besides GZ, conducted the realization of the study and edited the manuscript. All the authors read and approved the final manuscript.

The study was funded by Peter Brehm GmbH, Weisendorf, Germany. The authors are grateful for the data supplied by the Wichernhaus Orthopaedic Clinic at Rummelsberg Hospital, Schwarzenbruck; the Orthopaedic University Medical Center, Würzburg; the Orthopaedic University Medical Center, Erlangen; and the University Medical Center, RWTH Aachen, Aachen.

Peter Brehm GmbH, Weisendorf, Germany, acted as sponsor of the study. SG has received research grants from the same institution. The authors declare that they have no other competing interests.

Altman D G, Machin D, Bryant T N, Gardner M J. Statistics with Confidence: Confidence Intervals and Statistical Guidelines, 2nd edition. British Medical Journal, Wiley 2000.

Berry D J. Femoral revision: distal fixation with fluted, tapered grit-blasted stems. *J Arthroplast* 2002; 17: 142–6.

Böhm P, Bischel O. Femoral revision with the Wagner SL revision stem: evaluation of one hundred and twenty-nine revisions followed for a mean of 4.8 years. *J Bone Joint Surg (Am)* 2001; 83: 1023–31.

Charnley J. The long-term results of low-friction arthroplasty of the hip performed as a primary intervention. *J Bone Joint Surg (Br)* 1972; 54: 61–76.

Dohmae Y, Bechthold J E, Sherman R E, Puno R M, Gustilo R B. Reduction in cement-bone interface shear strength between primary and revision arthroplasty. *Clin Orthop* 1988; (36): 214–20.

Engh C A, Massin P, Suthers K E. Roentgenographic assessment of the biologic fixation of porous-surfaced femoral components. *Clin Orthop* 1990; (257): 107–28.

Engh CA Jr, Ellis TJ, Koralewicz LM, McAuley JP, Engh CA Sr. Extensively porous-coated femoral revision for severe femoral bone loss: minimum 10-year follow-up. *J Arthroplast* 2002; 17: 955–960.

Fink B, Grossmann A, Schubring S, Schulz M S, Fuerst M. Short-term results of hip revisions with a curved cementless modular stem in association with the surgical approach. *Arch Orthop Trauma Surg* 2009; 129 (1): 65–73.

- Franklin J, Malchau H. Risk factors for periprosthetic femoral fracture. *Injury* 2007; 38 (6): 655–60.
- Gravius S, Mumme T, Andereya S, Maus U, Müller-Rath R, Wirtz D C. The morse taper junction in modular revision hip replacement. *Z Orthop Unfall* 2007; 145 (2): 157–60.
- Gravius S, Randau T, Wirtz D C. What can be done when hip prostheses fail? New trends in revision endoprosthetics. *Orthopade* 2011; 40 (12): 1084–94.
- Grünig R, Morscher E, Ochsner P E. Three- to 7-year results with the uncemented SL femoral revision prosthesis. *Arch Orthop Trauma Surg* 1997; 116 (4): 187–97.
- Gutierrez Del Alamo J, Garcia-Cimbrelo E, Castellanos V, Gil-Garay E. Radiographic bone regeneration and clinical outcome with the Wagner SL revision stem: a 5-year to 12-year follow-up study. *J Arthroplast* 2007; 22: 515–24.
- Head W C, Emerson R H Jr, Higgins L L. A titanium cementless calcar replacement prosthesis in revision surgery of the femur: 13-year experience. *J Arthroplasty* 2001; 16: 183–7.
- Kavanagh B F, Fitzgerald R H Jr. Clinical and roentgenographic assessment of total hip arthroplasty. A new hip score. *Clin Orthop* 1985; (193): 133–40.
- Kwong L M, Miller A J, Lubinus P. A modular distal fixation option for proximal bone loss in revision total hip arthroplasty: a 2- to 6-year follow-up study. *J Arthroplasty* 2003; 18: 94–7.
- Lie S A, Havelin L I, Furnes O N, Engesaeter L B, Vollset S E. Failure rates for 4762 revision total hip arthroplasties in the Norwegian Arthroplasty Register. *J Bone Joint Surg (Br)* 2004; 86 (4): 504–9.
- Mumme T, Müller-Rath R, Weisskopf M, Andereya S, Neuss M, Wirtz D C. The cement-free modular revision prosthesis MRP-hip revision stem prosthesis in clinical follow-up. *Z Orthop Ihre Grenzgeb* 2004; 142: 314–21.
- Mumme T, Müller-Rath R, Andereya S, Wirtz D C. Uncemented femoral revision arthroplasty using the modular revision prosthesis MRP-TITAN revision stem. *Oper Orthop Traumatol* 2007; 19: 56–77.
- Pak J H, Paprosky W G, Jablonsky W S, Lawrence J M. Femoral strut allografts in cementless revision total hip arthroplasty. *Clin Orthop* 1993; (295): 172–8.
- Paprosky W G, Lawrence J, Cameron H. Femoral defect classification: clinical application. *Orthop Rev (Suppl 9)* 1990; 19: 9–17.
- Patel P D, Klika A K, Murray T G, Elsharkawy K A, Krebs V E, Barsoum W K. Influence of technique with distally fixed modular stems in revision total hip arthroplasty. *J Arthroplasty* 2010; 25: 926–31.
- Rader C P, Eulert J. Verankerungstechniken. In: *Modulare Revisionsendoprothetik des Hüftgelenkes* (eds Thümler P, Forst R, Zeiler G (Hrsg)). Springer, Berlin, Heidelberg, New York 2005.
- Randhawa K, Hossain F S, Smith B, Mauffrey C, Lawrence T. A prospective study of hip revision surgery using the Exeter long-stem prosthesis: function, subsidence, and complications for 57 patients. *J Orthop Traumatol* 2009; 10: 159–65.
- Retpen J B, Varmarken J E, Jensen J S. Survivorship analysis of failure pattern after revision total hip arthroplasty. *J Arthroplasty* 1989; 4: 311–7.
- Salvati E A, Liebermann J R, Huk O L, Evans B G. Complications of femoral and acetabular modularity. *Clin Orthop* 1995; (319): 85–93.
- Schramm M, Wirtz D C, Holzwarth U, Pitto R P. The morse taper junction in modular revision hip replacement—a biomechanical and retrieval analysis. *Biomed Technik* 2000; 45: 105–9.
- Stromberg C N, Herbets P A. Cemented revision total hip arthroplasties in patients younger than 55 years old. *J Arthroplasty* 1996; 11: 489–99.
- Wagner H, Wagner M. Femur revision prosthesis. *Z Orthop* 1993; 131 (6): 574–7.
- Warren P J, Thompson P, Fletcher M D. Transfemoral implantation of the Wagner SL stem. The abolition of subsidence and enhancement of osteotomy union rate using Dall-Miles cables. *Arch Orthop Trauma Surg* 2002; 122: 557–60.
- Weber K L, Callaghan J J, Goetz D D, Johnston R C. Revision of a failed cemented total hip prosthesis with insertion of an acetabular component without cement and a femoral component with cement. *J Bone Joint Surg (Am)* 1996; 78: 982–94.
- Weeden S H, Paprosky W G. Minimal 11-year follow-up of extensively porous-coated stems in femoral revision total hip arthroplasty. *J Arthroplasty (Suppl 1)* 2002; 17 (4): 134–7.
- Weiss R J, Stark A, Kärrholm J. A modular cementless stem vs. cemented long-stem prostheses in revision surgery of the hip: a population-based study from the Swedish Hip Arthroplasty Register. *Acta Orthop* 2011; 82 (2): 136–42.
- Wimmer M D, Randau T M, Deml M C, Ascherl R, Nöth U, Forst R, Gravius N, Wirtz D, Gravius S. Impaction grafting in the femur in cementless modular revision total hip arthroplasty: a descriptive outcome analysis of 243 cases with the MRP-TITAN revision implant. *BMC Musculoskelet Disord* 2013; 14: 19.
- Wirtz D C, Heller K D, Holzwarth U, Siebert C, Pitto R P, Zeiler G, Blencke B A, Forst R. A modular femoral implant for uncemented stem revision in THR. *Int Orthop* 2000; 24 (3): 134–8.